



Since January 2020 Elsevier has created a COVID-19 resource centre with free information in English and Mandarin on the novel coronavirus COVID-19. The COVID-19 resource centre is hosted on Elsevier Connect, the company's public news and information website.

Elsevier hereby grants permission to make all its COVID-19-related research that is available on the COVID-19 resource centre - including this research content - immediately available in PubMed Central and other publicly funded repositories, such as the WHO COVID database with rights for unrestricted research re-use and analyses in any form or by any means with acknowledgement of the original source. These permissions are granted for free by Elsevier for as long as the COVID-19 resource centre remains active.

ORIGINAL ARTICLES

COVID-19 pneumonia: Relationship between initial chest X-rays and laboratory findings[☆]



Á. Nava-Muñoz^{a,*}, S. Gómez-Peña^a, M.E. Fuentes-Ferrer^b, B. Cabeza^a,
A. Victoria^a, A. Bustos^c

^a Servicio de Radiología, Hospital Clínico Universitario San Carlos, Madrid, Spain

^b Servicio de Medicina Preventiva, Hospital Clínico Universitario San Carlos, Madrid, Spain

^c Jefe de Sección de Radiología de Tórax Hospital Clínico Universitario San Carlos, Madrid, Spain

Received 1 February 2021; accepted 7 June 2021

Available online 27 October 2021

KEYWORDS

SARS-CoV-2;
 COVID-19;
 Chest radiography;
 Laboratory findings;
 Radiographic score

Abstract

Objective: To analyze the initial findings in chest X-rays of patients with RT-PCR positive for SARS-CoV-2, and to determine whether there is a relationship between the severity of these findings and the clinical and laboratory findings.

Materials and methods: This retrospective study analyzed the relationship between initial chest X-rays and initial laboratory tests in symptomatic adults with nasopharyngeal RT-PCR results positive for SARS-CoV-2 seen at our center between February 29 and March 23, 2020. Among other radiologic findings, we analyzed ground-glass opacities, consolidations, linear opacities, and pleural effusion. We also used a scale of radiologic severity to assess the distribution and extent of these findings. Among initial laboratory findings, we analyzed leukocytes, lymphocytes, platelets, neutrophil-to-lymphocyte ratio, and C-reactive protein.

Results: Of 761 symptomatic patients, 639 (84%) required hospitalization and 122 were discharged to their homes. The need for admission increased with increasing scores on the scale of radiologic severity. The extent of initial lung involvement was significantly associated with the laboratory parameters analyzed ($P < .05$ for platelets, $P < .01$ for lymphocytes, and $P < .001$ for the remaining parameters), as well as with the time from the onset of symptoms ($P < .001$).

Conclusion: It can be useful to use a scale of radiologic severity to classify chest X-ray findings in diagnosing patients with COVID-19, because the greater the radiologic severity, the greater the need for hospitalization and the greater the alteration in laboratory parameters.

© 2021 SERAM. Published by Elsevier España, S.L.U. All rights reserved.

[☆] Please cite this article as: Nava-Muñoz Á, Gómez-Peña S, Fuentes-Ferrer ME, Cabeza B, Victoria A, Bustos A. Neumonía COVID-19: relación entre la radiografía de tórax inicial y los datos analíticos. Radiología. 2021;63:484–494.

* Corresponding author.

E-mail address: angelitonava@gmail.com (Á. Nava-Muñoz).

PALABRAS CLAVE

SARS-CoV-2;
 COVID-19;
 Radiografía de tórax;
 Resultados de
 laboratorio;
 Puntuación
 radiográfica

Neumonía COVID-19: relación entre la radiografía de tórax inicial y los datos analíticos**Resumen**

Objetivo: Analizar los hallazgos radiológicos iniciales en las radiografías de tórax de pacientes con RT-PCR positiva para SARS-CoV-2 y valorar si existe una relación entre la graduación de los mismos y los datos clínicos y analíticos.

Materiales y métodos: Estudio retrospectivo donde se analizaron las radiografías de tórax iniciales de pacientes adultos sintomáticos entre el 29 de febrero y el 23 de marzo de 2020 con una prueba RT-PCR nasofaríngea positiva para SARS-CoV-2 y una analítica inicial que incluía: leucocitos, linfocitos, plaquetas, cociente linfocitos/leucocitos y PCR. Entre otros hallazgos radiológicos se valoraron: opacidades en vidrio deslustrado, consolidaciones, opacidades lineales y derrame pleural. También la distribución y la extensión de estos hallazgos mediante un índice de gravedad radiográfico.

Resultados: De 761 pacientes sintomáticos, 639 precisaron ingreso hospitalario (84%) y 122 fueron dados de alta con aislamiento domiciliario. La necesidad de ingreso fue mayor cuanto más alto el índice de gravedad radiográfico. Existió una relación estadísticamente significativa entre la extensión de la afectación pulmonar inicial y los parámetros analíticos estudiados ($P < ,05$ para plaquetas, $P < ,01$ para linfocitos y $P < ,001$ para el resto), así como con los días de evolución desde el inicio de los síntomas ($P < ,001$).

Conclusión: La graduación de los hallazgos radiológicos al diagnóstico y su relación con los datos analíticos podría ser útil a la hora de valorar la evolución de pacientes con COVID-19, pues a mayor índice de gravedad radiográfico, mayor incidencia de ingreso hospitalario y parámetros analíticos más alterados.

© 2021 SERAM. Publicado por Elsevier España, S.L.U. Todos los derechos reservados.

Introduction

On 31 December 2019, a number of cases of a form of pneumonia of unknown aetiology detected in Wuhan, China, were reported to the World Health Organization (WHO). The causative agent of this pneumonia was identified as a novel virus belonging to the family *Coronaviridae*; it was subsequently named SARS-CoV-2 (severe acute respiratory syndrome coronavirus 2). The disease associated with this virus has been termed COVID-19 (COrona VIRUS Disease-2019). The WHO declared COVID-19 a public health emergency of international concern on 30 January 2020 and a pandemic on 12 March 2020.^{1,2} To date (18 December 2020), 1,797,236 confirmed cases and 48,926 deaths have been reported in Spain.³

The clinical spectrum of COVID-19 ranges from asymptomatic forms to severe forms with adult respiratory distress syndrome and death. The most commonly reported clinical signs are fever, cough, muscle pain, headache and shortness of breath.⁴ Severe or fatal disease is more common in admitted patients.⁵

Most initial radiology publications on COVID-19 focused on findings in computed tomography (CT) of the chest, since China started using this technique as a first-line option given its high sensitivity.⁶ The American College of Radiology (ACR), the Society of Thoracic Radiology (STR) and American Society of Emergency Radiology (ASER) subsequently discouraged systematic use of CT of the chest as a screening technique or as a first-line option in the diagnosis of patients with suspected COVID-19.⁷ A meta-analysis by Kim

et al. confirmed that, outside of China, where there is a low prevalence of COVID-19 (1%–22.9%), CT of the chest in patients with clinically suspected COVID-19 had a low positive predictive value (1.5%–30.7%).⁸ In another more recent meta-analysis, Xu et al. concluded that, in general, CT of the chest had good sensitivity for detecting COVID-19 pneumonia, especially in regions with severe outbreaks, and it was useful for detecting suspicious cases in early stages. Its sensitivity, on the other hand, was relatively low (25%–33%).⁹

Chest X-ray is less sensitive than CT and therefore may be normal in early stages of COVID-19, but it is a useful, fast, widely available and easy-to-perform technique. In most cases, it has been the only diagnostic imaging technique performed in these patients.⁷ However, chest X-ray has wide interobserver variability. To attempt to mitigate this variability, different objective methods of assessing the extent and severity of lung involvement have been used. For example, the Radiographic Assessment of Lung Edema (RALE) score was useful for measuring the extent of adult respiratory distress syndrome.¹⁰ More recently, different scoring systems, both for CT and for chest X-ray, that measure lung involvement in patients with COVID-19 have also been used.^{11–16}

To date, very few studies linking measurements of severity of chest X-ray findings to laboratory findings have been published.^{12,17} The main laboratory findings that have linked the severity of COVID-19 pneumonia and the clinical course of patients have been increased C-reactive protein (CRP), increased D-dimer, increased lactate dehydrogenase (LDH) and lymphopenia.¹⁸

The objective of this study was to determine whether there is a relationship between, on the one hand, findings on chest X-ray and measurement of their severity and, on the other hand, laboratory findings at the time of diagnosis and time elapsed since the onset of symptoms.

Material and methods

A descriptive, cross-sectional, retrospective, single-centre study was conducted. This study was approved by the Independent Ethics Committee at our hospital.

Study population

Symptomatic adult patients seen at our hospital between 29 February and 23 March 2020, with a positive nasopharyngeal reverse transcription-polymerase chain reaction (RT-PCR) test for SARS-CoV-2, a chest X-ray and blood testing at diagnosis were consecutively included.

Patients were excluded if they had a positive RT-PCR test but no chest X-ray at diagnosis, no initial laboratory testing and/or initial laboratory testing that did not include any of the five following values: leukocyte count, lymphocyte count, platelet count, lymphocyte-to-leukocyte ratio or CRP (Fig. 1).

Study variables

All data were collected from the patients' medical records.

Primary endpoints

The primary endpoints were radiological findings on the initial chest X-ray, measurement of their extent (X-ray severity score) and correlation thereof with initial laboratory findings.

The following findings on the chest X-rays were assessed: ground-glass opacities, consolidations, linear opacities, pleural effusion, lymphadenopathy, pulmonary fibrosis due to prior lung disease, emphysema and nodules/masses. The Fleischner Society criteria for defining radiological findings were followed.¹⁹ In cases in which ground-glass opacities or lung consolidations were present, data on their distribution – central (in the inner two thirds of the lung), peripheral (in the outer third) or diffuse (with involvement of both) – was collected. In addition, those lung fields that were affected (upper, middle or lower in each lung) and whether lesions were unilateral or bilateral were determined.

In order to grade the extent of lung involvement (X-ray severity score), each lung was divided into three fields separated by two horizontal lines: an upper line at the lower edge of the aortic arch and a lower line at the height of the pulmonary veins^{13,15} (Fig. 2). Extent of lung involvement was measured by adding up the score in each lung field (0 = normal and 1 = featuring involvement), yielding an overall score for both lungs of 0–6.

Regarding the initial laboratory data corresponding to the first chest X-ray, the following were collected: leukocyte count, lymphocyte count and percentage, platelet count, CRP, D-dimer, lactate dehydrogenase (LDH), ferritin and cre-

atine kinase (CK). The time elapsed between blood testing and chest X-ray never exceeded 24 h.

Independent variables

The anthropometric and demographic data that were collected were sex, age, weight and body mass index (BMI). BMI was divided into six categories: underweight (<18.5), normal weight (18.5–24.9), overweight (25–29.9), class 1 obesity (30–34.9), class 2 obesity (35–39.9) and morbid obesity (40–49.9).

The clinical data that were included were: patient origin (accident and emergency department or elsewhere), symptoms presented (fever, cough, shortness of breath, chest pain, gastrointestinal symptoms, syncope and other) and date of onset, need for admission in the first 30 days (yes or no), number of days of admission, prolonged admission (more than 30 days) and date of entering and exiting the hospital.

The dates of all the RT-PCR tests performed and the time elapsed from a positive RT-PCR test to a chest X-ray were collected.

Analysis of imaging and acquisition of information

Two second- and third-year diagnostic imaging residents (SGP and ANM, respectively) reviewed all reports corresponding to chest X-rays in systems with IMPAX 6.5.33 (Agfa-Gevaert N.V.). In cases in which no radiology report was available and uncertain cases, the residents consulted with two expert thoracic radiologists with 16 and 26 years of experience (BCM and ABGC, respectively); uncertainties were resolved by consensus.

Statistical analysis

Qualitative variables are presented with their frequency distribution. Quantitative variables are summarised with their mean and standard deviation (SD). Quantitative variables showing an asymmetrical distribution are summarised with their median and interquartile range (IQR). The distribution of continuous variables was evaluated by means of graphical inspection of histograms, box plots and Q–Q plots.

X-ray severity score was analysed as a categorical variable. For quantitative variables, means were compared using analysis of variance (ANOVA) or the Kruskal–Wallis test where quantitative variables did not have a normal distribution. The ordinal relationship between laboratory values and X-ray severity scores was evaluated using the Jonckheere–Terpstra non-parametric test. Qualitative variables were compared using the χ^2 test or Fisher's exact test where required. A level of significance of 5% was accepted for all tests. Data processing and analysis were performed using the SPSS Statistics V21.0 software package.

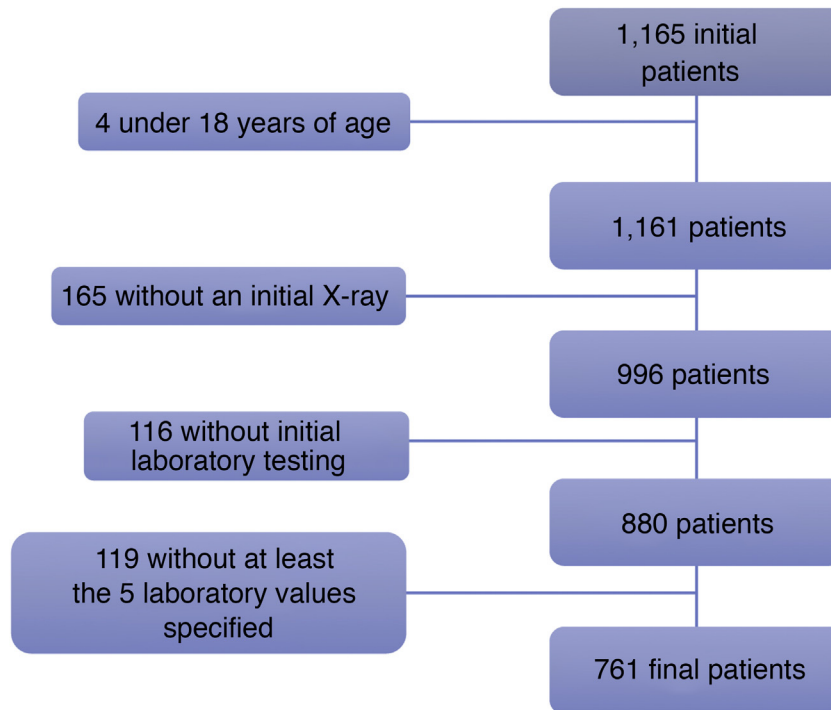


Figure 1 Of the 1165 initial patients, four patients under 18 years of age were excluded. Another 165 patients were excluded because they did not have a chest X-ray taken at the onset of their disease, and 116 more patients were excluded as they did not have initial blood testing done. Finally, of the 880 remaining patients, 119 lacked laboratory testing corresponding to all five values required for inclusion in this study: leukocyte count, lymphocyte count, platelet count, lymphocyte-to-leukocyte ratio and CRP.

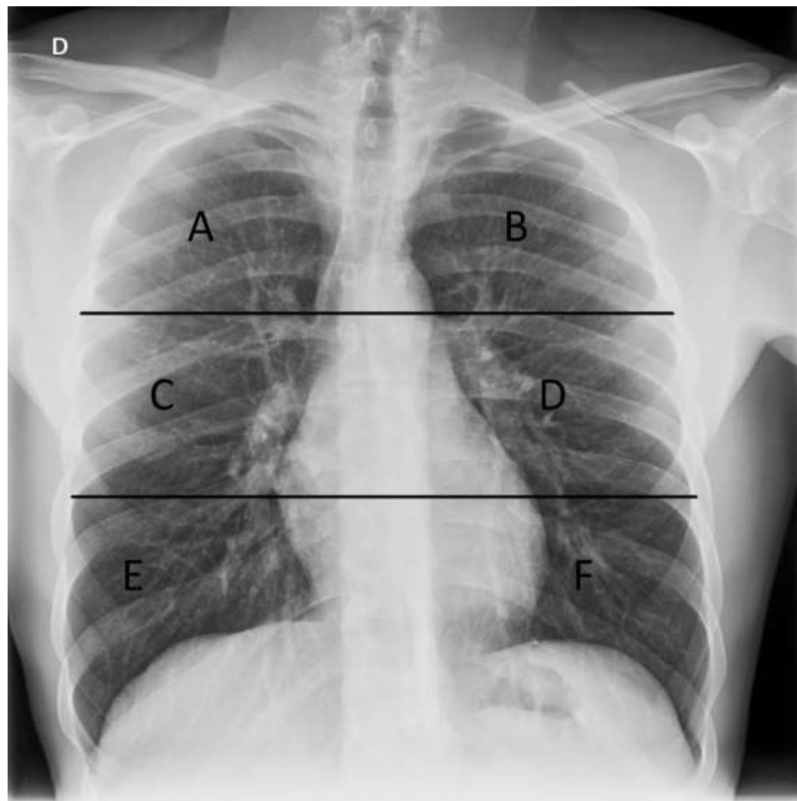


Figure 2 Chest X-ray with lung division into six fields used in our study to assess distribution of X-ray findings. The upper horizontal line is at the lower edge of the aortic arch and the lower horizontal line is at the height of the inferior pulmonary veins. A and B) Upper fields. C and D) Middle fields. E and F) Lower fields.

Table 1 Epidemiological and clinical characteristics of the patients.

Clinical characteristics	n 761 (%)
Sex	Men 391 (51.4%), women 370
Age (years)	
<30 years	22 (2.9%)
31–40	45 (5.9%)
41–50	93 (12.2%)
51–60	121 (15.9%)
61–70	125 (16.4%)
71–80	177 (23.3%)
81–90	149 (19.6%)
91–100	29 (3.8%)
BMI	
Underweight	3 (0.4%)
Normal weight	109 (14.3%)
Overweight	227 (29.8%)
Obesity	204 (26.9%)
Missing data	218 (28.6%)
Clinical presentation	
Cough	562 (73.9%)
Fever	566 (74.4%)
Shortness of breath	340 (44.7%)
Chest pain	102 (13.4%)
Gastrointestinal symptoms	193 (25.4%)
Syncope	15 (2%)
Time since the onset of symptoms (days)	
0–2	165 (21.7%)
3–5	221 (29%)
6–9	241 (31.7%)
>9	134 (17.6%)
Admitted	639 (84%)

Results

Descriptive analysis

Of the total of 1165 consecutive patients with a positive RT-PCR test for SARS-CoV-2 seen at our hospital between 29 February and 23 March 2020, 761 symptomatic adult patients comprised our study population (Fig. 1): 370 women and 391 men with a mean age of 65.8 ± 17.1 years. Regarding BMI, 0.4% of patients were underweight, 14.3% were normal weight, 29.8% were overweight and 26.9% were obese. Some data required to calculate BMI were not available for 218 (28.6%) patients (Table 1).

In total, 97.2% of the patients went to the accident and emergency department with symptoms, 14 patients contracted COVID-19 during ward admission and seven contracted the disease during intensive care unit admission.

Fever was seen in 74.4% of the 761 patients, cough in 73.9%, shortness of breath in 44.7%, gastrointestinal symptoms in 25.4%, chest pain in 13.4% and syncope in 2%. The time elapsed between onset of symptoms and medical consultation was 0–2 days in 165 patients (21.7%), 3–5 days

Table 2 Frequency of hospital admission by X-ray severity score.

X-ray severity score	Hospital admission	
	Yes	No
0	201 (68.1%)	94 (31.9%)
1	121 (85.8%)	20 (14.2%)
2	108 (95.6%)	5 (4.4%)
3	80 (98.8%)	1 (1.2%)
4	81 (97.6%)	2 (2.4%)
5 + 6 ^a	48 (100%)	0 (0%)

^a Due to the limited number of patients with a high severity score, a decision was made to combine severity scores of 5 and 6 into a single category.

in 221 (29%), 6–9 days in 241 patients (31.7%) and more than 9 days in 134 (17.6%) (Table 1).

Of the 761 patients, 639 required hospital admission (84%) whereas 122 were discharged to isolate at home. The higher the X-ray severity score, the greater the need for admission (Table 2).

X-ray analysis

A total of 368 chest X-rays (48.4%) were taken with the patient standing (posteroanterior and lateral views) and 393 chest X-rays (51.6%) were taken in an anteroposterior view, of which 361 (91.8%) were portable X-rays.

Of the 761 patients studied, 295 (38.8%) had a normal chest X-ray at diagnosis and 466 (61.2%) had pathological findings. Among the pathological X-rays, 168 (36%) showed increased density in the form of ground-glass opacities, while 202 showed lung consolidation (43.3%). Ground-glass opacities and lung consolidation were seen in 40 patients (8.5%), and lobar pneumonia was seen in 56 (12%) patients. Other less common findings were pleural effusion in 25 cases (5.4%), pulmonary fibrosis due to prior disease in 15 patients (3.2%), linear opacities in nine patients (1.9%), pulmonary emphysema in another nine cases (1.9%) and pulmonary nodules or masses in four cases (0.9%). Lymphadenopathy was not identified in any patient (Table 3).

Regarding the distribution of the chest X-ray findings, a peripheral distribution and bilateral involvement predominated: 417 cases (89.5%) showed a peripheral location; 45 cases (9.7%) showed a diffuse location, both central and peripheral; and four of 466 cases showed a central distribution (0.9%). Unilateral involvement was seen in 175 (37.6%) patients, whereas 291 had involvement in both lungs (62.4%) (Table 3).

The most commonly involved lung fields were the middle and lower fields: the right middle lung field in 56.4%, the right lower lung field in 55.8%; the left middle lung field in 57.5% and the left lower lung field in 55.6%. Involvement of the right upper lung field was found in 20.4% of cases, while involvement of the left upper lung field was found in 12.2% (Table 3).

Table 3 Findings on chest X-ray and X-ray severity score.

Findings on chest X-ray	n = 761 (%)	
Normal chest X-ray	295 (38.8%)	
Pathological chest X-ray	466 (61.2%)	
Ground-glass opacities	168 (36%)	
Consolidation	202 (43.3%)	
Consolidation and ground-glass opacities	40 (8.5%)	
Lobar pneumonia	56 (12%)	
Pleural effusion	25 (5.4%)	
Prior pulmonary fibrosis	15 (3.2%)	
Linear opacities	9 (1.9%)	
Pulmonary emphysema	9 (1.9%)	
Nodule/mass	4 (0.9%)	
Lymphadenopathy	0 (0%)	
Distribution by fields	n = 466 (%)	
	Left	Right
Upper	57 (12.2%)	95 (20.4%)
Middle	259 (57.5%)	263 (56.4%)
Lower	259 (55.6%)	260 (55.8%)
Involvement	n = 466 (%)	
Unilateral involvement	175 (37.6%)	
Bilateral involvement	291 (62.4%)	
Distribution	n = 466 (%)	
Peripheral distribution	417 (89.5%)	
Central distribution	4 (0.9%)	
Diffuse distribution	45 (9.7%)	
X-ray severity score	n = 466 (%)	
1	141 (30.3%)	
2	113 (24.2%)	
3	81 (17.4%)	
4	83 (17.8%)	
5	28 (6%)	
6	20 (4.3%)	

Measurement of severity of lung involvement

Of the 761 patients, 295 (38.8%) patients showed no initial involvement on X-ray (X-ray severity score 0); 141 (18.5%) patients had a score of 1; 113 (14.8%) patients had a score of 2; and 81 (10.6%) patients had a score of 3. Among the 131 remaining patients, the score was 4 for 83 (10.9%) patients, 5 for 28 patients (3.7%) and 6 for 20 patients (2.6%) (Table 3).

There were no statistically significant differences in X-ray severity score either by sex or by age group; however, there were such differences by BMI ($P < .001$), as BMI was higher in patients with a high X-ray severity score than in patients with a low X-ray severity score.

A statistically significant direct relationship was found between days elapsed since the onset of symptoms and X-ray severity score ($P < .001$). In patients with symptoms with an onset 0–2 days earlier, no findings were encountered in 59.4% of cases; this percentage progressively decreased to 24.6% in patients with symptoms with an onset 9 or more days earlier (Fig. 3).

Of the total of 466 X-rays with findings (61.2%), the frequency of ground-glass opacities was higher in low X-ray severity scores and decreased as those scores increased

($P < .001$), whereas the opposite happened with lung consolidation, which became more common as severity scores increased ($P < .001$) (Fig. 4 and Table 4).

The association between the laboratory values obtained (leukocytes, lymphocytes –absolute and relative values–, platelets, CRP, D-dimer, LDH, ferritin and CK) and the X-ray severity score for lung involvement on the initial chest X-ray was statistically significant in all cases. All laboratory values increased as the X-ray severity score increased, except for two, lymphocyte count and lymphocyte-to-leukocyte ratio, which decreased as involvement on X-ray increased. Statistical significance corresponded to $P < .05$ for platelets, $P < .01$ for lymphocytes and $P < .001$ for all other values (Table 5).

Discussion

Our study found a statistically significant relationship between the extent of involvement on the initial chest X-ray and the laboratory values studied, as well as the number of days since the onset of symptoms. The higher the X-ray severity score, the greater the need for hospital admission.

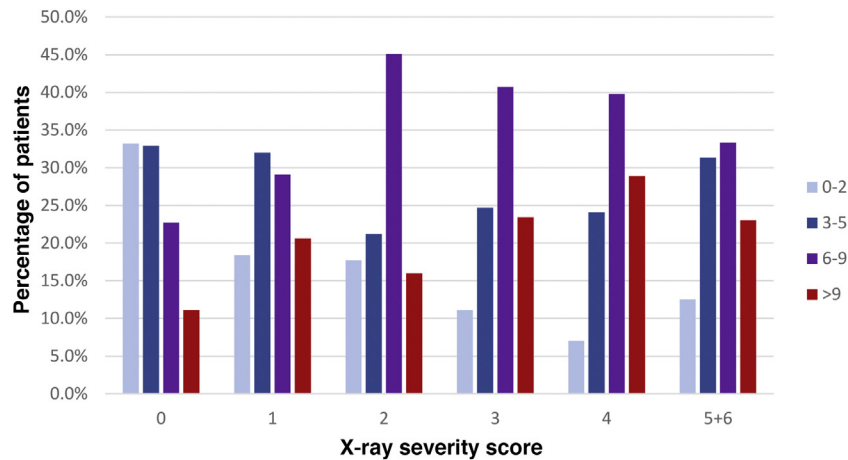


Figure 3 Percentage relationship between days elapsed since the onset of symptoms and X-ray severity score. The x-axis represents each X-ray severity score (scores 5 and 6 were combined due to limited numbers of patients). The y-axis represents the percentage of patients with a particular time since the onset of symptoms within each severity score.

Table 4 Incidence of ground-glass opacities and lung consolidation by X-ray severity score.

		Ground-glass opacities (n = 466)		Consolidation (n = 466)	
		No	Yes	No	Yes
X-ray severity score	1	79	62	111	30
	2	48	65	62	51
	3	38	43	26	55
	4	55	28	16	67
	5 + 6	38	10	9	39
	Total	258	208	224	242

Due to the limited number of patients with a high severity score, a decision was made to combine severity scores of 5 and 6 into a single category.

Fever and cough were the most commonly found clinical signs, followed by shortness of breath, gastrointestinal symptoms and chest pain.

In our study, 38.8% of symptomatic patients with COVID-19 had a normal chest X-ray at diagnosis and 61.2% had pathological findings; these rates were similar to those in other series, 60%–91%.^{15,20,21} Lung involvement was predominantly bilateral, in the lower lung fields and on the lung periphery, as reported in the medical literature.^{15,18,22} Consolidation was the most common finding, followed by ground-glass opacities, consistent with findings published in other series.¹⁵ Lobar pneumonia was seen in 12% of our patients. This finding usually suggests a bacterial aetiology; however, these patients had a positive PCR test and were not initially diagnosed with a bacterial infection. Pleural effusion was an uncommon finding and, in nearly all cases, secondary to another disease (history of heart failure or pre-existing chronic pleural effusion on prior chest X-rays).

Various authors have proposed scoring systems for radiological findings for both CT and chest X-ray in attempts to grade or measure the extent of lung involvement in patients with COVID-19 and link it to the clinical course of these patients. Warren et al. used the RALE score, which was useful for measuring the severity of adult respiratory distress syndrome.¹⁰ Other authors have subsequently used a modi-

fied version of this scoring system to estimate the severity of lung involvement in patients with COVID-19^{14–16,23,24} or have created their own measurement systems, such as that of Borghesi et al.,¹³ who found significantly higher X-ray severity scores ($P \leq .002$) in patients who died. Moreover, Xiao et al. identified a statistically significant association between X-ray severity score and need for intubation.²⁵

Older patients and patients with larger numbers of comorbidities have been reported to have more severe cases of SARS-CoV-2 pneumonia.²⁶ Toussie et al. found that male patients, older patients and patients with higher BMIs had a higher X-ray severity scores, while Borghesi et al. observed that X-ray severity scores were significantly higher in men and patients 50–80 years of age.^{11,27} However, our study did not find any statistically significant differences between the X-ray severity score and the age or sex of our patients, but did find such differences with BMI ($P < .001$).

Our study found a significant direct linear relationship between the presence of lung consolidations on chest X-ray and a higher X-ray severity score, as well as a significant inverse linear relationship between the frequency of ground-glass opacities and lower X-ray severity scores. As in the study by Toussie et al., a significant direct relationship was also seen between days elapsed since the onset of symptoms and X-ray severity score: as the number of days increased,

Table 5 Mean laboratory values by X-ray severity score.

	X-ray severity score	0	1	2	3	4	5 + 6	P value
Leukocytes	Median	5400	5200	5400	6000	6000	7850	<.001
	IQR	4100–7500	4300–6850	4500–7150	4800–8400	4500–8000	5925–10,775	
Lymphocytes	Median	900	900	1000	800	800	800	.007
	IQR	600–1300	600–1400	600–1400	600–1300	500–1100	600–1000	
Lymphocytes (%)	Median	17.6	18.4	18.1	14	12.1	10.6	<.001
	IQR	10.7–24.2	11.9–25.2	13.6–25.6	9.6–20.8	8.5–19	6.6–14.3	
Platelets	Median	171,000	163,000	180,000	187,000	185,000	195,000	.028
	IQR	13,9000–223,000	12,7500–212,000	13,7000–218,000	14,7000–224,500	14,9000–257,000	15,1000–235,750	
CRP	Median	3.11	3.3	6.1	8.2	10.7	14.1	<.001
	IQR	0.9–6.4	1.5–6.9	2.8–10.9	4.9–12.9	5.1–16.1	6.5–24.1	
D-dimer	Median	624	564	672	648	580	1013	<.001
	IQR	389–1202	374–877	403–1139	443–969	444–1101	783–1867	
LDH	Median	499	543	629	710	706	909	<.001
	IQR	403–634	448–554	531–789	517–838	584–949	761–1100	
Ferritin	Median	323	355	551	618	477	907	<.001
	IQR	142–791	165–711	250–974	349–1072	206–919	404–1737	
CK	Median	85	93	116	127	85	183	.001
	IQR	61–150	53–169	64–214	73–220	61–155	74–370	

Due to the limited number of patients with a high severity score, a decision was made to combine severity scores of 5 and 6 into a single category.

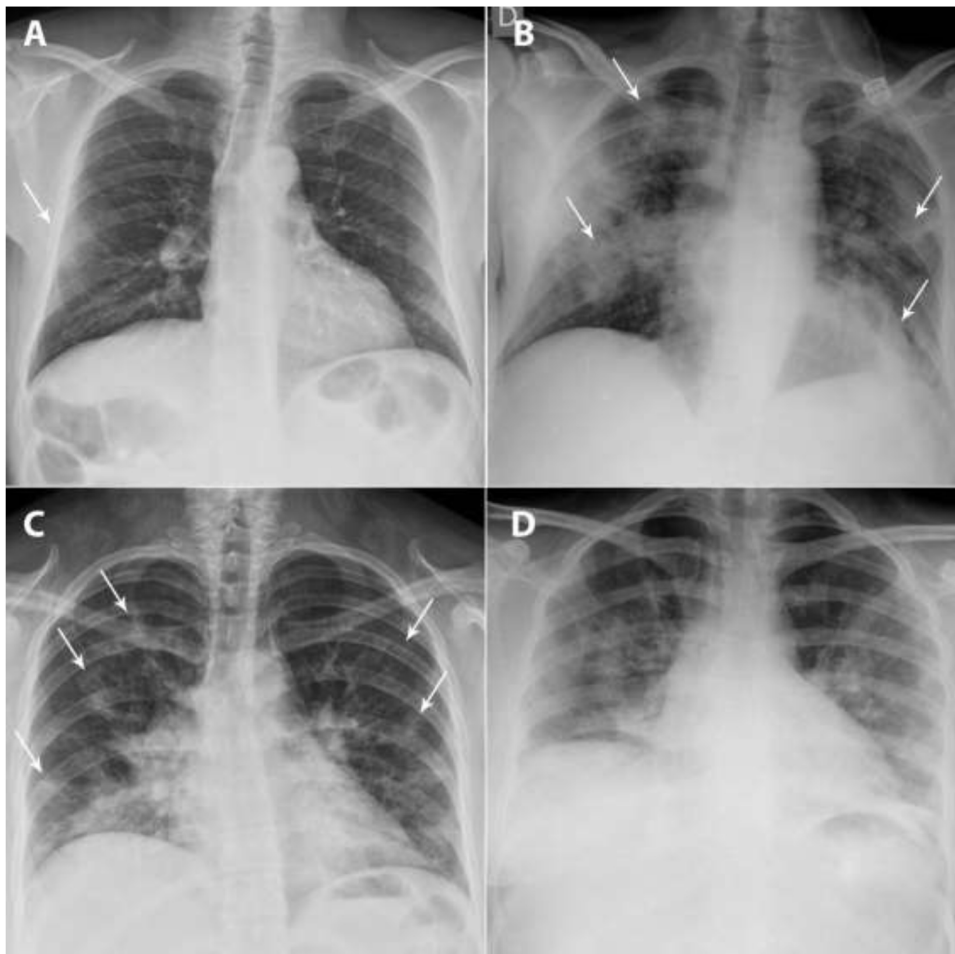


Figure 4 A and B) A 49-year-old man, a former smoker who quit smoking five years earlier, had a history of hypertension, dyslipidaemia, hypertensive cardiomyopathy, hyperuricaemia, kidney transplantation and total thyroidectomy due to papillary thyroid carcinoma. He came in with fever, dry cough and muscle pain for the past four days. Laboratory data: leukocytes 7100/ μ L, lymphocytes 600/ μ L (lymphocyte-to-leukocyte ratio 7.7%), platelets 140,000/ μ L, CRP 1.63 mg/dL, D-dimer 754 ng/mL and LDH 471 U/L. A posteroanterior chest X-ray taken on 16 March 2020 showed a peripheral ground-glass opacity in the right middle field (X-ray severity score = 1) (arrow). The patient was admitted, and a chest X-ray taken on 24 March 2020 showed clear radiological worsening with more extensive bilateral lung consolidations (arrows) associated with an increased need for oxygen therapy. C and D) A 33-year-old woman from Guatemala with no personal history of note visited the accident and emergency department with a referral from her primary care doctor due to cough and fever for the past nine days. Blood testing: leukocytes 5100/ μ L, lymphocytes 1400/ μ L (lymphocyte-to-leukocyte ratio 27.9%), platelets 224,000/ μ L, CRP 8.44 mg/dL, D-dimer 500 ng/mL and LDH 666 U/L. A posteroanterior chest X-ray taken on 17 March 2020 identified patchy bilateral lung consolidations predominantly in the lower lobes (score = 5) (arrows). The patient was admitted, and two days later, she showed worsening of signs and symptoms as well as laboratory values; a chest X-ray taken on 23 March showed radiological worsening, with confluence of her prior consolidations.

the score worsened.¹¹ This was consistent with studies that have reported changes over time in pulmonary findings: ground-glass opacities are the predominant pattern at the onset of symptoms, then there is progression towards a mixed pattern of ground-glass opacification and lung consolidation with peak expression from days six to 13. Finally, ground-glass opacities become predominant once again up to resolution. A percentage of patients do not follow a favourable course and show signs of pulmonary fibrosis of variable extent.^{23,28,29}

The main laboratory findings that have been linked to the severity of COVID-19 pneumonia and the clinical course of these patients are increased CRP (58.3%–60.7%), increased

D-dimer (46.6%), increased LDH (41%–57%) and lymphopenia (43%–83.2%). Increased leukocytes, platelets and CK have also been reported.^{12,18,24} In fact, Gatti et al. affirmed that LDH and CRP are the main predictors of findings on chest X-ray, with a sensitivity of 90% if both are high.¹⁷ In our study, patients with more severe disease had more pronounced abnormalities than those with less severe disease, with a significant association seen between laboratory values obtained and X-ray severity score. All laboratory values increased as the X-ray severity score increased, except for two, lymphocyte count and lymphocyte-to-leukocyte ratio, which decreased as involvement on X-ray increased.

Our study had some limitations. First, as it was a retrospective study focused on the first part of the pandemic, we lacked both established protocols for radiology reports in patients with COVID-19 and definitive knowledge of which values were most useful in blood testing; consequently, there were substantial amounts of missing data, ultimately limiting the final sample size. However, the time elapsed between the chest X-ray and the blood testing at diagnosis was always less than 24 h. Second, our study had the limitations inherent to the radiology technique used in execution and interpretation, in many cases magnified by the clinical condition of these patients.

In conclusion, chest X-ray is a valid technique in the initial assessment of patients with COVID-19, and its findings should be taken into account along with laboratory and clinical data when evaluating the clinical course of these patients, as a higher X-ray severity score is associated with a higher incidence of hospital admission and more abnormal laboratory values.

Authorship

- 1 Responsible for study integrity: AB, BC.
- 2 Study concept: AB, BC.
- 3 Study design: AB, ÁNM, SGP.
- 4 Data collection: ÁNM, SGP, AV.
- 5 Data analysis and interpretation: MEFF.
- 6 Statistical processing: MEFF.
- 7 Literature search: AB.
- 8 Drafting of the article: ÁNM, SGP.
- 9 Critical review of the manuscript with intellectually significant contributions: AB, BC.
- 10 Approval of the final version: AB, BC.

Conflicts of interest

The authors declare that they have no conflicts of interest.

References

1. Coronavirus disease (COVID-19) – World Health Organization [Internet]. [Accessed 19 Dec 2020]. Available from: <https://www.who.int/emergencies/diseases/novel-coronavirus-2019>.
2. WHO Western Pacific | World Health Organization [Internet]. [19 Dec 2020]. Available from: <https://www.who.int/westernpacific/emergencies/covid-19>.
3. Actualizacion.274.COVID-19.pdf [Internet]. [19 Dec 2020]. Available from: https://www.mscbs.gob.es/profesionales/saludPublica/ccayes/alertasActual/nCov/documentos/Actualizacion_274_COVID-19.pdf.
4. Huang C, Wang Y, Li X, Ren L, Zhao J, Hu Y, et al. Clinical features of patients infected with 2019 novel coronavirus in Wuhan, China. *Lancet*. 2020;395:497–506.
5. Petrilli CM, Jones SA, Yang J, Rajagopalan H, O'Donnell L, Chernyak Y, et al. Factors associated with hospital admission and critical illness among 5279 people with coronavirus disease 2019 in New York City: prospective cohort study. *BMJ*. 2020;369:m1966.
6. Ai T, Yang Z, Hou H, Zhan C, Chen C, Lv W, et al. Correlation of chest CT and RT-PCR testing in coronavirus disease

- 2019 (COVID-19) in China: a report of 1014 cases. *Radiology*. 2020;296:E32–40.
7. ACR Recommendations for the use of Chest Radiography and Computed Tomography (CT) for Suspected COVID-19 Infection [Internet]. [19 Dec 2020]. Available from: <https://www.acr.org/Advocacy-and-Economics/ACR-Position-Statements/Recommendations-for-Chest-Radiography-and-CT-for-Suspected-COVID19-Infection>.
8. Kim H, Hong H, Yoon SH. Diagnostic performance of CT and reverse transcriptase polymerase chain reaction for coronavirus disease 2019: a meta-analysis. *Radiology*. 2020;296:E145–55.
9. Xu B, Xing Y, Peng J, Zheng Z, Tang W, Sun Y, et al. Chest CT for detecting COVID-19: a systematic review and meta-analysis of diagnostic accuracy. *Eur Radiol*. 2020;30:5720–7.
10. Warren MA, Zhao Z, Koyama T, Bastarache JA, Shaver CM, Semler MW, et al. Severity scoring of lung oedema on the chest radiograph is associated with clinical outcomes in ARDS. *Thorax*. 2018;73:840–6.
11. Toussie D, Voutsinas N, Finkelstein M, Cedillo MA, Manna S, Maron SZ, et al. Clinical and chest radiography features determine patient outcomes in young and middle-aged adults with COVID-19. *Radiology*. 2020;297:E197–206.
12. Wu J, Wu X, Zeng W, Guo D, Fang Z, Chen L, et al. Chest CT findings in patients with coronavirus disease 2019 and its relationship with clinical features. *Invest Radiol*. 2020;55:257–61.
13. Borghesi A, Maroldi R. COVID-19 outbreak in Italy: experimental chest X-ray scoring system for quantifying and monitoring disease progression. *Radiol Med (Torino)*. 2020;125:509–13.
14. Cozzi D, Albanesi M, Cavigli E, Moroni C, Bindi A, Luvàrà S, et al. Chest X-ray in new Coronavirus Disease 2019 (COVID-19) infection: findings and correlation with clinical outcome. *Radiol Med (Torino)*. 2020;125:730–7.
15. Wong HYF, Lam HYS, Fong AH-T, Leung ST, Chin TW-Y, Lo CSY, et al. Frequency and distribution of chest radiographic findings in patients positive for COVID-19. *Radiology*. 2020;296:E72–8.
16. Kerpel A, Apter S, Nissan N, Hourli-Levi E, Klug M, Amit S, et al. Diagnostic and prognostic value of chest radiographs for COVID-19 at presentation. *West J Emerg Med [Internet]*. 2020;21(5) [accessed 19 Dec 2020]. Available from: <https://escholarship.org/uc/item/20s5v5k7>
17. Gatti M, Calandri M, Barba M, Biondo A, Geninatti C, Gentile S, et al. Baseline chest X-ray in coronavirus disease 19 (COVID-19) patients: association with clinical and laboratory data. *Radiol Med (Torino)*. 2020;125:1271–9.
18. Rodríguez-Morales AJ, Cardona-Ospina JA, Gutiérrez-Ocampo E, Villamizar-Peña R, Holguin-Rivera Y, Escalera-Antezana JP, et al. Clinical, laboratory and imaging features of COVID-19: a systematic review and meta-analysis. *Travel Med Infect Dis*. 2020;34:101623.
19. Hansell DM, Bankier AA, MacMahon H, McLoud TC, Müller NL, Remy J. Fleischner society: glossary of terms for thoracic imaging. *Radiology*. 2008;246:697–722.
20. Yoon SH, Lee KH, Kim JY, Lee YK, Ko H, Kim KH, et al. Chest radiographic and CT findings of the 2019 novel coronavirus disease (COVID-19): analysis of nine patients treated in Korea. *Korean J Radiol*. 2020;21:494.
21. Ng M-Y, Lee EYP, Yang J, Yang F, Li X, Wang H, et al. Imaging profile of the COVID-19 infection: radiologic findings and literature review. *Radiol Cardiothorac Imaging*. 2020;2:e200034.
22. Li K, Fang Y, Li W, Pan C, Qin P, Zhong Y, et al. CT image visual quantitative evaluation and clinical classification of coronavirus disease (COVID-19). *Eur Radiol*. 2020;30:4407–16.
23. Pan F, Ye T, Sun P, Gui S, Liang B, Li L, et al. Time course of lung changes at chest CT during recovery from coronavirus disease 2019 (COVID-19). *Radiology*. 2020;295:715–21.
24. Francone M, Iafrate F, Masci GM, Coco S, Cilia F, Manganaro L, et al. Chest CT score in COVID-19 patients: correlation

- with disease severity and short-term prognosis. *Eur Radiol.* 2020;30:6808–17.
25. Xiao N, Cooper JG, Godbe JM, Bechel MA, Scott MB, Nguyen E, et al. Chest radiograph at admission predicts early intubation among inpatient COVID-19 patients. *Eur Radiol* [Internet]. 2020 [19 Dec 2020]; Available from: <http://link.springer.com/10.1007/s00330-020-07354-y>
 26. Salehi S, Abedi A, Balakrishnan S, Gholamrezanezhad A. Coronavirus disease 2019 (COVID-19): a systematic review of imaging findings in 919 patients. *Am J Roentgenol.* 2020;215:87–93.
 27. Borghesi A, Zigliani A, Masciullo R, Golemi S, Maculotti P, Farina D, et al. Radiographic severity index in COVID-19 pneumonia: relationship to age and sex in 783 Italian patients. *Radiol Med (Torino).* 2020;125:461–4.
 28. Vancheri SG, Saviotto G, Ballati F, Maggi A, Canino C, Bortolotto C, et al. Radiographic findings in 240 patients with COVID-19 pneumonia: time-dependence after the onset of symptoms. *Eur Radiol.* 2020;30:6161–9.
 29. Ojha V, Mani A, Pandey NN, Sharma S, Kumar S. CT in coronavirus disease 2019 (COVID-19): a systematic review of chest CT findings in 4410 adult patients. *Eur Radiol.* 2020;30:6129–38.