

# Acrometastases to the Hand: A Systematic Review

Giuseppe Emmanuele Umana <sup>1,\*</sup>, Gianluca Scalia <sup>2,†</sup>, Paolo Palmisciano <sup>1</sup>, Maurizio Passanisi <sup>1</sup>, Valerio Da Ros <sup>3</sup>, Gianluca Pompili <sup>4</sup>, Fabio Barone <sup>1</sup>, Paolo Amico <sup>5</sup>, Santino Ottavio Tomasi <sup>6,7</sup>, Francesca Graziano <sup>2</sup>, Iolanda Valeria Patti <sup>8,9</sup>, Stefania Mele <sup>8,9</sup>, Rosario Maugeri <sup>10</sup>, Giovanni Raffa <sup>11</sup>, Giuseppe Roberto Giammalva <sup>10</sup>, Gerardo Domenico Iacopino <sup>10</sup>, Antonino Germanò <sup>11</sup>, Giovanni Federico Nicoletti <sup>2</sup>, Massimo Ippolito <sup>12</sup>, Maria Gabriella Sabini <sup>8,9</sup>, Salvatore Cicero <sup>1</sup>, Lidia Strigari <sup>13</sup> and Giacomo Cuttone <sup>9</sup>

- <sup>1</sup> Trauma Center, Gamma Knife Center, Department of Neurosurgery, Cannizzaro Hospital, 95126 Catania, Italy; paolo.palmisciano94@gmail.com (P.P.); mpassanisi@tiscali.it (M.P.); fbarone1969@gmail.com (F.B.); cicerosalvatore@yahoo.it (S.C.)
  - <sup>2</sup> Department of Neurosurgery, Highly Specialized Hospital and of National Importance “Garibaldi”, 95122 Catania, Italy; gianluca.scalia@outlook.it (G.S.); fragraziano9@gmail.com (F.G.); gfnicoletti@alice.it (G.F.N.)
  - <sup>3</sup> Department of Biomedicine and Prevention, University Hospital of Rome “Tor Vergata”, 00133 Rome, Italy; darosvalerio@gmail.com
  - <sup>4</sup> Plastic Surgery Unit, Cannizzaro Hospital, 95126 Catania, Italy; gianluca.pompili@yahoo.it
  - <sup>5</sup> Department of Pathological Anatomy, Cannizzaro Hospital, 95126 Catania, Italy; p.amico80@gmail.com
  - <sup>6</sup> Department of Neurological Surgery, Christian Doppler Klinik Paracelsus Medical University, 5020 Salzburg, Austria; s.tomasi@salk.at
  - <sup>7</sup> Laboratory for Microsurgical Neuroanatomy, Christian Doppler Klinik, 5020 Salzburg, Austria
  - <sup>8</sup> Medical Physics Unit, Cannizzaro Hospital, 95126 Catania, Italy; valeriapatti72@gmail.com (I.V.P.); mele.stefania@gmail.com (S.M.); mgabsabini@gmail.com (M.G.S.)
  - <sup>9</sup> INFN-Laboratori Nazionali del Sud, Via S. Sofia 62, 95123 Catania, Italy; cuttone@lns.infn.it
  - <sup>10</sup> Post-Graduate Residency Programme in Neurological Surgery, Department of Experimental Biomedicine and Clinical Neurosciences, School of Medicine, Neurosurgical Clinic, AOUP “Paolo Giaccone”, 90127 Palermo, Italy; rosario.maugeri1977@gmail.com (R.M.); robertogiammalva@gmail.com (G.R.G.); gerardo.iacopino@gmail.com (G.D.I.)
  - <sup>11</sup> BIOMORF Department, Division of Neurosurgery, University of Messina, 98124 Messina, Italy; giovanni.raffa@unime.it (G.R.); germano@unime.it (A.G.)
  - <sup>12</sup> Department of Advanced Technologies, Nuclear Medicine and PET Cannizzaro Hospital, 95126 Catania, Italy; ippolitomas@yahoo.it
  - <sup>13</sup> Department of Medical Physics, IRCCS University Hospital of Bologna, 40138 Bologna, Italy; lidia.strigari@aosp.bo.it
- \* Correspondence: umana.nch@gmail.com  
† These authors contributed equally to the work.



**Citation:** Umana, G.E.; Scalia, G.; Palmisciano, P.; Passanisi, M.; Da Ros, V.; Pompili, G.; Barone, F.; Amico, P.; Tomasi, S.O.; Graziano, F.; et al. Acrometastases to the Hand: A Systematic Review. *Medicina* **2021**, *57*, 950. <https://doi.org/10.3390/medicina57090950>

Academic Editor: François Cornelis

Received: 5 July 2021

Accepted: 6 September 2021

Published: 9 September 2021

**Publisher's Note:** MDPI stays neutral with regard to jurisdictional claims in published maps and institutional affiliations.



**Copyright:** © 2021 by the authors. Licensee MDPI, Basel, Switzerland. This article is an open access article distributed under the terms and conditions of the Creative Commons Attribution (CC BY) license (<https://creativecommons.org/licenses/by/4.0/>).

**Abstract:** *Background and Objectives:* The term acrometastases (AM) refers to secondary lesions sited distally to the elbow and knee, representing 0.1% of all bony metastases. By frequency, pulmonary cancer and gastrointestinal and genitourinary tract neoplasms are the most responsible for the reported AM. Improvements in oncologic patient care favor an increase in the incidence of such rare cases. We performed a systematic review of acrometastases to the hand to provide further insight into the management of these fragile patients. We also present a peculiar case of simultaneous acrometastasis to the ring finger and pathological vertebral fracture. *Material and Methods:* A literature search according to the PRISMA (Preferred Reporting Items for Systematic Reviews and Meta-Analyses) statement was conducted using the PubMed, Google Scholar, and Scopus databases in December 2020 on metastasis to the hand and wrist, from 1986 to 2020. MeSH terms included acrometastasis, carpal metastasis, hand metastasis, finger metastasis, phalangeal metastasis, and wrist metastasis. *Results:* In total, 215 studies reporting the follow-up of 247 patients were analyzed, with a median age of 62 years (range 10–91 years). Overall, 162 out of 247 patients were males (65.6%) and 85 were females (34.4%). The median reported follow-up was 5 months (range 0.5–39). The median time from primary tumor diagnosis to acrometastasis was 24 months (range 0.7–156). Acrometastases were located at the finger/phalanx (68.4%), carpal (14.2%), metacarpal (14.2%), or other sites (3.2%). The primary tumors were pulmonary in 91 patients (36.8%). The average interval

from primary tumor diagnosis to acrometastasis varied according to the primary tumor type from 2 months (in patients with mesenchymal tumors) to 64.0 months (in patients with breast cancer). *Conclusions:* Acrometastases usually develop in the late stage of oncologic disease and are associated with short life expectancy. Their occurrence can no longer be considered rare; physicians should thus be updated on their surgical management and their impact on prognosis and survival.

**Keywords:** acrometastases; thumb metastases; carcinoma; immunotherapy; chemotherapy; radiotherapy

## 1. Introduction

The term acrometastases (AM) refers to secondary lesions sited distally to the elbow and knee [1], which represent 0.1% of all bone metastases [2]. Usually, AM develop during follow-up of oncologic patients, but in 10% of cases, their occurrence is the first sign of a previously undiagnosed tumor [3]. This rare finding is usually detected in multi-organ neoplastic patients, thus indicating a short life expectancy (6 months) after their diagnosis. By frequency, pulmonary cancer and gastrointestinal and genitourinary tract neoplasms are the most responsible for the reported AM [4]. Improvements in oncologic patient care favor an increase in such rare cases [5]. Macroscopically, acrometastases show as painful, swollen, and reddened lesions that affect soft tissue and cause a reduced range of motion. Due to their characteristics, these lesions need to be distinguished from primary integumentary neoplasm, pyogenic granuloma, osteomyelitis, tuberculosis, inflammatory processes, cysts, gout, and ganglia [2,6–31]. A systematic review was performed on acrometastases to the hand and wrist to provide further insights into the management of these fragile patients, who have an increased risk of developing acrometastases due to improvements in treatment, and the subsequent extension of life expectancy.

## 2. Materials and Methods

### 2.1. Study Selection

A literature search on metastases to the hand and wrist was performed in accordance with the PRISMA (Preferred Reporting Items for Systematic Reviews and Meta-Analyses) guidelines in December 2020 using the PubMed, Google Scholar, and Scopus databases, from 1986 to 2020, and registered to PROSPERO (ID 277733) [32]. Relevant MeSH terms included acrometastasis, carpal metastasis, hand metastasis, finger metastasis, phalangeal metastasis, and wrist metastasis. This search was restricted to case reports, case series, letters to the Editor, and abstracts. The reference lists of all articles and cross-references were checked and, if relevant, were included in this systematic review. Additionally, non-English-language papers were considered relevant and included in this study after translating the relevant data. The PRISMA flow diagram for our search is outlined in Figure 1.

### 2.2. Data Extraction

A total of 254 articles were identified, but 39 were excluded because they had redundancies in their publications, concerned foot acrometastases, or presented ambiguous, repeated, or incomplete data. This operation yielded 215 articles with a total of 247 patients, who were enrolled in our systematic review. The articles were written in English, French, German, Hungarian, Italian, Spanish, Portuguese, Russian, Turkish, and Japanese. All included studies were meticulously reviewed and scrutinized for their study design, methodology, patient characteristics, and the following data points: authors; year of publication; and patients' age, sex, metastatic locations, primary tumor origin, interval time from primary tumor diagnosis to acrometastasis treatment options, and survival (months) when available. The extracted data are presented in Supplementary Table S1 [3,4,6–31,33–217].

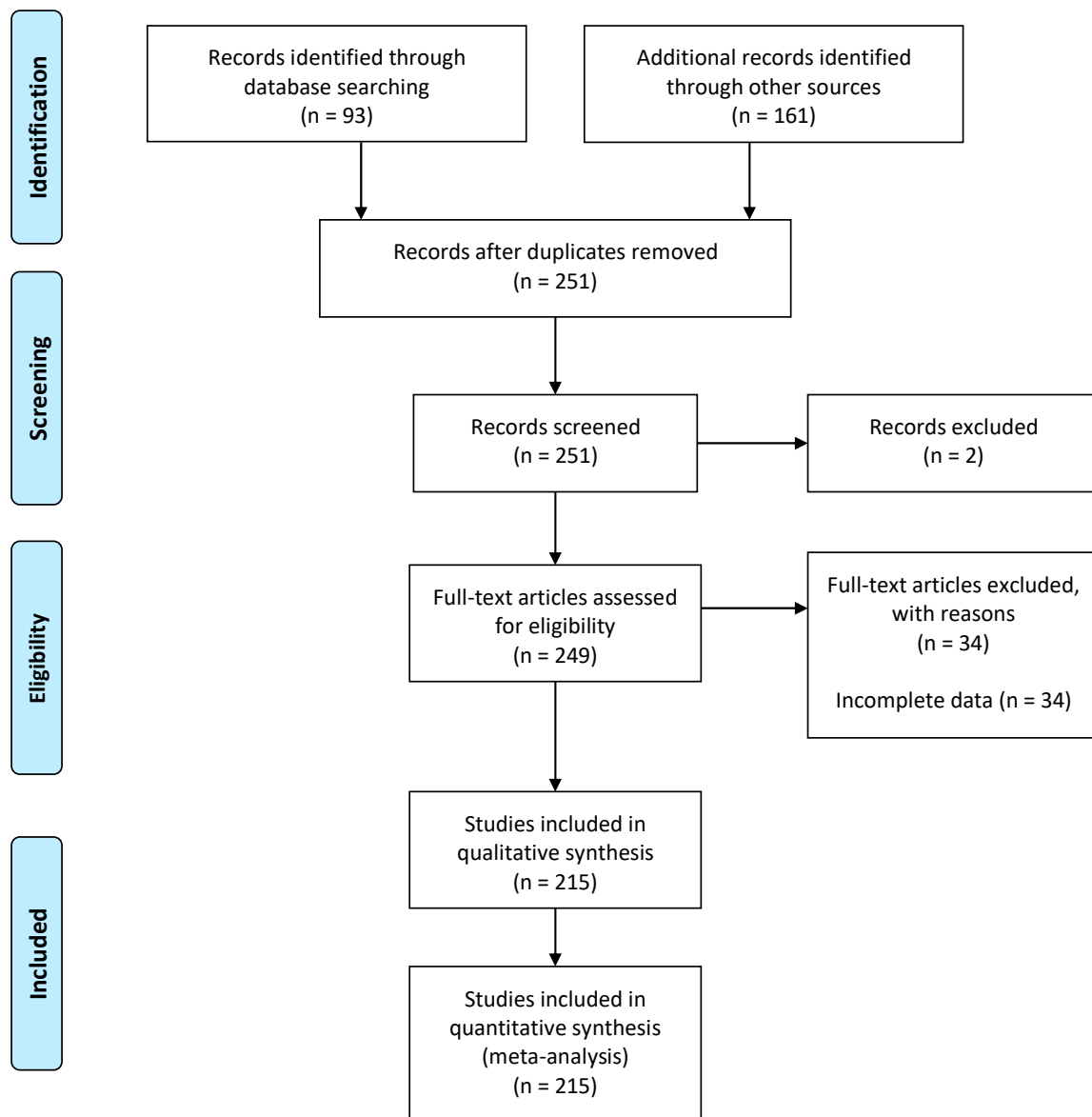


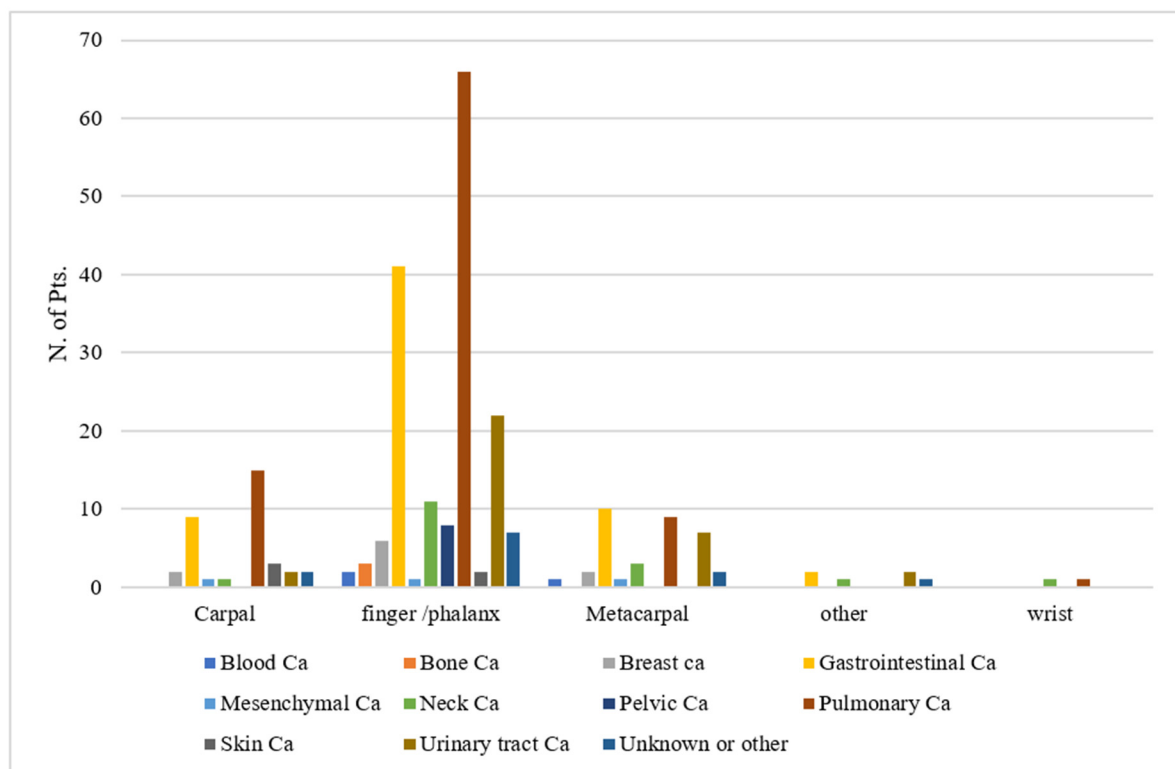
Figure 1. PRISMA flow diagram regarding acrometastases to the hand.

### 3. Results

In total, 215 studies reporting the follow-up of 247 patients were analyzed. The median age was 62 years (range 10–91 years). Overall, 162 out of 247 (65.6%) patients were males and 85 (34.4%) were females. The median (range) reported follow-up was 5 (0.5–39) months. The median time from primary tumor diagnosis to acrometastasis was 24 months (range 0.7–156). Acrometastases were located at the finger/phalanx (68.4%), carpal (14.2%), metacarpal (14.2%), or other sites (3.2%). The primary tumors were pulmonary in 91 (36.8%), gastrointestinal in 62 (25.1%), urinary tract tumors in 33 (13.4%), neck tumors in 17 (6.9%), breast tumors in 10 (4.0%), pelvic tumors in 8 (3.2%), skin tumors in 5 (2.0%), bone tumors in 3 (1.2%), blood tumors in 3 (1.2%), mesenchymal tumors in 3 (1.2%), of unknown origin in 3 (1.2%), and other types in 9 (3.6%) patients. The average interval from primary tumor diagnosis to acrometastasis varied according to the primary tumor type from 2 months (in patients with mesenchymal tumor) to 64.0 months (in patients with breast cancer) (Table 1). The distribution of acrometastases’ localization versus the type of primary site is shown in Figure 2.

**Table 1.** The average interval from primary tumor diagnosis to acrometastasis (in months) according to the primary tumor type.

Primary Tumor Type	No. of Patients	Average Interval from Primary Tumor Diagnosis to Acrometastasis (Months)
Blood Ca	3	48
Bone Ca	3	44
Breast Ca	10	64
Gastrointestinal Ca	62	26.1
Mesenchymal Ca	3	2
Neck Ca	17	32.2
Pelvic Ca	8	6
Pulmonary Ca	91	13.4
Skin Ca	5	58
Urinary tract Ca	33	40.5
Other or unknown	12	27.3
Total	247	29.8



**Figure 2.** The distribution of acrometastases' localization against the primary tumor site.

#### 4. Discussion

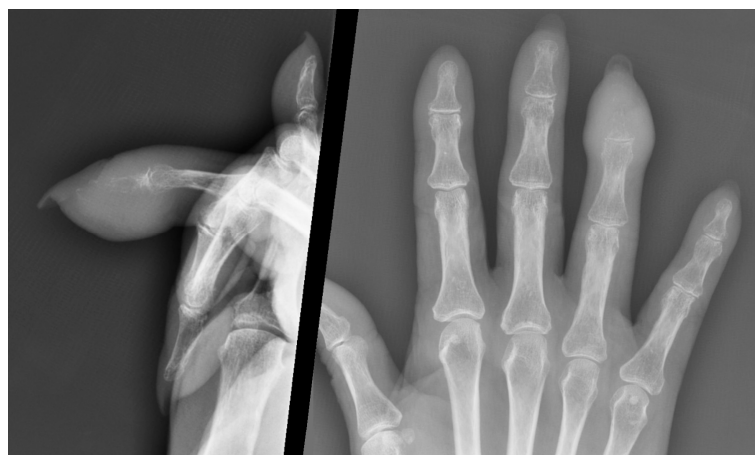##### 4.1. Pathophysiology

Bone metastases show tropism towards red marrow, found mainly in vertebral bodies. Since hands contain little red marrow, they are rarely a site of bone metastasis [146,218,219]. Moreover, bone metastases usually affect bones with low blood flow within the capillaries, and this also explains why acrometastases are so rare as such a blood perfusion setting is scarce in distal bones [147,220–223]. AM's development and pathophysiology are not yet fully understood. The most plausible hypothesis is that malignant cells metastasize to distal bones through blood, not lymphatic circulation [1,148]. The most frequent primitive tumor-related cause of AM is lung cancer, likely because of the connection with the heart and blood circulation, bypassing the pulmonary and liver filter. AM can be a secondary localization of

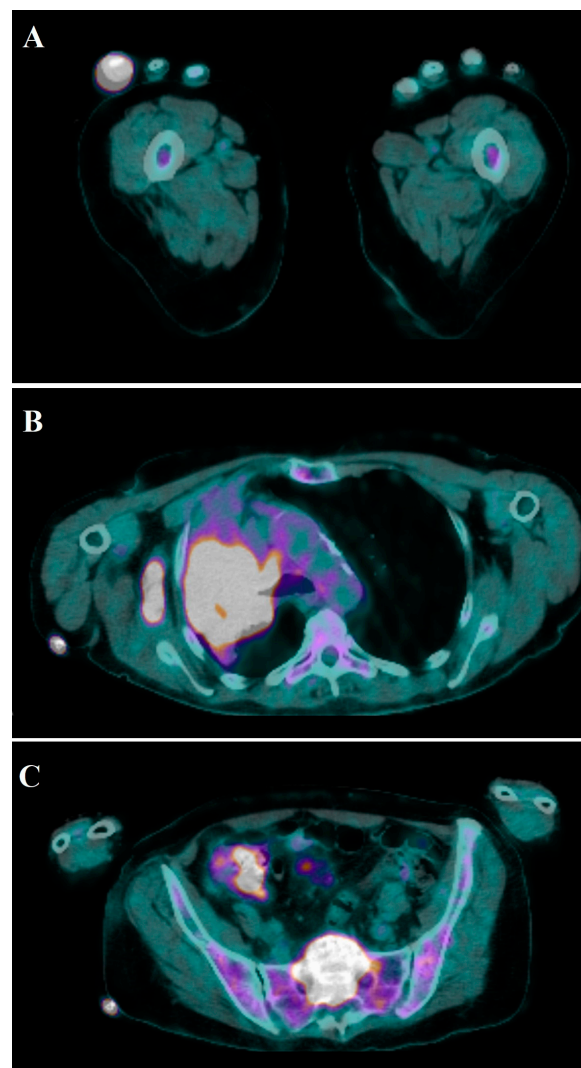
several other primitive cancers, from esophageal squamous cell carcinoma [150] to gastric adenocarcinoma [169] following orthopedic surgery for a pathologic fracture [155]. In this systematic review of the literature, 215 studies reported the outcome of 247 patients with multi-organ concurrent metastases, mainly from lung cancer in 91 (36.8%), gastrointestinal cancer in 62 (25.1%), urinary tract cancer in 33 (13.4%), neck cancer in 17 (6.9%), breast cancer in 10 (4.0%), pelvic cancer in 8 (3.2%), skin cancer in 5 (2.0%), bone cancer in 3 (1.2%), blood cancer in 3 (1.2%), mesenchymal cancer in 3 (1.2%), an unknown origin in 3 (1.2%), and other types in 9 (3.6%) patients. The finger/phalanx (68.4%), carpal (14.2%), and metacarpal (14.2%) sites are the prevalent sites of AM because chemotactic factors released after continued traumatism stimulate the release of prostaglandins, which favor tumor cell adhesion [152,218]. Furthermore, the distal phalanges have higher blood perfusion than the proximal phalanges [153]. The importance of blood supply and chemotaxis has been further postulated after a report of AM from colon adenocarcinoma following a dog bite wound [154]. Direct seeding has been suggested after a patient, affected by lung cancer metastasis and who used to digitally occlude his tracheostomy to speak better, developed thumb metastasis [155]. Voskuil et al. [142] reported a patient with history of colon adenocarcinoma one year before who complained of worsening wrist pain after trauma (car wheel change). He underwent a carpectomy and survived one year after AM diagnosis. Other authors have reported direct or indirect traumatism before the development of AM, confirming the pathophysiological hypothesis suggesting that trauma plays an important role [128–130].

#### 4.2. Imaging

Osteolytic areas are detected by standard hand X-ray (Figure 3); AM from breast cancer can appear as sclerotic lesions [4,224], while metastases from prostatic cancer have osteoblastic features [3,148]. To better identify suspicious radiological findings at full-body examination, isotope bone scans have proven useful [3,56,148,225]. Positron emission tomography (PET) represents an advanced and comprehensive diagnostic tool that allows a precise differential diagnosis of benign and malignant tumors, detecting primary and secondary tumors before other diagnostic tools with 90% sensitivity and 78% specificity [157,226] (Figure 4). A case of an asymptomatic metastatic lesion to the fourth metacarpal from vaginal squamous cell carcinoma, discovered during a PET examination at follow-up, has been reported in the literature [158]. CT scans offer low resolution at the level of small structures. Magnetic resonance imaging (MRI) is an accurate diagnostic methodology to characterize metastatic bone and related soft tissue involvement [6].



**Figure 3.** Hand X-ray showing thickening of the soft tissue of the right ring finger's distal phalanx, with fracture of the distal phalanx and moderate loss of bone substance.



**Figure 4.** Total-body  $^{18}\text{F}$ -FDG PET-CT scans showing accumulation of tracer in the fourth finger of the right hand (SUV max 18.3) (A) and middle and upper lobes of the right lung (SUV max 15.8) associated with  $^{18}\text{F}$ -FDG uptake in the lymph nodes of the right axilla, prevascular, right paratracheal, at the Baret space, at precarenal, subcarinal, and hilum of the right lung (SUV max 16.6) (B). Additionally, tracer uptake at T7, T8, T10, L3, sacrum, right acetabulum, and ipsilateral ischiopubic branch is shown (C).

#### 4.3. Patient Population

From the systematic analysis of the literature, the age at presentation of AM was found to progressively increase, with a median age of 62 years (range 10–91 years), probably due to improvements in therapeutic management, even if the overall survival remains unaltered [160,220,227]. The incidence of AM is greater in men because primary lung cancer, which is the main cause of these metastases, is more frequent in the male population [3,146,227]. No association has been documented between right and left hands or dominant and non-dominant hands, although a greater incidence has been reported in the dominant hand due to more frequent traumatism [3,146,227]. Lechmiannandan et al. [139] reported a patient affected by proximal humerus metastasis from clear cell renal carcinoma who developed AM to his right thumb one month after orthopedic surgery. The AM were treated surgically one month later, with progressive worsening; the patient was referred for palliative treatment. This experience suggests a higher risk of AM following orthopedic surgery for pathological fractures.

#### 4.4. Therapeutic Management

AM develop in the late stage of oncologic disease, often characterized by multi-organ spread of secondary tumors. Thus, the management of those patients depends on the comprehensive evaluation of the clinical condition, and the therapeutic strategy is defined on a patient-specific basis, without established guidelines [51,228–230]. The main goals of the treatment are pain control and function sparing of the hand of interest in the setting of a demolitive surgery represented by phalanx or finger amputation [3,146,227]. Life expectancy is influenced by the primary tumor [218], but the development of AM represents progression of the disease to distal districts and is thus associated to the very last period of survival of the patient. AM developed after a mean of 2 months in patients affected by mesenchymal tumors but after a mean of 64 months in those affected by breast cancer. These data suggest that patients suffering from highly malignant tumors may develop earlier AM compared to those dealing with less malignant neoplasms. In 30% of the studies reported in the literature, AM can be the first presentation of diffuse tumor. When present, the association of the acral swelling together with the pathological sacral fracture may make the diagnosis easier, allowing to provide prompt treatment and comprehensive oncologic management. Distal acral tumefaction associated to ulceration, pain, and progressive worsening should prompt evaluation for possible metastasis, especially in oncologic patients but also in apparently healthy patients. AM have traditionally been considered a rare finding, but reports of them in recent years have increased, probably thanks to improvements in the therapeutic protocols of oncologic patients, and it is reasonable that they will further increase in the future. Hayden et al. [218] suggested that the real incidence of AM could be much higher considering the risk of unreported cases due to misdiagnosis.

#### 5. Conclusions

Acrometastases usually develop in the late stage of oncologic disease and are associated with poor life expectancy. Their occurrence can no longer be considered rare. According to this review on acrometastases, which is the first systematic report to date, AM should be considered a finding that may be faced in daily practice. Physicians should be updated on AM, their surgical management, and their impact on prognosis and survival.

**Supplementary Materials:** The following are available online at <https://www.mdpi.com/article/10.3390/medicina57090950/s1>: Table S1: Patient's demographics.

**Author Contributions:** Conceptualization, G.E.U., G.S., S.C., L.S., G.C. and M.P.; methodology, G.E.U. and G.S.; software, L.S.; validation, G.E.U., F.G., R.M., G.R., A.G., G.F.N., G.D.I., M.P., G.P., P.A. and F.B.; formal analysis, L.S.; investigation, G.S., P.P., and V.D.R.; resources, G.S., R.M., G.R.G. and F.G.; data curation, G.S., M.P., F.B., S.O.T., I.V.P., S.M., M.I. and M.G.S.; writing—original draft preparation, G.E.U., G.S., and L.S.; writing—review and editing, S.C., A.G., G.D.I., G.P., P.A. and G.F.N.; visualization, G.C., I.V.P., S.M. and M.G.S.; supervision, G.C., G.S. and G.E.U. All authors have read and agreed to the published version of the manuscript.

**Funding:** This research received no external funding.

**Institutional Review Board Statement:** Not applicable.

**Informed Consent Statement:** Written informed consent was obtained from the patients to publish this paper.

**Data Availability Statement:** Data sharing not applicable. No new data were created or analyzed in this study. Data sharing is not applicable to this article.

**Conflicts of Interest:** The authors declare no conflict of interest.

#### References

1. Mavrogenis, A.F.; Mimidis, G.; Kokkalis, Z.T.; Karampi, E.-S.; Karampela, I.; Papagelopoulos, P.J.; Armaganidis, A. Acrometastases. *Eur. J. Orthop. Surg. Traumatol.* **2014**, *24*, 279–283. [[CrossRef](#)]
2. Kerin, R. Metastatic tumors of the hand. A review of the literature. *J. Bone Jt. Surg. Am.* **1983**, *65*, 1331–1335. [[CrossRef](#)] [[PubMed](#)]

3. Spiteri, V.; Bibra, A.; Ashwood, N.; Cobb, J. Managing acrometastases treatment strategy with a case illustration. *Ann. R. Coll. Surg. Engl.* **2008**, *90*, 8–11. [[CrossRef](#)] [[PubMed](#)]
4. Abrahams, T. Occult malignancy presenting as metastatic disease to the hand and wrist. *Skeletal Radiol.* **1995**, *24*, 135–137. [[CrossRef](#)]
5. Stomeo, D.; Tulli, A.; Ziranu, A.; Perisano, C.; De Santis, V.; Maccauro, G. Acrometastasis: A literature review. *Eur. Rev. Med. Pharmacol. Sci.* **2015**, *19*, 2906–2915.
6. Henderson, J.J. Metastatic carcinoma in the hand presenting as an acute paronychia. *Br. J. Clin. Pract.* **1987**, *41*, 805–806. [[PubMed](#)]
7. Yasaka, N.; Ando, I.; Kukita, A. An acral “inflammatory” cutaneous metastasis of oesophageal carcinoma. *Br. J. Dermatol.* **1999**, *141*, 938–939. [[CrossRef](#)] [[PubMed](#)]
8. Henderson, M.; Jehangir, S. A swollen finger and abdominal pain. *Lancet* **2001**, *358*, 636. [[CrossRef](#)]
9. Parungao, A.J.; Milner, S. Photo quiz A swollen, draining thumb. *Am. Fam. Physician* **2002**, *65*, 105–106.
10. Theunissen, C.C.W.; Engelkens, H.J.H.; Mulder, L.J.M.M.; Dees, A. Diagnostic image (107). A man with weight loss and skin nodes. *Ned. Tijdschr. Geneesk.* **2002**, *146*, 1832.
11. Blanes, M.; Bañuls, J.; Guijarro, J.; Betloch, I.; Payá, A. Metástasis acral digital ósea por adenocarcinoma renal con afectación cutánea. *Actas Dermosifiliogr.* **2003**, *94*, 555–558. [[CrossRef](#)]
12. Chou, Y.C.; Lin, J.Y.; Chen, H.H.; Ho, H.C. A patient of esophageal carcinoma presenting with fever and multiple nodules on fingers. *Dermatol. Sin.* **2004**, *22*, 199–200.
13. Gawley, B.; Motykie, G.; Piazza, R.C.; Holding, J.; Gould, L.J. Rapid progression of metastatic bronchogenic carcinoma after felon drainage. *Orthopedics* **2006**, *29*, 1035–1036. [[CrossRef](#)]
14. Park, K.-H.; Rho, Y.-H.; Choi, S.-J.; Hong, S.-J.; Lee, J.-H.; Choi, I.-K.; Kim, S.-J.; Seo, J.-H.; Choi, C.-W.; Kim, B.-S.; et al. Acute arthritis of carpal bones secondary to metastatic gastric cancer. *Clin. Rheumatol.* **2006**, *25*, 258–261. [[CrossRef](#)] [[PubMed](#)]
15. Kanatani, T.; Fujioka, H.; Yamasaki, K. Re: Metastatic oesophageal carcinoma presenting in a finger. *J. Hand Surg.* **2008**, *33*, 537–538. [[CrossRef](#)] [[PubMed](#)]
16. Anandan, S.M.; Iyer, S.; Uppal, R. Metastases to the finger masquerading as flexor tenosynovitis. *J. Hand Surg.* **2010**, *35*, 597–598. [[CrossRef](#)]
17. Sim, E. Misinterpretation of a metastatic process within the scope of Sudeck’s dystrophy. A case report. *Aktuelle Traumatol.* **1989**, *19*, 85–89. [[PubMed](#)]
18. Bowles, F.; Wells, H. Paronychia: Not always what it seems. *Emerg. Med. J.* **2011**, *28*, 342. [[CrossRef](#)]
19. Kontogeorgakos, V.; Korompilias, A.; Georgousis, M.; Papachristou, D. Digital Metastasis Presenting as Infection. *J. Hand Microsurg.* **2016**, *3*, 25–27. [[CrossRef](#)]
20. Roohi, S.A.; Samsudin, O.C.; Shukur, M.H.; Ibrahim, S. Metastatic adenocarcinoma to the wrist presenting as carpal tunnel syndrome: A report of an unusual case. *Malaysian Orthop. J.* **2011**, *5*, 75–77. [[CrossRef](#)]
21. Verardino, G.C.; da Silva, R.S.; Obadia, D.L.; Gripp, A.C.; Alves, M.D.F.G.S. Rare cutaneous metastasis from a probable basaloid carcinoma of the colon mimicking pyogenic granuloma. *An. Bras. Dermatol.* **2011**, *86*, 537–540. [[CrossRef](#)]
22. Borgohain, B.; Borgohain, N.; Khonglah, T.; Bareh, J. Occult renal cell carcinoma with acrometastasis and ipsilateral juxta-articular knee lesions mimicking acute inflammation. *Adv. Biomed. Res.* **2012**, *1*, 48. [[CrossRef](#)] [[PubMed](#)]
23. Ragois, P.; Didaiell, P.; Rizzi, P. Métastase cutanée d’un cancer pulmonaire simulant une maladie de Dupuytren. *Chir. Main* **2012**, *31*, 259–261. [[CrossRef](#)] [[PubMed](#)]
24. Ho, P.S.S.; Yip, L.Y.; Nguyen, M.; Wijesinghe, W.; Sahu, A. A Painful Finger: An Unusual Presentation of Von Hippel-Lindau-Associated Advanced Renal Cell Carcinoma. *Case Rep. Oncol.* **2020**, *13*, 245–248. [[CrossRef](#)] [[PubMed](#)]
25. Farouk, A.R.; McBride, D.J.; Bingham, J. A case of tumour simulating pulp space infection. *Br. J. Clin. Pract.* **1990**, *44*, 737–738.
26. Kolomiets, S.A.; Lytkin, A.S. Metastasis of small-cell lung cancer to the bone of the finger simulating osseous paronychia. *Vestn. Khir. Im. I. I. Grek.* **1991**, *147*, 55–56.
27. Lambert, D.; Escallier, F.; Collet, E.; Dallac, S.; Maingon, P.; Mayer, F.; Bastien, H. Distal phalangeal metastasis of a chondrosarcoma presenting initially as bilateral onycholysis. *Clin. Exp. Dermatol.* **1992**, *17*, 463–465. [[CrossRef](#)] [[PubMed](#)]
28. Moens, P.; De Smet, L.; Fabry, G.; Van Damme, B. Acrometastasis of the hand presenting as a whitlow. General review apropos of a case. *Rev. Chir. Orthop. Reparatrice Appar. Mot.* **1993**, *79*, 66–69.
29. Javed, S.; Fenyar, B.; Cilursu, A.M. Finger Metastasis Mimicking Osteomyelitis Case Report and Review of Literature. *JCR J. Clin. Rheumatol.* **1997**, *3*, 168–170. [[CrossRef](#)]
30. Chin, K.R.; Pess, G.M.; Jupiter, J.B. Chronic lymphocytic leukemia presenting as pyogenic arthritis of the proximal interphalangeal joint. *J. Hand Surg. Am.* **1998**, *23*, 545–550. [[CrossRef](#)]
31. Umebayashi, Y. Metastasis of Esophageal Carcinoma Manifesting as Whitlow-like Lesions. *J. Dermatol.* **1998**, *25*, 256–259. [[CrossRef](#)]
32. Page, M.J.; McKenzie, J.E.; Bossuyt, P.M.; Boutron, I.; Hoffmann, T.C.; Mulrow, C.D.; Shamseer, L.; Tetzlaff, J.M.; Akl, E.A.; Brennan, S.E.; et al. The PRISMA 2020 statement: An updated guideline for reporting systematic reviews. *BMJ* **2021**, 372. [[CrossRef](#)]
33. Filloux, J.F.; Fontaine, C. Tumeurs métastatiques des parties molles des doigts. À propos de six cas. *Chir. Main* **2000**, *19*, 63–66. [[CrossRef](#)]



34. Houston, J.D.; Telepak, R.J. An Isolated Digital Metastasis of Esophageal Basaloid Squamous Cell Carcinoma. *Clin. Nucl. Med.* **2000**, *25*, 557–558. [[CrossRef](#)]
35. Ryu, J.S.; Cho, J.W.; Moon, T.H.; Lee, H.L.; Han, H.S.; Choi, G.S. Squamous cell lung cancer with solitary subungual metastasis. *Yonsei Med. J.* **2000**, *41*, 666. [[CrossRef](#)]
36. Tochigi, H.; Nakao, Y.; Horiuchi, Y.; Toyama, Y. Metastatic malignant melanoma in the hand muscle—A case report. *Hand Surg.* **2000**, *5*, 69–72. [[CrossRef](#)] [[PubMed](#)]
37. Asthana, S.; Deo, S.V.; Shukla, N.K.; Raina, V. Carcinoma breast metastatic to the hand and the foot. *Australas. Radiol.* **2001**, *45*, 380–382. [[CrossRef](#)] [[PubMed](#)]
38. Caglar, M.; Ceylan, E. Isolated Carpal Bone Metastases from Bronchogenic Cancer Evident on Bone Scintigraphy. *Clin. Nucl. Med.* **2001**, *26*, 352–353. [[CrossRef](#)]
39. Chang, H.C.; Lew, K.H.; Low, C.O. Metastasis of an adenocarcinoma of the stomach to the 4th metacarpal bone. *Hand Surg.* **2001**, *6*, 239–242. [[CrossRef](#)]
40. Fang, Y.R.; Huang, Y.S.; Wu, J.C.; Chao, Y.; Tsay, S.H.; Chan, C.Y.; Chang, F.Y.; Lee, S.D. An unusual cutaneous metastasis from hepatocellular carcinoma. *Zhonghua Yi Xue Za Zhi* **2001**, *64*, 253–257.
41. Mehta, N.J.; Mehta, R.N.; Jani, K.; Nehra, A. Subungual and ocular metastases from small cell carcinoma of the lung. *Hosp. Physician* **2001**, *37*, 38–40.
42. Silfen, R.; Amir, A.; Tobar, A.; Hauben, D.J. The Digital Pulp as a Presenting Site of Metastatic Esophageal Carcinoma. *Ann. Plast. Surg.* **2001**, *46*, 183–184. [[CrossRef](#)] [[PubMed](#)]
43. Carvalho, H.d.A.; Tsai, P.W.C.; Takagaki, T.Y. Thumb metastasis from small cell lung cancer treated with radiation. *Rev. Hosp. Clin. Fac. Med. Sao. Paulo.* **2002**, *57*, 283–286. [[CrossRef](#)] [[PubMed](#)]
44. Raissouni, Z.; Ismael, F.; Elmrini, A.; Boutayeb, F. Acrometastasis of the hand. Case report. *Acta Orthop. Belg.* **2002**, *68*, 297–300. [[PubMed](#)]
45. Vadivelu, R.; Drew, S. Phalangeal metastasis secondary to an occult breast carcinoma. *Arch. Orthop. Trauma Surg.* **2002**, *122*, 530–531. [[CrossRef](#)]
46. Aguiar Bujanda, D.; Bohn Sarmiento, U.; Aguiar Morales, J. Some Unusual Paraneoplastic Syndromes. *J. Clin. Oncol.* **2003**, *21*, 2620. [[CrossRef](#)]
47. Dimri, K.; Rastogi, N.; Lal, P. Carcinoma of esophagus with unusual metastasis to gingiva and phalanx. *Indian J. Cancer* **2003**, *40*, 37–38.
48. Fusetti, C.; Kurzen, P.; Bonaccio, M.; Büchler, U.; Nagy, L. Hand metastasis in renal cell carcinoma. *Urology* **2003**, *62*, 141. [[CrossRef](#)]
49. Oron, A.; Reshef, N.; Siegelmann-Danieli, N.; Lin, E.; Aghasi, M. Colon cancer metastasizing to the proximal phalanx of an index finger—A case report. *J. Hand Surg.* **2003**, *28*, 26–27. [[CrossRef](#)]
50. Campa, T.; Fagnoni, E.; Ripamonti, C. Palliative surgery of acrometastases from lung cancer: A case report. *Support. Care Cancer* **2004**, *12*, 202–204. [[CrossRef](#)] [[PubMed](#)]
51. De Smet, L. Late Appearance and Slow Progression of a Breast Carcinoma Metastasis of the Index Metacarpal. *Acta Chir. Belg.* **2004**, *104*, 345–346. [[CrossRef](#)]
52. Fontana, T.; Siciliano, M.; Franceschelli, A.; Annicchiarico, B.E.; Rossi, P.; Bigotti, G.; Bombardieri, G. An atypical bone metastasis of hepatocellular carcinoma: Case report and review of the literature. *Clin. Ter.* **2004**, *155*, 447–451.
53. Riter, H.G.; Ghobrial, I.M. Renal Cell Carcinoma with Acrometastasis and Scalp Metastasis. *Mayo Clin. Proc.* **2004**, *79*, 76. [[CrossRef](#)]
54. Sahbaz, S.; Kilinç, O.; Vayvada, H.; Topçu, A.; Yörükoğlu, K.; Uçan, E.S. Distal phalanx metastasis in operated bronchial carcinoma. *Tuberk. Toraks* **2004**, *52*, 378–381. [[PubMed](#)]
55. Keramidias, E.; Brotherton, M. Extensive metastasis to the hand from undiagnosed adenocarcinoma of the lung. *Scand. J. Plast. Reconstr. Surg. Hand Surg.* **2005**, *39*, 113–115. [[CrossRef](#)]
56. Mousavi, S.R.; Ghasemi, A.; Tajodini, A. Metastasis of esophageal cancer to finger. *Arch. Iran. Med.* **2005**, *8*, 319–320.
57. Nakamura, H.; Shimizu, T.; Kodama, K.; Shimizu, H. Metastasis of lung cancer to the finger: A report of two cases. *Int. J. Dermatol.* **2005**, *44*, 47–49. [[CrossRef](#)] [[PubMed](#)]
58. Tomas, X.; Conill, C.; Combalia, A.; Pomes, J.; Castel, T.; Nicolau, C. Malignant melanoma with metastasis into the capitate. *Eur. J. Radiol.* **2005**, *56*, 362–364. [[CrossRef](#)]
59. Akjouj, S.; El Kettani, N.; Semlali, S.; Chaguar, B.; Chaouir, S.; Hanine, A.; Benameur, M. Acrométastase du pouce révélant un adénocarcinome pulmonaire: À propos d'un cas avec revue de la littérature. *Chir. Main* **2006**, *25*, 106–108. [[CrossRef](#)] [[PubMed](#)]
60. Bülbül, Y.; Özsu, S.; Özlü, T.; Öztuna, F. Acrometastasis in a case with bronchial carcinoma. *Toraks. Dergisi.* **2006**, *7*, 200–203.
61. Carty, H.-M.; Simons, A.W.; Isgar, B. Breast carcinoma bone metastasis first presenting to single middle phalanx. *Breast* **2006**, *15*, 127–129. [[CrossRef](#)]
62. Gallagher, B.; Yousef, G.; Bishop, L. Subungual Metastasis from a Rectal Primary: Case Report and Review of the Literature. *Dermatologic Surg.* **2006**, *32*, 592–595. [[CrossRef](#)]
63. Gamblin, T.C.; Santos, R.S.; Baratz, M.; Landreneau, R.J. Metastatic colon cancer to the hand. *Am. Surg.* **2006**, *72*, 98–100. [[CrossRef](#)] [[PubMed](#)]

64. Heidarpour, M.; Rajabi, P.; Eftekhari, A.; Ghasemibasir, H.R. Lung carcinoma metastasis to the distal part of the index finger: A case report. *Iran J. Pathol.* **2006**, *1*, 173–176.
65. Reparaz Padros, J.; Arenas Planelles, A.J.; Martinez Mariscal, J.; Garbayo Marturet, A.J. Acrometástasis. A propósito de dos Casos. *Rev. Esp. Cir. Osteoartic.* **2006**, *41*, 39–43.
66. Afshar, A.; Ayatollahy, H.; Lotfinejad, S. A Rare Metastasis in the Hand: A Case of Cutaneous Metastasis of Choriocarcinoma to the Small Finger. *J. Hand Surg. Am.* **2007**, *32*, 393–396. [[CrossRef](#)] [[PubMed](#)]
67. Bigot, P.; Desbois, E.; Benoist, N.; Besnier, L.; Moui, Y. Acrométastase révélée par une douleur isolée de la main. À propos d'un cas. *Chir. Main* **2007**, *26*, 300–302. [[CrossRef](#)]
68. Elhassan, B.; Fakhouri, A. Metastasis of squamous-cell carcinoma of the lung to the first web space of the hand. *J. Bone Joint Surg. Br.* **2007**, *89-B*, 1243–1246. [[CrossRef](#)]
69. French, F.P.; Murray, P.M.; Perdakis, G. Extensive Cutaneous Metastatic Breast Carcinoma of the Hand and Upper Extremity: A Case Report. *J. Hand Surg. Am.* **2007**, *32*, 252–255. [[CrossRef](#)] [[PubMed](#)]
70. Kanbay, A.; Oguzulgen, K.I.; Ozturk, C.; Memis, L.; Demircan, S.; Kurkcuoglu, C.; Akyurek, N.; Kurul, C. Malignant Pleural Mesothelioma with Scalp, Cerebellar, and Finger Metastases: A Rare Case. *South. Med. J.* **2007**, *100*, 63–65. [[CrossRef](#)]
71. Nikolic, I.; Patrnogic, A.; Stojiljkovic, B.; Bogdanovic, B.; Kukic, B. Thumb metastases in a patient with colorectal cancer. *Arch. Oncol.* **2007**, *15*, 97–98. [[CrossRef](#)]
72. Preto, A.S.; Teixeira, R.; Cruz, R. Atypical presentation of lung cancer. *Acta Reumatol. Port.* **2007**, *32*, 282–286.
73. Ramseier, L.E.; Dumont, C.E.; Ulrich Exner, G. Multiple subungual soft tissue metastases from a chondrosarcoma. *Scand. J. Plast. Reconstr. Surg. Hand Surg.* **2007**, *41*, 332–333. [[CrossRef](#)] [[PubMed](#)]
74. Salesi, N.; Russillo, M.; Marandino, F.; Ruggeri, E.M.; Metro, G.; Cognetti, F.; Fabi, A. Bone of the hands as unusual metastatic site of renal cell carcinoma. *J. Exp. Clin. Cancer Res.* **2007**, *26*, 595–597. [[PubMed](#)]
75. Ahlmann, E.R.; Greene, N.W.; Menendez, L.R.; Stevanovic, M.V. Unusual locations for metastatic malignancy of the hand: A report of three cases. *J. Surg. Orthop. Adv.* **2008**, *17*, 267–270. [[PubMed](#)]
76. Chen, T.-J.; Chiou, C.-C.; Chen, C.-H.; Kuo, T.; Hong, H.-S. Metastasis of Mediastinal Epithelioid Angiosarcoma to the Finger. *Am. J. Clin. Dermatol.* **2008**, *9*, 181–183. [[CrossRef](#)]
77. Gaston, R.G.; Lourie, G.M.; Scott, C.C. Isolated metastatic lesion of the trapezium. *Am. J. Orthop.* **2008**, *37*, E144–E145.
78. Miyamoto, W.; Yamamoto, S.; Uchio, Y. Metastasis of gastric cancer to the fifth metacarpal bone. *Hand Surg.* **2008**, *13*, 193–195. [[CrossRef](#)]
79. Ottomani, S.; Levadoux, M.; Cathelineau, O.; Nguyen, M.; Monchal, T. Double localisation métastatique d'un carcinome épidermoïde au niveau de la pulpe digitale. À propos d'un cas et revue de la littérature. *Chir. Main* **2008**, *27*, 243–245. [[CrossRef](#)]
80. Plotkine, E.; Coscas, R.; Guigui, P. Digital metastasis of a nasopharyngeal carcinoma: A surgical trap. *Chir. Main* **2008**, *27*, 187–190. [[CrossRef](#)]
81. Seth, R.; Athanassopoulos, A.; Mir, S. First Presentation of Lung Adenocarcinoma as a Subungual Metastasis. *HAND* **2008**, *3*, 69–71. [[CrossRef](#)]
82. Tzaveas, A.; Paraskevas, G.; Papis, I.; Dimitriadis, A.; Kitsoulis, P.; Vrettakos, A. Metastasis of bronchogenic carcinoma to the 5th metacarpal bone: A case report. *Cases J.* **2008**, *1*, 284. [[CrossRef](#)]
83. Jakhar, S.; Dana, R.; Punia, D. Cancer lung: An unusual presentation. *Indian J. Med. Paediatr. Oncol.* **2009**, *30*, 149. [[CrossRef](#)]
84. Kodama, T.; Kikuchi, N.; Satoh, H.; Ohtsuka, M. Metacarpal Bone Metastasis from Lung Cancer. *Oncol. Res. Treat.* **2009**, *32*, 216–217. [[CrossRef](#)] [[PubMed](#)]
85. Madjidi, A.; Cole, P.; Laucirica, R. Digital acrometastasis: A rare initial sign of occult pulmonary squamous cell carcinoma. *J. Plast. Reconstr. Aesthetic Surg.* **2009**, *62*, e365–e367. [[CrossRef](#)] [[PubMed](#)]
86. Mitrovic, R.; Pakevic, N.; Jeremic, B.; Cesarevic, D.; Živanović, P. Renal cell carcinoma metastasis to hand: Rare localisations of solitary metastases. *Eur. Urol.* **2009**, *8*, 632. [[CrossRef](#)]
87. Otsuji, M.; Matsunaga, S.; Koga, H.; Kawabata, N.; Imakiire, T.; Hiwaki, T.; Tashiro, Y.; Shirahama, H.; Komiya, S. An atypical extrahepatic metastasis of the distal phalanx from hepatocellular carcinoma. *Int. J. Clin. Oncol.* **2009**, *14*, 159–162. [[CrossRef](#)] [[PubMed](#)]
88. Rauh, M.A.; Duquin, T.R.; McGrath, B.E.; Mindell, E.R. Spread of Squamous Cell Carcinoma From the Thumb to the Small Finger via the Flexor Tendon Sheaths. *J. Hand Surg. Am.* **2009**, *34*, 1709–1713. [[CrossRef](#)] [[PubMed](#)]
89. Shrivastava, R.; Singh, K.; Umbarker, B.; Karle, R.; Shrivastava, M. Phalange metastasis from carcinoma of alveolus. *Indian J. Dent. Res.* **2009**, *20*, 496. [[CrossRef](#)] [[PubMed](#)]
90. Wavreille, G.; Baroncini, M.; Rtaimate, M. Une cause rare de pseudohippocratisme digital: L'acrométastase. À propos d'un cas. *Chir. Main* **2009**, *28*, 381–383. [[CrossRef](#)]
91. Afshar, A.; Ilkhanizadeh, B. Leukaemia cutis of the distal phalanx of the right thumb. *J. Hand Surg.* **2010**, *35*, 153–154. [[CrossRef](#)]
92. Anoop, T.M.; George, S.; Divya, K.P.; Jabbar, P.K. Metastatic phalangeal osteolysis as an initial presentation of carcinoma colon. *Am. J. Surg.* **2010**, *200*, e61–e63. [[CrossRef](#)] [[PubMed](#)]
93. Anglada-Curado, F.J.; De Haro-Padilla, J.; Carrasco-Valiente, J.; Alvarez-Kindelan, J.; Ruiz-Garcia, J.; Requena-Tapia, M.J. Hand Metastasis From Renal Carcinoma. *Urology* **2010**, *76*, 846. [[CrossRef](#)] [[PubMed](#)]
94. Biyi, A.; Oufroukhi, Y.; Doudouh, A. Acrométastases de la main et du pied compliquant un cancer mammaire. *Chir. Main* **2010**, *29*, 40–43. [[CrossRef](#)]

95. Borobio León, G.; García Plaza, A.; García Cepeda, I.; González Alconada, R.; Hernández Cosido, L. Metástasis en mano de adenocarcinoma de recto. Un caso excepcional. *Cirugía Española* **2010**, *88*, 195–197. [[CrossRef](#)] [[PubMed](#)]
96. Chakravarthy, V.K.; Rao, N.D.C.; Chandra, S.T. Study of papillary carcinoma of thyroid with uncommon sites of metastasis. *Indian J. Otolaryngol. Head Neck Surg.* **2010**, *62*, 198–201. [[CrossRef](#)] [[PubMed](#)]
97. Long, L.S.; Brickner, L.; Helfend, L.; Wong, T.; Kubota, D. Lung Cancer Presenting as Acrometastasis to the Finger: A Case Report. *Case Rep. Med.* **2010**, *2010*, 1–3. [[CrossRef](#)]
98. Lozić, A.A.B.; Silconi, Z.B.; Misljenović, N. Metastases to rare locations as the initial manifestation of non-small cell lung cancer: Two case reports. *Coll. Antropol.* **2010**, *34*, 609–612.
99. Lucilli, N.; Mattacheo, A.; Palacios, A. Acrometástasis por cáncer de pulmón. A propósito de un caso. *Arch. Bronconeumol.* **2010**, *46*, 279–280. [[CrossRef](#)] [[PubMed](#)]
100. Myrehaug, S.; Bezjak, A. Rapidly progressive bone destruction of the finger as first presentation of systemic metastases from lung cancer. *Case Rep.* **2010**, *2010*, bcr0520091912. [[CrossRef](#)]
101. Vasic, L. Osteolysis of hand bones due to metastatic deposits from colon cancer: A case report. *Med. Pregl.* **2010**, *63*, 719–722. [[CrossRef](#)]
102. Wurapa, R.K.; Bickel, B.A.; Mayerson, J.; Mowbray, J.G. Metastatic esophageal adenocarcinoma of the carpus. *Am. J. Orthop.* **2010**, *39*, 283–285.
103. Amar, M.F.; Almoubaker, S.; Lahrach, K.; Chbani, B.; Bennani, A.; Marzouki, A.; Boutayeb, F. Tumeur géante du pouce révélant un adénocarcinome pulmonaire (à propos d'un cas). *Chir. Main* **2011**, *30*, 133–135. [[CrossRef](#)]
104. Çetin, B.; Büyükberber, S.; Yüksel, M.; Coşkun, U.; Yıldız, R.; Benekli, M. Metastasis of rectal cancer to soft tissue of the hand: An unusual case. *Turk. J. Gastroenterol.* **2011**, *22*, 229–230. [[CrossRef](#)]
105. Chao, D.; Harinarayanan, S.; Reynolds, D. The acromet. *J. Thorac. Dis.* **2011**, *3*, 209–210. [[CrossRef](#)] [[PubMed](#)]
106. Elvey, M.H.; Aghasi, M.; Wasrbrou, Z.; Avisar, E. Metastasis of parotid basal cell adenocarcinoma to the hand—a case report. *Hand* **2011**, *6*, 321–323. [[CrossRef](#)] [[PubMed](#)]
107. Huri, G. An atypical metastasis of follicular-type adenocarcinoma of the thyroid gland to thumb. *Case Rep. Orthop.* **2011**, *2011*, 735789. [[CrossRef](#)]
108. Jenzer, A.; Badur, N.; Vögelin, E. Composite bone cement arthrodesis in acrometastasis of the proximal phalanx of the hand—A case report. *J. Orthop. Surg.* **2011**, *19*, 1–6.
109. Kumar, R.; Kumar, P.; Ghosal, S.; Sharma, S.; Kumar, N.; Bera, A.; Angurana, S.; Srinivasan, R. Palliative and supportive care in acrometastasis to the hand: Case series. *Indian J. Palliat. Care* **2011**, *17*, 241. [[CrossRef](#)] [[PubMed](#)]
110. Taleb, C.; Pelissier, P.; Choughri, H. Bladder urothelial carcinoma with acrometastasis: A case report and review of the literature. *Chir. Main* **2011**, *30*, 136–139. [[CrossRef](#)] [[PubMed](#)]
111. Corrales Pinzón, R.; Alonso Sánchez, J.M.; de la Mano González, S.; El Karzazi Tarazona, K. A single metastasis in the carpal bones as the first clinical manifestation of a hepatocellular carcinoma. *Radiologia* **2014**, *56*, e42–e45. [[CrossRef](#)] [[PubMed](#)]
112. Fadli, A.R.; Azmi, M.N.; David, O.; Zailani, M.H. Isolated metacarpal bone metastasis from advanced rectosigmoid carcinoma. *Int. J. Malaysia.* **2012**, *11*, 59–61.
113. Ferraro, D.; Lucero, P. Metastatic lung adenocarcinoma presenting as thumb pain. *Chest* **2012**, *142*, 567A. [[CrossRef](#)]
114. Gharwan, H.; Yarlagadda, L.; Duffy, A. Acrometastasis as the Initial Presentation of a KRAS -Positive Colon Cancer. *Case Rep. Oncol.* **2012**, *5*, 404–408. [[CrossRef](#)]
115. Kamolz, L.-P.; Stiglbauer, W.; Längle, F. Palmar metastasis of an adenocarcinoma of the esophago-gastric-junction: First case report. *Int. J. Surg. Case Rep.* **2012**, *3*, 412–414. [[CrossRef](#)]
116. Kim, J.I.; Song, C.H.; Gong, H.S. Finger skin metastasis from hepatocellular carcinoma: A case report. *Hand Surg.* **2012**, *17*, 131–134. [[CrossRef](#)] [[PubMed](#)]
117. Ornetti, P.; Favier, L.; Varbedian, O.; Ansemant, T. Digital acrometastasis revealing endometrial cancer relapse. *Arthritis Rheum.* **2012**, *64*, 3167. [[CrossRef](#)] [[PubMed](#)]
118. Rauf, M.S.; Motta, L.; Connolly, C. Digital acrometastases as first sign of hepatocellular carcinoma. *Scott. Med. J.* **2012**, *57*, 247. [[CrossRef](#)]
119. Rinonapoli, G.; Caraffa, A.; Antenucci, R. Lung cancer presenting as a metastasis to the carpal bones: A case report. *J. Med. Case Rep.* **2012**, *6*, 384. [[CrossRef](#)]
120. Roushdi, I.; Jeswani, T.; Clark, D. Lymphoma presenting as a metastasis to the hand. *J. Hand Surg. Eur. Vol.* **2012**, *37*, 286–287. [[CrossRef](#)]
121. Stahl, S.; Santos Stahl, A.; Lotter, O.; Pfau, M.; Perner, S.; Schaller, H.-E. Palliative surgery for skeletal metastases from melanoma in the scaphoid—a critical case report appraisal. *J. Plast. Reconstr. Aesthet. Surg.* **2012**, *65*, 1111–1115. [[CrossRef](#)]
122. Tan, K.T.; Simpson, C.; Chandrasekar, C.R. Hand metastasis: An unusual presentation of renal cell carcinoma. *Hand* **2012**, *7*, 204–206. [[CrossRef](#)]
123. Khmamouche, M.R.; Aassab, R.; Debbagh, A.; Elbabraouy, A.; Mahfoud, T.; Tanz, R.; Ichou, M.; Errihani, H.; Khmamouche, M.R.; Aassab, R.; et al. A thumb acrometastasis revealing lung adenocarcinoma: A case report and review. *J. Clin. Case Rep.* **2013**, *3*, 100–101.
124. Krishnamurthy, A.; Ramshankar, V. Metastatic iodophilic follicular carcinoma of thyroid to a hand bone. *Thyroid. Res. Pr.* **2013**, *10*, 36–37. [[CrossRef](#)]

125. Yoneda, S.; Kinjo, T.; Nonomura, D.; Yamamoto, Y.; Nomura, H.; Tei, N.; Takada, S.; Matsumiya, K.; Fujioka, H. A case of bladder cancer with metastasis to the bone of the hand. *Hinyokika Kyo*. **2013**, *59*, 129–131. [[PubMed](#)]
126. Gilardi, R.; Della Rosa, N.; Pancaldi, G.; Landi, A. Acrometastasis showing an occult lung cancer. *J. Plast. Surg. Hand Surg.* **2013**, *47*, 550–552. [[CrossRef](#)] [[PubMed](#)]
127. Rommer, E.; Leilabadi, S.N.; Lam, G.; Soltani, A.; Ellis, C.V.; Rizvi, M.; Wong, A.K. Metastasis of hepatocellular and renal cell carcinoma to the hand. *Plast. Reconstr. Surgery. Glob. Open* **2013**, *1*, e83. [[CrossRef](#)] [[PubMed](#)]
128. van Veenendaal, L.M.; de Klerk, G.; van der Velde, D. A painful finger as first sign of a malignancy. *Geriatr. Orthop. Surg. Rehabil.* **2014**, *5*, 18–20. [[CrossRef](#)]
129. Hernández-Cortés, P.; Caba-Molina, M.; Gómez-Sánchez, R.; Ríos-Peregrina, R. Renal Clear Cell Carcinoma Acrometastasis. An Unusual Terminal Condition. *J. Hand Microsurg.* **2015**, *7*, 149–151. [[CrossRef](#)]
130. Sumodhee, S.; Huchot, E.; Peret, G.; Marchal, C.; Paganin, F.; Magnin, V. Radiotherapy for a phalanx bone metastasis of a lung adenocarcinoma. *Case Rep. Oncol.* **2014**, *7*, 727–731. [[CrossRef](#)]
131. Liu, W.-C.; Ho, C.-J.; Lu, C.-K.; Wu, C.-C.; Fu, Y.-C.; Chien, S.-H. Acrometastasis to metacarpal bone disclosing an occult lung cancer. *Case reports Plast. Surg. hand Surg.* **2014**, *1*, 23–25. [[CrossRef](#)] [[PubMed](#)]
132. Lambe, G.; Le, P.; Clay, T.D. A finding with a diagnosis: I just can't put my finger on it. *BMJ Case Rep.* **2014**, *2014*. [[CrossRef](#)] [[PubMed](#)]
133. Gorospe Sarasúa, L.; Mezquita Pérez, L.; Pacios Blanco, R.E. Acrometastasis as the initial presentation of lung adenocarcinoma in a young woman. *Arch. Bronconeumol.* **2016**, *52*, 482–483. [[CrossRef](#)] [[PubMed](#)]
134. Reynolds, J.; Skandan, S.P. An uncommon presentation of non-small-cell lung cancer with acrometastases to the great toe and index finger. *J. community Support. Oncol.* **2016**, *14*, 122–125. [[CrossRef](#)] [[PubMed](#)]
135. Sahoo, T.K.; Das, S.K.; Majumdar, S.K.D.; Senapati, S.N.; Parida, D.K. Digital Acrometastasis as Initial Presentation in Carcinoma of Lung A Case Report and Review of Literature. *J. Clin. Diagn. Res.* **2016**, *10*, XD01–XD02. [[CrossRef](#)]
136. Asirvatham Gjorup, C.; Ottesen, S.S.; Gjerloff, C. Acrometastasis as the first sign of an occult non-small cell carcinoma of lung. *J. Plast. Surg. Hand Surg.* **2017**, *51*, 156–157. [[CrossRef](#)] [[PubMed](#)]
137. Muñoz-Mahamud, E.; Combalia, A.; Carreño, A.; Arandes, J.M. Five cases of acrometastasis to the hand from a carcinoma and review of the literature. *Hand Surg. Rehabil.* **2017**, *36*, 12–16. [[CrossRef](#)]
138. Xie, P.; Huang, J. Solitary Thumb Acrometastasis Identified on Bone Scintigraphy. *Clin. Nucl. Med.* **2017**, *42*, 549–550. [[CrossRef](#)]
139. Lechmiannandan, S.; Aida, N.; Paul, A.G.; Thevarajah, S. "Thumb's off" for acrometastasis of renal cell carcinoma: Is there a role for acrometastectomy in the era of targeted therapy? *Asian J. Urol.* **2018**, *5*, 199–201. [[CrossRef](#)]
140. El Idrissi, M.; Akasbi, N.; Elibrahimi, A.; Elmrini, A. Acrometastasis as the first manifestation of lung carcinoma. *Eur. J. Rheumatol.* **2018**, *5*, 212–213. [[CrossRef](#)]
141. Tabrizi, A.; Afshar, A.; Shariyate, M.J.; Gharalari, F.H.; Aidenlou, A. Isolated Metastatic Carcinoma to the Hamate Bone: The First Manifestation of an Occult Malignancy. *J. Hand Microsurg.* **2019**, *11*, S01–S05. [[CrossRef](#)] [[PubMed](#)]
142. Voskuil, R.T.; Smith, J.R.; Swafford, R.E.; Jemison, D.M. Colon adenocarcinoma with metastases to the scaphoid: A case report and review of the literature. *J. Surg. Case Rep.* **2019**, *2019*, rjz011. [[CrossRef](#)] [[PubMed](#)]
143. Hirano, Y.; Sato, R.; Ohshima, N.; Matsui, H. Acrometastasis of Lung Cancer. *Intern. Med.* **2020**, *59*, 1919–1920. [[CrossRef](#)] [[PubMed](#)]
144. Cruz, D.; Wild, T.; Glavynskiy, I.; Weissenberg, K.; Frenzel, S.; Florschütz, A.; Winter, J. Unusual Manifestation of Chronic Lymphocytic Leukemia in the Hand. *J. Hand Surg. Am.* **2021**, *46*, 74.e1–74.e8. [[CrossRef](#)]
145. Gallardo-Alvarado, L.; Ramos, A.A.; Perez-Montiel, D.; Ramirez-Morales, R.; Diaz, E.; Leon, D.C. Hand metastasis in a patient with cervical cancer: A case report. *Medicine* **2020**, *99*, e20897. [[CrossRef](#)] [[PubMed](#)]
146. Flynn, C.J.; Danjoux, C.; Wong, J.; Christakis, M.; Rubenstein, J.; Yee, A.; Yip, D.; Chow, E. Two Cases of Acrometastasis to the Hands and Review of the Literature. *Curr. Oncol.* **2008**, *15*, 51–58. [[CrossRef](#)] [[PubMed](#)]
147. Viswanathan, P.N.; Rangad, F.; Roul, R.K. Metastases to the Hand from Carcinoma of the Lower Alveolus. *J. Hand Surg. Am.* **1996**, *21*, 544–546. [[CrossRef](#)]
148. Tolo, E.T.; Cooney, W.P.; Wenger, D.E. Renal cell carcinoma with metastases to the triquetrum: Case report. *J. Hand Surg. Am.* **2002**, *27*, 876–881. [[CrossRef](#)]
149. Shannon, F.J.; Antonescu, C.R.; Athanasian, E.A. Metastatic thymic carcinoma in a digit: A case report. *J. Hand Surg. Am.* **2000**, *25*, 1169–1172. [[CrossRef](#)]
150. Dar, A.M.; Kawoosa, N.u.N.; Sharma, M.L.; Bhat, M.A. Unusual metastasis to all the digits of both hands in a patient previously operated on for esophageal carcinoma. *Gen. Thorac. Cardiovasc. Surg.* **2011**, *59*, 225–227. [[CrossRef](#)]
151. Bahk, W.-J.; Rhee, S.-K.; Kang, Y.-K.; Lee, A.-H.; Park, J.-M.; Chung, Y.-G. Gastric cancer acrometastases to all digits of one hand following closed intramedullary nailing. *Skeletal Radiol.* **2006**, *35*, 529–532. [[CrossRef](#)] [[PubMed](#)]
152. Sipahioglu, S.; Zehir, S.; Ozkanli, U. Nasopharyngeal carcinoma with hand metastasis. *J. Hand Surg. (European Vol.)* **2012**, *37*, 578–579. [[CrossRef](#)]
153. De Abaffy, A.M.; Richter, R.H.; Grünert, J. Peripheral bone metastasis of a rare lung cancer. *Arch. Orthop. Trauma Surg.* **1998**, *117*, 477–478. [[CrossRef](#)] [[PubMed](#)]

154. Mátrai, Z.; Péley, G.; Rényi Vámos, F.; Farkas, E.; Kovács, T.; Köves, I. The similarities between the mechanism of wound healing and tumor development—literature review on the occasion of a patient with colonic adenocarcinoma metastasis in a dog-bite wound. *Orv. Hetil.* **2005**, *146*, 99–109. [[PubMed](#)]
155. Lewin, J.S.; Cleary, K.R.; Eicher, S.A. An Unusual Metastasis to the Thumb in a Laryngectomized Tracheoesophageal Speaker. *Arch. Otolaryngol.—Head Neck Surg.* **1997**, *123*, 1007–1009. [[CrossRef](#)] [[PubMed](#)]
156. Ozcanli, H.; Ozdemir, H.; Ozenci, A.M.; Söyüncü, Y.; Aydin, A.T. Metastatic tumors of the hand in three cases. *Acta Orthop. Traumatol. Turc.* **2005**, *39*, 445–448. [[PubMed](#)]
157. Hsieh, C.-Y.; Bai, L.-Y.; Lo, W.-C.; Huang, H.-H.; Chiu, C.-F. Esophageal Squamous Cell Carcinoma with a Solitary Phalangeal Metastasis. *South. Med. J.* **2008**, *101*, 1159–1160. [[CrossRef](#)] [[PubMed](#)]
158. Stone, R.; Davies, J. Isolated digital metastasis in bronchogenic carcinoma. *Palliat. Med.* **1990**, *4*, 137–138. [[CrossRef](#)]
159. Bhandari, T.; Brown, E. Acrometastasis and the Potential Benefits of Early Positron Emission Tomography Scanning. *Ann. Plast. Surg.* **2011**, *67*, 189–192. [[CrossRef](#)]
160. Reichert, B.; Hoch, J.; Plötz, W.; Mailänder, P.; Moubayed, P. Metastatic Clear-Cell Sarcoma of the Capitate. *J. Bone Jt. Surgery-American Vol.* **2001**, *83*, 1713–1717. [[CrossRef](#)]
161. Khosla, D.; Rai, B.; Patel, F.D.; Sapkota, S.; Srinivasan, R.; Sharma, S.C. Acrometastasis to hand in vaginal carcinoma: A rare entity. *J. Cancer Res. Ther.* **2012**, *8*, 430–432. [[CrossRef](#)] [[PubMed](#)]
162. Song, Y.; Yao, J. Trapezial Metastasis as the First Indication of Primary Non-small Cell Carcinoma of the Lung. *J. Hand Surg. Am.* **2012**, *37*, 1242–1244. [[CrossRef](#)] [[PubMed](#)]
163. Ghert, M.A.; Harrelson, J.M.; Scully, S.P. Solitary renal cell carcinoma metastasis to the hand: The need for wide excision or amputation. *J. Hand Surg. Am.* **2001**, *26*, 156–160. [[CrossRef](#)] [[PubMed](#)]
164. Kosuda, S.; Gokan, T.; Tamura, K.; Dokiya, T.; Kubo, A.; Hashimoto, S. Radionuclide Imaging of Two Patients with Metastasis to a Distal Phalanx of the Hand. *Clin. Nucl. Med.* **1986**, *11*, 659–660. [[CrossRef](#)] [[PubMed](#)]
165. Vijayakumar, S.; Creditor, M. Metastasis to the hand. *J. Natl. Med. Assoc.* **1986**, *78*, 441–442. [[PubMed](#)]
166. Buckley, N.; Brown, P. Metastatic tumors in the hand from adenocarcinoma of the colon. *Dis. Colon Rectum* **1987**, *30*, 141–143. [[CrossRef](#)]
167. Hindley, C.J.; Metcalfe, J.W. A colonic metastatic tumor in the hand. *J. Hand Surg. Am.* **1987**, *12*, 803–805. [[CrossRef](#)]
168. Bourne, M.H.; Amadio, P.C.; Wold, L.E.; Sim, F.H. Metastatic lesions of the hand: Report of a case. *Orthopedics* **1988**, *11*, 219–221. [[CrossRef](#)]
169. Craigen, M.; Chesney, R. Metastatic adenocarcinoma of the carpus: A case report. *J. Hand Surg. J. Br. Soc. Surg. Hand* **1988**, *13*, 306–307. [[CrossRef](#)]
170. Dalicho, F.H.; Beckmann, D.; Hübner, L. Metastasis of cervical cancer to the end phalanx of the small finger. *Zentralbl. Gynakol.* **1988**, *110*, 111–114.
171. Haas, O.; Bernard, A.; Cougard, P.; Viard, H. Phalangeal metastasis of cancer of the esophagus. Apropos of a case. *Ann. Chir.* **1988**, *42*, 37–38. [[PubMed](#)]
172. Müller, S.; Dörner, A.; Dallek, M.; Supra, T. Handmetastasen—eine seltene Metastasierungsform des kolorektalen Karzinoms. *DMW—Dtsch. Medizinische Wochenschrift* **2008**, *113*, 728–730. [[CrossRef](#)]
173. Sanjay, B.; Raj, G.A.; Vishwakarma, G. A small-cell osteosarcoma with multiple skeletal metastases. *Arch. Orthop. Trauma. Surg.* **1987**, *107*, 58–60. [[CrossRef](#)]
174. Tenenbaum, F.; Reverberi, J.; Vacher, B.; Pulik, M. Metastasis in the carpal bones and cancer of the esophagus. *J. Chir.* **1988**, *125*, 443–444.
175. Heymans, M.; Jardon-Jeghers, C.; Vanwijck, R. Hand metastases from urothelial tumor. *J. Hand Surg. Am.* **1990**, *15*, 509–511. [[CrossRef](#)]
176. Lederer, A.; Flückiger, F.; Wildling, R.; Fruhwirth, J. A solitary metastasis in the trapezium bone. *Radiologe* **1990**, *30*, 79–80. [[PubMed](#)]
177. Turan, I.; Sjöden, G.O.J.; Kalen, A. Ovarian carcinoma metastasis to the little finger. *Acta Orthop. Scand.* **1990**, *61*, 185–186. [[CrossRef](#)] [[PubMed](#)]
178. Desmanet, E.; Amrani, M.; Fievez, R.; Six, C. Les acrométastases. *Ann. Chir. la Main du Memb. Supérieur* **1991**, *10*, 154–157. [[CrossRef](#)]
179. Henkert, K.; Berge, G. Malignant metastases on the hand. *Zentralbl. Chir.* **1991**, *116*, 337–341. [[PubMed](#)]
180. Moutet, F.; Bellon-Champel, P.; Lebrun, C.; Sarrazin, R. A propos d'une métastase isolée au grand os. *Ann. Chir. la Main du Memb. Supérieur* **1991**, *10*, 148–150. [[CrossRef](#)]
181. Rochet, N.; Pages, M.; Lassoued, S.; Poey, C.; Fournié, B.; Fournié, A. Phalangeal metastasis of the hand. Apropos of a case. *Rev. Rhum. Mal. Osteoartic.* **1991**, *58*, 73–74.
182. Troncoso, A.; Ro, J.Y.; Grignon, D.J.; Han, W.S.; Wexler, H.; von Eschenbach, A.; Ayala, A.G. Renal cell carcinoma with acrometastasis: Report of two cases and review of the literature. *Mod. Pathol.* **1991**, *4*, 66–69.
183. Bloom, R.A.; Sulkes, A.; Freilick, G.; Libson, E. Breast metastases to bones of the extremities: Simultaneous involvement of all four limbs. *Clin. Oncol.* **1992**, *4*, 58–59. [[CrossRef](#)]
184. DiSpaltro, F.X.; Bickley, L.K.; Nissenblatt, M.J.; Devereux, D. Cutaneous acral metastasis in a patient with primary gastric adenocarcinoma. *J. Am. Acad. Dermatol.* **1992**, *27*, 117–118. [[CrossRef](#)]

185. Hayes, M.M.; Jones, E.C.; Verma, A.K.; Lim, C.H.; Milne, G.; Tse, E. Transitional cell carcinoma of the renal pelvis metastatic to the metacarpal. A case report correlating cytologic and histologic findings. *Acta Cytol.* **1992**, *36*, 946–950.
186. Jebson, P.; Buckwalter, J.; Blair, W.; Platz, C. Hand metastasis from renal carcinoma. *Iowa Orthop. J.* **1992**, *12*, 85–87.
187. Kobus, R.J.; Leinberry, C.; Kirkpatrick, W.H. Metastatic renal carcinoma in the hand: Treatment with preoperative irradiation and ray resection. *Orthop. Rev.* **1992**, *21*, 983–984. [[PubMed](#)]
188. Rousseau, A.; Madinier, J.F.; Favre, A.; Michenet, P. Tumeurs métastatiques des parties molles de la main A propos d'un cas. Revue de la littérature. *Ann. Chir. la Main du Memb. Supérieur* **1992**, *11*, 57–61. [[CrossRef](#)]
189. Bibi, C.; Benmeir, P.; Maor, E.; Sagi, A. Hand Metastasis from Renal Cell Carcinoma with No Bone Involvement. *Ann. Plast. Surg.* **1993**, *31*, 377–378. [[CrossRef](#)]
190. Marya, S.K.; Singh, S.; Jaswal, T.S.; Garg, P.; Gupta, A.K. Digital and clavicular bone metastasis from transitional cell carcinoma of urinary bladder: A case report. *Indian J. Pathol. Microbiol.* **1993**, *36*, 75–77. [[PubMed](#)]
191. Roncaglio, C.; Arena, B. Metastasi alla mano da carcinoma broncopolmonare. *Minerva Ortop. Traumatol.* **1993**, *44*, 37–43.
192. Knapp, D.; Abdul-Karim, F.W. Fine needle aspiration cytology of acrometastasis. A report of two cases. *Acta Cytol.* **1994**, *38*, 589–591. [[PubMed](#)]
193. Walsh, T.M.; Mileski, R.A.; Ferlic, T.P. Metastatic transitional cell carcinoma to the hand. *J. Hand Surg. Am.* **1994**, *19*, 806–808. [[CrossRef](#)]
194. De Maeseneer, M.; Machiels, F.; Naegels, S.; Verhaeghe, W. Hand and foot acrometastases in a patient with bronchial carcinoma. *J. Belge Radiol.* **1995**, *78*, 274–275.
195. Castello, J.R.; Garro, L.; Romero, F.; Campo, M.; Najera, A. Metastatic Tumours of the Hand. *J. Hand Surg. Am.* **1996**, *21*, 547–550. [[CrossRef](#)]
196. Hetzel, D.J.; Olt, G.J.; Sorosky, J.I.; Mortel, R.; Singapuri, K.; Podczaski, E.S. Gestational Trophoblastic Disease Presenting as a Large Metastasis to the Finger. *Gynecol. Oncol.* **1996**, *63*, 123–126. [[CrossRef](#)]
197. Königsberger, H.; Goth, D. Bone metastasis of bronchial carcinoma to the wrist. Case report. *Handchir. Mikrochir. Plast. Chir.* **1996**, *28*, 46–49.
198. Saglike, Y.; Demirtas, M.; Demirors, H. Metastatic tumours of the hand. *Int. Orthop.* **1996**, *20*, 123–124. [[CrossRef](#)]
199. Vine, J.E.; Cohen, P.R. Renal cell carcinoma metastatic to the thumb: A case report and review of subungual metastases from all primary sites. *Clin. Exp. Dermatol.* **1996**, *21*, 377–380. [[CrossRef](#)]
200. Bauer, P.; Saalfeld, U.; Schmidt, G.; Partecke, B.D. A rare case of metastasis of urinary bladder carcinoma in the pisiform bone. A case report. *Handchir. Mikrochir. Plast. Chir.* **1997**, *29*, 154–157.
201. Hatakeyama, S.; Tachibana, A.; Suzuki, K.; Okano, H. A case of metastasis to the metacarpal bone of the right thumb from squamous cell carcinoma of the lung. *Jpn. J. Lung Cancer* **1997**, *37*, 531–535. [[CrossRef](#)]
202. Méndez López, J.M.; García Mas, R.; Salvà Coll, G. Metastasis of an adenocarcinoma of the colon to the 1st metacarpal bone. *Ann. Chir. Main Memb. Super.* **1997**, *16*, 134–137.
203. Rügenapf, G.; Rupperecht, H.; Groitl, H.; Grunert, J.; Hohenberger, W. Fingermetastase eines Kolonkarzinoms. *Coloproctology* **1997**, *19*, 169–172. [[CrossRef](#)]
204. Baron, J.M.; Borrego, P.; Solis, J.A. Metastasis en la mano, a proposito de un caso. *Oncologia* **1998**, *21*, 184–186.
205. Delsmann, B.; Lienemann, A.; Nerlich, A.; Hoffmann, E.; Caselmann, W.; Refior, H. Primärmanifestation eines hepatozellulären Carcinoms als osteolytische Handmetastase—Ein Fallbericht. *Z. Orthop. Ihre Grenzgeb.* **2008**, *136*, 571–573. [[CrossRef](#)]
206. Baran; Guillot; Tosti Metastasis from carcinoma of the bronchus to the distal aspect of two digits. *Br. J. Dermatol.* **1998**, *138*, 708. [[CrossRef](#)] [[PubMed](#)]
207. Celik, G.; Saryal, S.; Enacar, N. Mixed squamous and small cell lung carcinoma with separate histologic subtypes in eye and phalanx metastases. *J. Exp. Clin. Cancer Res.* **1998**, *17*, 129–130.
208. Chirodian, N.; Dickson, M.G.; Kerr, P.S. Fingertip metastasis presenting with a history of trauma. *Hosp. Med.* **1998**, *59*, 819. [[PubMed](#)]
209. Galmarini, C.; Kertesz, A.; Oliva, R.; Porta, J.; Galmarini, F.C. Metastasis of bronchogenic carcinoma to the thumb. *Med. Oncol.* **1998**, *15*, 282–285. [[CrossRef](#)] [[PubMed](#)]
210. Massraf, A.B.; Wand, J.S. Haemorrhagic secondary prostatic metastasis of the terminal phalanx of the thumb. *Injury* **1998**, *29*, 243–245. [[CrossRef](#)]
211. Adegboyega, P.A.; Adesokan, A.; Viegas, S.F. Acrometastasis in Renal Cell Carcinoma. *South. Med. J.* **1999**, *92*, 1009–1012. [[CrossRef](#)] [[PubMed](#)]
212. Chang, S.E.; Choi, J.H.; Sung, K.J.; Moon, K.C.; Koh, J.K. Metastatic squamous cell carcinoma of the nail bed: A presenting sign of lung cancer. *Br. J. Dermatol.* **1999**, *141*, 939–940. [[CrossRef](#)]
213. Giberti, C.; Mantero, R.; Schienone, M.; Costa, M.; Lavagna, M. Unusual location for secondary bone metastasis from advanced renal cell carcinoma. *Acta Urol. Ital.* **1999**, *13*, 177–178.
214. Lee, K.-S.; Lee, S.-H.; Kang, K.-H.; Oh, K.-J. Metastatic hepatocellular carcinoma of the distal phalanx of the thumb: A case report. *Hand Surg.* **1999**, *4*, 95–100. [[CrossRef](#)]
215. Okada, H.; Weller, M.; Huang, R.; Finocchiaro, G.; Gilbert, M.R.; Wick, W.; Ellingson, B.M.; Hashimoto, N.; Pollack, I.F.; Brandes, A.A.; et al. Immunotherapy response assessment in neuro-oncology: A report of the RANO working group. *Lancet Oncol.* **2015**, *16*, e534–e542. [[CrossRef](#)]

216. Vanhooiteghem, O.; Dumont, M.; André, J.; Leempoel, M.; de la Brassinne, M. Bilateral subungual metastasis from squamous cell carcinoma of the lung: A diagnostic trap! *Rev. Med. Liege* **1999**, *54*, 653–654. [[PubMed](#)]
217. Esther, R.J.; Bos, G.D. Management of metastatic disease of other bones. *Orthop. Clin. North Am.* **2000**, *31*, 647–659. [[CrossRef](#)]
218. Hayden, R.J.; Sullivan, L.G.; Jebson, P.J. The hand in metastatic disease and acral manifestations of paraneoplastic syndromes. *Hand Clin.* **2004**, *20*, 335–343. [[CrossRef](#)]
219. Umana, G.E.; Passanisi, M.; Tranchina, M.G.; Fricia, M.; Nicoletti, G.F.; Cicero, S.; Scalia, G. Letter to the Editor Regarding “Rare Thymoma Metastases to the Spine: Case Reports and Review of the Literature. *World Neurosurg.* **2020**, *138*, 567–569. [[CrossRef](#)]
220. Afshar, A.; Farhadnia, P.; Khalkhali, H. Metastases to the Hand and Wrist: An Analysis of 221 Cases. *J. Hand Surg. Am.* **2014**, *39*, 923–932. [[CrossRef](#)]
221. Ponzo, G.; Umana, G.E.; Giuffrida, M.; Furnari, M.; Nicoletti, G.F.; Scalia, G. Intramedullary craniovertebral junction metastasis leading to the diagnosis of underlying renal cell carcinoma. *Surg. Neurol. Int.* **2020**, *11*, 152. [[CrossRef](#)] [[PubMed](#)]
222. Fiori, R.; Coco, I.; Nezzo, M.; Kabunda, G.; Umana, G.E.; Fraioli, M.F.; Simonetti, G. Spinal Hydatidosis Relapse: A Case Report. *Case Rep. Orthop.* **2014**, *2014*, 1–6. [[CrossRef](#)] [[PubMed](#)]
223. Passanisi, M.; Scalia, G.; Palmisciano, P.; Franceschini, D.; Crea, A.; Capone, C.; Tranchina, M.G.; Nicoletti, G.F.; Cicero, S.; Umana, G.E. Difficulty differentiating between a posterior extradural lumbar tumor versus sequestered disc even with gadolinium-enhanced MRI. *Surg. Neurol. Int.* **2021**, *12*, 267. [[CrossRef](#)] [[PubMed](#)]
224. Libson, E.; Bloom, R.A.; Husband, J.E.; Stoker, D.J. Metastatic tumours of bones of the hand and foot. *Skeletal Radiol.* **1987**, *16*, 387–392. [[CrossRef](#)] [[PubMed](#)]
225. Kerin, R. The hand in metastatic disease. *J. Hand Surg. Am.* **1987**, *12*, 77–83. [[CrossRef](#)]
226. Sonoda, L.I.; Halim, M.Y.; Balan, K.K. Solitary Phalangeal Metastasis of Renal Cell Carcinoma on Bone Scintigram. *Clin. Nucl. Med.* **2011**, *36*, 237–239. [[CrossRef](#)]
227. Healey, J.H.; Turnbull, A.D.; Miedema, B.; Lane, J.M. Acrometastases. A study of twenty-nine patients with osseous involvement of the hands and feet. *J. Bone Joint Surg. Am.* **1986**, *68*, 743–746. [[CrossRef](#)] [[PubMed](#)]
228. Tewari, M.K.; Khosla, V.K.; Sharma, B.S.; Vashistha, R.K.; Khandelwal, N.K.; Kak, V.K. Brain metastasis from urachal carcinoma: Case report. *Surg. Neurol.* **1994**, *42*, 340–342. [[CrossRef](#)]
229. Rodrigues, L.; Cornelis, F.H.; Reina, N.; Chevret, S. Prevention of Pathological Fracture of the Proximal Femur: A Systematic Review of Surgical and Percutaneous Image-Guided Techniques Used in Interventional Oncology. *Medicina.* **2019**, *55*, 755. [[CrossRef](#)]
230. Toliušis, V.; Kalesinskas, R.; Kiudelis, M.; Maleckas, A. Surgical treatment of humeral metastatic tumors. *Medicina* **2009**, *45*, 607. [[CrossRef](#)]