

# Life-threatening arterioureteral fistula treatment by endovascular complete anatomic iliac artery bifurcation reconstruction

Alexander Massmann, MD,<sup>a</sup> Peter Fries, MD,<sup>a</sup> Roushanak Shayesteh-Kheslat, MD,<sup>b</sup> Arno Buecker, MD,<sup>a</sup> Michael Stöckle, MD,<sup>c</sup> and Christina Niklas, MD,<sup>c</sup> Homburg/Saar, Germany

## ABSTRACT

We present an endovascular approach for anatomic reconstruction of the iliac bifurcation in life-threatening arterio-ureteral fistula without sacrificing the pelvic arterial vascular supply. Five consecutive patients suffering from acute onset of significant gross hematuria caused by iliac-ureteral fistula resulting from previous oncologic surgery and radiation therapy were treated by transfemoral stent graft implantation in a double-barrel technique. Iliac-ureteral pseudoaneurysm coverage succeeded in an iliac neobifurcation with preservation of pelvic perfusion. Follow-up ranging from 9 to 37 months confirmed cessation of hematuria. One patient experienced stent graft thrombosis of the external iliac artery as a result of large cervical cancer invasion treated by crossover bypass. In all other patients, stent grafts were patent. (*J Vasc Surg Cases and Innovative Techniques* 2020;6:199-204.)

**Keywords:** Hematuria; False aneurysm; Pseudoaneurysm; Vascular fistula; Ureter; Stent graft

Arterioureteral fistula (AUF), a rare, potentially life-threatening condition, is caused by a connection of the distal ureter to the distal common iliac artery (CIA) or proximal external iliac artery (EIA). Endovascular treatment by percutaneous deployment of stent grafts for false aneurysm coverage has been established as the treatment of choice.<sup>1,2</sup> However, for closure of the underlying pseudoaneurysm, the internal iliac artery (IIA) is regularly sacrificed. This technical report illustrates a minimally invasive concept for IIA preservation, avoiding consecutive sequelae (eg, impaired pelvic perfusion) resulting in buttock claudication or compromised wound healing.

## METHODS

During 2014 to 2019, five consecutive patients (four women; mean age, 55 years; range, 41-67 years) complained of flank pain and acute onset of relevant gross hematuria after multiple retrograde ureteral stent exchanges. Numerous ureteral catheterizations were

necessary during the last years because of urinary obstruction after combined surgical rectum amputation and irradiation for the treatment of cervical or rectal carcinoma. One patient additionally suffered from vesicoureteral fistula, and one patient suffered from large tumor invasion into the EIA (Table). In each case, contrast-enhanced computed tomography confirmed an underlying pseudoaneurysm originating from the right distal CIA at the iliac bifurcation. An additional small dissection and thrombus extended to the proximal EIA (Fig 1).

**Interventional treatment.** This study obtained approval from Ethikkommission der Ärztekammer des Saarlandes, Saarbrücken/Germany. All procedures performed were in accordance with the ethical standards of the institutional or national research committee and with the 1964 Helsinki Declaration and its later amendments or comparable ethical standards. Informed consent was obtained from all individual participants included in the study.

Percutaneous endovascular coverage of the false aneurysm was performed by deployment of standard stent grafts in a double-barrel technique by a single interventional radiologist (Fig 2). First, a crossover sheath was placed into the contralateral common femoral artery. Angiography verified pseudoaneurysms of the CIA next to the iliac bifurcation (Fig 3, A and B; Video 1). Additional 8F access was established to the ipsilateral common femoral artery. For iliac bifurcation reconstruction, self-expanding (Viabahn; W. L. Gore & Associates, Flagstaff, Ariz) and balloon-mounted (Advanta V12; Maquet, Rastatt, Germany) stent grafts were used off label at the operator's discretion. A stent graft was deployed into the CIA from ipsilateral (Video 2). The

---

From the Clinic for Diagnostic and Interventional Radiology,<sup>a</sup> Clinic for Urology and Pediatric Urology,<sup>b</sup> and Clinic for General, Abdominal and Vascular Surgery,<sup>c</sup> Saarland University Medical Center.

Author conflict of interest: none.

Correspondence: Priv-Doz Dr med Alexander Massmann, MD, Saarland University Medical Center, Diagnostic and Interventional Radiology, Kirrberger Straße, Gebäude 50.1, 66421 Homburg/Saar, Germany (e-mail: alexander.massmann@uks.eu).

The editors and reviewers of this article have no relevant financial relationships to disclose per the Journal policy that requires reviewers to decline review of any manuscript for which they may have a conflict of interest.

2468-4287

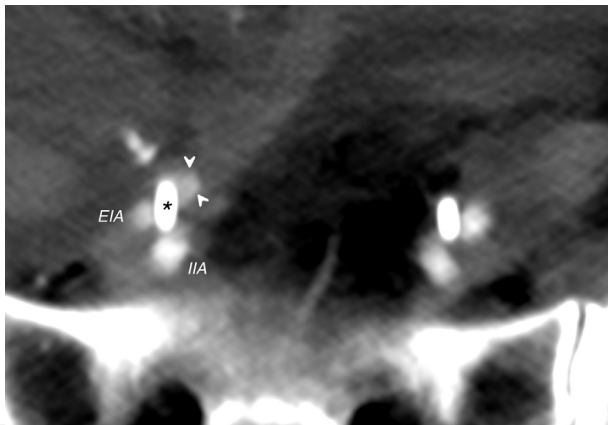
© 2020 The Authors. Published by Elsevier Inc. on behalf of Society for Vascular Surgery. This is an open access article under the CC BY-NC-ND license (<http://creativecommons.org/licenses/by-nc-nd/4.0/>).

<https://doi.org/10.1016/j.jvscit.2020.01.012>

**Table.** Patient chart

	Symptoms	Tumor	Confounding factors	AUF location
Patient 1	Gross hematuria	Cervical cancer	Vesicocutaneous fistula	Proximal EIA (Figs 1 and 3)
Female		Radical hysterectomy and TMMR with iatrogenic sigmoid perforation	Indwelling ureteral catheters for 3 years	
66 years		Radiation therapy, chemotherapy		
Patient 2	Gross hematuria	Cervical cancer	EIA tumor invasion	Distal CIA
Female		Radical hysterectomy and TMMR	Indwelling ureteral catheters for 2 years	
41 years		Radiation therapy, chemotherapy Relapse with pelvic tumor debulking and sigmoid resection		
Patient 3	Gross hematuria	Cervical cancer	Indwelling ureteral catheters for 3 years	Distal CIA
Female		Radical hysterectomy and TMMR		
55 years		Radiation therapy, chemotherapy		
Patient 4	Gross hematuria	Rectal cancer	Indwelling ureteral catheters for 4 years	Distal CIA
Male		Low anterior rectum resection		
67 years		Radiation therapy, chemotherapy		
Patient 5	Gross hematuria	Cervical cancer	Indwelling ureteral catheters for 3 years	Distal CIA
Female		Radical hysterectomy and TMMR		
44 years		Radiation therapy, chemotherapy		

AUF, Arterioureteral fistula; CIA, common iliac artery; EIA, external iliac artery; TMMR, total mesometrial resection.



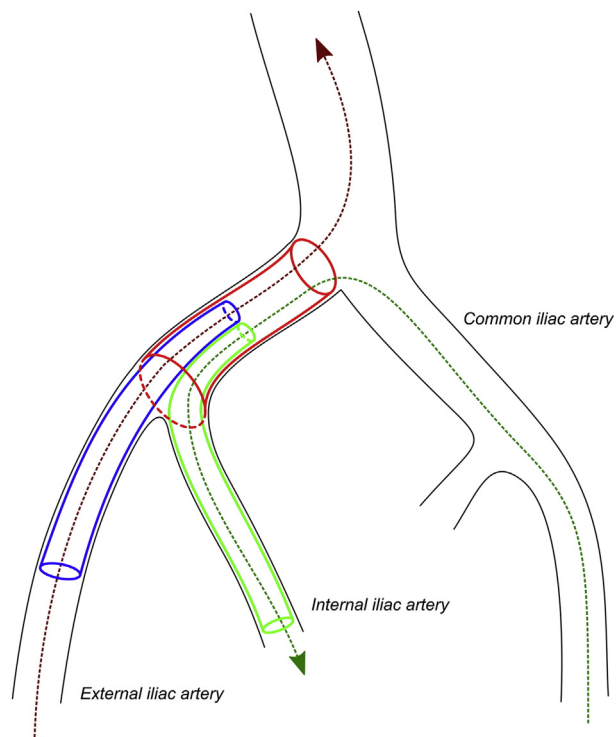
**Fig 1.** Contrast-enhanced computed tomography illustrates a pseudoaneurysm (arrowheads) at the proximal external iliac artery (EIA) in close relationship to the junction of the distal ureter identifiable by the ureteral stent (asterisk). IIA, Internal iliac artery.

stent graft and IIA were catheterized from contralateral. Other stent grafts were introduced into the IIA from contralateral and into the EIA from ipsilateral. After parallel alignment, both stent grafts were simultaneously deployed out of the CIA stent graft into the EIA and IIA in kissing stent position (Fig 3, C-F; Video 3).

Periprocedural anticoagulation included 5000 units of unfractionated heparin and therapeutic anticoagulation for 48 hours, clopidogrel 75 mg/d orally for 4 weeks, and acetylsalicylic acid 100 mg/d orally lifelong. Prospective follow-up included regular urologic examinations, ultrasound, and computed tomography for a median of 18 (range, 7-37) months.

## RESULTS

Technical success for deployment of stent grafts resulting in an iliac neobifurcation was 100%. Mean procedure time from vessel puncture to access closure was 54 (range, 40-60) minutes; fluoroscopy time was 12.6 (9-17) minutes using 50 (40-60) mL of iodinated contrast medium. All pseudoaneurysms were successfully covered. Iliac arteries showed preserved IIA perfusion. Hematuria stopped immediately. During follow-up of a median 18 (9-37) months, no signs of pelvic ischemia or infection occurred. In one patient, pre-existing chronic vesicocutaneous fistula disappeared after 3 months. In one patient suffering from tumor invasion into the EIA, clinically significant stent graft thrombosis of the EIA occurred after 6 weeks, resulting in symptomatic limb ischemia. For this patient, relatively small balloon-mounted stent grafts of 8 mm and 6 mm had to be used. Because of previous tumor invasion,



**Fig 2.** Sketch of endovascular anatomic reconstruction of iliac neobifurcation for preservation of the hypogastric artery in sandwich technique. In a first step, a stent graft (red tube) is deployed into the ipsilateral common iliac artery (CIA) through a femoral-aorta guidewire (red dotted line). In a second step, the lumen of the CIA stent graft and internal iliac artery (IIA) are cannulated in crossover technique from contralateral transfemoral access. After insertion of a femoral-IIA guidewire (green dotted line), another stent graft is introduced from the CIA stent graft into the IIA (green tube). Finally, a stent graft is advanced from ipsilateral to connect the CIA stent graft into the external iliac artery (EIA). Both stent grafts are simultaneously deployed in kissing stent position, which results in an Y-configured iliac neobifurcation.

endovascular thrombectomy was avoided in favor of surgical crossover bypass. In all other patients, iliac arteries and stent grafts were patent.

## DISCUSSION

AUF is a potentially life-threatening condition; a high level of clinical suspicion is essential for establishing the correct diagnosis. Extensive pelvic surgery, radiation therapy, and resulting ureteral obstruction in combination with indwelling ureteral stents are common causes of AUF.<sup>1,2</sup> Demographics in industrial nations, improved long-term survival after pelvic irradiation, and increasing numbers of patients with ureteral stenting result in rising numbers of patients with AUF. Typical localization is the pelvic brim, where ureters are crossing the CIA. The CIA is more often involved than the IIA or EIA. Complex AUF may present as ureteroenteric or vesicocutaneous, as described in one patient of our case series.<sup>1</sup> A key

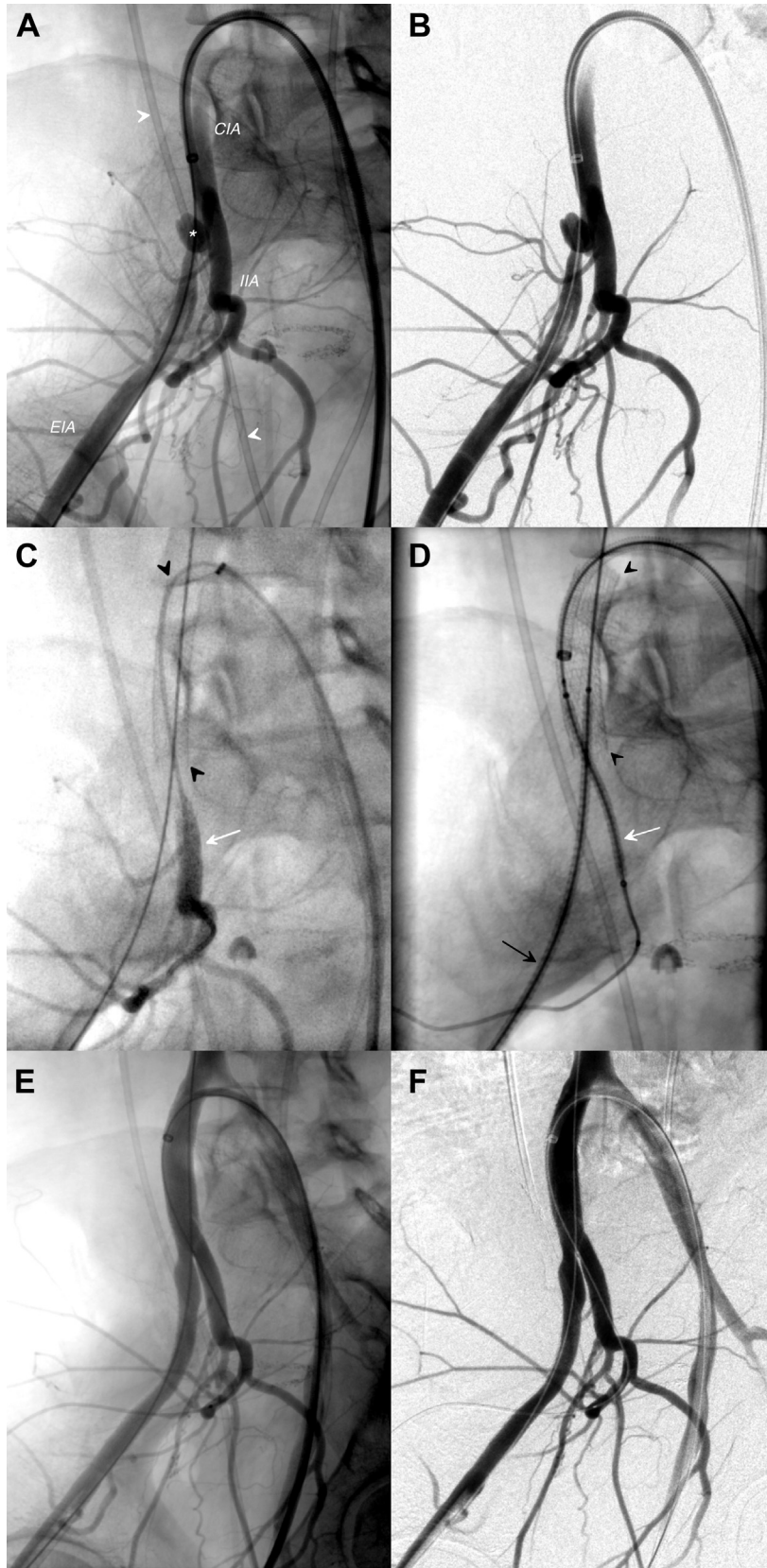
indication is intermittent microhematuria or gross hematuria necessitating blood transfusions. High mortality is caused by significant delay in diagnosis and effective treatment.<sup>1,2</sup>

Development of AUF is attributed to impairment of the vasa vasorum. Consecutive inflammation and vulnerability result in ureteral obstruction and ureteral or arterial wall necrosis. Arterial injury is directly related to radiation dosage, with higher doses causing larger injury.<sup>3</sup> Trauma during ureteral catheterization causes additional alteration to fragile ureteral and arterial wall with pseudoaneurysm development.<sup>4</sup> Ureteral stents act as a counterbrace. Large ureteral stents lead to increased wall compression and ischemia. Given the fact that 7F stents provide the same flow rate as 12F stents, the smallest diameter and softest material available should be used for ureteral catheterization.<sup>5</sup>

Acute treatment of AUF challenges immediate control of life-threatening bleeding and repair of pathologic arterioureteral communication. Open surgical repair includes iliac artery ligation and in situ bypass or extra-anatomic bypass reconstruction. Typical endovascular approaches include a coil-and-cover stent technique. Primary repair of the iliac artery or arterial occlusion should be avoided. Preceding surgery or irradiation risks bowel injury and arterial complications including a high rate of enterocutaneous fistula.<sup>1,2</sup> In case of short life expectancy, ureteral diversion with percutaneous nephrostomy and ureteral occlusion is performed. Without arterial occlusion or repair, this method is associated with recurrent bleeding.<sup>1,2</sup> Stent grafts allow prompt hemorrhage control. In case of enteric communication, endovascular treatment may serve as a provisional bridging solution for patients with considerable comorbidities.<sup>1,3</sup> Ureteral disease is manageable by ureteral stenting, nephrostomy, ureteral resection and primary anastomosis, creation of an ileal interposition, nephrectomy with ureteral ligation, or nephroureterectomy.<sup>1-3</sup>

All these concepts deal with discontinuation of iliac arteries and ureter. The commonly used coil-and-cover approach for IIA occlusion does not focus on the underlying cause of critically impaired arterial perfusion. IIA embolization is known for the risk of significant buttock claudication, erectile dysfunction, and colonic or sigmoid ischemia.<sup>5,6</sup> Iliac side branch devices or stent grafts have been used for IIA preservation in aneurysmal aortoiliac disease.<sup>7</sup> In our patients, iliac side branch devices were not feasible because of unsuitable iliac artery diameters.<sup>8</sup> Difficult morphology and small (tortuous) vessels are main predictors for unfavorable outcome.<sup>6-10</sup>

Stent grafts for reconstruction of iliac neobifurcation using the double-barrel technique are illustrated in Fig 1. Standard available off-the-shelf stent grafts were used off label. In case of tortuosity and severely



angulated IIA, self-expanding stent grafts are favored. These stent grafts are also available in longer lengths. Balloon-mounted stent grafts, characterized by an increased radial force, are predominantly used for stenotic cases. Oversizing of the double-barrel stent grafts generates a seamless implantation into the CIA stent graft, reducing the risk for gutter endoleak by interspaces between the stent grafts.<sup>6,8-10</sup> Presence of relevant gutter endoleak would clinically result in persisting hematuria. Contrast-enhanced ultrasound and computed tomography are typically used for imaging of endoleaks. Occlusion can be performed by stent graft upsizing with oversized balloon dilation, proximal or distal stent graft extension, or various types of embolization material according to endoleak therapy after endovascular aortic aneurysm repair. The length of the stent graft for the CIA was adapted to the length of the CIA. The proximal end of the stent grafts branching into the IIA and EIA were positioned from the middle of the CIA stent graft to allow sufficient overlap of at least 2 cm. Stent graft length for the IIA and EIA was chosen to achieve sufficient coverage into healthy IIA and EIA segments.

The described endovascular technique adapted from aortoiliac aneurysm treatment proved to be beneficial for iliac pseudoaneurysm coverage.<sup>7</sup> The primary objective—to demonstrate the technical feasibility of iliac pseudoaneurysm coverage for control of life-threatening bleeding with preservation of hypogastric artery perfusion by endovascular means—has been achieved. Closure of pseudoaneurysms was effective. Stent graft implantation in double-barrel technique for complete anatomic iliac artery reconstruction was successful. The main benefit of our approach is hypogastric artery preservation, avoiding gluteal claudication. Although not systematically assessed, quality of life showed impressive improvement in some of our

patients. As a sign of arterial perfusion improvement, vesicocutaneous fistula in one patient disappeared after 3 months without need for additional interventions. Tumor infiltration and obstruction of iliac arteries and symptomatic peripheral artery occlusive disease were delayed using covered stent graft implantation. In one patient, early stent graft thrombosis occurred, probably caused by pre-existing large tumor vessel invasion and small vessel diameters. However, closure of false aneurysm with cessation of gross hematuria was achieved. Lower limb ischemia was successfully treated by femoral crossover bypass, which is by far a less invasive procedure compared with aneurysm resection and aortofemoral bypass, especially in case of tumor encasement. Embolization of the IIA alone would not be sufficient for treatment of AUF. In general, additional stent grafting is necessary for coverage of the iliac AUF. IIA coil embolization prevents retrograde perfusion of the pseudoaneurysm through the gluteal arteries. Femoral crossover bypass is necessary only in case of symptomatic obstruction of the CIA or EIA.

Foreign body (eg, stent grafts) may be prone to infection. In case of stent graft infection, explantation, surgical AUF resection combined with proximal and distal iliac artery ligation, and extra-anatomic aortofemoral or crossover femoral bypass are indicated. We estimated the risks for failure of endovascular AUF repair to be much lower compared with the risks of a primary surgical approach. In case of stent graft infection, naive to conservative treatment using antibiotics, surgical repair is always possible.

This study has several limitations. AUF is a rare disease. AUF is an important diagnosis for which a high clinical index of suspicion must be maintained in the relevant patient cohort. The presented technique is available only in highly specialized endovascular centers. Follow-up is heterogeneous. There is lack of a control case.

**Fig 3. A,** Angiography from contralateral transfemoral access depicts a pseudoaneurysm (*asterisk*) combined with small dissection and thrombus of the proximal external iliac artery (*EIA*) directly at the iliac bifurcation in close relationship to the crossing distal ureter marked by a ureteral stent (*arrowheads*). *CIA*, Common iliac artery; *IIA*, internal iliac artery. **B,** Digital subtraction angiography of **(A)**. **C,** A self-expanding stent graft (Viabahn 10/50 mm; W. L. Gore & Associates, Flagstaff, Ariz) is deployed into the right CIA (*arrowheads*) with its distal end precisely proximal to the origin of the IIA. The stent graft lumen and IIA (*arrow*) are cannulated from the contralateral 8F crossover sheath using a 4F catheter. **D,** After cannulation of the CIA stent graft and IIA from crossover, another stent graft (Viabahn 7/50 mm) is introduced from the 8F crossover sheath out of the CIA stent graft into the IIA. A stent graft (Viabahn 8/100 mm) is advanced through the ipsilateral 11F sheath out of the CIA stent graft into the EIA. The image shows stent grafts to IIA and EIA after parallel alignment just before final deployment. **E,** Final angiography confirms anatomic reconstruction of iliac neobifurcation after simultaneous deployment of both stent grafts out of the stent graft in the CIA in kissing stent position. Pseudoaneurysm is completely excluded, and patent perfusion to iliac arteries is present. **F,** Digital subtraction angiography of **(E)**.



## CONCLUSIONS

Life-threatening bleeding caused by AUF is a must-see diagnosis for urologists. Multidisciplinary treatment should be performed at specialized centers. Percutaneous endovascular iliac neobifurcation reconstruction for coverage of iliac pseudoaneurysms combined with preservation of the IIA proved to be beneficial as a technically safe and feasible option.

## REFERENCES

1. van den Bergh RC, Moll FL, de Vries JP, Lock TM. Arterio-ureteral fistulas: unusual suspects—systematic review of 139 cases. *Urology* 2009;74:251-5.
2. Heers H, Netsch C, Wilhelm K, Secker A, Kurtz F, Spachmann P, et al. Diagnosis, treatment, and outcome of arterio-ureteral fistula: the urologist's perspective. *J Endourol* 2018;32:245-51.
3. Himmel PD, Hassett JM. Radiation-induced chronic arterial injury. *Semin Surg Oncol* 1986;2:225-47.
4. Adams PS. Iliac artery-ureteral fistula developing after dilatation and stent placement. *Radiology* 1984;153:647-8.
5. Chew BH, Knudsen BE, Denstedt JD. The use of stents in contemporary urology. *Curr Opin Urol* 2004;14:111-5.
6. Massmann A, Mosquera Arochena NJ, Shayesteh-Kheslat R, Buecker A. Endovascular anatomic reconstruction of the iliac bifurcation with covered stentgrafts in sandwich-technique for the treatment of complex aorto-iliac aneurysms. *Int J Cardiol* 2016;222:332-9.
7. Donas KP, Torsello C, Pitoulias GA, Austermann M, Papadimitriou DK. Surgical versus endovascular repair by iliac branch device of aneurysms involving the iliac bifurcation. *J Vasc Surg* 2011;53:1223-9.
8. Lobato AC. Sandwich technique for aortoiliac aneurysms extending to the internal iliac artery or isolated common/internal iliac artery aneurysms: a new endovascular approach to preserve pelvic circulation. *J Endovasc Ther* 2011;18:106-11.
9. Massmann A, Serracino-Inglott F, Buecker A. Endovascular aortic repair with the chimney technique using the ultra low-profile Ovation stent-graft for juxtarenal aneurysms having small iliac access vessels. *Cardiovasc Intervent Radiol* 2014;37:488-92.
10. DeRubertis BC, Quinones-Baldrich WJ, Greenberg JI, Jimenez JC, Lee JT. Results of a double-barrel technique with commercially available devices for hypogastric preservation during aortoiliac endovascular abdominal aortic aneurysm repair. *J Vasc Surg* 2012;56:1252-9.

Submitted Oct 31, 2019; accepted Jan 26, 2020.