



## Case Report

# Resolution of atlanto-occipital cyst with conservative management: A case report and review of the literature

Gaetano De Biase<sup>1</sup>, Gabriella A. Rivas<sup>1</sup>, Ricardo A. Domingo<sup>1</sup>, Mark Hurdle<sup>2</sup>, Selby Chen<sup>1</sup>, W. Christopher Fox<sup>1</sup> 

Departments of <sup>1</sup>Neurosurgery and <sup>2</sup>Pain Medicine, Mayo Clinic, Jacksonville, Florida, United States.

E-mail: Gaetano De Biase - [debiase.gaetano@mayo.edu](mailto:debiase.gaetano@mayo.edu); Gabriella A. Rivas - [gabriella.rivas@outlook.com](mailto:gabriella.rivas@outlook.com); Ricardo A. Domingo - [rdomingo94@gmail.com](mailto:rdomingo94@gmail.com); Mark Hurdle - [hurdle.mark@mayo.edu](mailto:hurdle.mark@mayo.edu); Selby Chen - [chen.selby@mayo.edu](mailto:chen.selby@mayo.edu); \*W. Christopher Fox - [fox.chris@mayo.edu](mailto:fox.chris@mayo.edu)



### \*Corresponding author:

W. Christopher Fox,  
Department of Neurosurgery,  
Mayo Clinic, Jacksonville,  
United States.

[fox.chris@mayo.edu](mailto:fox.chris@mayo.edu)

Received : 12 September 2022

Accepted : 23 September 2022

Published : 21 October 2022

### DOI

10.25259/SNI\_841\_2022

### Quick Response Code:



## ABSTRACT

**Background:** Spinal synovial cysts are cystic dilatations of synovial sheaths that extrude into the spinal canal. Despite their generally benign behavior, they can cause severe symptoms due to compression of neural structures. They are most commonly found in the lumbar spine and are rare in the cervical region, especially at the atlanto-occipital junction.

**Case Description:** A 65-year-old presented with neck pain and headaches. The magnetic resonance imaging (MRI) revealed a degenerative cyst within the anterior foramen magnum causing anterior spinal cord and brainstem compression. Multiple surgical treatment options were discussed, and he was prescribed methylprednisolone and immobilization of his cervical spine with a rigid collar. One month later, the patient reported dramatic improvement of his symptoms, and no surgery was performed. One year later, his pain had remained much improved with the continued use of the collar and pain management (i.e., using anti-inflammatories and muscle relaxants). The 1-year follow-up MRI showed the atlanto-occipital cyst compressing the cervicomedullary junction had completely resolved along with the brainstem compression.

**Conclusion:** A 65-year-old presented with myelopathy attributed to a large anterior foramen magnum atlanto-occipital cyst compressing the cord. Conservative management for 1 month with a rigid cervical collar and steroids resulted in marked neurological improvement; at 1 year follow-up, the patient was markedly improved with an MR that demonstrated spontaneous cyst regression.

**Keywords:** Atlantoaxial arthropathy, Cervical collar, Facet arthropathy, Neck pain, Synovial cyst

## INTRODUCTION

Spinal synovial cysts (SCs) are cystic dilatations of synovial sheaths that extrude into the spinal canal and can occur in various spinal regions. Their presence likely reflects excessive joint mobility/instability. They are most commonly found in the lumbar spine, are rare in the cervical region, even more uncommonly found at the atlanto-occipital junction where they can result in significant myelopathy secondary to spinal cord compression. Here, we describe an anterior atlanto-occipital SC markedly compressing the spinal cord of a 65-year-old male who spontaneously regresses utilizing steroids and a cervical collar for 1 year.

This is an open-access article distributed under the terms of the Creative Commons Attribution-Non Commercial-Share Alike 4.0 License, which allows others to remix, transform, and build upon the work non-commercially, as long as the author is credited and the new creations are licensed under the identical terms.

©2022 Published by Scientific Scholar on behalf of Surgical Neurology International

## CASE PRESENTATION

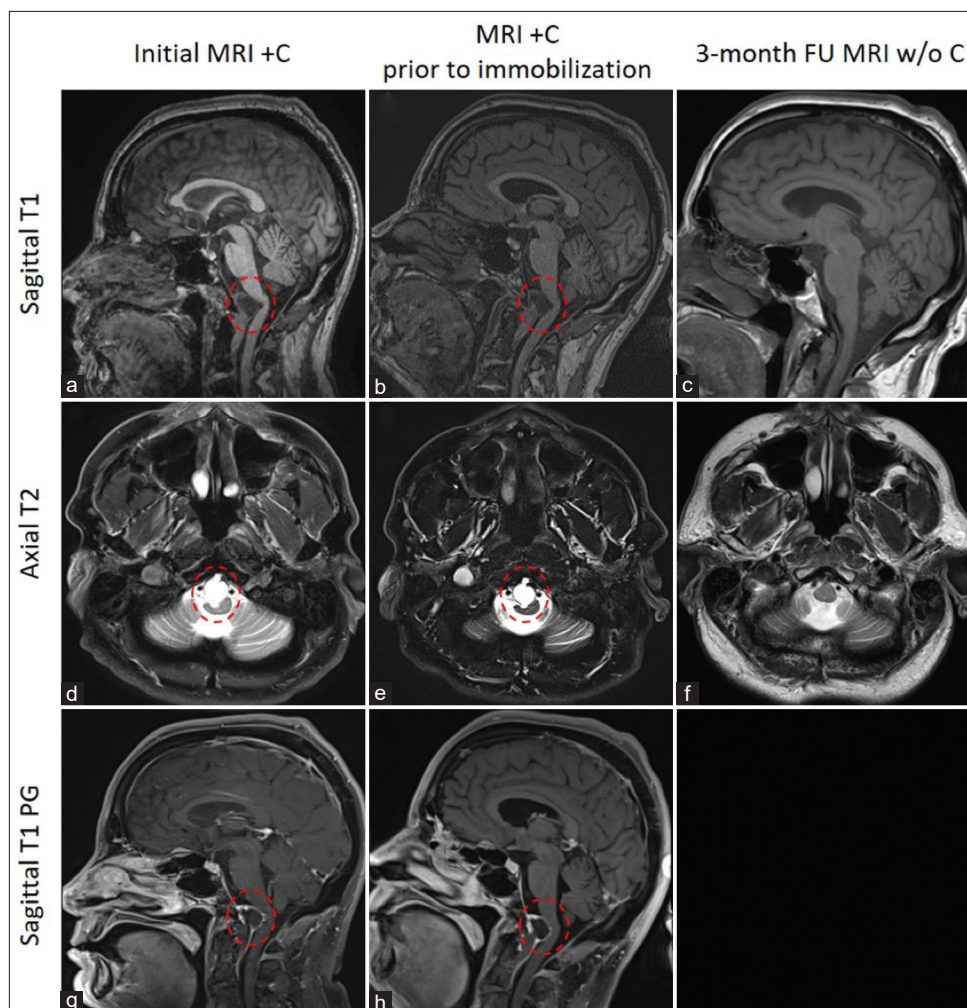
### History and presentation

A 65-year-old male presented with tension headaches and neck pain but no myelopathy for 2 years' duration. At that point, the cervical magnetic resonance imaging (MRI) scan showed an anterior atlanto-occipital cyst that filled the anterior foramen magnum and caused marked ventral brainstem and upper cervical spinal cord compression [Figure 1] but without intrinsic cord edema/myelomalacia. Notably, the peripheral enhancement indicated that it was a degenerative cyst. Due to the patient's refusal of surgery, conservative management was recommended (i.e., cervical

bracing/steroids). In addition, follow-up MR studies were ordered to follow the cyst.

### 6-Month follow-up MR

The 6-month follow-up MRI showed interval enlargement of the degenerative cyst at the occipitoatlantal junction, with increased pressure on brainstem at the cervicomedullary junction. Clinically, however, he did not have any problems with ambulation or bowel and bladder control and did not report any new symptoms referable to compression of the nervous tissue. Due to the cyst size and further enlargement, surgery, consisting of a transnasal endoscopic resection of the cyst



**Figure 1:** Serial magnetic resonance imaging scans before and after conservative management with the use of a soft collar illustrating resolution of a large atlanto-occipital cyst secondary to severe arthritis. Sagittal T1-weighted sequences at presentation (a), before immobilization (b), and at 3-month follow-up (c) showing complete resolution of a large atlanto-occipital cyst. Axial T2-weighted sequences at presentation (d), before immobilization (e), and at 3-month follow-up (f) showing resolution of initial brainstem compression. Sagittal T1 contrast-enhanced sequences at presentation (g) and before immobilization (h) showing atlanto-occipital cyst with an enhancing capsule causing significant brainstem compression and medullary kinking (circled in red is the atlanto-occipital cyst).

**Table 1:** Previous reported cases of atlanto-occipital joint synovial cysts, presentation, and management.

Case report	Age (y)/sex	Clinical presentation	Treatment
Mujic <i>et al.</i> , 2003	52/male	Dysarthria and swallowing difficulty	Far lateral approach
Baldauf <i>et al.</i> , 2005	51/female	Slurred speech	Far lateral endoscopic approach
Elhammady <i>et al.</i> , 2009	67/female	Neck discomfort, speech, and swallowing difficulty	Juxtacondylar approach
Hénaux <i>et al.</i> , 2011	75/female	Swallowing difficulty	Conservative
Gassie <i>et al.</i> , 2019	67/male	Decreased tongue dexterity and slurred speech	Suboccipital craniectomy
Current case	65/male	Neck pain and headaches	Conservative with cervical collar and steroids

followed by occipital cervical fusion was recommended, but the patient declined. Rather, he was prescribed methylprednisolone (Medrol Dosepak) and a cervical collar. At 1-month follow-up, the patient reported dramatic improvement of his pain; he was advised to continue to wear a semi-rigid neck collar and use meloxicam as needed.

### 8-Month and 1-year follow-up MR scans

The next follow-up MRI 8 months after his initial presentation showed that the cyst had stabilized in size/dimension, and he had symptomatically improved; he continued to use the cervical collar. At 1-year follow-up, pain at the OC junction largely resolved using the collar, anti-inflammatory medication, and muscle relaxants. This improvement correlated with the 1-year follow-up MRI that demonstrated complete spontaneous regression of the atlanto-occipital cyst with no further evidence of kink/compression of the brainstem at the cervicomedullary junction [Figure 1]. We recommended that he continues to wear his collar when physically active, with further follow-up with an MRI in 1 additional year.

## DISCUSSION

SCs are cystic dilatations of synovial sheaths that extrude into the spinal canal and can occur at various spinal levels. Notably, atlanto-occipital SCs are exceedingly rare. Several treatment options are available including surgical resection (with or without stabilization and computed tomography-guided cyst aspiration) versus various conservative measures (i.e., anti-inflammatory drugs, physical therapy, supportive braces, and steroid injections). Although some spinal SCs can resolve spontaneously, most SCs at the craniocervical junction in myelopathic patients with MR-documented cord/brainstem compression require decompression/fusion.

### Literature review of five prior cases of atlanto-occipital junction SCs

We found just five other case reports of SCs at the atlanto-occipital junction; the SCs spontaneously regressed in only

one patient [Table 1].<sup>[1-5]</sup> Our patient, who declined surgery, was conservatively with steroids and a cervical collar for 1 year during which time his myelopathy improved and the repeated MR studies confirmed cyst regression.

### Potential mechanisms of spontaneous cyst regression

The mechanism of spontaneous cyst resolution is still unclear. Spontaneous resolution may follow spontaneous rupture, or desiccation and phagocytosis both being promoted by the inflammatory response induced by the SC itself, similar to spontaneous resolution of lumbar disk herniations. Limitation of joint mobility with the use of a cervical collar could play a role in cyst resolution, particularly in cases with spinal instability.

## CONCLUSION

Here, we successfully treated a 65-year-old male with a large anterior atlanto-occipital cyst causing significant brainstem compression but without myelopathy with a cervical collar and steroids (i.e., latter PRN) for 1 year. This resulted in neurological improvement and spontaneous regression of the cyst.

### Declaration of patient consent

Patient's consent not required as patient's identity is not disclosed or compromised.

### Financial support and sponsorship

Nil.

### Conflicts of interest

There are no conflicts of interest.

## REFERENCES

- Baldauf J, Junghans D, Schroeder HW. Endoscope-assisted microsurgical resection of an intraneural ganglion cyst of the

- hypoglossal nerve. *J Neurosurg* 2005;103:920-2.
2. Elhammady MS, Farhat H, Aziz-Sultan MA, Morcos JJ. Isolated unilateral hypoglossal nerve palsy secondary to an atlantooccipital joint juxtafacet synovial cyst. *J Neurosurg Spine* 2009;10:234-9.
  3. Gassie K, Grewal S, Chen SG. Atlantooccipital synovial cyst with isolated hypoglossal nerve palsy: Case report of nonfusion surgical approach and review of literature. *World Neurosurg* 2019;126:434-8.
  4. Hénaux PL, Hamlat A, Riffaud L, Guégan Y, Morandi X. Spontaneous regression of a symptomatic atlanto-occipital joint cyst. Case report. *Neurochirurgie* 2011;57:129-32.
  5. Mujic A, Hunn A, Liddell J, Taylor B, Havlat M, Beasley T. Isolated unilateral hypoglossal nerve paralysis caused by an atlanto-occipital joint synovial cyst. *J Clin Neurosci* 2003;10:492-5.

**How to cite this article:** De Biase G, Rivas GA, Domingo RA, Hurdle M, Chen S, Fox WC. Resolution of atlanto-occipital cyst with conservative management: A case report and review of the literature. *Surg Neurol Int* 2022;13:478.

### Disclaimer

The views and opinions expressed in this article are those of the authors and do not necessarily reflect the official policy or position of the Journal or its management. The information contained in this article should not be considered to be medical advice; patients should consult their own physicians for advice as to their specific medical needs.