



Direct Wave Intraoperative Neuromonitoring for Spinal Tumor Resection: A Focused Review

Zachary T. Olmsted¹, Brendan Ryu¹, Ganesh Phayal¹, Ross Green¹, Sheng-Fu Larry Lo¹, Daniel M. Sciubba¹, Justin W. Silverstein^{1,2}, Randy S. D'Amico¹

Key words

- Corticospinal tract
- D-wave
- Intramedullary spinal cord tumor
- Intraoperative neuromonitoring
- Multimodal
- Predictive value
- Spinal tumor resection

Abbreviations and Acronyms

- CST:** Corticospinal tract
D-waves: Direct waves
GTR: Gross total resection
IDEM: Intradural extramedullary
IMSCT: Intramedullary spinal cord tumor
IONM: Intraoperative neurophysiological monitoring
MEP: Motor-evoked potentials
mIONM: Multimodal intraoperative neurophysiological monitoring
mMEP: Myogenic motor-evoked potentials
MMS: Modified McCormick scale
NPV: Negative predictive value
PPV: Positive predictive value
SSEP: Somatosensory-evoked potentials
tcMEP: Transcranial motor-evoked potentials

From the Departments of ¹Neurological Surgery and ²Neurology, Lenox Hill Hospital/Donald and Barbara Zucker School of Medicine at Hofstra, Northwell Health, New York, New York, USA

To whom correspondence should be addressed:
 Zachary T. Olmsted, Ph.D.
 [E-mail: zacholmsted3@gmail.com]

Citation: *World Neurosurg.* X (2023) 17:100139.
<https://doi.org/10.1016/j.wnsx.2022.100139>

Journal homepage: www.journals.elsevier.com/world-neurosurgery-x

Available online: www.sciencedirect.com

2590-1397/© 2022 The Author(s). Published by Elsevier Inc.
 This is an open access article under the CC BY-NC-ND license (<http://creativecommons.org/licenses/by-nc-nd/4.0/>).

INTRODUCTION

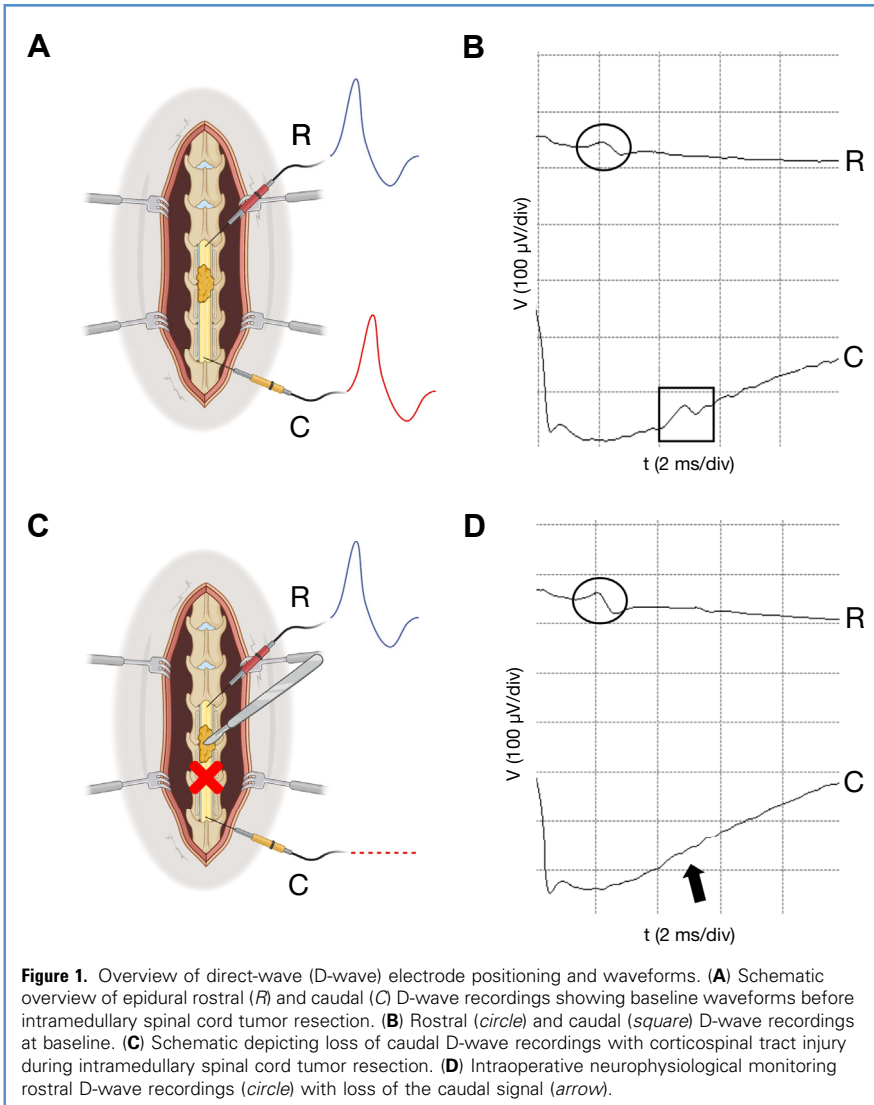
The resection of spinal cord tumors poses unique challenges compared with their supratentorial counterparts because of the physical space constraints and density of functionally distinct white matter tracts. Perhaps most challenging to treat are primary intramedullary spinal cord tumors (IMSCTs) arising within the spinal cord parenchyma that can displace and/or

At present, surgical resection of primary intramedullary spinal cord tumors is the mainstay of treatment. However, given the dimensional constraints of the narrow spinal canal and dense organization of the ascending and descending tracts, intramedullary spinal cord tumor resection carries a significant risk of iatrogenic neurological injury. Intraoperative neurophysiological monitoring (IONM) and mapping techniques have been developed to evaluate the functional integrity of the essential neural pathways and optimize the surgical strategies. IONM can also inform on impending harm to at-risk structures and can correlate with postoperative functional recovery if damage has occurred. Direct waves (D-waves) will provide immediate feedback on the integrity of the lateral corticospinal tract. In the present review, we have provided an update on the utility of D-waves for spinal cord tumor resection. We have highlighted the neuroanatomical and neurophysiological insights from the use of D-wave monitoring, the technical considerations and limitations of the D-wave technique, and multimodal co-monitoring with motor-evoked potentials and somatosensory-evoked potentials. Together with motor-evoked potentials, D-waves can help to guide the extent of tumor resection and provide intraoperative warning signs and alarm criteria to direct the surgical strategy. D-waves can also serve as prognostic biomarkers for long-term recovery of postoperative motor function. We propose that the use of D-wave IONM can contribute key findings for clinical decision-making during spinal cord tumor resection.

invade the white matter, impairing neurotransmission between the brain and the periphery. Resection of IMSCTs, both benign and malignant, can result in postoperative functional deficits from fiber manipulation and poses a risk to patient quality of life after surgery.¹ During the past 3 decades, intraoperative neurophysiological monitoring (IONM) modalities have been established and widely implemented with the goal of minimizing iatrogenic injury risk via real-time assessment of neural pathway integrity.^{2,3} IONM has been particularly useful during IMSCT resection surgery with predictive value for functional outcomes.²⁻⁶ The interdependence of the neuroanatomy and system-level neurophysiology during IONM has resulted in an ideal neurosurgical strategy.

Multiple IONM modalities have been developed and have often been implemented together to monitor at-risk

pathways simultaneously. Monitoring of motor-evoked potentials (MEP), reflecting descending motor neurotransmission, and somatosensory-evoked potentials (SSEP), reflecting ascending cuneatus and gracilis pathways, has been routinely used.^{7,8} Direct waves (D-waves) provide a continuous method to selectively monitor the lateral corticospinal tract (CST), which is one spinal conduit involved in musculoskeletal control.⁹⁻¹¹ D-waves can provide an explanation of the integrity of the CST at a given instant in the form of a mathematical algorithm using an electric current. By establishing the physical correlates of waveform changes with anatomic deformation and intraoperative events, neurosurgical teams have developed standardized biomarkers for use as warning signs and alarm criteria to identify imminent, reversible injury that should prompt surgical adjustments. This ability to



detect and adapt reduces the potential for irreversible harm.² By retrospectively correlating neurological function with IMSCT anatomic involvement, surgical events, and IONM data, an expanding body of evidence is being generated to refine the prognostic accuracy within the operating room to predict the long-term functional outcomes.^{12,13}

Historically, MEP have been favored over D-waves owing to the inability to predict for neurological deterioration in the immediate postoperative setting. However, recent extended studies have revealed the power of D-wave IONM to predict the motor function in the long term.¹² As the reference standard for CST monitoring, D-waves, combined with

MEP and SSEP, have seen increased usage during tumor resection to generate a holistic view of separate, yet integrated, spinal pathway functioning.^{2,12-19} This IONM strategy has implications both intraoperatively, to avoid preventable injury and direct surgical strategies, and postoperatively, to predict the neurological status that is essential to patient satisfaction and quality of life. In the present focused review, we have summarized the D-wave technique and provided an update of D-wave utility during IMSCT resection. In addition to the neurophysiology and technical considerations inherent to D-wave IONM, we have discussed the multimodal analysis of D-waves with MEP and SSEP

and the role of D-waves in guiding the extent of spinal tumor resection. The prognostic value of using the warning signs and alarm criteria related to the intraoperative events and functional recovery in the context of multimodal IONM has been emphasized.

METHODS

Search Criteria

The Medline/PubMed and Google Scholar databases were queried using the following search terms: corticospinal tract, spinal tumor, intramedullary spinal cord tumor, intradural extramedullary tumor, D-wave, somatosensory evoked potential, motor evoked potential, intraoperative neurophysiological monitoring, multimodal intraoperative neuro-monitoring, and spinal cord neuro-monitoring. English language reports were considered from 1954 to 2022. The full text of the included studies was acquired and carefully reviewed by multiple authors. We synthesized findings from basic neuroanatomy and neurophysiology, 1 case report, multiple retrospective cases series, systematic reviews, and meta-analyses to summarize the state of the field and current recommendations for the use of D-wave monitoring. Abstract-only and non-English reports were excluded.

Review

Neurophysiological Insight Provided by D-Waves. Neuromonitoring using epidural recordings of MEP and/or D-waves is the reference standard for assessing CST integrity intraoperatively.^{14,16} In this paradigm, a single anodal pulse stimulus to the motor cortex is used to achieve cortical activation and generates descending cortical neuron volleys.²⁰ Peripheral propagation (~50 m/second) of the resulting action potentials from the cortex to the muscle can be measured en route within the spinal cord as D-waves or at the muscle terminus itself as MEP.^{7,8,21,22} However, the detection of activated, fast-conducting motor fibers within the CST as triphasic D-waves provides the most direct report of CST function.^{14,16} These measurable D-waves can be recorded by electrodes positioned in the epidural or subdural compartment,

just caudal to the surgical site. A control electrode placed rostrally to this site will provide a reference recording upstream of the manipulated CST fibers that will be susceptible to injury (Figure 1).¹² Unlike myogenic MEP, which depend on short-pulse train activation at the cortex to generate multiple descending volleys and reflect multiple descending pathways, CST-specific D-wave recordings are obtained in a continuous fashion for real-time feedback.¹⁰ The single pulse stimulation paradigm also solves the issue of MEP detection in patients under general anesthesia for whom the ability of the motor cortex to generate multiple descending volleys will be impaired.⁹ This seemingly simplistic technical adaptation was sufficient to overcome the longstanding inability to monitor CST activity intraoperatively in anesthetized patients. Within D-wave neuromonitoring, the single most important metric used to assess CST stability or compromise is the peak-to-peak amplitude of the D-wave from baseline compared with at various operative stages (e.g., opening of the dura, start of resection, removal of mass, irrigation, and recovery). The evidence-based consensus is that the total disruption, or disappearance, of D-waves can affirm the presence of paraplegia. The derangement of D-waves to <50% of the caudal baseline amplitude should also be a reason to stop or pause surgery to avoid permanent neurological damage. Because D-waves deteriorate gradually, prompt recognition of attenuation will help to avoid such outcomes and allow for modification of the surgical strategy.²³ Among the various intraoperative neuromonitoring modalities, including SSEP monitoring, MEP monitoring, and electromyography, D-wave preservation has been the strongest functional predictor of the long-term postoperative motor status.^{2,16,17,19} As such, the ability to monitor D-waves has been demonstrated as an independent positive prognostic factor for long-term functioning, even when the MEP and/or SSEP have been lost or are unobtainable. A multimodal combination of the durable D-wave technique with MEP and other neuromonitoring tools can further enhance the neurosurgical team's understanding of the clinical

picture intraoperatively, informing on both temporary deficits and the likelihood of long-term functional recovery.^{2,16}

Technical Considerations with D-Wave Neuromonitoring. D-waves will often be elicited using the same cephalic stimulation electrodes used for transcranial MEP (tcMEP) monitoring. The cephalic electrodes should be arranged in a bipolar configuration using the anode as the primary stimulator and the ground electrode placed on one of the shoulders.^{12,24} Thus, the stimulating electrodes should be positioned ~1 cm anterior to the C₃ and C₄ scalp positions, as described by the International 10-20 system. A lower stimulus intensity is used to deliver a single pulse (75–500- μ s duration) instead of the pulse trains used for tcMEP monitoring. In addition to the transcranial stimulating electrodes, separate downstream spinal electrodes must be placed to monitor the CST.

For the recording electrodes placed at the level of the spinal cord, 3-lead configurations will typically be used to allow for testing of several bipolar arrangements. The organization that generates the most robust D-waves should be chosen for recording and monitoring. Although traditionally placed in the epidural compartment, 2- or 3-contact catheter-type electrodes (Ad-Tech, Oak Creek, Wisconsin, USA) can also be inserted within the subdural space. The electrodes should ideally be placed immediately caudally and rostrally to the level of the tumor. The rostral electrode will record the D-waves above that surgical site and will serve as a positive control regarding the caudal electrode placed downstream of the manipulated tract fibers, reporting on CST integrity. One example of a recording montage was presented by Costa et al.¹⁸ in which electrode 1 (active) to electrode 2 (reference) and/or electrode 2 to electrode 3 were used for the rostral recordings and electrode 2 to electrode 1 and/or electrode 3 to electrode 2 were used for the caudal recordings to achieve the same polarity response from both sites. It is crucial that the electrodes have a low impedance for D-wave recordings to avoid a stimulus artifact from the current applied over the scalp.⁹ Amplified signals of $\leq 10,000\times$ are fed

through bandpass filters of ~50–3000 Hz, although this value has varied between groups.^{16,18,24} Occasionally, the D-waves will need to be averaged over a series of 5–25 consecutive 50-ms sweeps to improve the signal/noise ratio. This will become particularly salient during revision surgery because the normal anatomic planes have already been distorted. Baseline D-waves should be established before tumor resection, and the amplitude should be set using onset-to-peak markers.²⁴ These should then be sampled as necessary during the procedure with a constant reference to the baseline values.

Practical Use and Limitations of D-Wave Neuromonitoring. The ability to monitor the D-waves provides a durable and effective metric to assess CST integrity during spinal resection surgery. The technique has been approved and well-established for use with human spinal surgery for >20 years. Its use does not require special consent in addition to that required for neuromonitoring. In addition to traditional SSEP and MEP electrodes, D-wave-specific spinal electrodes are required to detect volleys. The method is adaptable by community neurosurgery with existing neuromonitoring capabilities. The neurophysiologist must have an advanced understanding of the signal/noise ratio with an ability to troubleshoot noise artifacts because the amplitudes tend to be small compared with those of limb MEP. Mitigation of the noise artifact can be accomplished by adjusting the filter settings, stimulation averaging, and/or placement of the epidural electrodes into the subdural compartment. Interpreting and troubleshooting D-wave recordings also requires the understanding that intramedullary tumors can desynchronize corticospinal axon firing, complicating the elicitation of stable D-waves.

Additional technical limitations related to the CST anatomy and patient-specific scenarios exist. If the spinal tumor is located below the spinal cord level of T₁₀–T₁₁, D-wave neuromonitoring cannot be used because no CST input occurs below this level and, therefore, no signal will be detectable.⁹ The use of rostral control electrodes will not be feasible for high cervical tumors because of anatomic

Table 1. Intraoperative Interventions and Predicted Motor Outcomes Informed by Combined D-Wave and mMEP Monitoring

mMEP	D-Wave	Suggested Intraoperative Adjustments	Predicted Motor Outcome
Baseline	Baseline	No change	Baseline
Attenuated	Baseline or decreased <50%	Surgical pause to recover mMEP; perform warm irrigation, correct vital signs (e.g., hypotension)	Baseline
Absent (unilateral or bilateral)	Baseline or decreased <50%	Surgical pause to recover mMEP; surgery can proceed without mMEP recovery in most cases	Transient motor deficit
Absent (bilateral)	Decreased \geq 50%	Stop operation; abandon procedure if D-waves do not recover	Permanent motor deficit

D-wave, direct wave; mMEP, myogenic motor-evoked potentials.

constraints.¹² Below T₁, concomitant MEPs will be recorded from the lower extremities only; however, above this level, the upper extremities will also be included.

Patient-specific considerations such as their medical and surgical histories are also critical. A routine practice with IONM-guided resection surgery of spinal tumors includes comprehensive characterization of the preoperative neurological status. Most studies investigating the feasibility and effects of IONM have reported the modified McCormick scale (MMS) grades at admission that quantify functional independence (grades I and II) versus dependence (grades IV and V).⁴ The ability to monitor the D-waves at baseline can be significantly compromised by preexisting deficits or a poor preoperative neurological status. Patients with a good preoperative neurological status and low MMS scores will tend to exhibit robust D-wave monitoring. Revision after previous spinal resection surgery or radiation therapy must contend with distorted anatomic planes and dense dural adhesions that can either affect the intrinsic D-wave CST signal or prevent electrode placement.^{2,12,24} Disruption of the CST by irradiation or intramedullary tumor invasion or a mass effect can result in a D-wave desynchronization phenomenon that will impair D-wave monitoring.²⁵ In countries where D-wave electrodes have not yet been approved, myogenic MEP (mMEP) monitoring alone can be a viable

alternative.²⁵ An additional caveat is that amplitude monitoring alone will not capture the entire length of the CST; thus, defects arising distal to the placed electrodes could remain undetected.²⁰ Physical placement of epidural or subdural electrodes also carries the risk of CSF fistula formation, parenchymal damage and bleeding, which should be minimized by careful technique.

D-Wave Clinical Biomarkers, Warning Signs, and Alarm Criteria. One goal of neurosurgical intervention for IMSCTs is to eliminate or minimize the disease burden by safely resecting as much of the tumor as possible. Equally important is preservation of the patient's neurological functioning at least to the preoperative level, which, in large part, will necessitate avoiding new iatrogenic injury during surgery. The purpose of IONM is to assess the function of separable neurological subsystems such as motor and sensory processing to provide real-time feedback regarding the integrity of a given pathway along the continuum from the origin to the terminus. The combination of modalities chosen will depend on the location of surgery and which pathways will be placed at risk. Distinct modalities such as D-wave, SSEP, and tcMEP monitoring will generate characteristic waveforms reflecting steady-state neurophysiology in healthy tissue. Reproducible derangements in these waveforms from an established baseline can be used as indicators of functional compromise when they have been

sufficiently correlated with the neurological outcomes both in the short term perioperatively and for longer term recovery. This, in turn, will establish a neurophysiological biomarker that can be used as a guide to inform clinical decision-making when warning signs or alarm criteria become evident. For D-waves used to monitor CST integrity, a decrease of \geq 50% from the baseline amplitude should be considered significant and is the accepted, although arbitrary, standard.¹⁷ An amplitude reduction beyond this threshold should prompt a halt in surgery to allow for the return of the signal before continuing. The disappearance of the D-waves is highly suggestive of permanent motor impairment. If the D-wave amplitude remains $>$ 50% of baseline value, motor deficits could still occur but are more likely to be transient. Therefore, even when the tcMEP are lost or unobtainable, a durable D-wave signal greater than threshold will be sufficient to proceed with resection. Because D-waves deteriorate gradually, the surgical strategy can usually be modified before reaching the absolute alarm criterion for cessation.¹⁰ The adaptations performed because of the presence of minor warning criteria reported by Sala et al.¹⁷ included dissecting at a different area, irrigating the surgical field with warm saline, and/or correcting hypotension. If the D-wave amplitude does decrease to $<$ 50%, a wait time of 30 minutes will typically be sufficient to recover the signal and continue with the resection.⁸ However, these recommendations should not be extrapolated to supratentorial resection surgery.

Multimodality IONM for IMSCT Resection: Combined Recordings of D-Waves and MEP. Each IONM modality used alone has technical, clinical, and predictive value limitations that can be overcome using combined monitoring to eliminate gaps and provide a more accurate global perspective on the intraoperative morbidity and functional outcomes. Multimodal IONM (mIONM), combining D-wave monitoring with MEP and SSEP monitoring has been studied.^{6,8} Complementary D-wave and myogenic MEP (mMEP) recordings can inform on which intraoperative measures to

Table 2. Summary of IMSCT and IDEMSCT resection studies using D-waves

Investigator	Study Type	Total Cases (n)	IONM Modalities	Cases with D-Waves Monitored (n)	Results Summary
IMSCT resection					
Kothbauer et al., 1998	R	100	mMEP, D-wave	59	>50% Decrease in D-waves predicted loss of postoperative motor function
Sala et al., 2006	HC	100	mMEP, D-wave	50	Use of D-waves resulted in better improvement in postoperative MMS grade; >50% decrease in D-wave predicted loss of postoperative motor function
Costa et al., 2013	R	23*	mMEP, SSEP, D-wave	78	Presence of stable D-waves predicted good motor outcome despite deterioration in mMEP
Kimchi et al., 2021	R	28	tcMEP, SSEP, D-wave	28	Measures for D-waves at POD1, POW6, and final follow-up—sensitivity: 40%, 33%, 100%; specificity: 100%, 83%, 90%; NPV: 70%, 71%, 100%; PPV: 100%, 50%, 50%, respectively
Skrap et al., 2021	R	100	mMEP, SSEP, D-wave	67	MEP loss predicted short-term postoperative worsening; strongest predictors of good functional long-term outcome were MMS grade and D-wave preservation
IDEMSCT resection					
Costa et al., 2013	R	55*	mMEP, SSEP, D-wave	78	Presence of stable D-waves predicted good motor outcome despite deterioration in mMEP
Korn et al., 2014	R	100	tcMEP, SSEP, D-wave, EMG	19	mIONM at latest follow-up: sensitivity, 82%; specificity, 95%; PPV, 82%; NPV, 95%
Ghadirpour et al., 2019	R	108	mMEP, SSEP, D-wave	71	D-wave at follow-up: sensitivity, 100%; specificity, 98%; PPV, 67%; NPV, 100%
Cofano et al., 2020	R	249	mMEP, SSEP, D-wave	99	Use of D-waves resulted in better clinical outcomes at follow-up but not at discharge
<p>IMSCT, intramedullary spinal cord tumor; IDEMSCT, intradural extramedullary spinal cord tumor; IONM, intraoperative neurophysiological monitoring; D-wave, direct wave; R, retrospective; mMEP, myogenic motor-evoked potentials; HC, historical control; MMS, modified McCormick scale; SSEP, somatosensory-evoked potentials; tcMEP, transcranial motor-evoked potentials; POD, postoperative day; POW, postoperative week; NPV, negative predictive value; PPV, positive predictive value; MEP, motor-evoked potentials; mIONM, multimodal intraoperative neurophysiological monitoring; EMG, electromyography.</p> <p>*Same study, separated by tumor location.</p>					

perform after waveform deterioration and on the functional motor outcome.^{12,17}

The current general consensus has been to elicit both D-waves and mMEP, especially during IMSCT surgery, because both recordings will provide complementary data that can predict the short- and long-term motor function outcomes.^{2,17,18} Thus, deterioration and/or disappearance of mMEP during IMSCT resection suggests the potential for postoperative motor deficits. However, disappearance of the D-waves suggests irreversible damage to the CST fibers, resulting in permanent motor deficits. D-waves that remain within 50% of baseline have correlated with long-term CST preservation, even with the presence of disconcerting motor deficits in the

immediate postoperative period. Surgically induced transient paraplegia in the setting of abnormal mMEP and stable D-waves might be related to reversible inactivation of non-CST descending tracts reflected by the abnormal mMEP signal, although the fast-conducting CST fibers are preserved. The potential scenarios during mIONM for IMSCT resection using D-wave and mMEP monitoring, including suggested surgical measures to address the changes and the effects on the predicted functional motor outcomes, are summarized in **Table 1**.

D-Waves as a Guide to the Extent of Spinal Cord Tumor Resection. IMSCTs and intradural extramedullary (IDEM) tumors account for 2%–4% and 15% of central

nervous system tumors, respectively.^{8,10} Surgical resection is the most effective treatment modality, and the extent of tumor resection has been correlated with preservation of neurologic function and survival.⁸ Although the treatment goal for IDEM tumors is gross total resection (GTR),¹³ the treatment goal for IMSCTs varies by etiology. Benign ependymoma will be most effectively treated with GTR, but infiltrative astrocytoma could necessitate more conservative subtotal resection.^{12,26,27} Because of the tumor location within the spinal canal and difficulty in identifying the appropriate plane of resection, ≤44%–55% of patients will experience postoperative neurological deficits.^{1,12} Therefore, the role and effect of IONM, including

D-wave monitoring, in guiding the extent of tumor resection has been an area of focus in the spinal cord tumor field. One case series within a larger systematic review and meta-analysis reported a greater extent of resection for true-negative versus false-positive cases.⁶ In contrast, Cofano et al.¹⁰ found no association between the extent of IDEM tumor resection and the use of IONM. For IMSCT cases for which the D-waves cannot be monitored, a conservative approach should be taken to avoid neural worsening.² To the best of our knowledge, no studies have documented a negative correlation between IONM use and the extent of resection. Because of the ethical challenges of designing a randomized controlled trial to investigate the effects of IONM on spinal cord tumor surgery, many retrospective studies and a historical control study have provided evidence of the utility of D-waves for both IMSCT and IDEM tumor resection (Table 2). The intraoperative scenarios described in Table 1 can also inform the safety of continued resection versus halting surgery to balance the risk of resection-associated neurologic injury with the risk of an incomplete tumor resection.¹² Thus, monitoring the D-waves plays a key role in the surgical decision-making process and requires an ongoing dialogue between the neurophysiologist and operative team.

Correlating D-Waves with Prognostic Factors and Outcomes. A central feature of IONM is the ability to predict the functional outcomes from inside the operating room. Although this ability will vary on an individual case basis and by the IONM modality used, consistent trends identified by several large mIONM studies have provided a basic framework. Thus, although the loss of the MEP signal is the most sensitive indicator of short-term neurological deterioration, D-wave preservation and good preoperative MMS scores are the greatest predictors of long-term postoperative recovery of motor function.^{2,3,12,13,17,18} Recent studies have calculated the sensitivity, specificity, and positive and negative predictive values (PPV and NPV respectively) for D-wave IONM during IMSCT resection and IDEM tumor resection (Table 2).^{12,19} In a study of 28 patients, Kimchi et al.¹² formalized

the ability of D-waves to predict the long-term outcomes after IMSCT surgery with MMS scores measured preoperatively and at postoperative day 1, week 6 and the latest available follow-up point. They reported that although the PPV decreased with increased time postoperatively (day 1, week 6, and latest follow-up: 100%, 50%, 50%, respectively), the corresponding NPVs increased (70%, 71%, 100%). However, the D-wave modality had the highest and most consistent specificity over time (day 1, week 6, and latest follow-up: 100%, 83%, 90%, respectively), twice that of tcMEP monitoring. These findings were supported by the results for a consecutive series of 100 patients.¹³ For IDEM tumors, another series of 108 cases over 10 years had similar findings with a cumulative D-wave specificity of 98%, NPV of 100%, and PPV of 67% at a 12-month follow-up endpoint.¹⁹ No patients with D-waves that could be monitored had reported permanent deficits at 12 months postoperatively. In that study, multiple logistic regression analyses determined that age >65 years and an anterolateral tumor location (near the CST) are independent risk factors associated with significant IONM changes, potentially identifying a population that could benefit most by D-wave IONM, irrespective of sex.¹⁹

DISCUSSION

D-wave IONM, in conjunction with MEP and SSEP modalities, has seen increased usage owing to the recognized benefits in predicting the long-term motor outcomes that underscore patients' quality of life. In the present review, we have discussed the neurophysiology of D-waves in relationship to the neuroanatomy and practical considerations for IONM and the insight provided by combined monitoring with MEP and SSEP to predict the functional outcomes. We have provided an update to the current literature, highlighting the role of monitoring the D-waves in preventing irreversible intraoperative damage to the neural pathways with an emphasis on the prognostic value. The stop-and-go conversation between the neurophysiologist and neurosurgeon during tumor resection will establish a recursive checks-and-balances system to optimize patient safety and postoperative neurological

status and can simultaneously inform the extent of tumor resection necessary to achieve GTR. Thus, D-wave IONM has a valuable role in clinical decision-making and real-time risk/benefit analysis during spinal tumor surgery.

Despite the promise of the use of D-waves in IONM, the full clinical potential has been difficult to gauge because of the ethical considerations in the design of prospective randomized controlled trials for IMSCT patients. Such investigations would place the control group at unnecessary risk by the lack of IONM or the lack of communication of the IONM data with the operating neurosurgeon. As such, historical control and retrospective analyses will remain the standard.¹⁷ In addition, mIONM studies using D-waves have routinely included large sample sizes of ~100 cases to offset this limitation.

The D-wave technique also provides a useful adjunct when combined with other emerging technologies, such as D-wave CST monitoring with direct spinal cord stimulation mapping and integrated diffusion tensor imaging tractography to identify tumor–spinal cord interfaces. Barzilai et al.²⁸ combined D-wave monitoring with continuous CST mapping during IMSCT surgery using an electrified ultrasonic aspirator. D-wave IONM contributed to more refined mapping of the spinal cord and the development and usage of innovative strategies. This is likely to include intraoperative connectomics and virtual or augmented reality systems in the future.

CONCLUSIONS

The potential of D-wave monitoring both for traditional IONM for tumor resection and for the refinement of advanced approaches renders this an invaluable technique in the larger toolkit of neurosurgery and neurophysiological monitoring.

CONFLICT OF INTEREST STATEMENT

The authors declare that the article content was composed in the absence of any commercial or financial relationships that could be construed as a potential conflict of interest.

ACKNOWLEDGMENTS

The figures were created using a combination of Keynote and BioRender.

REFERENCES

- McCormick PC, Torres R, Post KD, Stein BM. Intramedullary ependymoma of the spinal cord. *J Neurosurg.* 1990;72:523-532.
- Kothbauer KF, Deletis V, Epstein FJ. Motor-evoked potential monitoring for intramedullary spinal cord tumor surgery: correlation of clinical and neurophysiological data in a series of 100 consecutive procedures. *Neurosurg Focus.* 1998;4:e1.
- Rijs K, Klimek M, Scheltens-de Boer M, Biesheuvel K, Harhangi BS. Intraoperative neuromonitoring in patients with intramedullary spinal cord tumor: a systematic review, meta-analysis, and case series. *World Neurosurg.* 2019;125:498-510.e2.
- Dauleac C, Boulogne S, Barrey CY, et al. Predictors of functional outcome after spinal cord surgery: relevance of intraoperative neurophysiological monitoring combined with preoperative neurophysiological and MRI assessments. *Neurophysiol Clin.* 2022;52:242-251.
- Ille S, Wagner A, Joerger AK, Wostrack M, Meyer B, Shiban E. Predictive value of transcranial evoked potential monitoring for intramedullary spinal cord tumors. *J Neurol Surg Part Cent Eur Neurosurg.* 2021;82:325-332.
- Kurokawa R, Kim P, Itoki K, et al. False-positive and false-negative results of motor evoked potential monitoring during surgery for intramedullary spinal cord tumors. *Oper Neurosurg (Hagerstown).* 2018;14:279-287.
- Boyd SG, Rothwell JC, Cowan JMA, et al. A method of monitoring function in corticospinal pathways during scoliosis surgery with a note on motor conduction velocities. *J Neurol Neurosurg Psychiatry.* 1986;49:251-257.
- Verla T, Fridley JS, Khan AB, Mayer RR, Ibrahim O. Neuromonitoring for intramedullary spinal cord tumor surgery. *World Neurosurg.* 2016;95:108-116.
- Deletis V, Sala F. Intraoperative neurophysiological monitoring of the spinal cord during spinal cord and spine surgery: a review focus on the corticospinal tracts. *Clin Neurophysiol.* 2008;119:248-264.
- Cofano F, Giambra C, Costa P, et al. Management of extramedullary intradural spinal cord tumors: the impact of clinical status, intraoperative neurophysiological monitoring and surgical approach on outcomes in a 12-year double-center experience. *Front Neurol.* 2020;11:598619.
- Natali AL, Reddy V, Bordoni B. *Neuroanatomy, Corticospinal Cord Tract.* Treasure Island, FL: Stat Pearls Publishing; 2021.
- Kimchi G, Knoller N, Korn A, et al. Delayed variations in the diagnostic accuracy of intraoperative neuromonitoring in the resection of intramedullary spinal cord tumors. *Neurosurg Focus.* 2021;50:E21.
- Skrap B, Tramontano V, Faccioli F, Meglio M, Pinna G, Sala F. Surgery for intramedullary spinal cord ependymomas in the neuromonitoring era: results from consecutive series of 100 patients. *J Neurosurg Spine.* 2021;10:11-11.
- Patton HD, Amassian VE. Single and multiple-unit analysis of cortical stage of pyramidal tract activation. *J Neurophysiol.* 1954;17:345-363.
- Morota N, Deletis V, Constantini S, Kofler M, Cohen H, Epstein FJ. The role of motor evoked potentials during surgery for intramedullary spinal cord tumors. *Neurosurgery.* 1997;41:1327-1336.
- Sala F, Bricolo A, Faccioli F, Lanteri P, Gerosa M. Surgery for intramedullary spinal cord tumors: the role of intraoperative (neurophysiological) monitoring. *Eur Spine J.* 2007;16(suppl 2):130-139.
- Sala F, Palandri G, Basso E, et al. Motor evoked potential monitoring improves outcomes after surgery for intramedullary spinal cord tumors: a historical control study. *Neurosurgery.* 2006;58:1129-1143.
- Costa P, Peretta P, Faccani G. Relevance of intraoperative D wave in spine and spinal cord surgery. *Eur Spine J.* 2013;22:840-848.
- Ghadirpour R, Nasi D, Iaccarino C, et al. Intraoperative neurophysiological monitoring for intradural extramedullary spinal tumors: predictive value and relevance of D-wave amplitude on surgical outcome during a 10-year experience. *J Neurosurg Spine.* 2019;30:259-267.
- Cheng JS, Ivan ME, Stapleton CJ, Quinones-Hinojosa A, Gupta N, Auguste KI. Intraoperative changes in transcranial motor evoked potentials and somatosensory evoked potentials predicting outcome in children with intramedullary spinal cord tumors. *J Neurosurg Pediatr.* 2014;13:591-599.
- Macdonald DB, Skinner S, Shils J, Yingling C. Intraoperative motor evoked potential monitoring—a position statement by the American Society of Neurophysiological Monitoring. *Clin Neurophysiol.* 2013;124:2291-2316.
- Park J-W, Hyun S-J. Intraoperative neurophysiological monitoring in spinal surgery. *World J Clin Cases.* 2015;3:765-773.
- Kothbauer KF. The interpretation of muscle motor evoked potentials for spinal cord monitoring. *J Clin Neurophysiol.* 2017;34:32-37.
- Korn A, Halevi D, Lidar Z, Biron T, Ekstein P, Constantini S. Intraoperative neurophysiological monitoring during resection of intradural extramedullary spinal cord tumors: experience with 100 cases. *Acta Neurochir.* 2015;157:819-830.
- Jin S-H, Chung CK, Kim CH, Choi YD, Kwak G, Kim BE. Multimodal intraoperative monitoring during intramedullary spinal cord tumor surgery. *Acta Neurochir.* 2015;157:2149-2155.
- Garces-Ambrossi GL, McGirt MJ, Mehta VA, et al. Factors associated with progression-free survival and long-term neurological outcome after resection of intramedullary spinal cord tumors: analysis of 101 consecutive cases. *J Neurosurg Spine.* 2009;11:591-599.
- Samartzis D, Gillis CC, Shih P, O'Toole JE, Fessler RG. Intramedullary spinal cord tumors: part II—management options and outcomes. *Glob Spine J.* 2016;6:176-185.
- Barzilai O, Lidar Z, Constantini S, Salame K, Bitan-Talmor Y, Korn A. Continuous mapping of the corticospinal tracts in intramedullary spinal cord tumor surgery using electrified ultrasonic aspirator. *J Neurosurg Spine.* 2017;27:161-168.

Received 12 June 2022; accepted 6 September 2022

Citation: *World Neurosurg.* X (2023) 17:100139.

<https://doi.org/10.1016/j.wnsx.2022.100139>

Journal homepage: www.journals.elsevier.com/world-neurosurgery-x

Available online: www.sciencedirect.com

2590-1397/© 2022 The Author(s). Published by Elsevier Inc.

This is an open access article under the CC BY-NC-ND license (<http://creativecommons.org/licenses/by-nc-nd/4.0/>).