



Since January 2020 Elsevier has created a COVID-19 resource centre with free information in English and Mandarin on the novel coronavirus COVID-19. The COVID-19 resource centre is hosted on Elsevier Connect, the company's public news and information website.

Elsevier hereby grants permission to make all its COVID-19-related research that is available on the COVID-19 resource centre - including this research content - immediately available in PubMed Central and other publicly funded repositories, such as the WHO COVID database with rights for unrestricted research re-use and analyses in any form or by any means with acknowledgement of the original source. These permissions are granted for free by Elsevier for as long as the COVID-19 resource centre remains active.

# Novel Screening and Triage Strategy in Iran During Deadly Coronavirus Disease 2019 (COVID-19) Epidemic: Value of Humanitarian Teleconsultation Service

*Amir H. Davarpanah, MD, Arash Mahdavi, MD, Ali Sabri, MD, Taraneh Faghihi Langroudi, MD, Shahram Kahkouee, MD, Sara Haseli, MD, Mohammad Ali Kazemi, MD, Payam Mehrian, MD, Ali Mahdavi, MD, Farahnaz Falahati, MD, Abuzar Moradi Tuchayi, MD, Mehرداد Bakhshayeshkaram, MD, Morteza Sanei Taheri, MD*

## THE PROBLEM

The current outbreak of coronavirus disease 2019 (COVID-19) in at least 156 countries has been classified by the World Health Organization as a global pandemic [1]. The long incubation period and low disease severity in the early stage contributed to rapid increase in case numbers. The infection ranges from mild to severe respiratory illness, potentially progressing to acute respiratory distress syndrome in 17% to 29% of patients [2]. Disease severity resulted in global public health efforts to contain person-to-person viral spread by early detection.

As of March 15, 2020, the total number of infected cases in Iran has reached 13,938, with 724 related deaths (highest numbers apart from China and Italy).

Currently, COVID-19 infection is diagnosed by real-time reverse-transcription polymerase chain reaction (rRT-PCR) analysis of nasopharyngeal swab specimens. The rapidly expanding number of cases could exceed laboratory testing capacity from potential testing kit shortages worldwide. Despite high specificity of rRT-PCR testing, the reported sensitivity is as low as 60% to

70% [3]. Therefore, effective exclusion of COVID-19 infection requires multiple negative tests, possibly exacerbating test kit shortage. Early problems with distribution and performance of test kits laboratories in the United States and around the world have already been reported.

Diagnostic issues pose challenges for health systems over quarantine decisions, such as shortage of hospital beds and medical supplies, should the number of suspected cases exceed a certain threshold. The additional impact of recent outbreaks on the global and state economies further complicates decision making on admissions, given the high projected rates of hospitalizations and deaths.

Early lung manifestations of COVID-19 infection consist of peripheral and basal predominant ground-glass opacities progressing to organizing pneumonia pattern in the later stage [2,4]. Notwithstanding that nearly 50% of patients imaged in the first 2 days after the symptom onset had normal chest CT [4], serial CT imaging is valuable in assessing progression of lung abnormalities [2,4].

Accuracy of CT diagnosis of COVID-19 infection depends on

radiological expertise because of the complex morphological patterns of lung involvement that can change in extent and appearance over time. The limited number of subspecialty-trained thoracic radiologists hampers reliable interpretation of complex chest examinations in Iran and other developing countries, where general radiologists and occasionally clinicians interpret chest imaging. Furthermore, to reduce exposure in health care settings during an epidemic, health services limit referrals to subspecialty medical centers.

The availability of radiology imaging equipment is an important part of high-quality patient care, particularly in developing countries. Iran, as a middle-income country with a population of nearly 80 million, had 6.5 CT scanners per million people at the end of 2016 [5], distributed in the centers of 31 provinces. On the other hand, access to diagnostic imaging equipment such as CT is relatively universal for patients in the United States, which has 42.6 CT scanners per million people [6]. Despite this, adequacy of CT interpretations is quite variable, potentially depriving a growing

number of people from appropriate screening during COVID-19 outbreak.

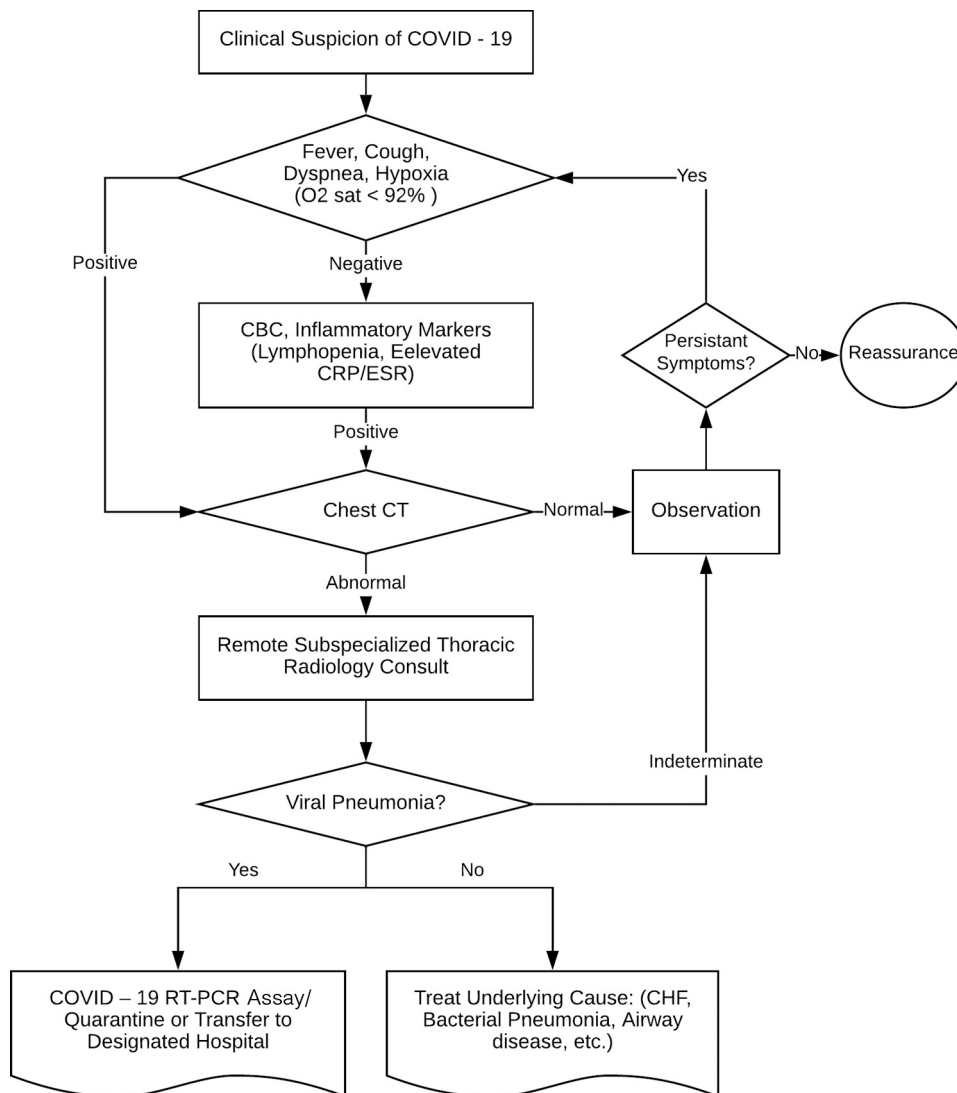
Teleradiology services eliminate the need to send patients to overpopulated hospitals and provide near real-time consultation from experts located around the country and the world to meet the local need. An increasing number of health care professionals have adopted social media for education and information exchange in various clinical settings. WhatsApp Messenger (WhatsApp Inc. Mountain View, CA) is a widely used messaging software application with nearly 2.0 billion users

worldwide. We strategically implemented social media to connect volunteer subspecialists in North America and the Iranian capital with undertrained clinicians throughout Iran for teleradiology consultation. We describe the use of these teleradiology services delivered through a social media platform to provide diagnostic expertise for COVID-19 in Iran.

## WHAT WE DID

In response to shortage of on-site thoracic radiologists, on February 18,

2020, the Iranian Society of Radiology (ISR), a nongovernmental, nonprofit organization representing more than 3,000 radiologists, assembled a second-opinion teleradiology group, the Iranian Society of Radiology COVID-19 Consultants (ISRCC), by inviting volunteer radiologists [7] on their WhatsApp open group. The 11 ISRCC volunteer participating radiologists (9 in Iran, 1 in Canada, and 1 in the United States) all received subspecialty fellowship training and have 4 to 24 years of experience in thoracic imaging.



**Fig 1.** Flowchart for triage of 2019 novel coronavirus disease in suspected cases in Iran. COVID-19 = coronavirus disease 2019; CBC = complete blood count; CHF = congestive heart failure; CRP = C-reactive protein; ESR = erythrocyte sedimentation rate; RT-PCR, reverse-transcription polymerase chain reaction.

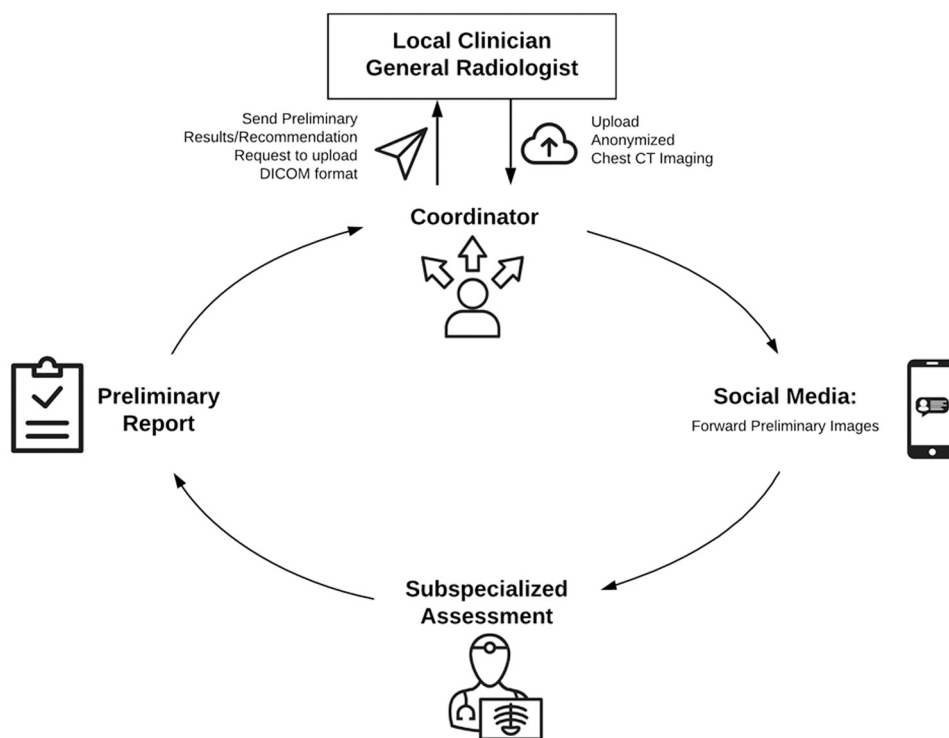


Fig 2. Schematic of the workflow process for remote consultations using social media and DICOM viewer.

Based on recent published literature of present outbreak in Wuhan, China, and short supply of test kits in Iran, the following triage strategy was established [2,4,8] (Fig. 1). Patients with early clinical and laboratory findings suspicious for COVID-19 infection should undergo chest CT interpreted by a local general radiologist. CT scans of patients with abnormalities are referred to a teleradiology group as described later. An additional patient triaging algorithm depending on the results of the CT scan with or without rRT-PCR testing is described in Figure 1.

Using the public website and messaging service of ISR, physicians and general radiologists across Iran were encouraged to submit abnormal chest CT examinations for second opinions. The teleconsultation system required referrers to submit anonymized CT images to the volunteer

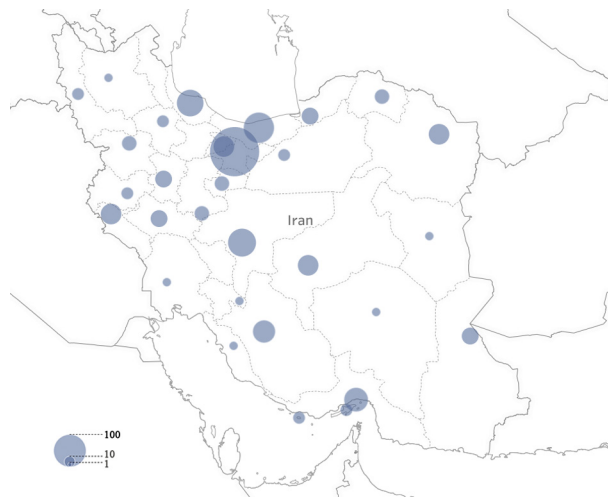
network coordinator (a physician assigned by ISR) using social media messaging software, WhatsApp (Fig. 2). Once a study (image files in JPEG format or cine clips in MP4 format) was submitted, the coordinator assigned a case number and posted images to the ISRCC private WhatsApp group. Then, one of the available volunteers generated a report using a standard format as a comment on the post [7]. Access to the private group was strictly limited to the coordinator and volunteer radiologists, who were instructed to access information on their password-protected devices to ensure the confidentiality of information. Disagreements on specific cases were resolved by consensus agreement through radiologists' discussions in the same post. Participation of expert radiologists in different time zones allowed efficient time coverage for

reviewing submitted images. The coordinator forwarded the final report to the referrer via WhatsApp or e-mail.

Both lung and mediastinal windows were submitted to facilitate interpretation of JPEG or MP4 files. DICOM images were forwarded via e-mail in cases with suboptimal image quality. Additional clinical information included the patient's age, chief complaint, vital signs, physical examination, laboratory results, and the course of care.

## OUTCOMES AND LIMITATIONS

Between February 18, 2020, and March 8, 2020, CT examinations from 1,138 patients (mean age, 53 years; range, 18 to 86 years; 664 men, 474 women) were uploaded to the social media platform from more than 65 cities (28 of 31 provinces; Fig. 3). Nearly 43% (489 of 1,138) had



**Fig 3.** Distribution of number of remote consults across Iranian provinces between February 18, 2020, and March 8, 2020. Circle size corresponds to number of cases.

imaging patterns suggestive of viral pneumonia and were referred for further rRT-PCR testing or isolation. Another 41% (467 of 1,138) had imaging patterns inconsistent with viral pneumonia and were referred for management of underlying alternative diagnoses. Approximately 16% (182 of 1,138) were categorized as indeterminate and referred for observation or CT follow-up. DICOM images were reviewed in approximately 19% of cases (216 of 1,138). The final reports were generated within 2 hours after initial posting in 100% of the cases.

Our study has limitations. We realize that using a broader definition of infection to include all positive cases on chest CT will result in a higher number of false-positive cases. We acknowledge the potential overlap of CT imaging features between COVID-19 infection and other viral pneumonia. Nonetheless, our priority was to identify the majority of suspicious cases on chest CT and use rRT-PCR testing in a more selective fashion to minimize resource drain. It is imperative that CT findings should

be interpreted in the context of positive exposure history and clinical symptoms, especially in epidemic areas with high pretest probability for disease. Although we were able to meet the current need using 11 volunteers, the increased demand for thoracic radiology expertise might exceed the capacity of traditional or even social media-delivered teleradiology services as the volunteers' home countries experience an influx of diagnostic cases and are themselves subject to infection. Despite the advantages of use of social media, we are aware of disadvantages in health care settings with respect to data security and privacy protection, and usage requires meticulous and adequate training of clinicians, radiologists, and staff.

Despite these limitations, our humanitarian teleconsultation strategy allows for reliable triage of COVID-19 infection using radiology experts from centers around the world to provide consultation in regions with limited access to thoracic radiology expertise during a rapidly growing epidemic. This highlights the important role of

radiologists during a global health crisis.

## ACKNOWLEDGMENTS

We are grateful to many frontline medical staff in Iran for their dedication in the face of this outbreak, despite the potential threat to their own lives and the lives of their families. We thank members of Iranian Society of Radiology for their support and efforts to provide consult to the remote parts of Iran.

## REFERENCES

1. World Health Organization. WHO Director-General's opening remarks at the media briefing on COVID-19—11 March 2020. Available at: <https://www.who.int/dg/speeches/detail/who-director-general-s-opening-remarks-at-the-media-briefing-on-covid-19—11-march-2020>. Published 2020. Accessed March 17, 2020.
2. Kanne JP, Little BP, Chung JH, Elicker BM, Ketai LH. Essentials for radiologists on COVID-19: an update-Radiology Scientific Expert Panel. *Radiology* 2020:200527.
3. Ai T, Yang Z, Hou H, et al. Correlation of chest CT and RT-PCR testing in coronavirus disease 2019 (COVID-19) in China: a report of 1014 cases. *Radiology* 2020:200642.
4. Bernheim A, Mei X, Huang M, et al. Chest CT findings in coronavirus disease-19 (COVID-19): relationship to duration of infection. *Radiology* 2020:200463.

5. Abedini Z, Sari AA, Foroushani AR, Jaafariipooyan E. Diffusion of advanced medical imaging technology, CT, and MRI scanners, in Iran: a qualitative study of determinants. *Int J Health Plann Manage* 2019;34:e397-410.
6. Ginde AA, Foianini A, Renner DM, Valley M, Camargo CA Jr. Availability and quality of computed tomography and magnetic resonance imaging equipment in U.S. emergency departments. *Acad Emerg Med* 2008;15:780-3.
7. Mahdavi A, Khalili N, Davarpanah AH, et al. Radiologic management of COVID-19: preliminary experience of the Iranian Society of Radiology COVID-19 Consultant Group (ISRCC). *Iran J Radiol* 2020:e102324. In press.
8. Zhang J, Zhou L, Yang Y, Peng W, Wang W, Chen X. Therapeutic and triage strategies for 2019 novel coronavirus disease in fever clinics. *Lancet Respir Med* 2020;8(3):e11-2.

---

Amir H. Davarpanah, MD, and Abuzar Moradi Tuchayi, MD, are from the Department of Radiology, Emory University School of Medicine, Emory University Hospital, Atlanta, Georgia. Arash Mahdavi, MD, and Taraneh Faghihi Langroudi, MD, are from the Department of Radiology, Shahid Beheshti University of Medical Sciences, Shahid Modarres Hospital, Tehran, Iran. Ali Sabri, MD, is from the Department of Radiology, McMaster University, Ontario, Canada. Shahram Kahkouee, MD, Sara Haseli, MD, Payam Mehrian, MD, and Mehrdad Bakhshayeshkaram, MD, are from the Department of Radiology, Shahid Beheshti University of Medical Science, Chronic Respiratory Diseases Research Center, National Research Institute of Tuberculosis and Lung Diseases (NRITLD), Masih Daneshvari Hospital, Tehran, Iran. Mohammad Ali Kazemi, MD, is from the Department of Radiology, Tehran University of Medical Sciences, Amiralam & Imam Hospitals, Tehran, Iran. Ali Mahdavi, MD, is from the Department of Radiology, Shahid Beheshti University of Medical Sciences, Imam Hossein Hospital, Tehran, Iran. Farahnaz Falahati, MD, is from the Iranian Society of Radiology, Tehran, Iran. Morteza Sanei Taheri, M, is from the Department of Radiology, Shahid Beheshti University of Medical Sciences, Shohada-e-Tajrish Hospital, Tehran, Iran.

The authors participated in this humanitarian program on a voluntary basis and state that they have no conflict of interest or involvement in any organization or entity with any financial interest.

Amir H. Davarpanah, MD: Emory University School of Medicine, 1364 Clifton Rd NE, Atlanta, GA 30322; e-mail: [amir.davarpanah@emory.edu](mailto:amir.davarpanah@emory.edu) or Morteza Sanei Taheri, MD: Shahid Beheshti University of Medical Sciences, Shohada-e-Tajrish Hospital, Tehran, Iran; e-mail: [Saneim@gmail.com](mailto:Saneim@gmail.com).