

## Case Report

# Mesenchymal Stem Cell Therapy Overcomes Steroid Resistance in Severe Gastrointestinal Acute Graft-Versus-Host Disease

Kyoko Moritani,<sup>1</sup> Reiji Miyawaki,<sup>1</sup> Kiriko Tokuda,<sup>2</sup>  
Fumihiko Ochi,<sup>1</sup> Minenori Eguchi-Ishimae,<sup>1</sup> Hisamichi Tauchi,<sup>1</sup>  
Mariko Eguchi,<sup>1</sup> Eiichi Ishii,<sup>1</sup> and Kozo Nagai<sup>1</sup>

<sup>1</sup>Department of Pediatrics, Ehime University Graduate School of Medicine, Ehime, Japan

<sup>2</sup>Department of Pediatrics, Ehime Prefectural Central Hospital, Ehime, Japan

Correspondence should be addressed to Kozo Nagai; [kouzou@m.ehime-u.ac.jp](mailto:kouzou@m.ehime-u.ac.jp)

Received 24 March 2019; Accepted 14 May 2019; Published 21 May 2019

Academic Editor: Janez Jazbec

Copyright © 2019 Kyoko Moritani et al. This is an open access article distributed under the Creative Commons Attribution License, which permits unrestricted use, distribution, and reproduction in any medium, provided the original work is properly cited.

The authors describe the high effectiveness of human mesenchymal stem cell (hMSC) therapy to treat steroid-refractory gastrointestinal acute graft-versus-host Disease (aGVHD) in a 15-year-old boy with acute lymphoblastic leukemia (ALL). He received allogeneic hematopoietic stem cell transplantation due to high-risk hypodiploid ALL. Around the time of engraftment, he developed severe diarrhea following high-grade fever and erythema. Although methylprednisolone pulse therapy was added to tacrolimus and mycophenolate mofetil, diarrhea progressed up to 5000~6000 ml/day and brought about hypocalcemia, hypoalbuminemia, and edema. Daily fresh frozen plasma (FFP), albumin, and calcium replacements were required to maintain blood circulation. After aGVHD was confirmed by colonoscopic biopsy, MSC therapy was administered. The patient received 8 biweekly intravenous infusions of  $2 \times 10^6$  hMSCs/kg for 4 weeks, after which additional 4 weekly infusions were performed. A few weeks after initiation, diarrhea gradually resolved, and at the eighth dose of hMSC, lab data improved without replacements. MSC therapy successfully treated steroid-refractory gastrointestinal GVHD without complications. Despite life-threatening diarrhea, the regeneration potential of children and adolescents undergoing SMC therapy successfully supports restoration of gastrointestinal damage. Even with its high treatment costs, SMC therapy should be proactively considered in cases where young patients suffer from severe gastrointestinal GVHD.

## 1. Introduction

Allogeneic hematopoietic stem cell transplant (Allo-HSCT) improves outcomes of high-risk hematological malignancy and severe non-malignant hematological diseases [1, 2]. Despite donor human leucocyte antigen (HLA) typing method and optimization of donor selection, HLA-mismatched transplantations are unavoidable due to a shortage of donors. Even though posttransplantation supportive care has improved, acute graft-versus-host disease (aGVHD) remains a leading cause of both transplantation-related mortality (TRM) and morbidity following allogeneic HSCT. Steroids, often added to methotrexate and calcineurin inhibitors, are employed as the first-line treatment for aGVHD; however, in 30–50% of patients, aGVHD is not controlled with first-line steroid therapy [3]. Steroid-refractory GVHD outcomes

are dismal, so further therapeutic intervention inhibitors are required. Second-line agents, including antithymocyte globulin (ATG), mycophenolate mofetil (MMF), and infliximab, provide limited improvement owing to a higher risk of infectious complications, immunosuppression-related toxicity, and incomplete GVHD remission [4–6].

Bone marrow contains pluripotent mesenchymal stem cells (MSCs) that form bone, cartilage, adipose tissue, and muscle. These stem cells are not immunogenic and escape recognition by allo-reactive T cells and natural killer cells. Mesenchymal stem cells given intravenously have been well tolerated [7]. Preliminary reports of co-transplantation of MSCs and HSCs from HLA-identical siblings show a reduction in acute and chronic GVHD [8]. In 2004, Le Blanc and coworkers first demonstrated that haploidentical MSC infusion dramatically improved severe steroid-refractory

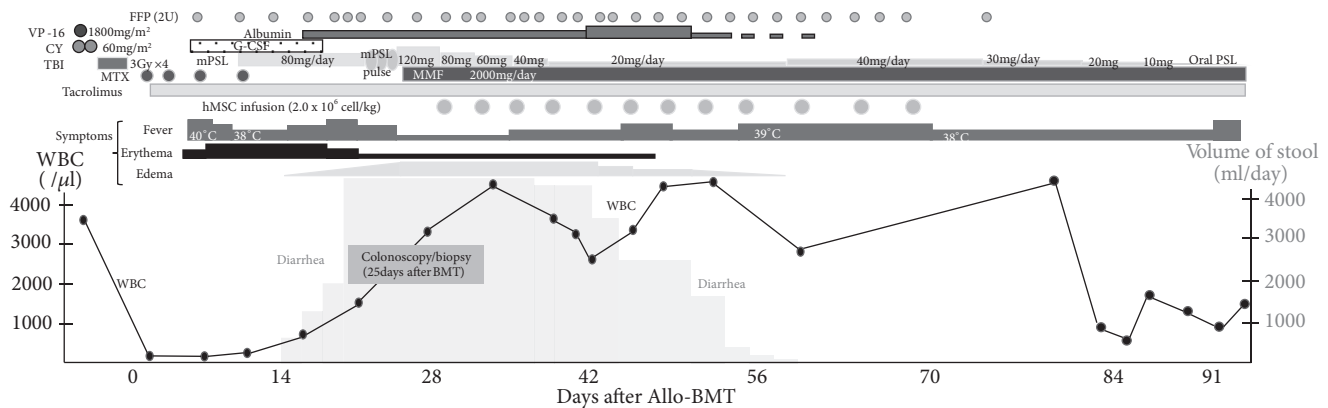


FIGURE 1: *Clinical course of patient.* VP-16: etoposide; CY: cyclophosphamide; TBI: total body irradiation; MTX: methotrexate; G-CSF: granulocyte colony stimulating factor; mPSL: methylprednisolone; PSL: prednisolone; MMF: mycophenolate mofetil.

aGVHD in a pediatric patient with acute lymphoblastic leukemia (ALL) [9]. A further phase II study of MSC therapy for severe steroid-refractory GVHD was conducted by same Le Blanc team. Among 55 patients, including Grade III ~ IV at 90%, 30 patients had a complete response and 9 showed improvement. Complete responders had lower transplantation-related mortality and a higher survival rate than did patients with partial or no response [10]. Following that, smaller and larger studies investigating the effect of MSCs in steroid-refractory GVHD were conducted, and its safety and effectiveness have been shown [11–13]. Nowadays, in many countries, hMSC infusion is approved as a second-line therapy for steroid-refractory GVHD.

The gastrointestinal tract is highly affected by preconditioning treatments. In the earliest pathophysiological events of GVHD, neoangiogenesis [14] and infiltration of innate neutrophil granulocytes and monocytes are caused [15, 16]. Recipient neutrophils induce epithelial cells damage and increased intestinal permeability through their activation and production of reactive oxygen species in gastrointestinal tract [15]. Bacteria, fungi, and viruses infiltrate to submucosa and activate antigen presenting cells (APCs) through toll-like receptor (TLR) and nucleotide-binding oligomerization domain-like receptor (NOD-R). Damaged tissue and activated APCs induce various immune cell alloreactions, especially donor T cells, resulting in GVHD [17]. Lower gastrointestinal tract GVHD is the predominant cause of morbidity and mortality from allo-HSCT. This complication has poor outcomes, with 25% overall survival [18].

In this report, we describe a case of MSC therapy improving life-threatening diarrhea caused by gastrointestinal GVHD refractory to continuous steroid and pulse therapy. This case report suggests MSC therapy to be highly effective for child and adolescent patients with severe steroid-refractory gastrointestinal GVHD.

## 2. Case Report

A 14-year-old boy was referred to a previous hospital with intermittent fever and joint pain. Laboratory findings revealed inflammatory change (C-reactive protein [CRP],

12.91mg/dL; ferritin, 246 ng/mL; soluble IL-2 receptor [sIL2R], 1389U/mL), normal white blood cell (WBC) count, 6880/ $\mu$ L, with 2% lymphoblasts, moderate thrombocytopenia (platelet [PLT] was  $6.4 \times 10^4/\mu$ L), normal transaminase levels, high lactate dehydrogenase (LDH), 1315U/L, and slightly abnormal blood coagulation test. Bone marrow aspiration showed that 56.2% of nucleated cells were lymphoblasts with immature nuclei, high N/C ratio, and positive staining for PAS. Flow cytometry revealed positivities for CD19, CD20, CD22, c-CD79, CD38, CD99 and HLA-DR, and a weak positivity for CD10. Although gene rearrangement, which frequently occurs in ALL, was not detected, low-hypodiploid with 36 or 37 chromosomes was detected in a chromosome test. Based on these findings, the diagnosis of B-lymphoblastic lymphoma (BLL) with hypodiploid was made. The patient was judged to have high-risk ALL and was scheduled to receive multidrug chemotherapy followed by high-dose chemotherapy with allo-HSCT.

Multidrug chemotherapy according to the JPLSG ALL-B12 protocol, which is BFM-based, consisting of steroid, Vincristine, anthracyclines, and L-asparaginase [19], was administered to the patient. After induction chemotherapy, he attained a complete clinical remission on day 33 after initiation. During intensification courses, minimal residual disease-polymerase chain reaction (MRD-PCR) targeting immunoglobulin heavy chain (IgH) in bone marrow was not detected. The patient was transferred to our hospital and underwent allogeneic bone marrow transplantation (BMT) with a conditioning regimen including 12 Gy total body irradiation, etoposide, and cyclophosphamide. A donor mismatched for two HLA antigens, -C and -DR, was selected due to a small number of candidates. Tacrolimus and short-term methotrexate (MTX), 15mg/m<sup>2</sup> on day 1 and 10mg/m<sup>2</sup> on days 3, 6, and 11, were administered as basic GVHD prophylaxes. The clinical course summary after HSCT is shown in Figure 1. Seven days after transplantation, engraft syndrome induced high-grade fever and progressive systemic erythema (Stage 3). G-CSF, 5μg/kg/day of Lenograstim was administered from day 5 but was stopped on day 17 to prevent immune reaction overload. Erythema and fever showed no improvement, and CRP rose to 20.2mg/dL at peak value.

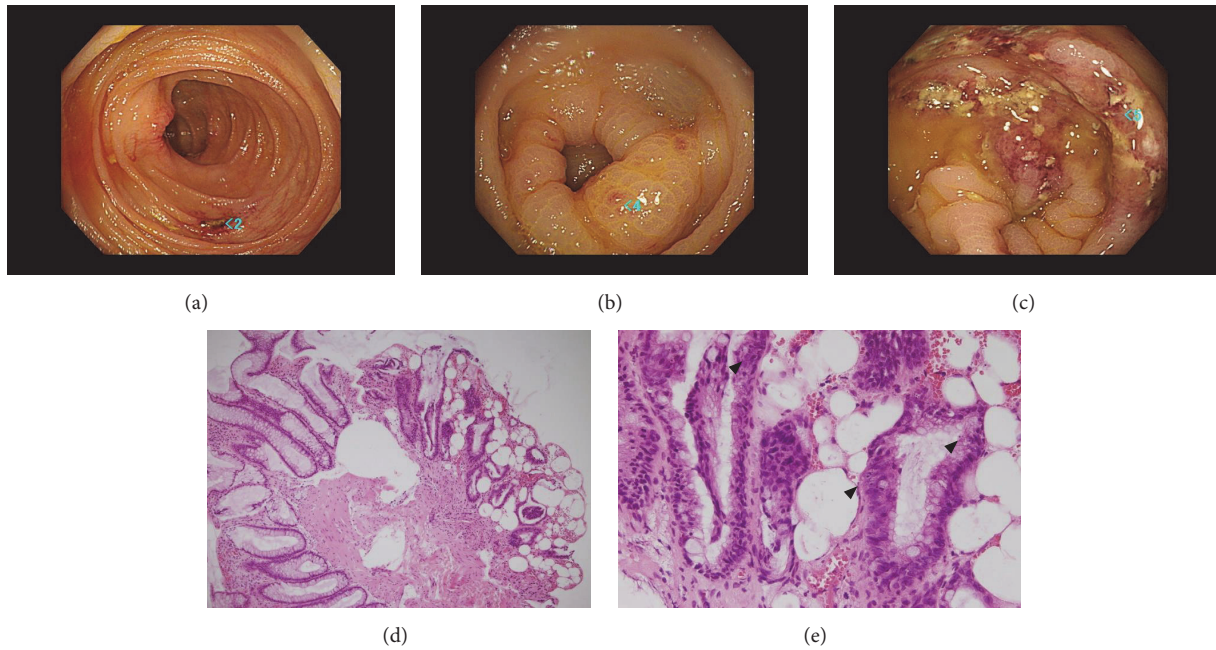


FIGURE 2: Colonoscopy image at ascending colon (a), at sigmoid colon (b), and at rectum (c). H-E staining  $\times 100$  of biopsy specimen (d). Apoptotic bodies (arrows) at  $\times 400$  (e). Edematous surface and scattered erosion were observed at whole colon and rectum. (a~c) Desquamated epithelium, interstitial edema, and submucosal fibrosis were seen as a result of inflammation. (d) Enlarged image showed submucosal lymphocyte infiltration and apoptotic bodies. There were no inclusion body cells (e).

Therefore, 1.33mg/kg/day (80mg) of methylprednisolone was added to tacrolimus and administered to the patient from day 7, improving the immune reactive symptoms. However, watery diarrhea appeared and gradually increased up to 5000~6000ml/day. Engraftment of neutrophil cells (neutrophil count  $\geq 500/\mu\text{L}$  for 3 days) was observed 14 days after transplant. Cytomegalovirus (CMV) DNA in blood was consistently negative. A methylprednisolone pulse from day 18 to 20 was followed by the administration of 2mg/kg of mPSL and MMF with dietary restrictions on day 21, but the watery diarrhea did not improve. Severe hypoalbuminemia (1.6~2.0 g/dL) progressed due to intestinal tract leaking, and replacement of FFP and albumin on consecutive days was unavoidable in order to maintain blood circulation. Severe hypocalcemia was observed, and an intensive supplement of calcium preparation was also required. Colonoscopy showed edematous surface and scattered erosion from ascending colon to rectum, colonoscopic biopsy revealed desquamated epithelium, interstitial edema, disordered structure of ducts, and submucosal fibrosis. Apoptosis with nuclear dust was observed occasionally in epithelium as a feature of gastrointestinal GVHD. There were no cells with inclusion body formation (Figure 2). After acute gastrointestinal GVHD was confirmed, MSC therapy at a dose of  $2 \times 10^6$  hMSCs/kg twice per week was added to daily methyl prednisolone treatment on day 28. To avoid steroid-related side effects, mPSL was gradually tapered: 80mg from day 26 to 29, 60mg from day 30 to 33, 40mg from day 34 to 37, and 20mg from day 38. At the fifth dose of hMSC, the volume of diarrhea decreased to around 1500ml/day, and eventually to 200ml/day, with

stool form at the eighth dose. An additional 4 doses were administered weekly following the twice-per-week induction dose, and MSC therapy was finished after a total of 12 doses. Albumin and calcium concentrations were easily maintained without replacement. Dietary restrictions were gradually removed, and methyl prednisolone was successfully tapered without relapse of intestinal symptoms. At day 60, the mPSL dose was increased to 40mg per day due to fever caused by GVHD. The fever had a good response to steroids and was transient, allowing for a smooth tapering of mPSL to 5mg of oral prednisolone. A chromosome test of bone marrow (BM) cells on day 88 revealed the complete replacement of the BM cells by female type (donor type, 46,XX). At 130 days after transplant, the patient was discharged. Although the patient requires a low dose of steroid for the treatment of appetite loss and gastrointestinal discomfort, he is in stable condition and has been without disease relapse at one year after transplant.

### 3. Discussion

In this report, the patient suffered from engraft syndrome followed by lower gastrointestinal aGVHD. The diagnosis of causes leading to posttransplant diarrhea is a complex process. The differential diagnosis with infection including CMV, adenovirus, rotavirus, norovirus, and *Clostridium difficile*, is a critical point before conducting immunosuppression treatment for gastrointestinal GVHD [20]. The possibility of intestinal tract infection was excluded by analyzing stool specimen and culture, determining the presence of CMV DNA in serum, observation and biopsy under colonoscopy.

Although the patient had steroid-refractory progression and life-threatening diarrhea, MSC therapy overcame steroid-refractory lower intestinal GVHD.

In a multicenter study of hMSC therapy for 55 cases with steroid-refractory GVHD (30 adult cases and 25 child cases), the overall response rate (RR) was 70.9%. Child cases had a better RR to MSC therapy (84.0%) compared to adult cases (70.9%) [10]. The effectiveness of hMSC therapy for aGVHD, including gastrointestinal GVHD, has been demonstrated in a phase II study. Twenty-five cases with steroid-refractory GVHD (grade III: 22 cases, grade IV: 3 cases) were enrolled. Results showed that at 24 weeks after initiation of MSC therapy, 12 cases (48%) remained in CR of GVHD for 28 days. The survival was significantly better in patients showing overall response (OR; CR+PR) than in those showing no OR at 4 weeks [21]. In multicenter Phase III study, Prochymal® (n = 163) or placebo (n = 61) were added to standard care in 244 patients with steroid-refractory GVHD (skin involvement n = 144, gastrointestinal involvement n = 179, liver involvement n = 61). Prochymal provided better response rate vs placebo at day 100 to liver (76% vs 47%) and gut (82% vs 68%) compared to skin involvement (78% vs 77%) [22]. Ball LM et al conducted a clinical study of hMSC therapy in a cohort of 37 children with steroid-refractory grade III-IV aGVHD. CR was observed in 24 children (65%) and PR in 8 children. Among 22 children with gastrointestinal GVHD, effective response was observed with CR in 19 children, and resolution of gastrointestinal symptoms occurred at a median time of 11 days [23]. Another study of hMSC treatment for gastrointestinal GVHD in pediatric patients demonstrated favorable results. Although all 12 patients had grade III-IV gastrointestinal GVHD even after multiple immunosuppression therapies, complete resolution of gastrointestinal symptoms occurred in 9 (75%) patients. Clinical responses, particularly in the gastrointestinal system, were seen in the majority of children with severe refractory aGVHD [24].

Tissue injury following high-dose chemotherapy and total body irradiation used in preparation for HCT triggers GVHD. Tissue damage, affecting primarily the gastrointestinal tract, generates a robust inflammatory response with release of cytokines that facilitate antigen recognition by allo-reactive donor T cells [17]. Human and animal models demonstrated that MSCs migrate specifically to damaged tissue sites exhibiting inflammation, although most become trapped in the microvasculature of the lung [25, 26]. T helper (Th) 1/Th2 balance has been identified as significant in GVHD [27]. MSCs interact with T cells and induce a Th1 to Th2 shift. Th1 cells reduce interferon- $\gamma$ , and Th2 cells increase secretion of interleukin (IL)-4 induced through the interaction with human MSCs [28]. Th17 cells, CD4 T cells producing proinflammatory cytokine, have been recognized as playing a pivotal role in aGVHD. MSCs prevent Th cells from differentiation into Th17 subset through PGE2 production [29]. MSCs are shown to have the ability to repair damaged tissue and differentiate into the cells of that tissue [30]. A clinical trial was conducted to repair damaged tissue associated with HSCT or aGVHD using hMSCs [31].

Once atrophy and desquamation in colon epithelium are caused by inflammation of GVHD, restoration of gut epithelium following immunomodulation takes several weeks. Therefore, the patient had persistent diarrhea and increased stool frequency up to 21 days after initiation of MSCs. Prompt analyzing of stool and serum plus endoscopy for excluding infectious disease are required to conduct MSC therapy in adequate timing.

While hMSC therapy for severe steroid-refractory GVHD is approved for coverage by the national health insurance system in Japan, the therapy itself is quite expensive, and physicians should take care when selecting cases to receive MSC therapy. In our experience, MSC therapy should be strongly considered for administration in pediatric patients with severe gastrointestinal GVHD, even after steroid pulse therapy.

In conclusion, we had an excellent outcome when treating a steroid-refractory gastrointestinal GVHD patient using hMSC therapy. Even though the patient had life-threatening watery diarrhea, steroids were successfully tapered without a recurrence of symptoms. The immunomodulation and regeneration induced by MSC therapy might be more effective for the pediatric population because of their rapid tissue restoration. When encountering a pediatric patient with severe gastrointestinal GVHD resistant to steroid pulse therapy, MSC therapy administration should be given active consideration following stool-serum test and endoscopy to exclude the possibility of infection.

## Consent

Informed consent was obtained from the patient and his parents.

## Conflicts of Interest

The authors declare that there are no conflicts of interest regarding the publication of this paper.

## References

- [1] E. D. Thomas, C. D. Buckner, M. Banaji et al., "One hundred patients with acute leukemia treated by chemotherapy, total body irradiation, and allogeneic marrow transplantation," *Blood*, vol. 49, pp. 511–533, 1977.
- [2] J. R. Passweg, H. Baldomero, P. Bader et al., "Hematopoietic SCT in Europe 2013: recent trends in the use of alternative donors showing more haploidentical donors but fewer cord blood transplants," *Bone Marrow Transplantation*, vol. 50, no. 4, pp. 476–482, 2015.
- [3] H. J. Deeg, "How I treat refractory acute GVHD," *Blood*, vol. 109, no. 10, pp. 4119–4126, 2007.
- [4] M. T. van Lint, C. Uderzo, A. Locasciulli et al., "Early treatment of acute graft-versus-host disease with high- or low- dose 6-methylprednisolone: a multicenter randomized trial from the Italian group for bone marrow transplantation," *Blood*, vol. 92, no. 7, pp. 2288–2293, 1998.
- [5] L. Cragg, B. R. Blazar, T. Defor et al., "A randomized trial comparing prednisone with antithymocyte globulin/prednisone as

- an initial systemic therapy for moderately severe acute graft-versus-host disease,” *Biology of Blood and Marrow Transplantation*, vol. 6, no. 4, pp. 441–447, 2000.
- [6] F. Patriarca, A. Sperotto, D. Damiani et al., “Infliximab treatment for steroid-refractory acute graft-versus-host disease,” *Haematologica*, vol. 89, no. 11, pp. 1352–1359, 2004.
  - [7] O. N. Koç, S. L. Gerson, B. W. Cooper et al., “Rapid hematopoietic recovery after coinfusion of autologous-blood stem cells and culture-expanded marrow mesenchymal stem cells in advanced breast cancer patients receiving high-dose chemotherapy,” *Journal of Clinical Oncology*, vol. 18, no. 2, pp. 307–316, 2000.
  - [8] F. Frassoni, M. Labopin, A. Bacigalupo et al., “Expanded mesenchymal stem cells (MSC), co-infused with HLA identical hematopoietic stem cell transplants, reduce acute and chronic graft-versus-host disease: a matched pair analysis,” *Bone Marrow Transplantation*, vol. 29, supplement 2, 2002.
  - [9] K. Le Blanc, I. Rasmusson, B. Sundberg et al., “Treatment of severe acute graft-versus-host disease with third party haploidentical mesenchymal stem cells,” *The Lancet*, vol. 363, no. 9419, pp. 1439–1441, 2004.
  - [10] K. Le Blanc, F. Frassoni, L. Ball et al., “Mesenchymal stem cells for treatment of steroid-resistant, severe, acute graft-versus-host disease: a phase II study,” *The Lancet*, vol. 371, no. 9624, pp. 1579–1586, 2008.
  - [11] M. Cetin, G. Akyol, Z. B. Gonen et al., “Additional infusions of mesenchymal stem cells improve response rate in multidrug-resistant GvHD patients,” *Bone Marrow Transplantation*, vol. 52, no. 5, pp. 783–785, 2017.
  - [12] K. Zhao, R. Lou, F. Huang et al., “Immunomodulation effects of mesenchymal stromal cells on acute graft-versus-host disease after hematopoietic stem cell transplantation,” *Biology of Blood and Marrow Transplantation*, vol. 21, no. 1, pp. 97–104, 2015.
  - [13] G. M. Dotoli, G. C. De Santis, M. D. Orellana et al., “Mesenchymal stromal cell infusion to treat steroid-refractory acute GvHD III/IV after hematopoietic stem cell transplantation,” *Bone Marrow Transplantation*, vol. 52, no. 6, pp. 859–862, 2017.
  - [14] O. Penack, E. Henke, D. Suh et al., “Inhibition of neovascularization to simultaneously ameliorate graft-vs-host disease and decrease tumor growth,” *JNCI: Journal of the National Cancer Institute*, vol. 102, no. 12, pp. 894–908, 2010.
  - [15] L. Schwab, L. Goroncy, S. Palaniyandi et al., “Neutrophil granulocytes recruited upon translocation of intestinal bacteria enhance graft-versus-host disease via tissue damage,” *Nature Medicine*, vol. 20, pp. 648–654, 2014.
  - [16] K. Reinhardt, D. Foell, T. Vogl et al., “Monocyte-induced development of th17 cells and the release of s100 proteins are involved in the pathogenesis of graft-versus-host disease,” *The Journal of Immunology*, vol. 193, no. 7, pp. 3355–3365, 2014.
  - [17] G. R. Hill and J. L. M. Ferrara, “The primacy of the gastrointestinal tract as a target organ of acute graft-versus-host disease: rationale for the use of cytokine shields in allogeneic bone marrow transplantation,” *Blood*, vol. 95, no. 9, pp. 2754–2759, 2000.
  - [18] C. Castilla-Llorente, P. J. Martin, G. B. McDonald et al., “Prognostic factors and outcomes of severe gastrointestinal GVHD after allogeneic hematopoietic cell transplantation,” *Bone Marrow Transplantation*, vol. 49, no. 7, pp. 966–971, 2014.
  - [19] A. Möricke, M. Zimmermann, A. Reiter et al., “Long-term results of five consecutive trials in childhood acute lymphoblastic leukemia performed by the ALL-BFM study group from 1981 to 2000,” *Leukemia*, vol. 24, no. 2, pp. 265–284, 2010.
  - [20] K. Robak, J. Zambonelli, J. Bilinski, and G. W. Basak, “Diarrhea after allogeneic stem cell transplantation: Beyond graft-versus-host disease,” *European Journal of Gastroenterology & Hepatology*, vol. 29, no. 5, pp. 495–502, 2017.
  - [21] K. Muroi, K. Miyamura, M. Okada et al., “Bone marrow-derived mesenchymal stem cells (JR-031) for steroid-refractory grade III or IV acute graft-versus-host disease: a phase II/III study,” *International Journal of Hematology*, vol. 103, no. 2, pp. 243–250, 2016.
  - [22] P. Martin, J. Uberti, R. Soiffer et al., “Prochymal improves response rates in patients with steroid-refractory acute graft versus host disease (SR-GVHD) involving the liver and gut: results of a randomized, placebo-controlled, multicenter phase III trial in GVHD,” *Biology of Blood and Marrow Transplantation*, vol. 16, no. 2, pp. S169–S170, 2010.
  - [23] L. M. Ball, M. E. Bernardo, H. Roelofs et al., “Multiple infusions of mesenchymal stromal cells induce sustained remission in children with steroid-refractory, grade III-IV acute graft-versus-host disease,” *British Journal of Haematology*, vol. 163, no. 4, pp. 501–509, 2013.
  - [24] V. K. Prasad, K. G. Lucas, G. I. Kleiner et al., “Efficacy and safety of ex vivo cultured adult human mesenchymal stem cells (Prochymal) in pediatric patients with severe refractory acute graft-versus-host disease in a compassionate use study,” *Biology of Blood and Marrow Transplantation*, vol. 17, no. 4, pp. 534–541, 2011.
  - [25] E. Horwitz, P. L. Gordon, W. K. Koo et al., “Isolated allogeneic bone marrow-derived mesenchymal cells engraft and stimulate growth in children with osteogenesis imperfecta: implications for cell therapy of bone,” *Proceedings of the National Academy of Sciences of the United States of America*, vol. 99, pp. 8932–8937, 2002.
  - [26] A. Mahmood, D. Lu, M. Lu et al., “Treatment of traumatic brain injury in adult rats with intravenous administration of human bone marrow stromal cells,” *Neurosurgery*, vol. 53, no. 3, pp. 697–703, 2003.
  - [27] D. H. Fowler, K. Kurasawa, R. Smith, M. A. Eckhaus, and R. E. Gress, “Donor CD4-enriched cells of Th2 cytokine phenotype regulate graft-versus-host disease without impairing allogeneic engraftment in sublethally irradiated mice,” *Blood*, vol. 84, no. 10, pp. 3540–3549, 1994.
  - [28] S. Aggarwal and M. F. Pittenger, “Human mesenchymal stem cells modulate allogeneic immune cell responses,” *Blood*, vol. 105, no. 4, pp. 1815–1822, 2005.
  - [29] R. Tatara, K. Ozaki, Y. Kikuchi et al., “Mesenchymal stromal cells inhibit Th17 but not regulatory T-cell differentiation,” *Cytotherapy*, vol. 13, no. 6, pp. 686–694, 2011.
  - [30] O. Ringdén, M. Uzunel, I. Rasmusson et al., “Mesenchymal stem cells for treatment of therapy-resistant graft-versus-host disease,” *Transplantation*, vol. 81, no. 10, pp. 1390–1397, 2006.
  - [31] O. Ringdén, M. Uzunel, B. Sundberg et al., “Tissue repair using allogeneic mesenchymal stem cells for hemorrhagic cystitis, pneumomediastinum and perforated colon,” *Leukemia*, vol. 21, no. 11, pp. 2271–2276, 2007.