

Infected urachal cyst in a young adult

Natalia Muško, Jakub Dobruch, Sebastian Piotrowicz, Przemysław Szostek, Andrzej Borówka

Postgraduate Medical Education Center at The European Health Centre in Otwock, Otwock, Poland

Article history

Submitted: Nov. 25, 2013

Accepted: March 4, 2014

Correspondence

Natalia Muško

Department of Urology

European Health Centre Otwock

14/18, Borowa Street

05-400 Otwock, Poland

phone: +48 694 312 931

nmusko@gazeta.pl

The urachus is the remnant of the cloaca, which in adults attaches the bladder dome to the umbilicus. After birth it obliterates and presents as the midline umbilical ligament. Patent urachal anomalies are usually detected in childhood. In adults they occur very rarely and the presentation and diagnosis may be occasionally challenging. We present and discuss the case of an infected urachal cyst found in a 30-year-old adult.

Key Words: urachus ◊ abdominal pain ◊ antibiotics ◊ laparotomy

CASE REPORT

A 30-year-old man presented to the outpatient clinic with abdominal pain and a purulent, cheesy discharge from the umbilicus which lasted for a few days. He was afebrile. The physical examination revealed periumbilical tenderness, erythema and discharge from the umbilicus. There were no signs of general infection. The laboratory tests were all within the normal limits. The ultrasound scan suggested the presence of an abscess within the abdominal anterior wall. A CT scan (Figure 1) confirmed the presence of an infected cyst in the midline of the abdominal wall, with no communication with the bladder. The patient was given antibiotics and prepared for surgery. During laparotomy, a urachal cyst with the cuff of the bladder dome were removed (Figure 2). Recovery was unremarkable. The patient was discharged four days after surgery. Pathology revealed benign urachal cells with no signs of malignancy.

DISCUSSION

The urachus is a fibrous remnant of the cloaca that in adults connects the dome of the bladder with ante-

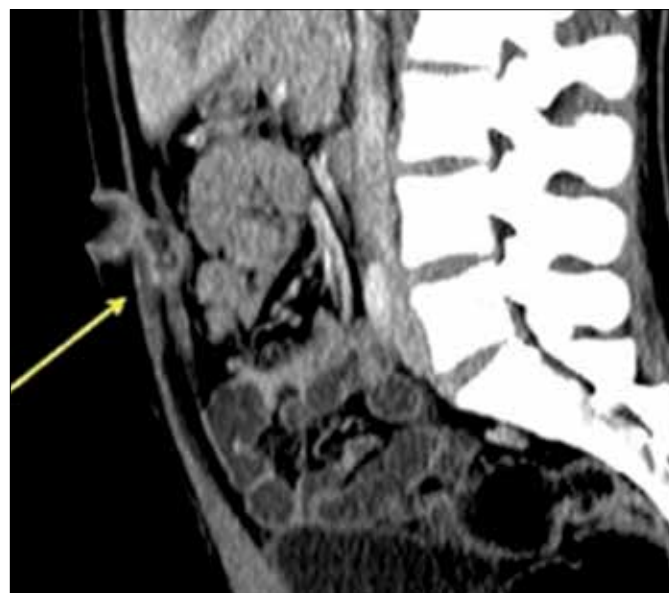


Figure 1. The midline cyst shown at CT.

rior abdominal wall. The cloaca, in the fetal life, is an extension of the urogenital sinus and allantois, and is derived from the yolk sac. After birth it obliter-

ates, forming the median umbilical ligament. Otherwise, it may present variably: a urachal cyst, a part of the urachal canal without any patent connection with the bladder or the umbilicus, a patent urachus communicating the bladder with the umbilicus, a urachal sinus which is a form of a cyst communicating with the umbilicus or a urachal diverticulum, a structure which opens within the bladder.

Those remnants found in neonates younger than 6 months usually resolve spontaneously without the need for surgery [1]. Those found in older patients require management because of a greater risk for infection, and of utmost importance in adults, due to an increased risk of neoplastic differentiation. The most commonly observed and managed urachal anomalies in children are: urachal cyst (54%), urachal sinus (30%), patent urachus or vesicourachal diverticulum [2].

Urachal anomalies are more commonly found in males and are rarely observed in adulthood. Modes of presentation differ from those seen in children. Urachal cancer (51%) and urachal cyst (35%), which is usually infected, are the most frequent modalities diagnosed in adults [2]. Some patients with urachal remnants are asymptomatic, but still carry a high risk for infection or cancer.

Typical clinical manifestations of patent urachal pathologies, as seen in our case, are umbilical discharge, tenderness, erythema or a mass within the umbilicus. Abdominal pain can be the only symptom of disease, and can mimic an acute abdomen due to appendicitis or Meckel's diverticulum [3]. The differential diagnosis of an umbilical mass should include hematoma, abscess, umbilical hernia, urachal carcinoma and tumors of the abdominal wall. Ultrasound can be helpful, but not sufficient, as shown by our case. CT is the most important in the diagnostic work-up. It reveals the type of urachal anomaly with a sufficient degree of accuracy. However, differentiation between the benign urachal remnant and urachal cancer may be difficult due to unclear contrast enhancement during CT, even though the presence of calcifications is suggestive of malignancy [4]. Sixty seven percent of adults who presented with a urachal mass at the time of diagnosis had, cancer [5]. Among them, 57% had calcifications seen on imaging [4, 6]. Ashley et al. found that patients older than 55, who experienced an episode of hematuria, were at greatest risk of having urachal malignancy, most commonly an adenocarcinoma [7].

In our case, there was no suspicion for malignancy due to the patients' ages, negative history suggestive of malignancy (hematuria) and CT scans. Therefore, cystoscopy was not performed. When urachal cancer cannot be excluded (hematuria and mass seen at the bladder dome on imaging) cystoscopy with biopsy

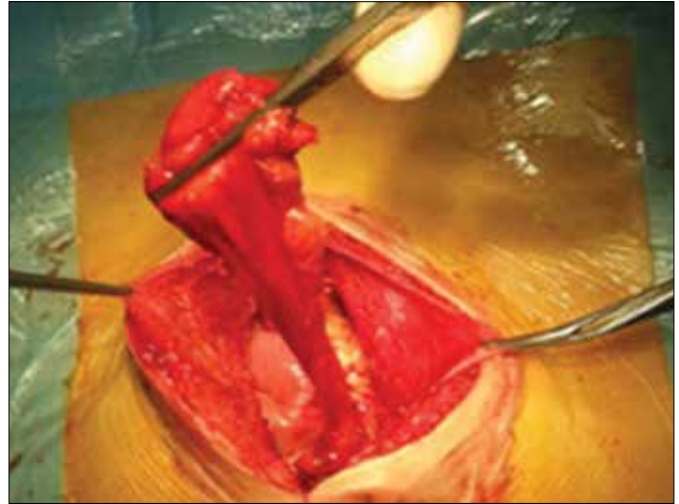


Figure 2. *Urachal cyst with the bladder cuff during abdominal surgery.*

and urine cytology should not be omitted. Cytology is positive in 38% of patients with urachal carcinoma and is correlated with an increased tumor grade.

If urachal pathology appears with signs of infection, a two-stage treatment is recommended [8]: initially, administration of antibiotics and resolution of inflammation, followed by surgical removal. In benign urachal anomalies, complete excision, with or without the cuff of the bladder, is sufficient. It is not necessary to remove the umbilicus. In case of urachal cancer, partial or radical cystectomy should be considered. Partial cystectomy with en bloc resection of the urachus with cancer within the bladder dome provides similar oncologic outcomes to radical cystectomy [9]. Open partial cystectomy is performed with a midline incision below the umbilicus. The umbilicus with urachus and bladder dome are resected with large margins (2 cm) of healthy tissue. Reports on laparoscopic partial cystectomy with urachus removal have been published [10]. It has been emphasized that the ports should be inserted 3–5 cm above and 2 cm to the left of the umbilicus to allow proper access to the operating field. The approach should be dictated by the surgeon's preferences and experience to ensure the best possible oncologic results.

CONCLUSIONS

Urachal pathology in adulthood is rare. Often its presentation is nonspecific, and as such, may cause many diagnostic problems. The patient's history and physical examination are crucial for the correct diagnosis. Although nowadays many methods are available for diagnosing pathology of urachal remnants, none of these is completely accurate.

References

1. Galati V, Donovan B, Ramji F, Campbell J, Kropp BP, Frimberger D. Management of urachal remnants in early childhood. *J Urol*. 2008; suppl 4: 1824–1826.
2. Ashley RA, Inman BA, Routh JC, Rohlinger AL, Husmann DA, Kramer SA. Urachal anomalies: a longitudinal study of urachal remnants in children and adults. *J Urol*. 2007; 178: 1615–1618.
3. Qureshi K, Maskell D, McMillan C, Wijewardena C. An infected urachal cyst presenting as an acute abdomen – A case report. *Int J Surg Case Rep*. 2013; 4: 633–635.
4. Nimmonrat A, Na-Chiang Mai W, Muttarak M. Urachal abnormalities: clinical and imaging features. *Singapore Med J*. 2008; 49: 930–935.
5. Tian J, Ma JH, Li CL, Xiao ZD. Urachal mass in adults: clinical analysis of 33 cases. *Zhonghua Yi Xue Za Zhi*. 2008; 88: 820–822.
6. Thali-Schwab CM, Woodward PJ, Wagner BJ. Computed tomographic appearance of urachal adenocarcinomas: review of 25 cases. *Eur Radiol*. 2005; 15: 79–84.
7. Ashley RA, Inman BA, Sebo TJ, Leibovich BC, Blute ML, Kwon ED, Zincke H. Urachal carcinoma: clinicopathologic features and long-term outcomes of an aggressive malignancy. *Cancer*. 2006; 107: 712–720.
8. Yoo KH, Lee SJ, Chang SG. Treatment of infected urachal cysts. *Yonsei Med J*. 2006; 47: 423–427.
9. Henly DR, Farrow GM, Zincke H. Urachal cancer: role of conservative surgery. *Urology*. 1993; 42: 635–639.
10. Colombo Jr JR, Desai M, Canes D, Frota R, Haber GP, Moinzadeh A, et al. Laparoscopic partial cystectomy for urachal and bladder cancer. *Clinics (Sao Paulo)*. 2008; 63: 731–734. ■