

Maxillary overdentures supported by four or six implants in the anterior region: 5-year results from a randomized controlled trial

Wim Slot¹, Gerry M. Raghoebar², Marco S. Cune¹, Arjan Vissink² and Henny J.A. Meijer^{1,2}

¹Department of Fixed and Removable Prosthodontics and Biomaterials, Dental School, University Medical Center Groningen, University of Groningen, Groningen, The Netherlands; ²Department of Oral and Maxillofacial Surgery, University Medical Center Groningen, University of Groningen, Groningen, The Netherlands

Slot W, Raghoebar GM, Cune MS, Vissink A, Meijer HJA. Maxillary overdentures supported by four or six implants in the anterior region: 5-year results from a randomized controlled trial. *J Clin Periodontol* 2016; 43: 1180–1187. doi: 10.1111/jcpe.12625.

Abstract

Objective: To compare a four- and six-implant maxillary overdenture after an observation period of 5 years.

Material and methods: Fifty subjects with functional problems concerning their maxillary denture, who had ample bone volume in the anterior region to place four or six implants, were included and randomly assigned to either group. Implant and overdenture survival, clinical performance, marginal bone loss and patient satisfaction were assessed.

Results: Forty-six patients completed the 5-year follow-up. One implant failed in the six implants group (99.2% survival) and none in the four implants group (100% survival). No overdentures had to be replaced during the observation period and the number of complications was limited. Clinical function was good, with no difference in clinical parameters between the groups. Mean marginal bone resorption was 0.50 ± 0.37 and 0.52 ± 0.43 mm in the four and six implant group respectively.

Conclusion: In patients with functional complaints of their maxillary denture, bar-supported overdentures on four implants in the anterior maxillary region were not inferior to overdentures supported by six implants after 5 years of function. Implant survival and patient satisfaction were high, clinical parameters favourable, bone loss and complications to the denture were minor in both groups (Clinical trial registration number: NTR2969).

Key words: dental implants; edentulous; healthy ageing; maxilla; overdenture

Accepted for publication 12 September 2016

Edentulous patients often experience problems with their complete dentures. The increase in comfort for patients wearing an implant-supported overdenture *versus* a conventional denture was striking,

especially for those who suffer from lack of stability and retention (Boven et al. 2015). Successful overdenture treatment was not only reported for the mandible (Ver-cruyssen et al. 2010), but also for the maxilla (Sanna et al. 2009, Raghoebar et al. 2014). Quality and volume of remaining bone, and the

Conflict of interest and source of funding statement

The authors have stated explicitly that there are no conflicts of interest in connection with this article.

Funding for the 1-year study was obtained by an unrestricted grant from Astra Tech AB, Mölndal, Sweden.

number and position of implants were factors which influenced success of implants and prosthesis in the upper jaw (Esposito et al. 1998). In a systematic review of maxillary overdentures, Slot et al. (2010) reported a 1-year survival rate of 98.2% in case of six implants with bar anchorage and 96.3% in case of four implants. These numbers were more or less confirmed by a more recent systematic review by Raghoebar et al. (2014). Both authors stated that longer follow-up periods are lacking; thus, not allowing for firm conclusions on how to best treat a patient with an implant-retained maxillary overdenture.

Since results of six bar-connected and four bar-connected implants seems comparable, and with favourable 1-year results, the question arises as to whether this premise will hold after a longer evaluation period and whether six implants are needed to support an implant-retained maxillary overdenture. Yet, there are no randomized controlled trials of ≥ 5 years in which the treatment outcome of four-implant maxillary overdentures are compared with six-implant maxillary overdentures. Prospective case series studies with a ≥ 5 years follow-up are limited to Jemt et al. (1996), Watson et al. (1997), Bergendal & Engquist (1998), Ferrigno et al. (2002), Mangano et al. (2011) and Eerdekens et al. (2015). Implant survival in these studies varied from 72.4% to 97.4%. Besides the lack of randomized controlled studies reporting on the treatment outcome of maxillary implant-retained overdentures, there are also no treatment guidelines in what position the implants preferably have to be placed. However, when sufficient bone in the anterior region in combination with enough space in the overdenture is available to cover an attachment system, there is an advantage of placing implants in the anterior region. When placing implants in this region, extensive bone augmentation procedures (maxillary sinus floor elevation surgery with bone harvested intra-orally or harvested from the iliac crest, sometimes in combination with bone substitutes) could be prevented, meaning less treatment time, less morbidity and less treatment costs (Kalk et al. 1996). Only Mangano et al. (2011)

and Eerdekens et al. (2015) mentioned that their studies were done in patients not needing extensive bone augmentation procedures.

There is a need for comparative studies on four *versus* six implants in the anterior region of the maxilla with a longer follow-up period. Therefore, the purpose of this 5-year randomized controlled trial was to assess the treatment outcome (implant survival, overdenture survival, peri-implant health, radiographic bone height changes, patients' satisfaction and biological/technical complications) of maxillary overdentures supported by four or six dental implants in the maxillary anterior region.

Material and Methods

Patient selection

Between January 2006 and December 2009, a total of 50 consecutive patients fulfilling the inclusion criteria were included in a randomized controlled trial (Fig. 1). Fully edentulous patients, referred to the Department of Oral and Maxillofacial Surgery (University Medical Center Groningen, the Netherlands), suffering from lack of retention and stability of the upper denture and lower denture, were considered for inclusion if they fulfilled the following criteria:

- At least 18 years of age;
- Capable of understanding and giving informed consent;
- At least 1 year edentulous in the maxilla and mandible;
- Bone dimensions in the region between the bicuspid in the anterior area of the maxilla had to be at least 12 mm in height and at least 5 mm in width to reach initial stability of the implant;
- Sufficient inter-occlusal space for a bar-supported attachment system in this region.

Excluded were patients with American Society of Anesthesiologists score (ASA score) \geq III (Smeets et al. 1998), who were smoking, with a history of radiotherapy in the head and neck region or a history of pre-prosthetic surgery or previous implant placement.

The patients were informed about the study on overdenture treatment

with insertion of four or six dental implants in the maxilla and about the extra efforts associated with the study (questionnaires, evaluation visits) before they signed an informed consent. The study was approved by the Medical Ethical Committee of the University Medical Center Groningen (ABR NL32503.042.11).

Rotational panoramic radiographs, lateral cephalograms and postero-anterior oblique radiographs were taken to assess the volume of the maxillary alveolar bone, the dimensions of the maxillary sinus and the antero-posterior relationship of the maxilla to the mandible. The radiographs were also screened for sinus pathology. In addition, to assess the bone volume of the maxillary process, a ridge-mapping procedure was performed as described by Ten Bruggenkate et al. (1994). In all cases, a diagnostic setup of the planned overdenture was made to obtain insight into the available dimensions for the bar-supported attachment system and overdenture.

The treatment and evaluation procedures have been described in detail with the reporting of 1-year results of the study by Slot et al. (2013). A short version of procedures is presented below.

Treatment procedure

Surgical procedures

Four or six dental implants with a length of at least 11 mm and a diameter of 4 mm were inserted in the maxillary anterior region (OsseoSpeed™ 4.0 S dental implants, Astra Tech AB, Mölndal, Sweden). The implants were placed at crestal bone level in predefined positions (positions 15, 13, 11, 21, 23, 25 in the six implants group and positions 13, 11, 21, 23 in the four implants group) with the help of a surgical template following a submerged healing protocol. In some cases, the most distal implant position may be 16 or 26 (in the six implants group), but it is always without a large sinus floor elevation. Small dehiscences or fenestrations were covered with bone harvested from the maxillary tuberosity and organic bovine bone (Bio-Oss®; Geistlich Pharma AG, Wolhusen, Switzerland) and subsequently covered with a resorbable membrane (Bio-Gide®; Geistlich

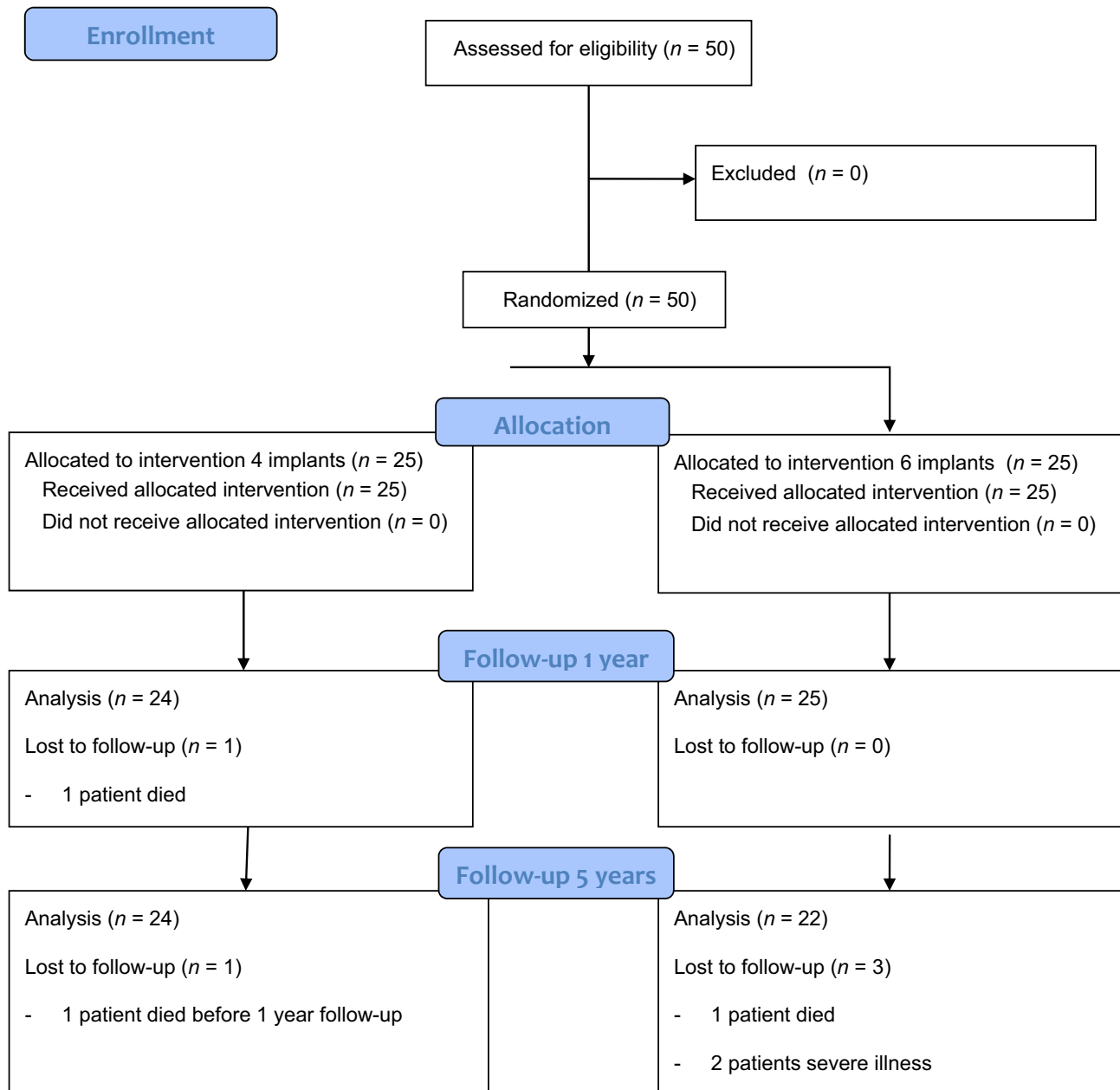


Fig. 1. Flow diagram of the study.

Pharma AG, Wolhusen, Switzerland). If the most distally placed implants (usually in the six implants group) were partially placed in the anterior part of the maxillary sinus, a small sinus floor elevation surgery was performed in that region to prevent a perforation of the sinus membrane by the implant. After a 3-month osseointegration period, second-stage surgery was performed and healing abutments (Uni Healing Abutments, Astra Tech AB) were placed.

Prosthetic procedure

After the second-stage surgery, prosthetic procedures were initiated. Healing abutments were replaced by 20° Uni Abutments (Astra Tech AB) and with impression copings and polyether material (Impregum F; 3M ESPE, St. Paul, Minn), a complete arch impression was made. A composite resin record base (Lightplast base plates; Dreve Dentamid GmbH, Unna, Germany) with a wax occlusion rim was used to

determine the occlusal vertical dimension and to record the maxillo-mandibular relationship. Acrylic resin artificial teeth (Ivoclar SR Orthotyp DCL and Ivoclar Vivodent PE, Ivoclar Vivadent AG, Schaan, Liechtenstein) were selected and arranged on the record base for a trial arrangement. A bilateral balanced occlusion concept was followed. The final superstructure consisted of a milled titanium egg-shaped bar with distal extensions, screw-retained to abutments, and an

overdenture with built-in cobalt chromium reinforcement structure and gold retentive clips attached to it (Slot et al. 2012). The design of the overdentures was with full coverage of the alveolar process, but with limited palatal coverage. The patient was instructed in hygiene procedures associated with the dentures and the bars (Fig. 2).

Outcome measures

Primary outcome measures were marginal bone-level alterations. Secondary outcome measures were implant survival, overdenture survival and soft tissue conditions (plaque index, presence of calculus, gingiva index, sulcus bleeding index and pocket probing depth). These parameters were scored at placement of the overdenture, and 1 year and 5 years after loading. Patients' satisfaction was also scored before treatment, and 1 year and 5 years after loading. Thereafter, the patients were followed up for routine check-up visits at 2, 3 and 4 years. Soft tissues and the superstructure were evaluated. If plaque and/or calculus were present at an evaluation period, cleaning was performed with additional hygiene reinstructions. No radiographs were taken at these time points.

Marginal bone-level alterations

Standardized intra-oral radiographs were taken according to a long-cone paralleling technique with an individualized X-ray holder as described by Meijndert et al. (2004). The digital images were analysed using computer software (Biomedical Engineering, University Medical Center Groningen, the Netherlands) to perform linear measurements on digital

radiographs. The known implant length was used as a reference to transform the linear measurements into mm. Reference line for bone level evaluation was the outer border of the neck of the implant.

Implant survival

Implant survival was defined as the percentage of implants initially placed that was still present and not mobile at follow-up. Failing implants were scored any time after placement. Potential mobility of individual implants was assessed after removing the bar.

Overdenture survival

Survival of maxillary overdentures was defined as the percentage of overdentures initially placed that was still present at follow-up. Remake or adjustment of the maxillary overdenture was scored any time after placement.

Clinical parameters

For presence of plaque, the index according to Mombelli et al. (1987) was used. The presence of calculus (score 1) or the absence of calculus (score 0) was scored. To qualify the degree of peri-implant inflammation, the modified Löe and Silness index (1963) was used. For bleeding, the bleeding index according to Mombelli et al. (1987) was used. Probing depth was measured at four sites of each implant (mesial, labial, distal and lingual) using a manual periodontal probe (Williams Colour-Coded Probe; Hu-Friedy, Chicago, IL, USA).

Peri-implant mucositis and peri-implantitis was calculated at patient level. As definition for peri-implant mucositis and peri-implantitis, the consensus reached at the VI and VII

European Workshop on Periodontology (Lindhe & Meyle 2008, Lang & Berglundh 2011) and reconfirmed at the VIII European Workshop on Periodontology (Sanz & Chapple 2012) has been used, being:

- Peri-implant mucositis (radiographic bone loss < 2 mm): BoP+ and/or suppuration and
- Peri-implantitis: BoP+ and/or suppuration in combination with marginal bone loss ≥ 2 mm.

Patients' satisfaction

Patients' satisfaction with their overdenture was assessed using a validated questionnaire (Vervoorn et al. 1988). This questionnaire focused on complaints and consisted of 54 items and was divided into six scales:

- Nine items concerning functional problems of the upper denture;
- Eighteen items concerning functional complaints in general;
- Three items concerning facial aesthetics;
- Three items concerning accidental lip, cheek and tongue biting ("neutral space");
- Twelve items concerning aesthetics of the denture.

The extent of each specific complaint could be expressed on a four-point rating scale (0 = no complaints, 1 = little, 2 = moderate, 3 = severe complaints).

All patients were requested to fill out a "Chewing ability" questionnaire (Stellingsma et al. 2005). In this questionnaire, patients gave their opinion about the ability to chew nine different kinds of food on a three-point rating scale (0 = good, 1 = moderate, 2 = bad). The items were grouped into three scales, being soft food, tough food and hard food. Next to these questionnaires, the patients' overall denture satisfaction was expressed on a 10-point rating scale (1 = very bad to 10 = excellent).

Statistical analysis

Study analysis was performed according to a non-inferiority design. It was assumed that an implant-supported overdenture on four implants was not inferior to an overdenture supported by six implants. Sample size calculation of the study and

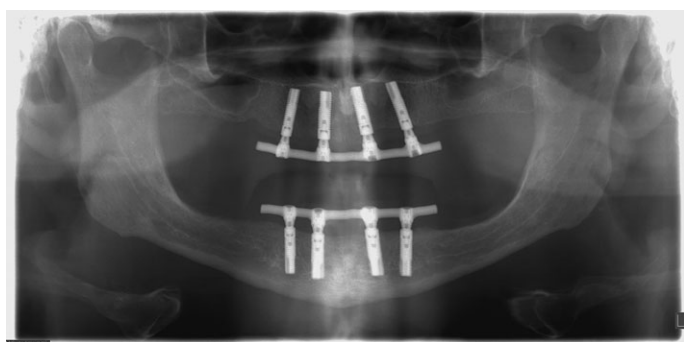


Fig. 2. Five-year panoramic radiograph of a patient with four implants connected with a bar in the maxillary anterior region.

allocation to the groups is described in the study of Slot et al. (2013). A difference of at least 0.4 mm in bone height (measured on standardized radiographs, with a standard deviation of 0.5 mm) between the four implants group and six implants group after 12 months was expected to differentiate between the two groups, based on the findings of a study on maxillary implant-supported overdentures (Raghoobar et al. 2003). A *t*-test given $\alpha = 0.05$ with a power 80% combined with the expected effect size for two independent means gives a sample size of 21 persons in each group. To deal with withdrawal of individuals in the study, the number of participants was determined to be 25 persons per group. Data collection and analysis of the radiographs were done by the same observer. For clinical and radiographical parameters, the implant has been taken as statistical unit (with multiple scores per implant, the worst score was taken). For calculation of percentage of peri-mucositis and peri-implantitis, the patient has been taken as statistical unit (worst implant per patient). And patient satisfaction has been calculated per patient. Data were analysed using the Statistical Package for Social sciences (version 22.0; SPSS Inc., IBM Corporation, Chicago, IL, USA). In all tests, a significance level of 0.05 was chosen. To see whether the data were normally distributed, the frequency distribution was plotted in a histogram. To test whether the result from the frequency analyses differed significantly from a normal distribution, Kolmogorov–Smirnov and Shapiro–Wilk test were performed. Data were normally distributed. The potential effects of imbalances between the study groups on the outcomes of this study were analysed by regression analysis. As no such effects were observed, differences between study groups were tested with an independent Student's *t*-test and between evaluation periods were tested with a paired Student's *t*-test.

Results

Baseline characteristics of the study groups are listed in Table 1. Two patients died during the follow-up period (one patient in the four

Table 1. Baseline characteristics (at placement of overdenture) of the groups with four implants (four implants group) and six implants (six implants group)

Group	Four implants group (<i>n</i> = 25)	Six implants group (<i>n</i> = 25)
Mean age in years (SD, range)	59.7 (8.0, 46–80)	57.4 (8.7, 39–71)
Gender (number male/female)	15/10	8/17
Mean edentulous period upper jaw in years (SD, range)	12.6 (11.7, 1–40)	15.8 (14.4, 1–45)
Number of maxillary dentures (SD, range)	2.5 (1.6, 1–8)	2.7 (1.7, 1–8)
Age present maxillary denture (SD, range)	3.4 (2.5, 1–10)	3.7 (3.0, 1–10)
Implant dehiscence or fenestration (patients/implants)	14/32	13/33
Sinus floor elevation surgery (patients/sinuses)	0/0	9/18
Mean plaque index (SD)	0.1 (0.3)	0.2 (0.5)
Mean calculus index (SD)	0.0 (0.0)	0.0 (0.0)
Mean gingival index (SD)	0.0 (0.0)	0.1 (0.3)
Mean bleeding index (SD)	0.3 (0.5)	0.2 (0.4)
Mean probing depth in mm (SD)	4.3 (1.0)	3.4* (0.9)

Differences between study groups were tested with the independent Student's *t*-test ($p < 0.05$).

*Significance between groups.

implants group before the 1-year evaluation and one patient in the six implants group between the 1-year and 5-year evaluation). Two patients of the six implants group did not attend the 5-year evaluation because of severe illness. The other 46 patients completed the 5-year evaluation. No implants failed in the four implants group, while one implant in the six implants group was lost during the osseointegration period. Because a bar-supported overdenture could still be made on the remaining five implants, there was no need to replace the implant. Five-years' survival rate of implants was 100% in the four implants group, 99.2% in the six implants group. Five-years' survival rate of overdentures was 100% in both groups.

The mean loss of marginal bone between baseline (placement of the overdenture) and the 5-year evaluation was 0.50 ± 0.37 mm in the four implants group and 0.52 ± 0.43 mm in the six implants group ($p > 0.05$, Table 2). Mean scores of the indices for plaque, calculus, gingiva and bleeding were very low at all evaluation periods and did not differ between the groups. Also no time-dependent significant changes in probing depth were observed between the groups ($p > 0.05$, Table 3). Patient-level incidence of peri-implant mucositis was 41.7% and 45.5%, and of peri-implantitis

was 8.3% and 4.5% in the four and six implants groups respectively.

Mean scores of the questionnaires are listed in Table 4. In both groups, all scores had improved significantly ($p < 0.05$) between pre-treatment and post-treatment assessments, but the scores did not differ between the groups ($p > 0.05$). After 5 years, patients continued to be very satisfied with their overdentures; the results are rather similar to the 1-year data.

The surgical and prosthetic after-care during 5 years of follow-up revealed a small number of events, mostly repair of the denture base or teeth. No new bars or new overdentures had to be made. Surgical treatment of peri-implantitis was not performed during the 5-year follow-up (Table 5). At the 5-year follow-up evaluation, a number of patients were identified as having peri-implant mucositis (treatment: cleaning and reinstruction) or peri-implantitis (treatment: cleaning, reinstruction and open-flap surgical treatment).

Discussion

This study revealed that both four and six dental implants placed in the anterior region of the edentulous maxilla, connected with a bar, form a proper base for the support of an overdenture. In none of the parameters studied, significant differences

Table 2. Mean values and standard deviations of marginal bone loss in mm, and frequency distribution of bone loss 1 and 5 years after placement of the overdenture of the four and six implants groups. Mean marginal bone loss did not differ significantly between the groups

	1 year		5 years	
	Four implants group (n = 96)	Six implants group (n = 149)	Four implants group (n = 96)	Six implants group (n = 131)
Mean (SD)	0.24 mm (0.32)	0.25 mm (0.29)	0.50 mm (0.37)	0.52 mm (0.43)
0–0.5 mm	86%	83%	64%	60%
>0.5–1.0 mm	11%	14%	21%	19%
>1.0–1.5 mm	2%	3%	12%	12%
>1.5–2.0 mm	1%	0%	1%	7%
>2.0 mm	0%	0%	2%	2%

Differences between study groups were tested with the independent Student's *t*-test ($p < 0.05$).

Table 3. Mean change from baseline to 1 and 5 years of follow-up for plaque index, calculus index, gingival index, bleeding index and probing depth. No time-dependent significant changes were observed between the groups

	Mean change from baseline to 1 year		Mean change from baseline to 5 years	
	Four implants group (n = 24)	Six implants group (n = 25)	Four implants group (n = 24)	Six implants group (n = 22)
Plaque index (SD) Score 0–3	0.2 (0.5)	0.1 (0.4)	0.5 (0.9)	0.4 (0.9)
Calculus index (SD) Score 0–1	0.0 (0.0)	0.0 (0.0)	0.1 (0.3)	0.1 (0.5)
Gingival index (SD) Score 0–3	0.2 (0.4)	0.2 (0.5)	0.4 (0.6)	0.2 (0.4)
Bleeding index (SD) Score 0–3	0.1 (0.6)	0.2 (0.5)	0.3 (0.7)	0.5 (0.8)
Probing depth in mm (SD)	0.3 (0.8)	0.2 (0.6)	–0.4 (0.8)	–0.1 (0.8)

Differences between study groups were tested with the independent Student's *t*-test ($p < 0.05$).

were observed between the four and six implants group.

Five-years' survival rate of implants was high in both the four

and six implants group. These results are on the high end compared to the implant survival reported in the 5-year follow-up case series of Jemt

et al. (1996), Watson et al. (1997) and Bergendal & Engquist (1998) who used implants with a machined surface (5-year implants survival 72.4–79%) and similar to those reported by Mangano et al. (2011) and Eerdeken et al. (2015) (5-year implant survival 96.6–97.4%). The latter studies also used implants with a roughened surface, as in this study. Although a study comparing various implant designs was not analysed, apparently implants with a roughened surface perform better than implants with a machined surface in the maxilla.

The mean marginal bone loss between baseline (placement of the overdenture) and the 5-year evaluation was limited in both groups and again comparable to those reported by Mangano et al. (2011) and Eerdeken et al. (2015) (0.50–0.70 mm). The very limited marginal bone loss might be due to the neck design of the implants used (Hermann et al. 1997, Broggin et al. 2003, Van de Velde et al. 2010).

Mean indices for plaque, calculus, gingiva and bleeding were very low at the 5-year evaluation and probing depth was not deviating. Again these data are in agreement with the observations of Eerdeken et al. (2015). There were no differences between the groups. There might be some extra effort in performing hygiene tasks with six implants, but this does not result in worse results.

Incidence of peri-implantitis after 5 years was 8.3% and 4.5% in the four and six implants groups respectively. Because there was no

Table 4. Mean score of 5 scales concerning the denture complaints (possible range 0–3), mean scores of chewing ability of soft, tough and hard food (possible range 0–2) and overall satisfaction score (possible range 1–10) before, and 1 and 5 years after treatment. No significant differences between the four and six implants group were observed at all evaluation periods

	Pre-treatment		1 year		5 years	
	Four implants group (n = 25)	Six implants group (n = 25)	Four implants group (n = 24)	Six implants group (n = 25)	Four implants group (n = 24)	Six implants group (n = 22)
Functional complaints about upper denture (SD)	1.3 (0.7)	1.5 (0.5)	0.1 (0.1)	0.1 (0.1)	0.1 (0.1)	0.2 (0.2)
Functional complaints in general (SD)	1.1 (0.6)	1.2 (0.4)	0.1 (0.2)	0.2 (0.2)	0.1 (0.3)	0.2 (0.2)
Facial aesthetics (SD)	1.1 (0.9)	1.4 (0.8)	0.2 (0.3)	1.1 (0.2)	0.3 (0.5)	0.3 (0.5)
“Neutral Space” (SD)	0.6 (0.6)	0.5 (0.6)	0.2 (0.4)	0.2 (0.3)	0.3 (0.5)	0.4 (0.5)
Aesthetics (SD)	0.4 (0.4)	0.3 (0.3)	0.1 (0.1)	0.0 (0.1)	0.1 (0.1)	0.1 (0.1)
Soft food (SD)	0.4 (0.5)	0.5 (0.4)	0.0 (0.2)	0.0 (0.0)	0.1 (0.3)	0.0 (0.0)
Tough food (SD)	1.2 (0.6)	1.5 (0.4)	0.2 (0.4)	0.1 (0.2)	0.1 (0.4)	0.1 (0.3)
Hard food (SD)	1.8 (0.6)	1.9 (0.3)	0.3 (0.5)	0.2 (0.4)	0.3 (0.5)	0.4 (0.5)
Overall satisfaction score (SD)	4.3 (1.9)	4.1 (1.6)	8.9 (1.3)	8.9 (0.8)	8.8 (1.3)	9.0 (0.7)

Differences between study groups were tested with the independent Student's *t*-test ($p < 0.05$).

Table 5. Surgical and prosthetic aftercare (number of events) during 5 years of follow-up

	Four implants group (n = 24)	Six implants group (n = 22)
Removal of hyperplasia	1	0
Surgical treatment of peri-implantitis	0	0
Clip repair	0	0
Repair denture base/teeth	15	12
Relining overdenture	0	1
Readjustment occlusion	0	0
New bar	0	0
New overdenture	0	0

significant change in pocket probing depth at an earlier stage, no extra radiographs were made. Nevertheless, bone loss as a sign of peri-implantitis could not be reliably excluded in some patients before the 5-year evaluation period.

In a systematic review of De Waal et al. (2013), it was reported that numbers of prevalence of peri-implant mucositis and peri-implantitis with standardized threshold levels are missing in studies with fully edentulous patients. In this study, the patient-level incidence of peri-implant mucositis was 41.7% and of peri-implantitis was 8.3% in the four implants group. In the six implants group, patient-level incidence of peri-implant mucositis was 45.5% and of peri-implantitis was 4.5%. For the maxilla, there are no comparable 5-year studies. Also in fully edentulous patients, but for mandibular overdentures, 51.9% peri-implant mucositis and 16.9% peri-implantitis was reported after 5 years (Meijer et al. 2014). Peri-implant mucositis and peri-implantitis are infectious diseases caused by bacterial biofilm. Existing studies have demonstrated clearly that edentulism per se is no protection from peri-implant disease and that continuous supportive care is essential in maintaining peri-implant health.

Patients' satisfaction improved significantly when wearing implant-supported maxillary overdentures and results were shown to be favourable at both the 1- and 5-year evaluation, again in agreement with data reported by Krennmair et al. (2008) and Eerdekens et al. (2015). Krennmair et al. (2008) also mentioned in their case series that patients with an overdenture on four or six implants in the anterior maxilla were equally satisfied. In other words, patients'

satisfaction seemed to be irrespective of whether the bar was supported by four or six implants in the anterior maxillary region. The high satisfaction might be due to the fact that the overdenture is supported by a bar, which gives a comparable stability for both treatment options. The idea that six implants gives more stability than four implants, and resulting in more patients' satisfaction, turned out to be not true. Probably because four and six implants are more or less placed in the same area and the fact that the length of the bar is the same in both designs.

The high satisfaction with maxillary overdentures, including opinions on speech, resemble the results of Heydecke et al. (2004) in which favourable results of an overdenture were displayed compared with a fixed implant prosthesis.

Surgical complications were scarce. Prosthetic complications were restricted to repair of denture base and teeth. Mangano et al. (2011) reported that the majority of complications were related to the weakness of the anchorage components connecting bar and overdenture. This is in contrast with this study in which no clip repairs were recorded. In this study, an overdenture with built-in cobalt chromium reinforcement structure and gold retentive clips attached to it were used, which probably led to a minimum of prosthetic complications (Slot et al. 2012).

Rotational panoramic radiographs, lateral cephalograms and postero-anterior oblique radiographs were made to assess bone volume and possible pathology. Nowadays, in terms of radiation protection and diagnostic possibilities, cone beam computer tomography is preferred. In the study, a bar-connection was

used. Some studies reveal that peri-implant hygiene of solitary attachment systems are superior compared with bar attachment systems (Zou et al. 2013). Long-term studies on comparison of attachment systems would be advantageous.

From this 5-year follow-up study, it was concluded that bar-connected maxillary overdentures on four or six implants resulted in a comparable treatment outcome with high implant survival, limited loss of peri-implant marginal bone and high patient satisfaction.

References

- Bergendal, T. & Engquist, B. (1998) Implant-supported overdentures: a longitudinal prospective study. *The International Journal of Oral & Maxillofacial Implants* **13**, 253–262.
- Boven, C., Raghoebar, G. M., Vissink, A. & Meijer, H. J. A. (2015) Improving masticatory performance, bite force, nutritional state and patient's satisfaction with implant overdentures: a systematic review of the literature. *Journal of Oral Rehabilitation* **42**, 220–233.
- Broggini, N., McManus, L. M., Hermann, J. S., Medina, R. U., Oates, T. W., Schenk, R. K., Buser, D., Mellonig, J. T. & Cochran, D. L. (2003) Persistent acute inflammation at the implant-abutment interface. *Journal of Dental Research* **82**, 232–237.
- De Waal, Y. C. M., Van Winkelhoff, A. J., Meijer, H. J. A., Raghoebar, G. M. & Winkel, E. G. (2013) Differences in peri-implant conditions between fully and partially edentulous subjects: a systematic review. *Journal of Clinical Periodontology* **40**, 266–286.
- Eerdekens, L., Schols, M., Coelst, L., Quirynen, M. & Naert, I. (2015) A 5-year prospective study on cone-anchored implants in the edentulous maxilla. *Clinical Implant Dentistry and Related Research* **17** (Suppl. 2), e621–e632.
- Esposito, M., Hirsch, J. M., Lekholm, U. & Thomsen, P. (1998) Biological factors contributing to failures of osseointegrated oral implants. (I). Success criteria and epidemiology. *European Journal of Oral Sciences* **106**, 527–551.
- Ferrigno, N., Laureti, M., Fanali, S. & Grippaudo, G. (2002) A long-term follow-up study of non-submerged ITI implants in the treatment of totally edentulous jaws. Part I: ten-year life table analysis of a prospective multicenter study with 1286 implants. *Clinical Oral Implants Research* **13**, 260–273.
- Hermann, J. S., Cochran, D. L., Nummikoski, P. V. & Buser, D. (1997) Crestal bone changes around titanium implants. A radiographic evaluation of unloaded nonsubmerged and submerged implants in the canine mandible. *Journal of Periodontology* **68**, 1117–1130.
- Heydecke, G., McFarland, D. H., Feine, J. S. & Lund, J. P. (2004) Speech with maxillary implant prostheses: ratings of articulation. *Journal of Dental Research* **83**, 236–240.
- Jemt, T., Chai, J., Harnett, J., Heath, M. R., Hutten, J. E., Johns, R. B., McKenna, S., McNamara, D. C., Van Steenberghe, D., Taylor, R., Watson, R. M. & Herrmann, I. (1996) A 5-year prospective multicenter follow-up report on

- overdentures supported by osseointegrated implants. *The International Journal of Oral & Maxillofacial Implants* **11**, 291–298.
- Kalk, W. W., Raghoobar, G. M., Jansma, J. & Boering, G. (1996) Morbidity from iliac crest bone harvesting. *Journal of Oral and Maxillofacial Surgery* **54**, 1424–1429.
- Krennmair, G., Krainhöfner, M. & Piehslinger, E. (2008) Implant-supported maxillary overdentures retained with milled bars: maxillary anterior versus maxillary posterior concept. A retrospective study. *The International Journal of Oral & Maxillofacial Implants* **23**, 343–352.
- Lang, N. P. & Berglundh, T., on Behalf of Working Group 4 of the Seventh European Workshop on Periodontology (2011) Peri-implant diseases: where are we now? – Consensus of the Seventh European Workshop on Periodontology. *Journal of Clinical Periodontology* **38** (Suppl.), 178–181.
- Lindhe, J. & Meyle, J. (2008) Peri-implant diseases: Consensus Report of the Sixth European Workshop on Periodontology. *Journal of Clinical Periodontology* **35**(Suppl. 8), 282–285.
- Löe, H. & Silness, J. (1963) Periodontal disease in pregnancy. II: Correlation between oral hygiene and periodontal condition. *Acta Odontologica Scandinavica* **21**, 533–551.
- Mangano, C., Mangano, F., Shibli, J. A., Ricci, M., Sammons, R. L. & Figliuzzi, M. (2011) Morse taper connection implants supporting “planned” maxillary and mandibular bar-retained overdentures: a 5-year prospective multicenter study. *Clinical Oral Implants Research* **22**, 1117–1124.
- Meijer, H. J. A., Raghoobar, G. M., De Waal, Y. C. & Vissink, A. (2014) Incidence of peri-implant mucositis and peri-implantitis in edentulous patients with an implant-retained mandibular overdenture during a 10-years’ follow-up period. *Journal of Clinical Periodontology* **41**, 1178–1183.
- Meijndert, L., Meijer, H. J. A., Raghoobar, G. M. & Vissink, A. (2004) A technique for standardized evaluation of soft and hard peri-implant tissues in partially edentulous patients. *Journal of Periodontology* **75**, 646–651.
- Mombelli, A., Van Oosten, M. A. C., Schürch, E. & Lang, N. (1987) The microbiota associated with successful or failing osseointegrated titanium implants. *Oral Microbiology and Immunology* **2**, 145–151.
- Raghoobar, G. M., Meijer, H. J., Slot, W., Slater, J. J. & Vissink, A. (2014) A systematic review of implant-supported overdentures in the edentulous maxilla, compared to the mandible: How many implants? *European Journal of Oral Implantology* **7**, 191–201.
- Raghoobar, G. M., Schoen, P., Meijer, H. J., Stellingma, K. & Vissink, A. (2003) Early loading of endosseous implants in the augmented maxilla: a 1-year prospective study. *Clinical Oral Implants Research* **14**, 697–702.
- Sanna, A., Nuytens, P., Naert, I. & Quirynen, M. (2009) Successful outcome of splinted implants supporting a “planned” maxillary overdenture: a retrospective evaluation and comparison with fixed full dental prostheses. *Clinical Oral Implants Research* **20**, 406–413.
- Sanz, M., Chapple, I. L. & on behalf of Working Group 4 of the VIII European Workshop on Periodontology. (2012) Clinical research on peri-implant diseases: consensus report of Working Group 4. *Journal of Clinical Periodontology* **39**(Suppl. 12), 202–206.
- Slot, W., Raghoobar, G. M., Van Dijk, G. & Meijer, H. J. A. (2012) Attachment of clips in a bar-retained maxillary implant overdenture: a clinical report. *Journal of Prosthetic Dentistry* **105**, 359–364.
- Slot, W., Raghoobar, G. M., Vissink, A., Huddleston Slater, J. J. & Meijer, H. J. (2010) A systematic review of implant-supported maxillary overdentures after a mean observation period of at least 1 year. *Journal of Clinical Periodontology* **37**, 98–110.
- Slot, W., Raghoobar, G. M., Vissink, A. & Meijer, H. J. A. (2013) Maxillary overdentures supported by 4 or 6 implants in the anterior region; 1-year results from a randomized controlled trial. *Journal of Clinical Periodontology* **40**, 303–310.
- Smeets, E. C., De Jong, K. J. & Abraham-Inpijn, L. (1998) Detecting the medically compromised patient in dentistry by means of the medical risk-related history. A survey of 29,424 dental patients in The Netherlands. *Preventive Medicine* **27**, 530–535.
- Stellingsma, K., Slagter, A. P., Stegenga, B., Raghoobar, G. M. & Meijer, H. J. A. (2005) Masticatory function in patients with an extremely resorbed mandible restored with mandibular implant-retained overdentures: comparison of three types of treatment protocols. *Journal of Oral Rehabilitation* **32**, 403–410.
- Ten Bruggenkate, C. M., de Rijke, T. B., Kraaijenhagen, H. A. & Oosterbeek, H. S. (1994) Ridge mapping. *Implant Dentistry* **3**, 179–182.
- Van de Velde, T., Collaert, B., Sennerby, L. & De Bruyn, H. (2010) Effect of implant design on preservation of marginal bone in the mandible. *Clinical Implant Dentistry and Related Research* **12**, 134–141.
- Vercruyssen, M., Marcelis, K., Coucke, W., Naert, I. & Quirynen, M. (2010) Long-term, retrospective evaluation (implant and patient-centred outcome) of the two-implants-supported overdenture in the mandible. Part I: survival rate. *Clinical Oral Implants Research* **21**, 357–365.
- Vervoorn, J. M., Duinkerke, A. S. H., Luteijn, F. & Van Der Poel, A. C. M. (1988) Assessment of denture satisfaction. *Community Dentistry and Oral Epidemiology* **16**, 364–367.
- Watson, R. M., Jemt, T., Chai, J., Harnett, J., Heath, M. R., Hutton, J. E., Johns, R. B., Lithner, B., McKenna, S., McNamara, D. C., Naert, I. & Taylor, R. (1997) Prosthodontic treatment, patient response, and the need for maintenance of complete implant-supported overdentures: an appraisal of 5 years of prospective study. *International Journal of Prosthodontics* **10**, 345–354.
- Zou, D., Wu, Y., Huang, W., Wang, F., Wang, S., Zhang, Z. & Zhang, Z. (2013) A 3-year prospective clinical study of telescopic crown, bar, and Locator attachments for removable four implant-supported maxillary overdentures. *The International Journal of Prosthodontics* **26**, 566–573.

Address:

Wim Slot

Department of Fixed and Removable Prosthodontics and Biomaterials Dental School

University Medical Center Groningen

PO Box 196

NL-9700 AD Groningen

The Netherlands

E-mail: j.w.a.slot@umcg.nl

Clinical Relevance

Scientific rationale for the study: Implants supporting an overdenture in the maxilla improve retention and stability. A systematic review supported this observation but simultaneously it showed that there were no long term controlled trials which provided a consensus

whether this should be on four or six implants.

Principal findings: No significant differences between the four and six implants group were observed regarding implant survival, overdenture survival, oral hygiene level (plaque and calculus), peri-implant health (modified gingiva index,

bleeding on probing and pocket probing depth), marginal bone loss and patients’ satisfaction during the five-years follow-up.

Practical implications: This randomized controlled trial supports the use of four implants instead of six implants to support a bar-supported overdenture.