

## Case Report

# Novel treatment of a central type, primitive neuroectodermal tumor of the ovary with postoperative pediatric medulloblastoma chemotherapy regimen: A case report and review of the literature



Stuart S. Winkler<sup>a</sup>, Anais Malpica<sup>b</sup>, Pamela T. Soliman<sup>c,\*</sup>

<sup>a</sup> Department of Obstetrics and Gynecology, Wake Forest School of Medicine, Winston Salem, NC, United States

<sup>b</sup> Department of Pathology, The University of Texas MD Anderson Cancer Center, Houston, TX, United States

<sup>c</sup> Department of Gynecologic Oncology and Reproductive Medicine, The University of Texas MD Anderson Cancer Center, Houston, TX, United States

## ARTICLE INFO

## Article history:

Received 11 May 2015

Received in revised form 22 June 2015

Accepted 23 June 2015

Available online 26 June 2015

## Keywords:

Central primitive neuroectodermal tumor

PNET

Germ cell tumor

Teratoma

Medulloblastoma

Ovary tumor

## 1. Introduction

Central type, primitive neuroectodermal tumors (cPNETs) of the ovary are exceedingly rare, poorly-differentiated germ cell tumors that share histology with PNET tumors of the central nervous system. Ovarian cPNETs can be primary malignancies (monophasic teratomas) or can exist as immature neural and glial precursors within teratomas (Morovic & Damjanov, 2008). Kanbour-Shakir et al. described an illustrative case of a PNET of the ovary arising in a mature cystic teratoma. Within the specimen, a transition zone of immature neoplastic elements from mature neural elements was noted (Kanbour-Shakir et al., 1993).

cPNETs are histologically identical to CNS-PNETs and recapitulate immature cell-types including medulloepitheliomas, ependymoblastomas and neuroblastomas (Kleinman et al., 1993). Ovarian medulloblastomas are currently classified as cPNETs but may be considered separate from other cPNETs to mirror the World Health Organization's 2007 classification of childhood CNS embryonal tumors (Louis et al., 2007). The WHO classification includes three main tumor groups: CNS-PNETs, medulloblastomas and atypical teratoid/rhabdoid tumors. Medulloblastomas are now separated from CNS-PNETs,

recognizing the molecular and clinical differences in these distinct tumors (Adamski et al., 2014).

We present a case of a patient with advanced stage cPNET tumor arising from an ovarian teratoma and describe our successful approach to treatment using a medulloblastoma chemotherapy regimen.

## 2. Case report

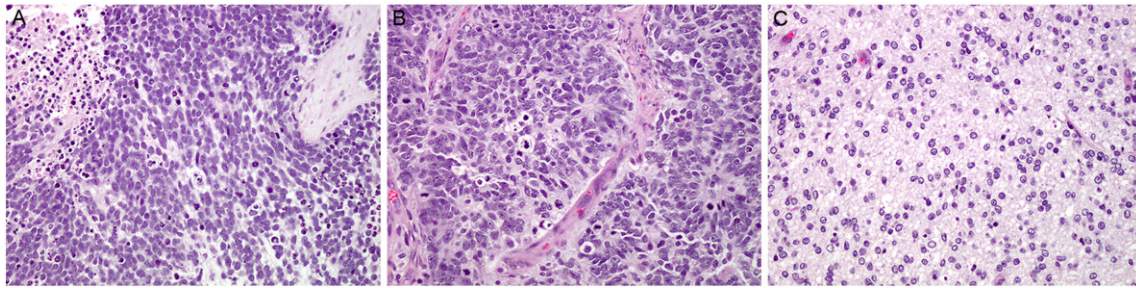
A 37-year old African American female presented to an outside emergency department in December 2013 with complaints of gradual onset abdominal pain and constipation. A computed tomography (CT) scan at that time showed a 10-cm left ovarian mass, omental cake, ascites, carcinomatosis and pelvic and paraaortic adenopathy as large as 2 cm in size. She was ultimately referred to a gynecologic oncologist and in February 2014 underwent an exploratory laparotomy, supracervical hysterectomy, bilateral salpingo-oophorectomy, omentectomy, lymph node dissection and suboptimal tumor reductive surgery. There was an extensive peritoneal disease left at the conclusion of surgery.

Upon the review of the pathology material, the tumor was diagnosed as a central type, primitive neuroectodermal tumor (cPNET) arising in an immature teratoma of the left ovary. The tumor extended to the left fallopian tube and metastasized to the contralateral ovary, right fallopian tube, uterine serosa, myometrium, uterine cervix and pelvic lymph nodes. The areas of cPNET contained mitotically active small blue cells arranged in sheets, trabeculae or confluent nests (Fig. 1A). Ependymal type rosettes and glial differentiation were noted (Fig. 1B and C, respectively). Immunohistochemical studies showed that the tumor cells were patchy positive for S-100, synaptophysin, GFAP and NSE (Fig. 2A and B) while rare cells showed membranous staining for CD99 (Fig. 2C). Very focal membranous expression of CD99, as seen in our case, contrasts with the strong and diffuse staining seen in peripheral type PNETs. This unusual finding has been noted in rare cases of supratentorial PNETs and in a rare case of cPNET involving the uterus (Visee et al., 2005; Euscher et al., 2008). The tumor cells were negative for keratin, EMA, chromogranin and WT<sup>-1</sup>. Fli-1 was non-contributory as there was background staining.

Postoperatively, she recovered well without complications; however, in the subsequent two months she developed symptomatic ascites and had two paracenteses. She presented to our gynecologic oncology clinic at MD Anderson in late April 2014 for treatment planning.

\* Corresponding author at: Department of Gynecologic Oncology and Reproductive Medicine, The University of Texas, MD Anderson Cancer Center, 1155 Herman Pressler, Unit 1362, Houston, TX 77030, United States.

E-mail address: [psoliman@mdanderson.org](mailto:psoliman@mdanderson.org) (P.T. Soliman).



**Fig. 1.** Sheets of mitotically active blue cells (A), ependymal type rosettes (B), and glial differentiation (C) (all images, H&E stained slides at 200× magnification).

At the time of consultation, we obtained a pretreatment CT of the chest, abdomen and pelvis that showed large volume ascites, extensive peritoneal disease with bulky implants, paraaortic and pelvic adenopathy, and diaphragmatic and mediastinal adenopathy. Serum tumor markers included a CA-125 20.2 U/mL, carcinoembryonic antigen serum 0.4 ng/mL, alpha fetoprotein 3.3 ng/mL, and human chorionic gonadotropin 4.4 mIU/mL.

Given the paucity of data informing treatment of cPNET of the ovary and the morphologic similarity to CNS-PNET and medulloblastoma, we consulted with our pediatric neuro-oncology colleagues. After discussion at our multidisciplinary planning conference, we elected to treat our patient with a departmental medulloblastoma regimen of etoposide 60 mg/m<sup>2</sup> IV on cycle days 1, 2 and 3; cisplatin 25 mg/m<sup>2</sup> IV on cycles days 1, 2, and 3; and cyclophosphamide 1000 mg/m<sup>2</sup> IV on cycle day 3. Cycles were repeated every three weeks. The patient was admitted for neutropenic fever and acute kidney injury following cycle #1 and pegfilgrastim was given with subsequent cycles. Otherwise, she tolerated the chemotherapy well.

After completion of cycle #3 a CT of the chest, abdomen and pelvis demonstrated treatment response with interval decrease in the abdominopelvic carcinomatosis and metastatic adenopathy in the mediastinal, paraaortic and pelvic nodes. Ca-125 was 25.2 U/mL. The patient underwent CT imaging after every 3 cycles of therapy to evaluate for response. She ultimately received a total of 10 cycles of therapy at which time she was noted to have disease progression. She is currently receiving combination therapy with doxorubicin and dacarbazine.

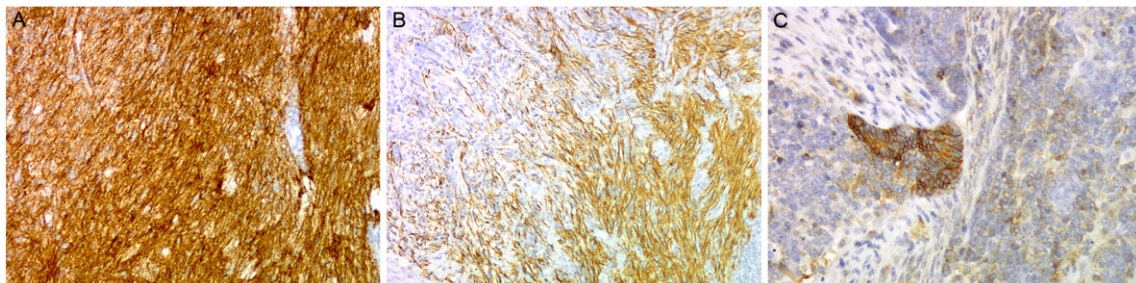
### 3. Discussion

Central type, primitive neuroectodermal tumors of the ovary are poorly differentiated malignant small round cell tumors composed of neural and glial precursors. These tumors are histologically related to primitive neuroectodermal tumors of the central nervous system (CNS-PNET). cPNETs are distinct from peripheral PNETs (pPNETs) of the ovary, which are part of the Ewing sarcoma group of tumors that arise from neural crest cells. As other authors have pointed out, this distinction between central and peripheral PNETs is not always clear in the literature (Lim et al., 2013). Molecular profiles of pPNETs usually demonstrate a signature chromosomal translocation, t(11:22)(q24;q12),

though multiple aberrations have been described including deletions in Rb and amplification of N-myc and EGFR (Chow et al., 2004 Mar). Ishii et al. performed molecular profiling to characterize classic pPNETs and cPNETs and concluded that cPNETs lack any specific genetic or protein markers (Chow et al., 2004 Mar; Ishii et al., 2001). Therefore, molecular profiling was not performed in our case.

Various treatment approaches have been described including surgery alone with observation and surgery with chemotherapy with or without radiation therapy. Original chemotherapy protocols for ovarian PNETs employed regimens established for the treatment of ovarian germ cell malignancies (i.e. bleomycin, etoposide, cisplatin), but outcomes are poor, especially for advanced stage disease (Kleinman et al., 1993; Gershenson et al., 1990). Other treatment regimens have been proposed which adapt pediatric neuro-oncology regimens to match the specific malignant cell type.

Few case reports describe a robust response to chemotherapy in patients with advanced stage ovarian PNETs. Block et al. reported a case of a 22-year old with recurrent metastatic neuroblastoma arising in an immature teratoma who was treated with a 9-month course of chemotherapy (cyclophosphamide, doxorubicin, vincristine and dimethyltriazenoimidazole carboxamide) followed by consolidation radiotherapy (Block et al., 1984). At the time of the case report, the patient was in complete remission 4 years after treatment. Lawlor et al. described a case of a 13-year old with metastatic ovarian PNET with neuroblastic and focal ganglionic differentiation treated with aggressive chemotherapy after suboptimal debulking (Lawlor et al., 1997). The regimen included cisplatin, etoposide, cyclophosphamide and doxorubicin with consolidation carboplatin, melphalan and thiotepa. This was followed by peripheral blood progenitor cell rescue. This patient had no evidence of disease at 14 months of follow-up. Clinkard et al. described a chemotherapy regimen using cisplatin and etoposide to treat a suboptimally debulked stage IIIc ovarian medulloblastoma. The patient was without evidence of disease at 7 years of follow-up (Clinkard et al., 2011) (Table 1). Kleinman et al. published a series of 12 ovarian PNET cases, 7 of which were advanced stage at the time of diagnosis. In this series, no distinction is made between central and peripheral PNETs. In addition, specific chemotherapy regimens were not described (Kleinman et al., 1993).



**Fig. 2.** Tumor cells are positive for synaptophysin (200× magnification) (A), some of the tumor cells are positive for GFAP (200× magnification) (B), and rare cells show membranous staining for CD99 (200× magnification) (C).

**Table 1**

Published reports of chemotherapy response in patients with advanced ovarian PNET.

Report	Pathology	Regimen	Duration of treatment	Outcome
Block et al. (1984)	Recurrent, metastatic ovarian neuroblastoma arising in immature teratoma	Cyclophosphamide, doxorubicin, vincristine and dimethyltriazenoimidazole carboxamide followed by consolidation radiotherapy	9 months	NED at 18 months
Lawlor et al. (1997)	Metastatic ovarian PNET with neuroblastic and focal ganglionic differentiation	Suboptimal debulking followed by induction with cisplatin, etoposide, cyclophosphamide and doxorubicin. After stimulation, apheresis performed followed by myeloablative doses of carboplatin, melphalan and thiotepa and reinfusion of peripheral blood progenitor cells	4 cycles	NED at 14 months
Clinkard et al. (2011)	Stage IIIc ovarian medulloblastoma	Suboptimal debulking followed by cisplatin and etoposide	3 cycles	NED at 7 years

For our patient, we elected to use an established medulloblastoma regimen with etoposide, cisplatin and cyclophosphamide. After 3 cycles of chemotherapy, she demonstrated an excellent response on repeat imaging. After 6 cycles of therapy, her disease was stable. She ultimately had progression of her disease with worsening ascites and carcinomatosis after 10 cycles of therapy.

#### 4. Conclusion

Central type, primitive neuroectodermal tumors of the ovary are exceedingly rare tumors that resemble CNS-PNETs. We report a case of advanced ovarian cPNET tumor with an excellent initial response to a pediatric medulloblastoma chemotherapy regimen using etoposide, cisplatin and cyclophosphamide.

#### Conflict of interest

The authors certify that they have no affiliations with or involvement in any organization or entity with any financial interest in the subject matter or materials discussed in this manuscript.

#### References

- Morovic, A., Damjanov, I., 2008. Neuroectodermal ovarian tumors: a brief overview. *Histol. Histopathol.* 23 (6), 765–771.
- Kanbour-Shakir, A., Sawaday, J., Kanbour, A.I., Kunschner, A., Stock, R.J., 1993. Primitive neuroectodermal tumor arising in an ovarian mature cystic teratoma: immunohistochemical and electron microscopic studies. *Int. J. Gynecol. Pathol.* 12 (3), 270–275.
- Kleinman, G.M., Young, R.H., Scully, R.E., 1993. Primary neuroectodermal tumors of the ovary. A report of 25 cases. *Am. J. Surg. Pathol.* 17 (8), 764–778.
- Louis, D.N., Ohgaki, H., Wiestler, O.D., Cavenee, W.K., Burger, P.C., Jouvett, A., et al., 2007. The 2007 WHO classification of tumours of the central nervous system. *Acta Neuropathol.* 114 (2), 97–109.

- Adamski, J., Ramaswamy, V., Huang, A., Bouffet, E., 2014. Advances in managing medulloblastoma and intracranial primitive neuro-ectodermal tumors. *Prime Rep.* 6, 56.
- Visee, S., Soltner, C., Rialland, X., Machet, M.C., Loussoarn, D., Milinkevitch, S., et al., 2005. Supratentorial primitive neuroectodermal tumours of the brain: multidirectional differentiation does not influence prognosis. A clinicopathological report of 18 patients. *Histopathology* 46 (4), 403–412.
- Euscher, E.D., Deavers, M.T., Lopez-Terrada, D., Lazar, A.J., Silva, E.G., Malpica, A., 2008. Uterine tumors with neuroectodermal differentiation: a series of 17 cases and review of the literature. *Am. J. Surg. Pathol.* 32 (2), 219–228.
- Lim, Y.K., Ku, C.W., Teo, G.C., Lim, S.L., Tee, C.S., 2013. Central primary primitive neuroectodermal tumor (cPNET) arising from an ovarian mature cystic teratoma in pregnancy: a case report and review of medical literature. *Gynecol. Oncol. Case Rep.* 4, 56–59.
- Chow, S.N., Lin, M.C., Shen, J., Wang, S., Jong, Y.J., Chien, C.H., 2004. Analysis of chromosome abnormalities by comparative genomic hybridization in malignant peripheral primitive neuroectodermal tumor of the ovary. *Gynecol. Oncol.* 92 (3), 752–760.
- Ishii, N., Hiraga, H., Sawamura, Y., Shinohe, Y., Nagashima, K., 2001. Alternative EWS-FLI1 fusion gene and MIC2 expression in peripheral and central primitive neuroectodermal tumors. *Neuropathology* 21 (1), 40–44.
- Gershenson, D.M., Morris, M., Cangir, A., Kavanagh, J.J., Stringer, C.A., Edwards, C.L., et al., 1990. Treatment of malignant germ cell tumors of the ovary with bleomycin, etoposide, and cisplatin. *J. Clin. Oncol.* 8 (4), 715–720.
- Block, M., Gilbert, E., Davis, C., 1984. Metastatic neuroblastoma arising in an ovarian teratoma with long-term survival. Case report and review of the literature. *Cancer* 54 (3), 590–595.
- Lawlor, E.R., Murphy, J.L., Sorensen, P.H., Fryer, C.J., 1997. Metastatic primitive neuroectodermal tumour of the ovary: successful treatment with mega-dose chemotherapy followed by peripheral blood progenitor cell rescue. *Med. Pediatr. Oncol.* 29 (4), 308–312.
- Clinkard, D.J., Khalifa, M., Osborn, R.J., Bouffet, E., 2011. Successful management of medulloblastoma arising in an immature ovarian teratoma in pregnancy. *Gynecol. Oncol.* 120 (2), 311–312.