

Pancreatic Adenocarcinoma Invading the Duodenum and Presenting as Idiopathic Gastroparesis with Nausea and Vomiting

Brent T. Cengia, MD¹, Paula S. Stuart, PA², and Kenneth L. Koch, MD²

¹Department of Internal Medicine, Wake Forest School of Medicine, Winston-Salem, NC

²Department of Gastroenterology, Wake Forest School of Medicine, Winston-Salem, NC

ABSTRACT

A 65-year-old woman presented with a 5-month history of nausea, vomiting, and weight loss. Prior esophagogastroduodenoscopy showed retained food and delayed gastric emptying, but abdominal computed tomography was normal. The working diagnosis was idiopathic gastroparesis. Subsequently, an electrogastrogram test showed normal 3-cycle-per-minute activity, although it was suggestive of obstructive gastroparesis. Repeat esophagogastroduodenoscopy showed obstruction at the postbulbar duodenum. Repeat abdominal computed tomography revealed a 2.2 x 1.6-cm mass in the pancreaticoduodenal groove narrowing the descending duodenum and aspiration of the mass revealed adenocarcinoma.

INTRODUCTION

Gastroparesis is associated with many vague, nonspecific but disabling symptoms such as nausea, vomiting, early satiety, and abdominal discomfort and pain.^{1,2} In severe cases, weight loss becomes significant. Although the most frequent causes of gastroparesis are associated with diabetes or are idiopathic, reversible forms of gastroparesis must be considered when a delay in gastric emptying is documented. Reversible causes of gastroparesis are due to obstruction at the pylorus and chronic mesenteric ischemia.^{3,4} In chronic mesenteric ischemia, a history of vascular disease and an abdominal bruit in patients with gastroparesis and gastric dysrhythmia are clues. Vascular stents or bypass graft operations correct the stenosis, restore blood flow, and correct gastric dysrhythmias and the delay of gastric emptying.⁴

In a subset of patients, gastroparesis is due to pyloric stenosis or pylorospasm. In these patients, the normal 3-cycle-per-minute (CPM) gastric myoelectrical rhythm is present.^{3,5} The normal 3-CPM electrical pattern indicates that the interstitial cells of Cajal (ICCs) and gastric enteric neurons of the corpus-antrum are normal.⁶⁻⁸ In these cases, therapy is directed towards the pylorus.³ We present a case in which a careful reconsideration of the cause of “idiopathic” gastroparesis, in light of characteristic electrogastrogram (EGG) findings, led to a new diagnosis: obstructive gastroparesis.

CASE REPORT

A 65-year-old woman was referred with a 5-month history of worsening nausea, vomiting, early satiety, and a working diagnosis of idiopathic gastroparesis. Prior to consultation, H₂ blocker and proton pump inhibitor therapy provided no relief of heartburn symptoms. Routine laboratory studies, amylase, and lipase were normal. A small bowel follow-through was normal. Abdominal computed tomography (CT) with arteriography 3 months prior to referral was normal. Upper endoscopy revealed retained food in the stomach. Cholelithiasis was detected and a

ACG Case Rep J 2016;3(4):e109. doi:10.14309/crj.2016.82. Published online: August 17, 2016.

Correspondence: Kenneth L. Koch, Gastroenterology, Wake Forest School of Medicine, Winston-Salem, North Carolina 27157 (kkoch@wakehealth.edu).



Copyright: © 2016 Cengia et al. This work is licensed under a Creative Commons Attribution-NonCommercial-NoDerivatives 4.0 International License. To view a copy of this license, visit <http://creativecommons.org/licenses/by-nc-nd/4.0>.

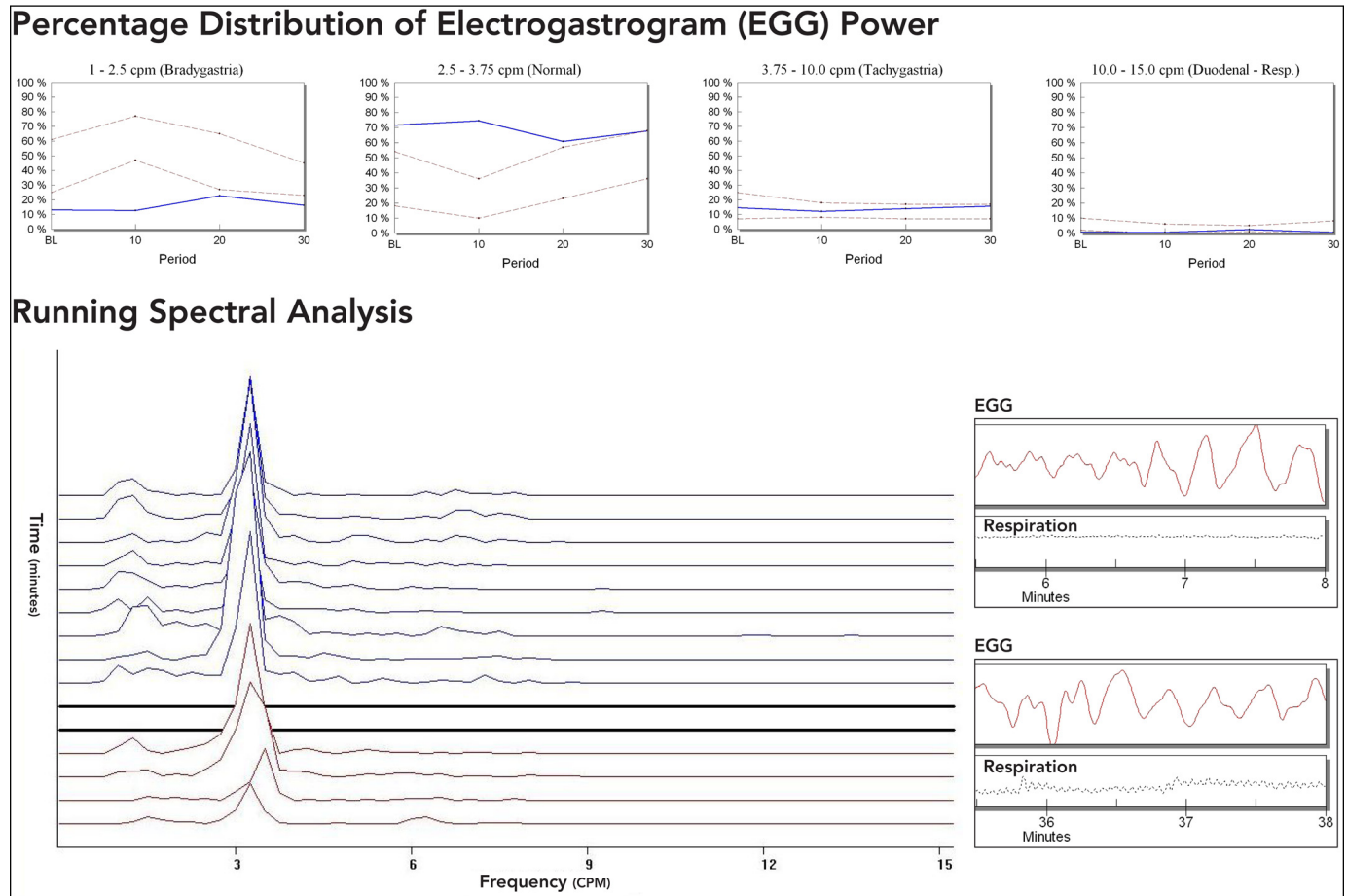


Figure 1. Normal 3-CPM GMA is seen in the rhythm strips, and normal 3-CPM peaks are seen in the spectral analysis.

laparoscopic cholecystectomy was performed, but symptoms did not improve. Three months prior to consultation, a solid-phase gastric emptying study revealed 25% of the meal emptied (75% meal retained) at 4 hours, consistent with severe gastroparesis. Metoclopramide, ondansetron, dronabinol, and domperidone did not help her symptoms.

At the time of her consultation, constant nausea was exacerbated by eating. She had lost 18 kg but denied abdominal pain, fevers, chills, sweats, chest pain, and dyspnea. Family history was unremarkable. She smoked in the remote past and used alcohol rarely but was taking 16 prescription and over-the-counter medications. A gastric emptying study was ordered to confirm severity of gastroparesis, and an EGG with water load test was obtained to determine gastric myoelectrical activity (GMA). The EGG demonstrated normal 3-CPM activity in response to a poor water load test volume (Figure 1).

Over the course of the next week, the patient's symptoms worsened with progressive weight loss necessitating hospitalization for expedited evaluation. On admission, her temperature was 36.7°C, blood pressure was 123/70, pulse was 83, and respiratory rate was 18. Body mass index was 28 kg/m².

Physical examination was notable for dry mucous membranes, 2/6 systolic ejection murmur. Abdomen was flat, soft, and mildly tender to palpation in the epigastrium and left upper quadrant. Bowel sounds were hyperactive, and a positive gastric succussion splash was present. Routine laboratory studies were normal with the exception of elevated liver chemistries: aspartate aminotransferase 105 U/L, alanine aminotransferase 15 U/L, alkaline phosphatase 99 U/L, and total bilirubin 2.3 mg/dL.

Endoscopy revealed esophagitis in the lower third of the esophagus. Approximately 1800 mL of retained liquid was suctioned from the stomach, but the gastric corpus, antrum, and pylorus were normal. An obstructing nodular mass was found in the postbulbar duodenum. Abdominal CT revealed abrupt narrowing of the descending duodenum. The common bile duct was dilated at 9 mm. A 2.2 x 1.6-cm ill-defined soft tissue mass in the pancreaticoduodenal groove between the descending duodenum and the pancreatic head was described (Figure 2). The pancreas was normal. Also noted was a 13-mm anterior portal vein lymph node and a 2.3 x 1.1-cm left adrenal mass. Endoscopic ultrasound-guided fine needle aspiration of the soft tissue mass showed adenocarcinoma. The lymph nodule biopsy

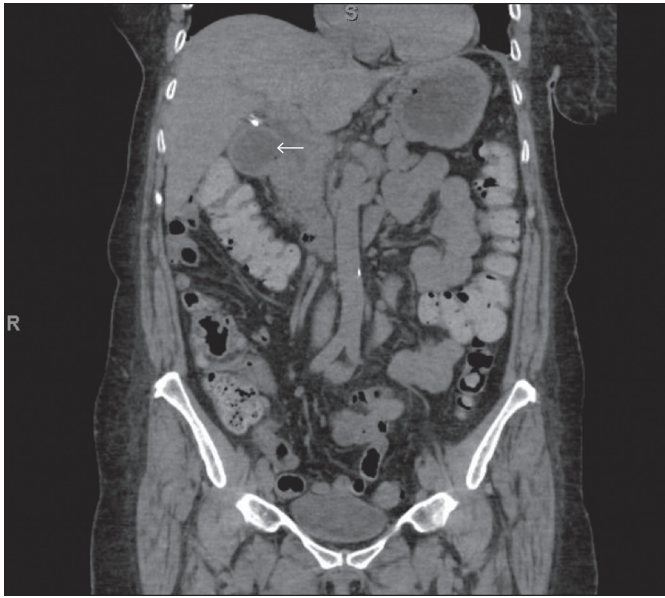

Figure 2. Abdominal CT (coronal view) shows a dilated duodenum and narrowing in the descending duodenum (arrow). There is a 2.2 x 1.6-cm soft tissue postbulbar mass, which is located between the descending duodenum and the pancreatic head, creating the postbulbar obstruction. Fine needle aspiration of the mass at endoscopic ultrasound revealed adenocarcinoma.

also showed adenocarcinoma. Gastrojejunostomy was performed to bypass the gastric outlet obstruction. Neoadjuvant chemotherapy with folinic acid, fluorouracil, and oxaliplatin was started for duodenal adenocarcinoma. After 4 cycles of chemotherapy, she underwent a Whipple procedure. The pathology report indicated an adenocarcinoma of the pancreas with extension into the duodenum and metastasis to the adrenal gland and 1 lymph node. Final pathology interpretation was pancreatic adenocarcinoma T3N1M1.

DISCUSSION

Chronic nausea and vomiting is associated with gastroparesis, and when gastroparesis is confirmed, causes such as mechanical obstruction, chronic mesenteric ischemia, diabetes, past surgeries, medications, neurologic causes, and scleroderma should be explored. Idiopathic gastroparesis is the most frequent cause,^{1,2} but reversible forms of gastroparesis due to obstruction and chronic mesenteric ischemia must be considered.^{3,4}

Obstructive gastroparesis generally means that pyloric stenosis or pylorospasm are responsible for the delay in gastric emptying of the test meal. In pylorospasm, the neuromuscular abnormality causing delayed emptying is localized to the pylorus, and the motility of the corpus and antrum are normal.⁵ In these cases, gastric smooth muscle, the pacemaker cells, the ICCs, and neurons of the corpus and antrum of the stomach are normal (greater than 5 ICCs/high power field normal 3-CPM GMA).^{6,7} If the gastroparesis is due to neuromuscular

disease of the corpus and antrum with depletion of ICCs and inflammatory infiltrates around abnormal gastric enteric neurons, then gastric dysrhythmias such tachygastrias, bradygastrias, and slow wave conduction defects are present.^{7,8} In patients with gastroparesis and the normal 3-CPM GMA pattern, treatment focuses on the pylorus to correct the delay in gastric emptying and improve symptoms. If mechanical obstructions at the pylorus are excluded by endoscopy or abdominal imaging, then the pyloric disorder is likely to be pylorospasm. In these cases, pyloric therapies such as balloon dilation or botulinum toxin A injection are helpful.^{9,10}

Our case emphasizes the importance of searching for a specific cause of gastroparesis, especially an obstructive, reversible cause. The EGG is a noninvasive measure of GMA. The water load test is a provocative test to stimulate GMA. Gastric dysrhythmias are present in most gastroparesis cases. A subset (<20%), however, has normal 3-CPM GMA. Because the EGG recording showed normal 3-CPM activity in this patient, an obstructive lesion at the pylorus was highly likely to be present. However, at endoscopy the pylorus was normal, but the obstructing lesion was found immediately distal to the duodenal bulb. This clinical approach to subtyping gastroparesis with EGG testing is evolving and more treatment and outcome data are needed.

Gastroparesis occurs in patients with pancreatic cancers both in the absence and presence of mechanical obstruction.^{11,12} Pancreatic cancer associated gastroparesis is a well-described condition that occurs in the absence of mechanical obstruction.¹³ Large and obvious pancreatic masses may obstruct the duodenum and common bile duct, but pancreatic masses were not appreciated in 2 CTs in our patient, and pancreatic cancer was only diagnosed after Whipple procedure. The small pancreatic primary cancer directly invaded the duodenum and caused the obstructive gastroparesis, an unusual cause of gastroparesis. The literature contains reports of malignant duodenal obstructions presenting as gastroparesis.¹⁴⁻¹⁶ We found no previous reports of pancreatic adenocarcinoma extending into the duodenum initially presenting as obstructive gastroparesis.

DISCLOSURES

Author contributions: All authors wrote the manuscript and reviewed the chart and literature. Kenneth Koch is the article guarantor.

Financial disclosure: K. Koch is a 3CPM Stockholder; Consultant: Glaxo-Smith-Kline; PI: Rhythm Pharma.

Informed consent was obtained for this case report.

Received July 30, 2015; Accepted February 1, 2016

REFERENCES

1. Camilleri M, Parkman HP, Shafi MA, et al. Clinical guideline: Management of gastroparesis. *Am J Gastroenterol*. 2013;108(1):18-37.
2. Koch KL. Gastric neuromuscular function and neuromuscular disorders. In: Feldman M, Friedman LS, Brandt LJ, eds. *Sleisenger and Fordtran's Gastrointestinal and Liver Disease: Pathophysiology/Diagnosis/Management*. Philadelphia, PA: Elsevier, Inc.; 2015:811-38.
3. Brzana RJ, Koch KL, Bingaman S. Gastric myoelectrical activity in patients with gastric outlet obstruction and idiopathic gastroparesis. *Am J Gastroenterol*. 1998;93(10):1803-9.
4. Liberski SM, Koch KL, Atnip RG, Stern RM. Ischemic gastroparesis: Resolution after revascularization. *Gastroenterology*. 1990;99(1):252-7.
5. Koch KL. Electrogastrography for evaluation of patients with suspected gastroparesis. In: Parkman H, McCallum R eds. *Gastroparesis: Pathophysiology, Presentation, Diagnosis and Treatment*. New York, NY: Springer; 2011:153-61.
6. O'Grady G, Angeli TR, Du P, et al. Abnormal initiation and conduction of slow wave activity in gastroparesis, defined by high-resolution electrical mapping. *Gastroenterology*. 2012;143(3):589-98.
7. Grover M, Farrugia G, Lurken MS, et al. Cellular changes in diabetic and idiopathic gastroparesis. *Gastroenterology*. 2011;140(5):1575-85.
8. Lin Z, Sarosiek I, Forster J, et al. Association of the status of interstitial cells of Cajal and electrogastrogram parameters, gastric emptying, and symptoms in patients with gastroparesis. *Neurogastroenterol Motil*. 2010;22(1):56-61.
9. Friedenberg FK, Palit A, Parkman HP, et al. Botulinum toxin a for the treatment of delayed gastric emptying. *Am J Gastroenterol*. 2008;103(2):416-23.
10. Kundu S, Koch KL. Effect of balloon distention or botulinum toxin a injection of the pylorus on symptoms and body weight in patients with gastroparesis and normal 3 cycle per minute gastric electrical activity. *Am J Gastroenterol*. 2011;106:S35.
11. Fagniez PL, Rotman N. Malignant tumors of the duodenum. In: RG Holzheimer, JA Mahnick, eds. *Surgical Treatment: Evidence-Based and Problem-Oriented*. Munich, Germany: Zuckschwerdt; 2001.
12. Donthireddy KR, Ailawadhi S, Nasser E, et al. Malignant gastroparesis: Pathogenesis and management of an underrecognized disorder. *J Support Oncol*. 2007;5(8):355-63.
13. Leung J, Silverman W. Diagnostic and therapeutic approach to pancreatic-cancer associated gastroparesis: Literature review and our experience. *Dig Dis Sci*. 2009;54:401-5.
14. Chang SS, Chen TS, Huang CC, et al. Pseudogastroparesis as a presentation of small-bowel malignancy. *Eur J Gastroenterol Hepatol*. 2000;12(3):351-5.
15. Ginori A, Vassallo L, Buturano MA, et al. Pancreatic adenocarcinoma in duodenal ectopic pancreas: A case report and review of the literature. *Pathologica*. 2013;105(2):56-8.
16. Patel VG, Eltaveb OM, Henderson VJ, et al. Primary duodenal low-grade mucosa-associated lymphoid tissue lymphoma presented with outlet obstruction. *Am Surg*. 2004;70(7):613-6.