

Received: 2019.03.16
Accepted: 2019.05.03
Published: 2019.08.12

e-ISSN 1941-5923
© Am J Case Rep, 2019; 20: 1189-1194
DOI: 10.12659/AJCR.916268

Grill Brush Bristle Case Series: Three Unique Presentations of Ingested Foreign Bodies

Authors' Contribution:
Study Design A
Data Collection B
Statistical Analysis C
Data Interpretation D
Manuscript Preparation E
Literature Search F
Funds Collection G

ABCDEF 1 **Rachel Appelbaum**
ABCDEF 1 **Thomas Nowakowski**
ABCDEF 2,3 **Angie Zhang**
CDE 1 **Paul B. Cesanek**
CDE 1 **Scott Beman**
CDE 1 **T. Daniel Harrison**

1 Department of Surgery, Lehigh Valley Health Network, Allentown, PA, U.S.A.
2 SELECT MD Program, Morsani College of Medicine, University of South Florida, Tampa, FL, U.S.A.
3 Lehigh Valley Health Network, Allentown, PA, U.S.A.

Corresponding Author: Rachel Appelbaum, e-mail: rachel.appelbaum@lvhn.org
Conflict of interest: None declared

Case series

Patient: Male, 55 • Female, 61 • Male, 41
Final Diagnosis: Metallic foreign body
Symptoms: Abdominal pain
Medication: —
Clinical Procedure: Diagnostic laparoscopy
Specialty: Surgery

Objective: Unusual clinical course





Background: Much of the medical literature regarding injury from the ingestion of wire bristles from grill brushes has been published only in the last decade. Grill brushes are often used to clean grills, and small wire bristles may break off of the brush during the scrubbing process and subsequently become embedded into food and are accidentally ingested. Fewer reports have been published on abdominal presentations with injuries past the gastroesophageal sphincter, yet perforation and subsequent need for operative management has been shown to be more prevalent in these types of cases.

Case Reports: Herein, we report on 3 unique cases of accidental ingestion of grill brush wire bristles. Case 1 involved a 55-year-old male who presented to the Emergency Department (ED) for evaluation after experiencing 2 days of abdominal pain while working in the yard. He was found to have a small bowel perforation secondary to a metallic foreign body. Case 2 involved a 61-year-old female who presented to the ED with gradual-onset, sharp epigastric pain radiating to her right side. She was found to have a fistula between her stomach and gallbladder secondary to a contained perforation with a metallic foreign body. Case 3 involved a 41-year-old male who presented to the ED after known ingestion of a grill brush bristle. He was found to have a small metallic foreign body protruding into the abdominal wall.

Conclusions: To avoid these injuries, there must be increased awareness among consumers, manufacturers, retailers, and medical professionals to promote prevention, timely diagnosis, and appropriate treatment.

MeSH Keywords: Abdominal Pain • Eating • Foreign Bodies

Full-text PDF: <https://www.amjcaserep.com/abstract/index/idArt/916268>

 1366  —  8  10



Background

Much of the medical literature regarding injury from the ingestion of wire bristles from grill brushes has been published only in the last decade [1]. During grill cleaning, small wire bristles may break off, become embedded into grilled food, and accidentally ingested. Although data from the Consumer Product Safety Commission's National Electronic Injury Surveillance System estimates that 1698 cases of grill brush wire injuries presented to an Emergency Department (ED) between 2002 and 2014, only 36 cases have been reported in the literature [2]. In the first known case, at Northwestern University in 1951, the foreign body was located just above the clavicle, causing concern for possible perforation of the esophagus [3]. Public awareness of the issue was increased in 2012 when the Centers of Disease Control and Prevention (CDC) published a 2-part report on 12 cases of bristle ingestion [4,5]. Given the insidious presentation and difficult visualization, physicians should be made aware of this issue to promote timely diagnosis and appropriate intervention.

Grill wire bristle ingestion has been reported as occurring in patients ranging from age 10 months to 92 years, with a mean age of 30 years and roughly equal incidence in males and females [1,2]. Common presenting symptoms after ingestion included sudden onset of dysphagia, odynophagia, throat pain, globus sensation, or abdominal pain [1,4,6,7]. The severity of injury ranged from puncture of the soft tissues of the neck to perforation of the gastrointestinal tract; treatment ranged from conservative management to surgical exploration and extraction [1,4]. Most cases pertained to upper aerodigestive tract presentations, with the oropharynx as the most common location [1–4,8,9]. Far fewer reports have been published on abdominal presentations with injuries past the gastroesophageal sphincter, yet perforation and subsequent need for operative management has been shown to be more prevalent in these types of cases [4,6,7,10]. Herein, we report on 3 cases of accidental ingestion of grill cleaning wire bristles with injury past the gastroesophageal sphincter.

Case Reports

Case #1

A 55-year-old male with a medical history of kidney stones and hyperlipidemia presented to the ED for evaluation after experiencing 2 days of abdominal pain while working in the yard. The pain, described as sharp and waxing and waning, began as periumbilical and progressed to radiation throughout the abdomen. The patient denied associated nausea, vomiting, or change in bowel movements. He additionally denied knowledge of ingesting a foreign body. He was afebrile, with vital

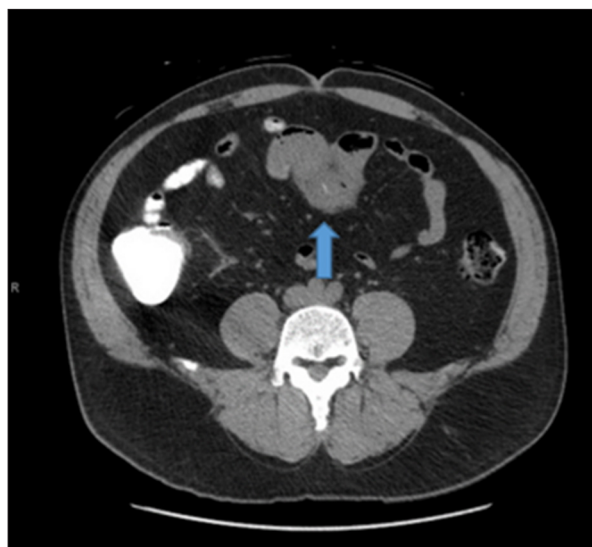


Figure 1. Case 1 – CT scan abdomen and pelvis demonstrating a metallic foreign body within the small bowel (blue arrow).

signs within normal limits. On physical exam, he was diffusely tender but did not have peritoneal signs. A computed tomography (CT) scan showed focal inflammation around a loop of the jejunum in the upper middle abdomen, with a small linear radio-opaque structure within the loop, concerning for a foreign body (Figure 1).

An exploratory laparoscopy found that a loop of the jejunum was severely inflamed (Figure 2A, 2B). The fibrinous outer layer was peeled back, revealing a metallic foreign body projecting out from the bowel wall (Figure 2C). This foreign body was removed (Figure 2D) and appeared to be a metal brush bristle (Figure 3). The enterotomy in the small bowel was repaired primarily. The patient's postoperative course was uneventful and he was discharged home on postoperative day 1.

Case #2

A 61-year-old female with a medical history of hypertension, irritable bowel syndrome, and gastroesophageal reflux disease presented to the ED with gradual-onset, sharp epigastric pain radiating to her right side, with nausea for 1 week. She denied any fevers, chills, vomiting, diarrhea, or change of appetite. Her surgical history included umbilical hernia repair and tubal ligation. The patient's vital signs were stable. Her physical exam was positive for tenderness to palpation in the right upper quadrant and epigastria. A CT scan of the abdomen and pelvis demonstrated a small metallic wire located between the distal stomach and gallbladder, surrounded by soft tissue inflammation. The patient was admitted for observation; managed with bowel rest, pain palliation, and intravenous hydration; and subsequently underwent an esophagogastroduodenoscopy, which

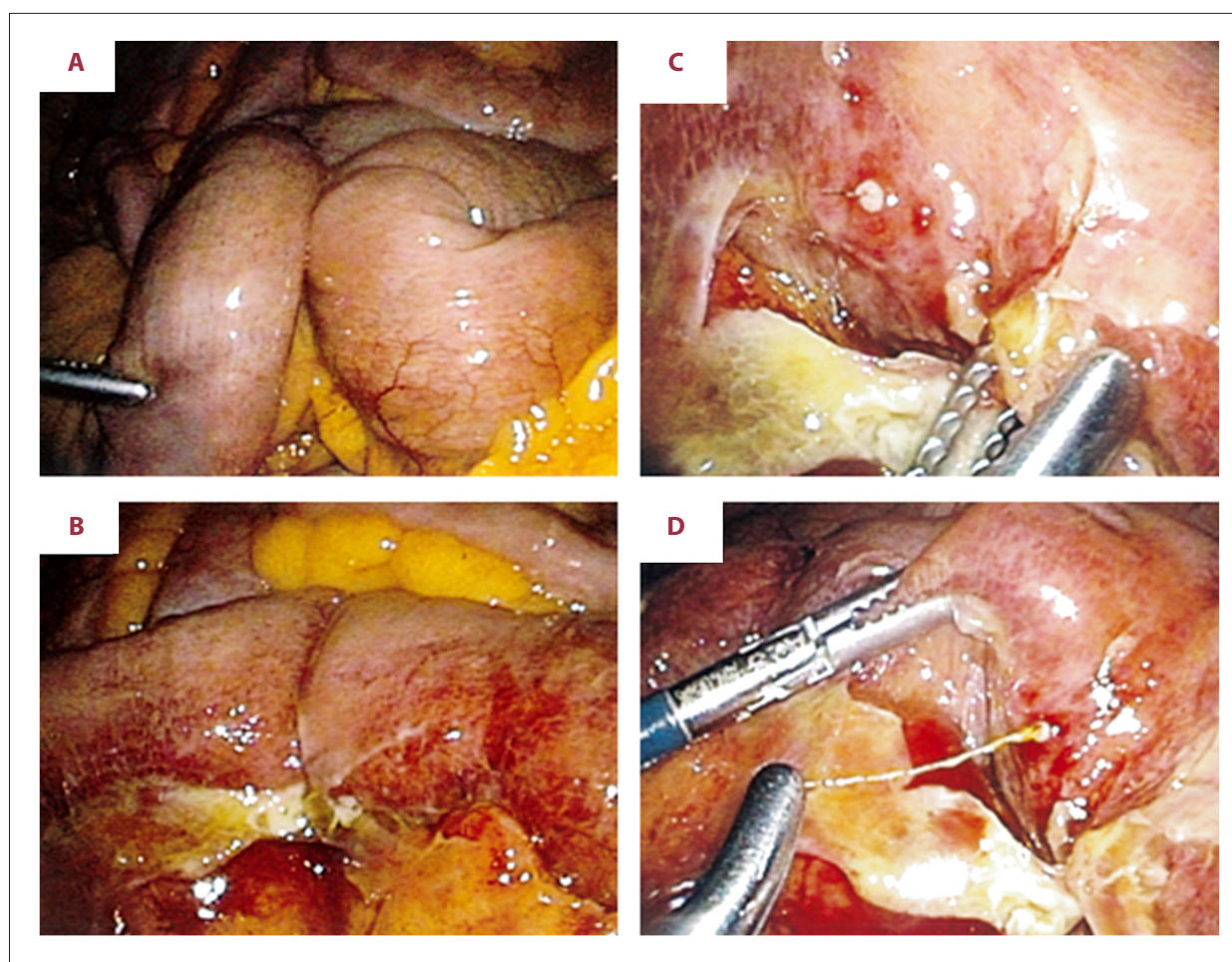


Figure 2. (A) Case 1 – Suspected area of perforation. (B) Case 1 – Inflamed small bowel with evidence of perforation. (C) Case 1 – Wire protruding through small bowel wall. (D) Case 1 – Removal of wire from small bowel.




Figure 3. Case 1 – Wire after removal from small bowel.

was unremarkable. She stayed in the hospital for 4 days, during which time her abdominal pain improved and nausea resolved. Her diet was advanced and the patient was discharged with instructions to follow up with outpatient general surgery.

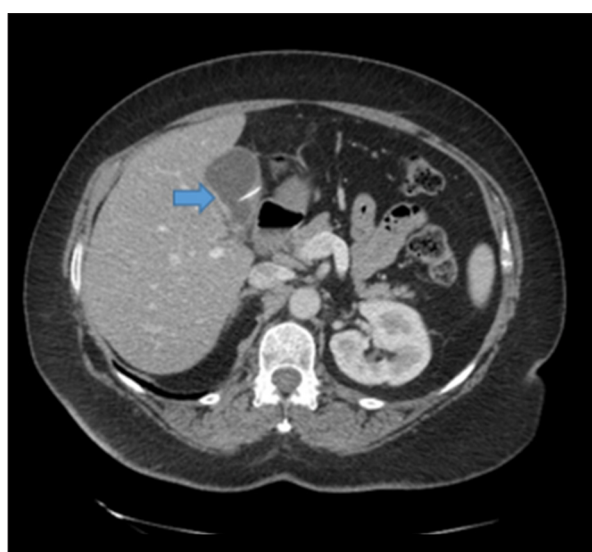


Figure 4. Case 2 – CT scan abdomen and pelvis demonstrating a metallic foreign body entering the gallbladder (blue arrow).

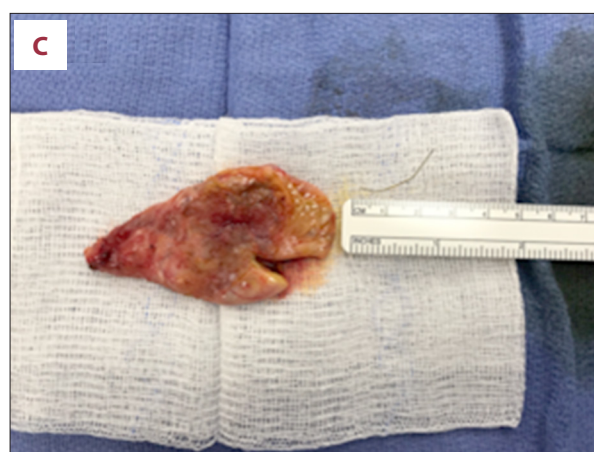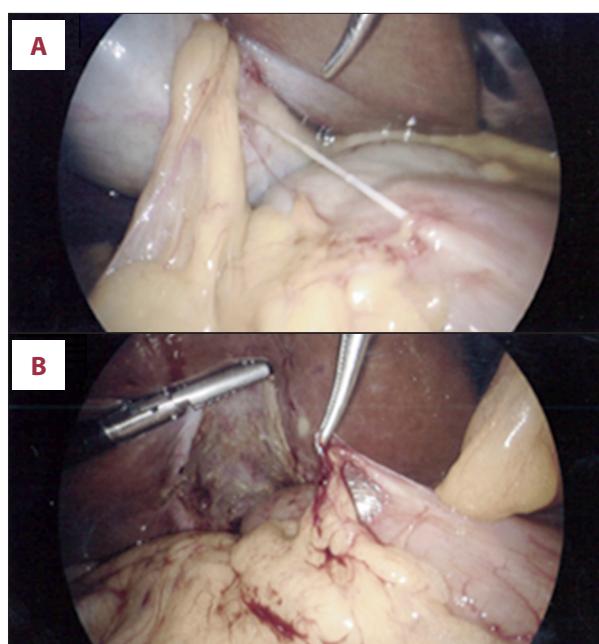


Figure 5. (A) Case 2 – Fistulous tract between the distal stomach and gallbladder. (B) Case 2 – Post gallbladder removal. (C) Case 2 – Metallic wire after removal from within the gallbladder wall.

At follow-up, the decision was made to repeat the CT, which revealed migration of the curvilinear foreign body between the gastric antrum and gallbladder towards the gallbladder (Figure 4). The metallic wire appeared to be embedded within the gallbladder wall. The patient was scheduled for a cholecystectomy. During the procedure, a thin fistulous tract from the distal stomach to the gallbladder wall was noted (Figure 5A). This tract was bluntly dissected off of the gallbladder wall and a clip was placed at the origin of the fistula tract on the stomach. The gallbladder was removed (Figure 5B) and opened on the surgical back table, revealing the presence of a thin metallic wire inside the specimen (Figure 5C). The patient's post-operative recovery was uneventful and she was discharged to home the same day.

Case #3

A 41-year-old male with a medical history of hypertension, hyperlipidemia, and cardiac arrhythmia presented to the ED after ingestion of a grill brush bristle. The patient recently had a barbecue and noted discomfort in his throat after eating a piece of grilled meat. A neck x-ray showed a small metallic wire (Figure 6). The Ear Nose and Throat specialist was consulted to attempt to remove this foreign body; however, it too small to visualize. It was thought to have passed into the gastric lumen. Next, Gastroenterology was consulted for possible evaluation and removal of the foreign body. An esophagogastroduodenoscopy was performed, but was unable to detect this foreign body. CT imaging was obtained, suggestive of a subtle extraluminal linear focus of high density in the left mesentery adjacent to a loop of small bowel as described, likely reflecting a retained metallic foreign body given the patient's

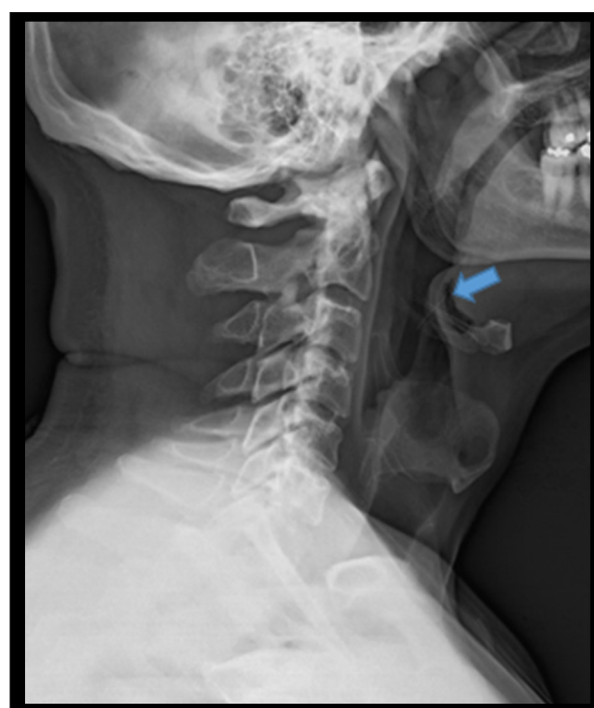

Figure 6. Case 3 – X-ray of the neck suggestive of a small metallic foreign body (blue arrow).

history (Figure 7). The patient was discharged home and informed to return for evaluation if abdominal pain developed. Several months later, the patient received an MRI for evaluation of shoulder pain. During the imaging, he developed acute abdominal discomfort and presented to the ED for re-evaluation. CT imaging suggested no evidence of intra-abdominal abscess with the presence of a thin linear metallic foreign body that migrated into the left upper quadrant omentum and abdominal wall, with mild surrounding inflammation (Figure 8).

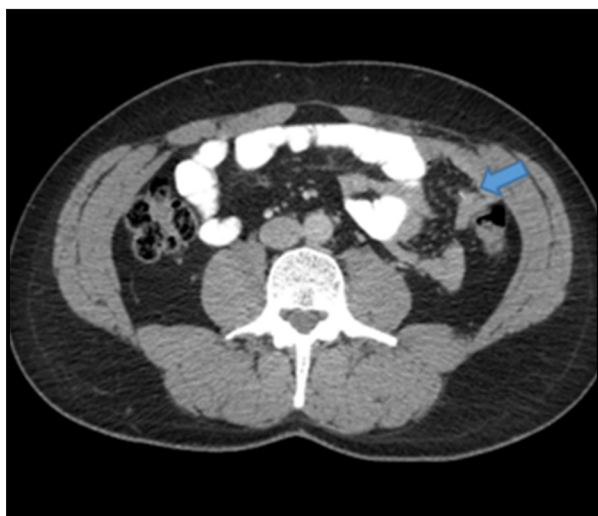

Figure 7. Case 3 – Subtle extraluminal linear focus of high density left mesentery adjacent to a loop of small bowel, likely reflecting a retained metallic foreign body (blue arrow).

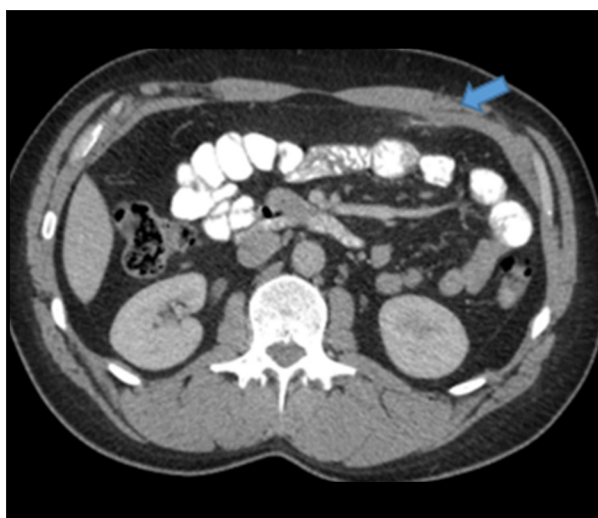

Figure 8. Case 3 – No evidence of intra-abdominal abscess. The thin, linear, metallic foreign body had migrated into the left upper quadrant omentum and abdominal wall, with mild surrounding inflammation (blue arrow).

The patient was taken to the OR for a diagnostic laparoscopy and removal of the foreign body. The omentum and anterior abdominal wall appeared bruised. A tiny metallic foreign body was protruding from the abdominal wall and was removed. The patient's postoperative course was uneventful.

Discussion

Ingestion of a foreign body should be in the differential when the onset, location, timing, course of pain, and a change from baseline are known. A provided history of ingested grilled food is valuable in making the correct diagnosis, but occasionally there is no such history given. In these cases, a CT scan was critical for diagnosing and locating small, thin, metallic objects. CT scans of the abdomen and pelvis should be performed without oral contrast, which can obscure the wire bristle [5]. Most notably, the foreign body is quite tiny; bristles are also thin and malleable, which can prevent a secure grip on the object. These features make wire bristles difficult to extract, leading to significant morbidity for the patient [9].

In light of the experience at our institution, we believe that accidental grill wire ingestion is more common than previously thought. To improve monitoring of this injury mechanism, medical professionals and consumers should report these injuries to the U.S. Consumer Product Safety Commission at <http://www.saferproducts.gov>. Recognizing ingestion of a grill brush wire should lead to prompt diagnosis and subsequent intervention.

Conclusions

Ingestion of grill wire bristles may be difficult to diagnose and manage, often leading to delayed intervention. If a small metallic foreign body consistent with a wire bristle is found incidentally post pyloric in the small or large intestine lumen and the patient is asymptomatic, clinical judgement should be used to determine if surgical or endoscopic removal is indicated. If the patient presents with symptoms or clinical signs of perforation with a wire bristle found post pyloric, surgical exploration should be considered.

References:

1. Wong S, Brook C, Grillone G: Management of wire brush bristle ingestion: review of literature and presentation of an algorithm. *Ann Otol Rhinol Laryngol*, 2016; 125: 160–64
2. Baugh TP, Hadley JB, Chang CW: Epidemiology of wire-bristle grill brush injury in the United States, 2002–2014. *Otolaryngol Head Neck Surg*, 2016; 154: 645–49
3. Ballenger J, Bennet R, Dorsey J: Perforation of esophagus by a wire bristle and its removal. *Q Bull Northwest Univ Med Sch*, 1952; 26: 309–11
4. Grand DJ, Eglin TK, Mayo-Smith WW et al: Injuries from ingesting wire bristles dislodged from grill-cleaning brushes – Providence, Rhode Island, 2009–2012. *J Safety Res*, 2012; 43: 413–15
5. Centers for Disease Control and Prevention: Injuries from ingestion of wire bristles from grill-cleaning brushes – Providence, Rhode Island, March 2011–June 2012. *MMWR Morb Mortal Wkly Rep*, 2012; 61: 490–92
6. Di Guglielmo M, Savage J, Gould S, Murphy S: Female adolescent presenting with abdominal pain: Accidental wire bristle ingestion leading to colonic perforation. *Pediatr Emerg Care*, 2017; 33: 356–58

7. Van Ness-Otunnu R, Foster JT, Hack JB: Male with left lower quadrant abdominal pain. Swallowed wire brush bristle foreign body resulting in small bowel perforation. *Ann Emerg Med*, 2012; 59: e11–12
8. Harlor EJ, Lindemann TL, Kennedy TL: Outdoor grilling hazard: Wire bristle esophageal foreign body – a report of six cases. *Laryngoscope*, 2012; 122: 2216–18
9. McMullen CP, Frank DK, Smith LP: Backyard hazard: A case series of ingested grill brush bristles and a novel approach to extraction. *Am J Otolaryngol*, 2012; 33: 731–34
10. Sharma A, Groblewski JC, Flis D: In reference to wire grill brush bristle as an unusual foreign body: Report of two pediatric cases. *Laryngoscope*, 2013; 123: 551