

Loss of Guide Wire: A Lesson Learnt Review of Literature

Rajiv Srivastav, Vishal Yadav¹, Dimpay Sharma¹, Vikas Yadav²

Departments of Cardio Vascular Thoracic Surgery and
¹Surgery, MGM Medical College, Navi Mumbai, ²Department
of Orthopaedics, Sidharth Hospital, Goregoan, Mumbai,
Maharashtra, India

INTRODUCTION

Central venous catheterization is a routine technique in emergency department and intensive care unit. Central venous catheters (CVCs) are needed for monitoring patients in special conditions and as a route for parenteral nutrition. Depending on the catheter type, cannulation is performed at different sites such as the jugular, subclavian, femoral, and brachial veins. Complications associated with the CVCs are infection, failure to place the catheter, arterial puncture, improper catheter position, pneumothorax, hematoma, hemothorax, asystolic cardiac arrest of unknown etiology, and inferior vena cava (IVC) trauma.^[1] Infection is the most common complication in subclavian vein route; though arrhythmias and air embolism can occur.^[2] These complications occur in about 12% of cases.^[2,3] One of these extremely rare complications is intravascular loss of a guide wire, which is usually recognized immediately or sometimes with delay.^[2-5] Here, we elucidate a case of retained guide wire during cannulation of the right external iliac vein, which was successfully treated with exploration of right iliac vessels.

CASE REPORT

A 60-year-old woman presented to the emergency department with complaints of generalized abdominal pain, constipation, and fever. Patient was hospitalized

Access this article online

Quick Response Code:



Website:

www.jstcr.org

DOI:

10.4103/2006-8808.128732

Address for correspondence: Dr. Vishal Yadav,
103/A Sani Apartment, S. V. Road, Mumbai - 400 102,
Maharashtra, India. E-mail: vish_yad_123@yahoo.co.in

ABSTRACT

Catheterization of central veins is a routine technique which is widely used in emergency department and medical intensive care units. Seldinger's technique is widely used to place central venous and arterial catheters and is generally considered safe. The technique does have multiple potential risks. Guide wire-related complications are rare but potentially serious. We describe a case of a lost guide wire during central venous catheter (CVC) insertion followed by a review of the literature of this topic. Measures which can be taken to prevent such complications are explained in detail as well as recommended steps to remedy errors should they occur.

Key words: Catheterization central venous, catheters, complications, surgical procedures

with primary diagnosis of intestinal obstruction. Due to patient's history of heart disease, the central venous catheterization was done for fluid resuscitation via the right internal jugular (IJ) vein using the Seldinger technique. The catheter was inserted by a 1st-year surgical resident with no supervision by senior residents. No complications or difficulties in cannulation were reported; back flow was also normal. The catheter tray was checked for the guide wire after the procedure which was missing. After the patient was stabilized, she underwent chest X-ray, plain abdominal radiography, and ultrasonography and the patient was admitted in surgical intensive care unit. Resident noticed the guide wire in chest and abdominal radiographs. The radiographs showed that the catheter had entered in the IVC via the right IJ vein and then, had remained in the right iliac vein at the point of bifurcation into the internal and external iliac veins [Figures 1 and 2]. Based on the consultation with the vascular surgeons and radiologists, the patient underwent exploration of right iliac vein. The method was successful and the retained guide wire was removed from right external iliac vein. The procedure was successful and intestinal obstruction was managed conservatively. Her hospital stay was uneventful.

DISCUSSION

Central venous catheterization has many complications such as infection, failure to place the catheter, arterial puncture, improper catheter position, pneumothorax, and hematoma.^[1,2] This study reports a case of retained

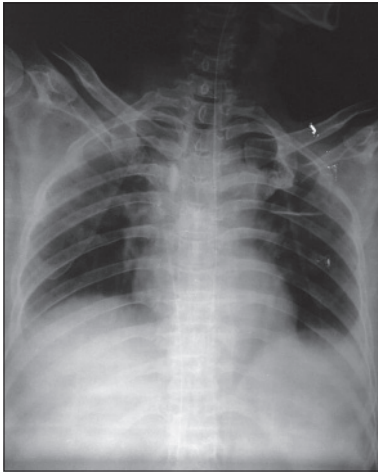


Figure 1: Chest X-ray showing guide wire of catheter had entered in the inferior vena cava (IVC) via the right internal jugular vein

guide wire and its treatment. In our case, the catheter was retained in the right iliac vein at the point of bifurcation. An important point in preventing this rare complication is that the guide wire should be held at least 18 cm distant from the vein.^[3,5] If this rule is followed, the guide wire cannot get lost.

The diagnosis is very simple, which is often established incidentally during routine radiographic exams.^[4,5]

We report the unnoticed intravascular insertion of a complete guide wire. This is a rare and completely avoidable complication of central venous catheterization. The guide wire should be held at the tip at all times to prevent passage into or out of the vessel. If this rule is followed, the guide wire cannot get lost. Predisposing factors for an intravascular placement of the guide wire include:

- Inattention
- Inexperienced operator- either in method (i.e. Seldinger technique) or actually central venous cannulation
- Inadequate supervision of trainees
- Overtired staff.

The signs of guide wire loss include:

- The guide wire is missing
- Resistance to injection via the distal lumen
- Poor venous backflow from the distal lumen
- Guide wire is visible on a radiograph.

The most commonly reported guide wire related complications are listed and will be discussed below.

- Cardiac dysrhythmias
- Cardiac conduction abnormalities
- Perforation of vessels or heart chamber
- Kinking, looping, or knotting of wire
- Entanglement of previously placed intravascular devices

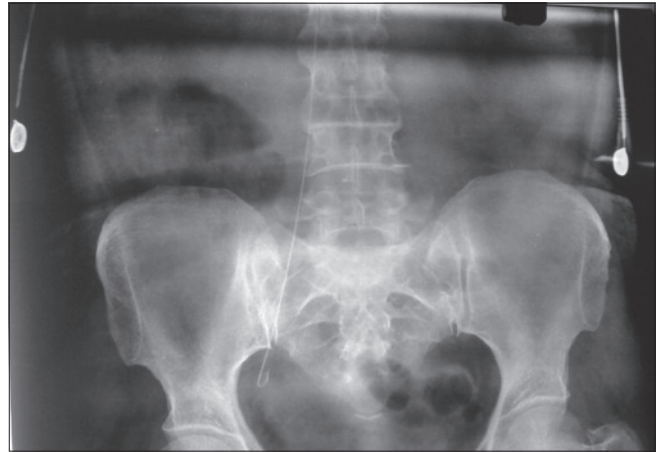


Figure 2: X-ray pelvis showing guide wire catheter had remained in the right iliac vein at the point of bifurcation into the internal and external iliac veins

- Breakage of the distal tip of the guide wire with subsequent embolization
- Complete loss of guide wire within the vascular system.

Cardiac dysrhythmias most often premature atrial or ventricular contractions are occasionally reported during subclavian or IJ CVC insertion.^[6] The arrhythmias are typically short lived, resulting from the guide wire touching the endocardium, and resolve when the tip is pulled back a few centimeters.^[6]

The most common cardiac conduction abnormalities seen during CVC placement are right bundle branch blocks, new left anterior and posterior fascicular blocks, and rarely asystole.^[7] The cause of these conduction problems, as described in the case of cardiac dysrhythmias, is also the overzealous advancement of the guide wire. The ease with which a right bundle branch block can be induced is probably related to the bundle branch's superficial position in the right ventricular endocardium, just inferior to the tricuspid valve.^[7] Conduction abnormalities are usually transient and may go unnoticed. However, in a patient with an underlying left bundle branch block, the induction of further conduction defects may lead to a life-threatening complete heart block requiring temporary pacing.^[7] The mentioned arrhythmias and conduction problems are essentially avoidable during central venous catheterization since placement should not involve entry into the heart by the guide wire or by the subsequently placed catheter.^[7]

Perforation of central veins or right-sided cardiac chambers can be catastrophic. In clinical practice, it is often difficult to ascertain what caused the venous perforation; the introducer needle, the guide wire, or the dilator. Nevertheless, the literature reports cases of guide

wire related perforation of the great vessels including the brachiocephalic and subclavian veins.^[8] This important complication occurs when excessive force is applied against resistance when introducing the guide wire, especially if the straight or angle tip wire, rather than J-tip style wire, is used. In most instances, bleeding from a small penetrating hole in a vein will stop spontaneously by vasospasm or by external compression of the surrounding tissues.^[8] However, serious cases of hemothorax, including fatalities, due to the above complication have been reported.^[8] Making a timely diagnosis in such cases requires maintaining a high index of suspicion when there is an unexplained drop in hemoglobin or the development of unilateral pleural effusion ipsilateral to a recently placed or attempted central venous catheterization. Treatment of a serious perforation may necessitate the insertion of a chest tube or an emergent thoracotomy.^[8]

Perforation of the heart may occur at the time of catheter insertion or any time the catheter tip is placed within the heart chambers.^[8] There are at least two reported cases in the literature of heart perforation attributed to the guide wire itself. Both of these complications occurred during the insertion of HD catheters: The first during a subclavian approach leading to a life-threatening cardiac tamponade and the second during an IJ approach leading to a fatal tamponade.^[9,10] Cardiac tamponade usually results from perforation of the right atrium, or less frequently, the right ventricle. Tamponade has also been reported after superior vena cava (SVC) perforation within the pericardium.^[10] The possibility of tamponade should be considered when a patient collapses during, or shortly after placement of a CVC. Other diagnoses to consider in that scenario include tension pneumothorax and air embolism. An emergent chest X-ray or bedside echocardiogram followed by pericardiocentesis can be life-saving in such situations.

Another occasional guide wire complication is kinking or looping of the wire itself. Applying force to thread a guide wire through the introducer needle despite significant resistance is likely to cause such a problem.^[11] Kinking can also result if the dilator is forced in a direction that diverges from the original path of the wire.^[11] If a clinician does not recognize this scenario there is potential for cutting through the vein with possible fatal complications.^[12] This type of complication can be avoided by intermittently moving the wire gently in and out as the dilator is being advanced through the subcutaneous tissue. Application of increasing force after looping or kinking sometimes results in knot formation. Both intravascular as well as extravascular knotting have been reported.^[11] It is almost

exclusively described following the subclavian approach which may be due to the curved path the vein takes as it loops over the first rib to descend into the SVC.^[11] This complication should be suspected when the guide wire cannot be pulled out after successful catheter insertion. In this situation, no force should be used to pull the catheter and wire out, and an immediate X-ray should be ordered. Once the diagnosis is established, interventional radiology should be consulted, and sometimes surgical intervention is necessary.

Entanglement of a guide wire with an existing intravascular apparatus is another reported complication of CVC placement. Special attention is needed in patients with IVC filters since there have been numerous reports of entrapment of guide wires in these filters.^[13] It results from over advancement of the guide wire leading to hooking of the J-tip to the filter. Interestingly, IVC filter entrapment with straight guide wires has not been reported.^[13] This complication should be suspected when the guide wire cannot be retrieved after catheter placement in a patient with an IVC filter already deployed. In such circumstances, no excessive force should be used to free the wire since this could lead to filter dislodgment and cava perforation.^[14] X-ray or examination under fluoroscopy should be ordered promptly followed by interventional radiology consultation once the diagnosis is made.

Tip breakage of a guide wire has been blamed on inherent design flaws.^[15] Shearing and breakage of the wire usually results from pulling the wire back through the needle after it has passed the bevel.^[11] Hence, if a guide wire fails to pass freely from the introducer needle into the vessel, the careful retraction of the wire through the needle is an option, but it is much safer to withdraw the wire and needle as a single unit.

The inadvertent intravascular insertion of the entire guide wire, as in our case, is a completely avoidable complication.^[5] Although the loss of a complete guide wire might cause arrhythmias, vascular damage, and thrombosis; it is usually asymptomatic and is often incidentally found on a routine X-ray done up to several months after the procedure.^[16] Holding on to the proximal tip of the wire at all times is fundamental in preventing this mistake. If this complication happens, use of interventional radiology techniques is the preferred method for retrieval and removal.^[5]

Interventional radiology is the method of choice. With modern devices a lost catheter, guide wire fragment, or

entire guide wire should be possible to be removed in most cases. During the intervention the patient should be heparinized.^[17] Usually, the foreign body (e.g. guide wire) is caught by a gooseneck snare passed via the femoral vein using radiographic control. The use of endovascular forceps or a Dormier basket increases the risk of endovascular trauma.^[17] If the foreign body is captured, it is usually necessary to remove it along with the vascular sheath. If the vascular sheath is twice the size of the lost catheter or the lost guide wire may be possible to withdraw the foreign body through it.^[17] If heparinization is contraindicated, extraction should be attempted by careful surgical exploration.

CONCLUSION

During central venous catheterization, guide wire-related complications are uncommon and essentially preventable. The following precautions should be taken:

- Inspect the wire for defects before insertion
- Consider a guide wire to be a delicate and fragile instrument
- When resistance to insertion is met, remove and inspect the wire for damage, reposition the introducer so that no resistance to its passage is felt
- Particular caution should be used when attempting central catheter placement in patients who are predisposed to thrombosis or have had repeated catheterizations of a particular vessel
- If multiple manipulations are needed, reinspect the wire and replace it if necessary
- Pass catheter over wire into the vein
- Make sure that the wire is visible at the proximal end, before the catheter is advanced
- The catheter should be 'railroaded' over the guide wire into the vein, holding the wire, and not pushing catheter and wire together into the vein
- Always inspect the wire for complete removal at the end of the procedure^[18]
- Hold onto the wire at all times until removal from the vessel.

REFERENCES

1. Wolf F, Scherthaner RE, Dirisamer A, Schoder M, Funovics M, Kettenbach J, *et al.* Endovascular management of lost or mis-placed intravascular objects: Experiences of 12 years. *Cardiovasc Intervent Radiol* 2008;31:563-8.
2. Abuhasna S, Abdallah D, Ur Rahman M. The forgotten guide wire: A rare complication of hemodialysis catheter insertion. *J Clin Imaging Sci* 2011;1:40.
3. Brunicaudi F, Brandt M, Andersen D, Billiar T, Dunn D, Hunter J, *et al.* Schwartz's Principles of Surgery. New York: McGraw-Hill Prof Med/Tech; 2010. p. 314-42.
4. Guo H, Peng F, Ueda T. Loss of the guide wire: A case report. *Circ J* 2006;70:1520-2.
5. Schummer W, Schummer C, Gaser E, Bartunek R. Loss of the guide wire: Mishap or blunder? *Br J Anaesth* 2002;88:144-6.
6. Stuart RK, Shiroka SA, Akerman P, Lowell JA, Baxter JK, Apovian C, *et al.* Incidence of arrhythmia with central venous catheter insertion and exchange. *J Parent Enteral Nutr* 1990;14:152-5.
7. Eissa NT, Kvetan V. Guide wire as a cause of complete heart block in patients with preexisting left bundle branch block. *Anesthesiol* 1990;73:772-4.
8. Innami Y, Oyaizu T, Ouchi T, Umemura N, Koitabashi T. Life-threatening hemothorax resulting from right brachiocephalic vein perforation during right internal jugular vein catheterization. *J Anesth* 2009;23:135-8.
9. Cavatorta F, Campisi S, Fiorini F. Fatal pericardial tamponade by a guide wire during jugular catheter insertion. *Nephron* 1998;79:352.
10. Blake PG, Uldall R. Cardiac perforation by a guide wire during subclavian catheter insertion. *Int J Artif Organs* 1989;12:111-3.
11. Khan KZ, Graham D, Ermenyi A, Pillay WR. Case report: Managing a knotted Seldinger wire in the subclavian vein during central venous cannulation. *Can J Anesth* 2007;54:375-9.
12. Jankovic Z, Boon A, Prasad R. Fatal haemothorax following large-bore percutaneous cannulation before liver transplantation. *Br J Anaesth* 2005;95:472-6.
13. Vines FY, Robb TV, Alapati K. J-tip spring guidewire entrapment by an inferior vena cava filter. *J Am Osteopath Assoc* 2004;104:87-9.
14. Nanda S, Strockoz-Scaff L. Images in clinical medicine. A complication of central venous catheterization. *N Engl J Med* 2007;356:e22.
15. Monaca E, Trojan S, Lynch J, Doehn M, Wappler F. Broken guide wire: A fault of design? *Can J Anesth* 2005;52:801-4.
16. Auweiler M, Kampe S, Zähringer M. The human error: Delayed diagnosis of intravascular loss of guidewires for central venous catheterization. *J Clin Anesth* 2005;17:562-4.
17. Kessel D, Robertson I. *Interventional radiology-A survival guide*. London: Churchill-Livingstone; 2000. p. 225-9.
18. Schwartz AJ, Horrow JC, Jobs DR, Ellison N. Guide wires-a caution. *Crit Care Med* 1981;9:347-8.

How to cite this article: Srivastav R, Yadav V, Sharma D, Yadav V. Loss of guide wire: A lesson learnt review of literature. *J Surg Tech Case Report* 2013;5:78-81.

Source of Support: Nil, **Conflict of Interest:** None declared.