

Received: 2011.08.01
Accepted: 2011.09.15
Published: 2012.03.01

The normal growth of the common iliac arteries in human fetuses – an anatomical, digital and statistical study

Authors' Contribution:

- A** Study Design
- B** Data Collection
- C** Statistical Analysis
- D** Data Interpretation
- E** Manuscript Preparation
- F** Literature Search
- G** Funds Collection

Michał Szpinda^{1ABCDEF}, Anna Szpinda^{1GDE}, Alina Woźniak^{2GD},
Marcin Daroszewski^{1D}, Celestyna Miła-Kierzenkowska^{2DE}

¹ Department of Normal Anatomy, Ludwik Rydygier Collegium Medicum in Bydgoszcz, The Nicolaus Copernicus University in Torun, Bydgoszcz, Poland

² Department of Medical Biology, Ludwik Rydygier Collegium Medicum in Bydgoszcz, Nicolaus Copernicus University in Torun, Bydgoszcz, Poland

Source of support: Departmental sources

Summary

Background:

The present study was carried out to compile normative data for dimensions of the common iliac arteries at varying gestational ages.

Material/Methods:

We used anatomical dissection, digital-image analysis (system of Leica QWin Pro 16) and statistical analysis (Student T test, one-way ANOVA, post-hoc RIR Tukey test, and regression analysis) to examine the increase in length (mm), proximal external diameter (mm), and volume (mm³) of the common iliac arteries in 124 (60 males, 64 females) spontaneously aborted human fetuses aged 15–34 weeks.

Results:

Neither sex nor right-left significant differences were found ($P > 0.05$). The length ranged from 4.76 ± 1.05 to 15.38 ± 1.60 mm on the right, and from 4.92 ± 1.33 to 14.91 ± 1.25 mm on the left, according to the linear functions $y = -3.598 + 0.585 \times \text{Age} \pm 1.522$ ($R^2 = 0.83$) and $y = -3.107 + 0.554 \times \text{Age} \pm 1.444$ ($R^2 = 0.83$). The proximal external diameter increased from 0.66 ± 0.19 to 2.30 ± 0.42 mm on the right, and from 0.66 ± 0.14 to 2.16 ± 0.42 mm on the left, according to the quadratic models $y = 1.392 - 0.110 \times \text{Age} + 0.004 \times \text{Age}^2 \pm 0.285$ ($R^2 = 0.77$) and $y = 1.283 - 0.099 \times \text{Age} + 0.004 \times \text{Age}^2 \pm 0.238$ ($R^2 = 0.81$). The volumes were increasing from 1.93 ± 1.74 to 66.95 ± 29.31 mm³ on the right, and from 1.91 ± 1.65 to 56.86 ± 25.17 mm³ on the left, given by the quadratic functions: $y = 99.69 - 10.60 \times \text{Age} + 0.287 \times \text{Age}^2 \pm 14.40$ ($R^2 = 0.67$) and $y = 82.62 - 8.86 \times \text{Age} + 0.242 \times \text{Age}^2 \pm 11.60$ ($R^2 = 0.71$).

Conclusions:

The common iliac arteries grow linearly in length, and parabolically in both diameter and volume. The right common iliac artery constitutes a predominant vessel in relation to its length, external diameter and volume. The morphometric data on the common iliac arteries may serve as a useful reference in the prenatal diagnosis and monitoring of congenital aorto-iliac abnormalities.

key words:

common iliac artery • length • external diameter • volume • digital-image analysis • regression analysis

Full-text PDF:

<http://www.medscimonit.com/fulltxt.php?ICID=882516>

Word count:

3198

Tables:

3

Figures:

5

References:

30

Author's address:

Michał Szpinda, Department of Normal Anatomy, Ludwik Rydygier Collegium Medicum, Karłowicza 24 St., Bydgoszcz 85-092, Poland, e-mail: kizanat@cm.umk.pl

BACKGROUND

The common iliac arteries start from the aortic bifurcation and terminate by dividing into the external and internal iliac arteries (Figure 1). The length of the common iliac artery constitutes the distance between its more variable origin and its more stable termination [1–3]. It is of note that these 2 points indicate an age-related shift in relation to the spine. During prenatal life, both the origin and termination of the common iliac arteries apparently ascend in relation to the spine (pseudoascensus) [4]. On the contrary, in adults the aortic bifurcation undergoes a downward shift (pseudodescensus) due to osteoporosis of the vertebrae, degenerative changes of the intervertebral discs, and reduction in the length of the spine [5,6]. In adults the left common iliac artery is shorter than the right one, because it begins on the left side of vertebra L4 [1,3].

The common iliac arteries develop from proximal segments of the primary umbilical arteries [6], in direct extension of the dorsal aortas. As reported by Mansfield and Howard [7], in case of complete absence of the common iliac arteries, the abdominal aorta is divided directly into 4 branches: the 2 internal and the 2 external iliac arteries. Llauger et al. [8] presented aplasia of the right common iliac artery in an asymptomatic patient, in whom both the right pelvis and lower limb were supplied by an anomalous branch from the left internal iliac artery. Some authors therefore [9,10] argued that congenital absence of the common iliac arteries should be included in the differential diagnosis for intermittent claudication of the legs (Leriche syndrome).

Advances in perinatal medicine have required an extensive knowledge of fetal aorto-iliac quantitative morphology. The normative morphometric data of the common iliac arteries in human fetuses may be useful as a reference for future Doppler studies in the prenatal diagnosis and monitoring of congenital abnormalities (aneurysms, idiopathic infantile arterial calcification) that include discordant diameters of the aorta and its branches [11–14]. Although morphometric values of the common iliac arteries in human fetuses have been presented by Gościcka et al. [3], and Özgüner and Sulak [15], to date, growth curves for the common iliac artery dimensions have not been reported in the professional literature. Because of this, in the present study we aimed to determine:

- age-specific reference intervals for length, external diameter and volume of the 2 common iliac arteries at varying gestational age, and
- the normal growth curves for each morphometric feature.

MATERIAL AND METHODS

The examinations were carried out on 124 human fetuses of both sexes (60 males, 64 females) derived from spontaneous abortions or stillbirths in the years 1989–2001. All the fetuses collected in our Department had Caucasian racial origin. Legal and ethical considerations had been approved by the University Research Ethics Committee (KB/217/2006). On macroscopic examination, both internal and external anatomical malformations were ruled out in all the included specimens, which were diagnosed as normal. In no case was the cause of fetal death related to congenital cardiovascular

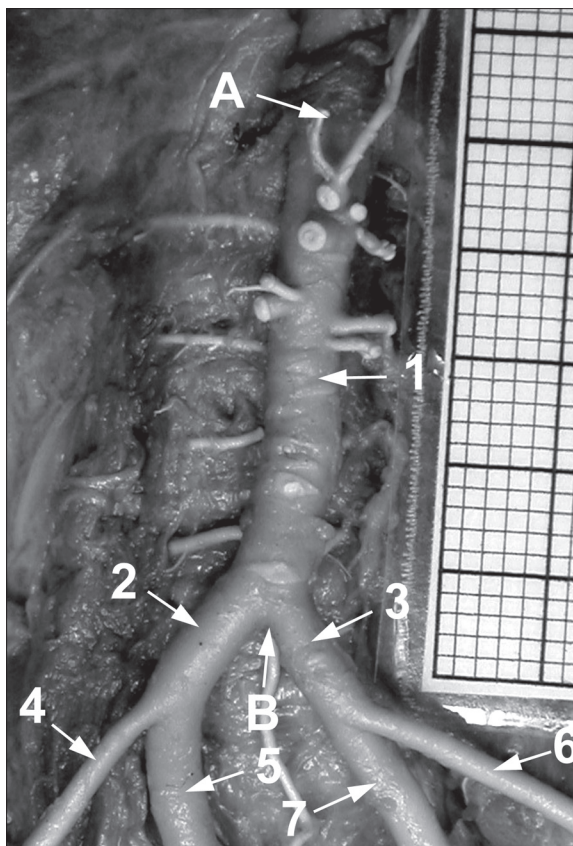


Figure 1. The abdominal aorta and common iliac arteries in a female fetus aged 25 weeks: A – aortic hiatus of the diaphragm, B – aortic bifurcation, 1 – abdominal aorta, 2 – right common iliac artery, 3 – left common iliac artery, 4 – right external iliac artery, 5 – right internal iliac artery, 6 – left external iliac artery, 7 – left internal iliac artery.

or non-cardiovascular anomalies. The sample included fetuses which were the outcome of causes of intra-uterine growth restriction. The gestational age varied from 15 to 34 weeks (Table 1). Gestational ages were determined from measurements of the crown-rump length on the basis of Iffy tables [16]. For statistical analysis, the fetuses were divided into 6 monthly groups, related to the 4th–9th months of gestation.

The arterial bed was filled with white latex LBS 3060 through a catheter Stericath (diameter of 0.5–1 mm), which was introduced by lumbar access into the abdominal aorta. The fetal arteries were filled under a controlled pressure of 50–60 mm Hg, using a syringe infusion pump SEP 11S (Ascor SA, Medical Equipment, Warsaw 2001). All specimens were immersed in 10% neutral buffered formalin solution for 4–24 months for preservation, and then dissected under 10-fold magnification using a stereoscope with Huygens ocular. In each fetus, the dissected common iliac arteries *in situ* with a millimeter scale were placed vertically to the optical lens axis, then recorded using a camera (Nikon Coolpix 8400), and digitalized to TIFF images (Figure 1). Next, digital pictures of the common iliac arteries were assessed by 1 researcher using digital image analysis (Leica QWin Pro 16, Cambridge), which semi-automatically estimated length, external diameter and volume of the marked common iliac arteries. Each measurement was performed 3 times and



Table 1. Distribution of fetuses studied.

Fetal age		Crown-rump length (mm)				Number	Sex	
Months	Weeks (Hbd-life)	Mean	SD	Min	Max		Male	Female
4	15	89.4	6.1	85.0	92.0	9	4	5
	16	103.7	6.1	95.0	106.0	7	3	4
	17	114.9	8.2	111.0	121.0	5	3	2
5	18	129.3	6.6	124.0	134.0	8	3	5
	19	142.7	7.7	139.0	148.0	9	5	4
	20	155.3	5.8	153.0	161.0	2	0	2
	21	167.1	4.7	165.0	173.0	3	2	1
6	22	178.1	6.9	176.0	186.0	7	4	3
	23	192.3	6.3	187.0	196.0	9	4	5
	24	202.9	5.7	199.0	207.0	11	6	5
	25	215.2	4.8	211.0	218.0	7	5	2
7	26	224.7	5.2	220.0	227.0	7	4	3
	27	234.1	4.3	231.0	237.0	4	0	4
	28	244.2	5.1	240.0	246.0	4	2	2
	29	253.8	4.5	249.0	255.0	6	1	5
8	30	262.7	3.1	260.0	264.0	6	3	3
	31	270.7	5.2	268.0	275.0	4	1	3
	32	281.4	3.7	279.0	284.0	5	4	1
9	33	290.3	6.1	286.0	293.0	7	4	3
	34	301.4	3.2	296.0	302.0	4	2	2
Total						124	60	64

the mean of them was then used. Briefly, measurements of the parameters examined were derived by assuming that the filled common iliac arteries constituted a flexible cylinder. Diameter measurements were derived by assuming that the filled vessels were circular in cross-section [3,17]. In order to calculate the arterial volume from a 2D image, it was assumed that each vessel of varying diameter can be divided into a large number of small irregular cylinders [17–19] with both varying diameter (d) and height (h). Their volumes could be described by the following equation:

$$V = \pi d^2 h / 4$$

(V – volume, $\pi \approx 3.14$, d – average cylinder diameter, h – average cylinder height). The sum of the volumes of such cylinders approximating the vessel was given in mm³ as the common iliac artery volume. The common iliac artery length constituted the length of the flexible cylinder axis.

For each fetus, on both sides, the 3 following parameters of the common iliac artery were assessed:

- length in mm – distance between the aortic bifurcation and the common iliac artery bifurcation,
- proximal external diameter in mm - immediately below the aortic bifurcation, and
- volume in mm³.

The length, proximal external diameter and volume of the common iliac arteries were correlated to fetal age so as to establish their growth. The relative growth of the common iliac arteries was expressed as the length-to-proximal external diameter ratio. As the first step in the statistical analysis, Student's T test was used to examine the influence of sex on the values of the parameters studied. The morphometric results were evaluated by one-way ANOVA test for unpaired data and post-hoc RIR Tukey test.

Regression analysis was used to derive the line of best fit for each morphometric feature of the common iliac arteries and gestational age. Coefficients of determination (R²) between the parameters and fetal age were estimated. Differences were considered significant at P<0.05.

Table 2. Block scheme of the statistical analysis of absolute values of the right common iliac artery parameters.

Fetal age [months]	n=124	Length [mm] (mean ±SD)	Proximal external diameter [mm] (mean ±SD)	Volume [mm ³] (mean ±SD)
4	16	4.76±1.05 ↓ (P<0.01)	0.66±0.19 ↓ (P>0.05)	1.93±1.74 ↓ (P>0.05)
5	24	7.34±1.54 ↓ (P<0.01)	0.81±0.25 ↓ (P<0.05)	4.61±3.78 ↓ (P<0.05)
6	30	10.33±1.63 ↓ (P>0.05)	1.04±0.23 ↓ (P<0.05)	9.75±6.65 ↓ (P<0.05)
7	22	11.59±2.02 ↓ (P<0.001)	1.29±0.30 ↓ (P<0.01)	16.47±11.56 ↓ (P<0.001)
8	21	14.14±1.79 ↓ (P>0.05)	1.86±0.47 ↓ (P<0.01)	42.46±27.68 ↓ (P<0.001)
9	11	15.38±1.60	2.30±0.42	66.95±29.31

Table 3. Block scheme of the statistical analysis of absolute values of the left common iliac artery parameters.

Fetal age [month]	n=124	Length [mm] (mean ±SD)	Proximal external diameter [mm] (mean ±SD)	Volume [mm ³] (mean ±SD)
4	16	4.92±1.33 ↓ (P<0.01)	0.66±0.14 ↓ (P>0.05)	1.91±1.65 ↓ (P>0.05)
5	24	7.26±1.62 ↓ (P<0.01)	0.76±0.17 ↓ (P<0.01)	3.67±2.61 ↓ (P<0.05)
6	30	9.89±1.44 ↓ (P<0.01)	0.99±0.14 ↓ (P<0.001)	7.95±3.35 ↓ (P<0.01)
7	22	11.29±1.84 ↓ (P<0.05)	1.29±0.27 ↓ (P<0.01)	15.97±9.17 ↓ (P<0.001)
8	21	13.78±1.68 ↓ (P>0.05)	1.79±0.42 ↓ (P<0.01)	37.34±22.72 ↓ (P<0.001)
9	11	14.91±1.25	2.16±0.42	56.86±25.17

RESULTS

No significant differences were found in the values of morphometric parameters of the common iliac arteries according to sex ($P>0.05$). Therefore, the values obtained for the right (Table 2) and left (Table 3) common iliac arteries have been summarized without regard to sex. By contrast, there were significant correlations between all the parameters studied and gestational age ($P=0.0000$). Although the right-left differences for the whole group were not found to be statistically significant ($P>0.05$), the results for each common iliac artery are presented separately because of their great inter-individual variability (Tables 2 and 3) and a strong trend towards greater values on the right side.

The values of the common iliac artery length increased from 4.76 ± 1.05 to 15.38 ± 1.60 mm on the right, and from 4.92 ± 1.33 to 14.91 ± 1.25 mm on the left for the 4-month group and 9-month group of gestation, respectively. In 75 (60.5%) specimens the individual values of the common iliac artery length were greater on the right side. With regard

to fetal age, the lengths of the right (Figure 2A) and left (Figure 2B) common iliac arteries increased according to the linear functions: $y=-3.598+0.585\times\text{Age}\pm 1.522$ ($R^2=0.83$) and $y=-3.107+0.554\times\text{Age}\pm 1.444$ ($R^2=0.83$), respectively.

The proximal external diameter of the common iliac artery took the values from 0.66 ± 0.19 to 2.30 ± 0.42 mm on the right, and from 0.66 ± 0.14 to 2.16 ± 0.42 mm on the left at the fetal ages of 4 and 9 months, respectively. The individual values of the proximal external diameter of the right common iliac artery were greater in 79 (63.7%) fetuses. Their growth followed the quadratic models: $y=1.392-0.110\times\text{Age}+0.004\times\text{Age}^2\pm 0.285$ ($R^2=0.77$) and $y=1.283-0.099\times\text{Age}+0.004\times\text{Age}^2\pm 0.238$ ($R^2=0.81$) for the right (Figure 3A) and left (Figure 3B) common iliac arteries.

Nevertheless, on the right and left sides both the length and external diameter of the common iliac artery did not rise proportionally during the study period, because they did not have the same rate of growth through the analyzed fetal ages. This change of rate is illustrated in Figure 4, in which the length-to-proximal external diameter ratio of the

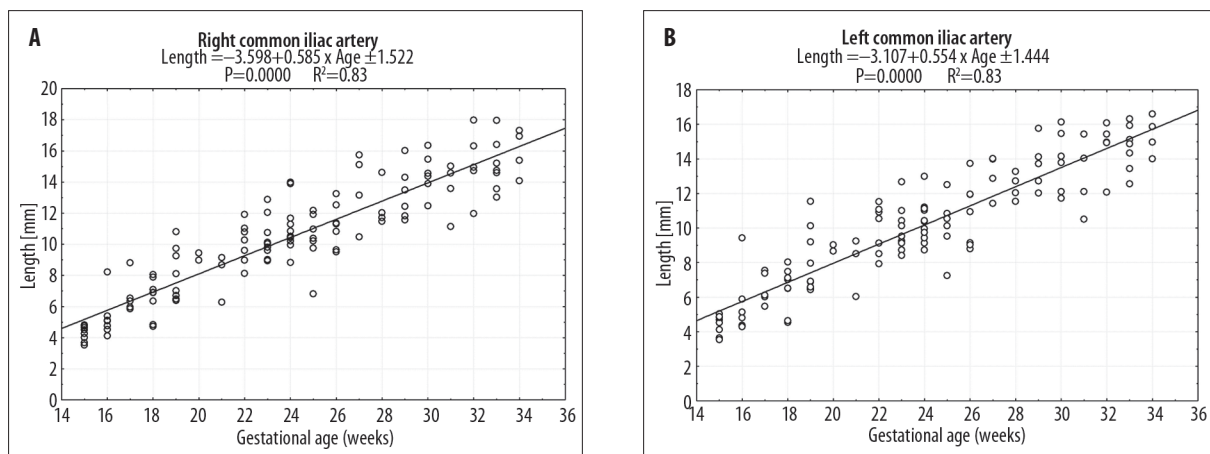


Figure 2. Regression lines for length of the right (A) and left (B) common iliac arteries vs. gestational age.

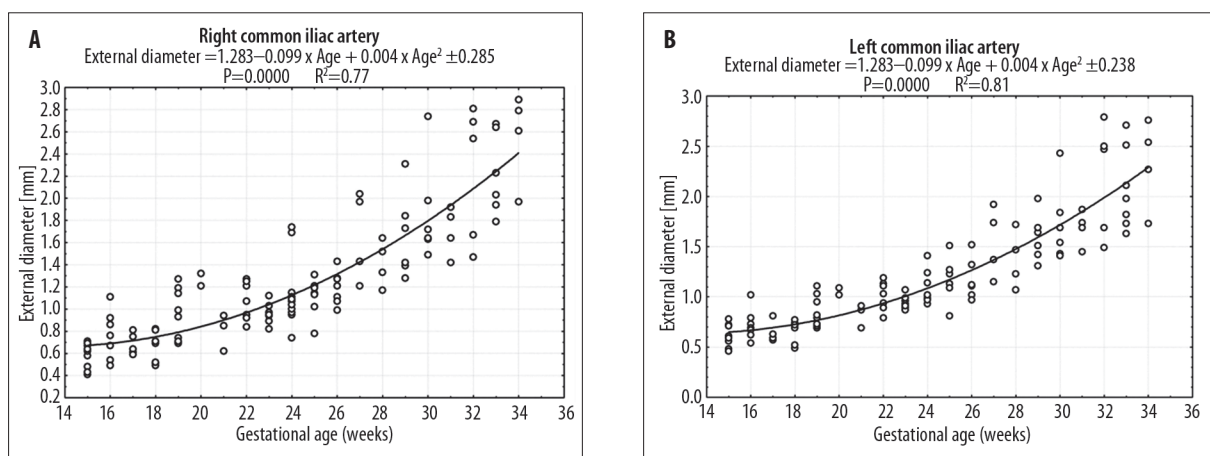


Figure 3. Regression lines for proximal external diameter of the right (A) and left (B) common iliac arteries vs. gestational age.

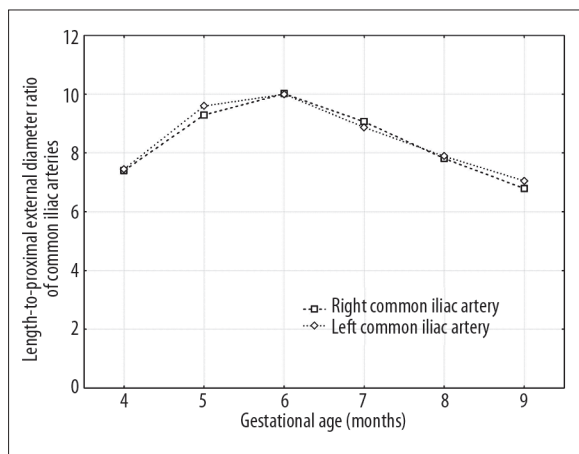


Figure 4. Length-to-proximal external diameter ratio of the common iliac arteries vs. gestational age.

common iliac arteries was found to increase until the age of 6 months, after which its value decreased.

In fetuses aged 4 and 9 months of gestation, the values of the common iliac artery volume were increasing from 1.93 ± 1.74 to $66.95 \pm 29.31 \text{ mm}^3$ on the right, and from 1.91 ± 1.65 to

$56.86 \pm 25.17 \text{ mm}^3$ on the left, respectively. In 84 (67.7%) fetuses the individual values of the common iliac artery volume were greater on the right side. The volumetric growth of the common iliac artery generated the quadratic functions: $y = 99.69 - 10.60 \times \text{Age} + 0.287 \times \text{Age}^2 \pm 14.40$ ($R^2 = 0.67$) on the right (Figure 5A), and $y = 82.62 - 8.86 \times \text{Age} + 0.242 \times \text{Age}^2 \pm 11.60$ ($R^2 = 0.71$) on the left (Figure 5B).

DISCUSSION

After reviewing the professional literature on the common iliac arteries in human fetuses we managed to find only limited reference data for their dimensions [3,15,20]. The existing data in the literature has focused on the length and diameter, with no information about their growth curves. Therefore, the present anatomical, digital and statistical study provides reference values for length, external diameter and volume of the common iliac arteries in normal human fetuses. In fact, because these spontaneous abortions and stillbirths were related to intra-uterine growth restriction, the measurements of the common iliac arteries may be somewhat smaller than normal. However, the aortic root diameter was reported to remain normal in most cases of intra-uterine growth retardation [21]. The lack of such quantitative information in the literature concerning the common iliac arteries limits discussion on this subject.

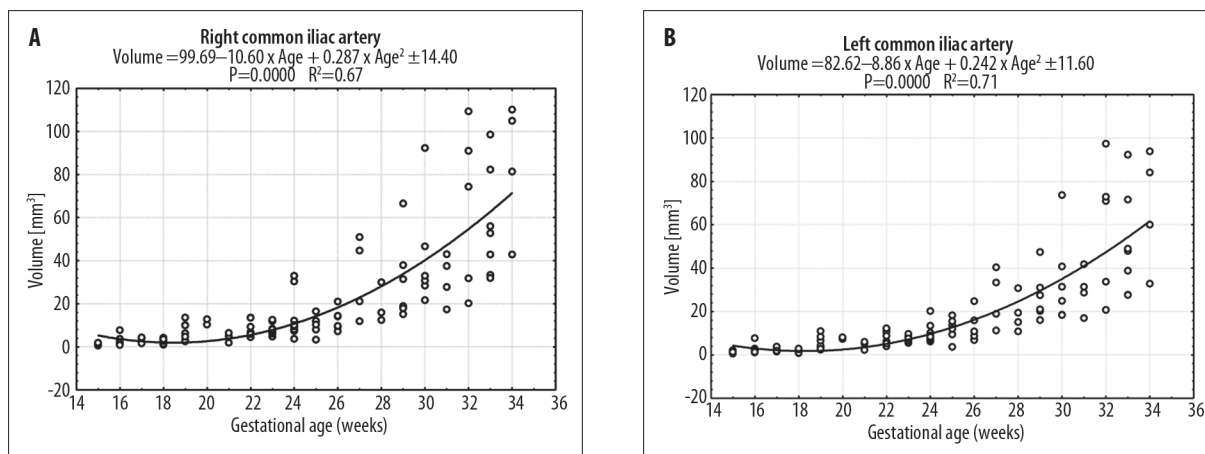


Figure 5. Regression lines for volume of the right (A) and left (B) common iliac arteries vs. gestational age.

Furthermore, tissue shrinkage related to neutral buffered formalin fixation has little influence on the measurements of the filled common iliac arteries *in situ*, the wall of which is mainly composed of elastic connective tissue. The autopsy findings of Szpinda [22] showed only 0.5–1% shrinkage in elastic fetal arteries *in situ*, which were filled with latex and then immersed in 10% neutral buffered formalin solution for 4–24 months.

In the current study, no significant male-female differences concerning the 3 morphometric parameters of the common iliac arteries were found, in keeping with the results of some authors concerning both the length and diameter of the common iliac arteries in fetuses [3,15,20] and adults [23].

Although no laterality differences for the 3 parameters within the whole group were observed, the individual anatomical parameters of the right common iliac artery were found to be greater than those of the left one in relation to its length (in 60.5% of individuals), external diameter (in 63.7% of fetuses), and volume (in 67.7% of cases). Similarly, Özgüner and Sulak [15] demonstrated no laterality differences in both the length and external diameter of the common iliac arteries. Our findings are in disagreement with Gościcka et al. [3], who emphasized that the left common iliac arteries were always both thinner and longer than the right ones.

As pointed out in the introduction, the vertebral levels at which the common iliac arteries start and bifurcate obviously influence the length of the common iliac arteries [1,2,24]. In cases having both high aortic bifurcation and low bifurcation of the common iliac arteries, the common iliac artery tends to be longer. Gościcka et al. [4] studied skeletony of the common iliac arteries in relation to the spine in 70 fetuses aged 4–9 months. Pseudoascensus of the common iliac arteries was found with advanced fetal age. During the study period, the origin of the common iliac artery was displaced upwards half the distance of the vertebral body and projected from the level of the upper half of vertebra L5 to the lower half of vertebra L4. At the same time, the termination of the common iliac artery shifted from the level of the lower border of vertebra S1 to the lower border of vertebra L5. According to these authors, the common iliac artery bifurcation displaced upwards in a double fashion due

to the development of both the longitudinal dimension of the spine and the transverse pelvic dimension. Some authors [23, 25, 26] revealed that the abdominal aorta length was negatively related to the length of the common iliac arteries, therefore the shorter common iliac arteries were correlated with the longer abdominal aortas.

We found that the common iliac artery length rose from 4.76 ± 1.05 to 15.38 ± 1.60 mm, and from 4.92 ± 1.33 to 14.91 ± 1.25 mm, and generated the linear patterns: $y = -3.598 + 0.585 \times \text{Age} \pm 1.522$ and $y = -3.107 + 0.554 \times \text{Age} \pm 1.444$ for the right and left sides, respectively. The mean values for the length of the common iliac arteries recorded by Gościcka et al. [3] were slightly greater in fetuses aged 4 and 9 months, and much smaller in fetuses aged 5–8 months, when compared to our results. These differences may be attributed in part to the inter-individual variability and methodological differences in measurements. According to findings of Özgüner and Sulak [15], the lengths of the common iliac arteries in 3 trimesters (9–12 weeks, 13–25 weeks, 26–37 weeks) and in full-term (38–40 weeks) fetuses were 2.10 ± 0.4 mm, 6.13 ± 1.8 mm, 12.72 ± 1.6 mm and 19.60 ± 2.3 mm on the right, and 1.92 ± 0.4 mm, 6.00 ± 1.8 mm, 12.7 ± 1.8 mm and 19.44 ± 1.8 mm on the left side, respectively.

Of note, we found that proximal external diameters of the right and left common iliac arteries varied from 0.66 ± 0.19 to 2.30 ± 0.42 mm, and from 0.66 ± 0.14 to 2.16 ± 0.42 mm for fetuses at the ages of 4 and 9 months, which were given by the quadratic patterns: $y = 1.392 - 0.110 \times \text{Age} + 0.004 \times \text{Age}^2 \pm 0.285$ and $y = 1.283 - 0.099 \times \text{Age} + 0.004 \times \text{Age}^2 \pm 0.238$, respectively. These quadratic functions were the best models for the diameter growth, because the coefficients of determination between the diameter and fetal age attained the greatest values for the right ($R^2 = 0.77$) and left ($R^2 = 0.81$) common iliac arteries. Although the mean values for external diameters of the common iliac arteries reported by Gościcka et al. [3] correspond reasonably well to our numerical data, these authors presented a quasi-linear relationship. To our knowledge, no other angiometric study dealt with a quadratic pattern for any diameter growth, which was always presented in a linear fashion [3,11,12,15,18–20,27–29].

In the material of Özgüner and Sulak [15] with the 4 above-mentioned groups of fetuses, external diameters of the

common iliac artery attained the following values: 0.92 ± 0.1 mm, 1.69 ± 0.3 mm, 3.06 ± 0.5 mm and 4.13 ± 0.3 mm for the right one, and 0.92 ± 0.7 mm, 1.63 ± 0.3 mm, 2.94 ± 0.5 mm and 4.07 ± 0.3 mm for the left one.

Because the size of the specimens varied, we took into account the relative growth of each common iliac artery, expressed as the length-to-proximal external diameter ratio. As indicated in Figure 4, their relative growth turned out to be not proportional. First, until the age of 6 months, the length of the common iliac artery grew faster than its external diameter, being expressed by the positive increment of the length-to-proximal external diameter ratio. Later, in contrast, the external diameter grew faster than the length of the common iliac artery, which was indicated by the decrement of the value of the length-to-proximal external diameter ratio. In our view, because the length and proximal external diameter of the common iliac arteries do not grow at the same rate all the time, the specific individual variations in growth may produce the specific adult forms in particular individuals. Thus, in adults the origin of the common iliac arteries was most often (80%) noted at the level of the lower (48%), middle (12%) or upper (12%) part of vertebra L4, rarely (12%) at the level of vertebra L5, and occasionally (8%) between L3 and L4 vertebrae [4]. The common iliac arteries were found to start as low as the upper part of S1 [5,30], and as high as the level of L2 [24]. According to Kornreich et al. [5], the position of the aortic bifurcation showed an age-related downward shift with increasing age, which was more pronounced in women ($R^2=0.26$) than in men ($R^2=0.13$). With each increasing decade of life there was a decline equivalent to 17.5% and 9.5% of the vertebral height for women and men, respectively. In turn, the bifurcation of the common iliac arteries in 60% of specimens projected on the lower margin of vertebra L5, in 30% of fetuses it projected slightly above, and in 10% of the remaining fetuses it projected slightly below this level [2].

In the only previous report related to the common iliac artery volume in human fetuses, Gościcka et al. [3] did not present any growth curves for its development. According to these authors, the mean volume of the common iliac arteries in fetuses aged 4–9 months varied from 2.14 to 74.82 mm³ on the right, and from 2.08 to 60.82 mm³ on the left. Thus, when compared to theirs, the volumetric data in the material under examination turned out to be smaller on both sides in fetuses aged 4 and 9 months, similar on both sides in fetuses aged 5 months, and on the left side in fetuses aged 6 months, and greater in the remaining fetuses.

Our findings demonstrated that the common iliac artery volume increased from 1.93 ± 1.74 to 66.95 ± 29.31 mm³ on the right, and from 1.91 ± 1.65 to 56.86 ± 25.17 mm³ on the left. It is noteworthy that several transformations were generated to find the most precise mathematical model for the volumetric growth of the common iliac artery. We have proved that the best fit correlation between the volumetric growth of the common iliac artery and gestational age is a parabola. This fact was confirmed by the quadratic regressions: $y=99.69-10.60 \times \text{Age}+0.287 \times \text{Age}^2 \pm 14.40$ and $y=82.62-8.86 \times \text{Age}+0.242 \times \text{Age}^2 \pm 11.60$ in relation to the right and left common iliac arteries, respectively. Of note, we did not come across any study dealing with the growth curves

for the common iliac artery volume. In the fetuses examined, the common iliac artery volume rose 35-fold on the right, and 30-fold on the left. These data were related to the product of the length and the squared external diameter, which increased approximately 3.2- and 3.5-fold for the right common iliac artery, and 3.0- and 3.3-fold for the left one.

The present study describes the normal growth of the length, external diameter and volume of the common iliac arteries, providing mathematical models for their growth curves. A particular strength of this study is the large number ($n=124$) of normal specimens used to generate the growth curves. In spite of the fact that this study was performed on autopsy material, the detailed morphometric data as a database for intra-uterine examination of the common iliac arteries may be useful in the early diagnosis, monitoring and management of aorto-iliac malformations in obstetrics, perinatology, and fetal pathology departments.

CONCLUSIONS

1. There are no significant differences between sexes for the morphometric parameters of the common iliac arteries.
2. The common iliac arteries grow linearly in length, and parabolically in both diameter and volume.
3. The right common iliac artery constitutes a predominant vessel in relation to its length (60.5%), external diameter (63.7%) and volume (67.7%).
4. The morphometric data on the common iliac arteries may serve as a useful reference to professionals working in the area of congenital aorto-iliac abnormalities and morphologists teaching human developmental anatomy.

REFERENCES:

1. Standring S (ed.): Gray's Anatomy. The Anatomical Basis of Clinical Practice. Edinburgh: Elsevier, 2008; 1086–89
2. Testut L, Latarjet A: Traite d'anatomie humaine. Paris, Doin, 1948
3. Gościcka D, Szpinda M, Stankiewicz W: Die Verzweigung der Aorta abdominalis bei menschlichen Feten. Ann Anat, 1995; 177: 549–52 [in German]
4. Gościcka D, Szpinda M, Stankiewicz W: Skeletopy of the common iliac arteries in human fetuses. Folia Morphol, 1995; 54: 129–36
5. Kornreich L, Hadar H, Sulkes J et al: Effect of normal ageing on the sites of aortic bifurcation and inferior vena cava confluence: a CT study. Surg Radiol Anat, 1997; 20: 63–68
6. Khamanarong K, Sae-Jung S, Supa-Adirek C et al: Aortic bifurcation: a cadaveric study of its relationship to the spine. J Med Assoc Thai, 2009; 92: 47–56
7. Mansfield AO, Howard JM: Absence of both common iliac arteries. A case report. Anat Rec, 1964; 150: 363–64
8. Llauger J, Sabate JM, Guardia E et al: Congenital absence of the right common iliac artery: CT and angiographic demonstration. Eur J Radiol, 1995; 21: 128–30
9. Dumanian AV, Frahm CJ, Benchik FA et al: Intermittent claudication secondary to congenital absence of iliac arteries. Arch Surg, 1965; 91: 604–6
10. Narverud G, Myhre HO: Congenital hypoplasia of the lower limb arteries. A report of two cases. Scand J Thorac Cardiovasc Surg, 1974; 8: 70–72
11. Achiron R, Zimand S, Hegesh J et al: Fetal aortic arch measurements between 14 and 38 weeks' gestation: in utero ultrasonographic study. Ultrasound Obstet Gynecol, 2000; 15: 226–30
12. Gembruch U, Shi C, Smrcek JM et al: Biometry of the fetal heart between 10 and 17 weeks of gestation. Fetal Diagn Ther, 2000; 15: 20–31
13. Nasrallah FK, Baho H, Sallout A et al: Prenatal diagnosis of idiopathic infantile arterial calcification with hydrops fetalis. Ultrasound Obstet Gynecol, 2009; 34: 601–4

14. Cansu A, Ahmetoglu A, Mutlu M et al: Idiopathic infantile arterial calcification: prenatal diagnosis and postnatal presentation. *Clin Exp Obstet Gynecol*, 2010; 37: 73–75
15. Özgüner G, Sulak O: Development of the abdominal aorta and iliac arteries during the fetal period: a morphometric study. *Surg Radiol Anat*, 2011; 33: 35–43
16. Iffy L, Jakobovits A, Westlake W et al: Early intrauterine development: I. The rate of growth of Caucasian embryos and fetuses between the 6th and 20th weeks of gestation. *Pediatrics*, 1975; 56: 173–86
17. Gościcka D, Gielecki J, Materka A: Application of digital image analysis system for measurements of the blood vessels parameters: diameter, length, volume. *Folia Morphol*, 1990; 1: 1–7
18. Szpinda M, Szwesta A, Szpinda E: Morphometric study of the ductus arteriosus during human development. *An Anat*, 2007; 189: 47–52
19. Szpinda M, Flisiński P, Szwesta A et al: Quantitative morphology of the left subclavian artery in human fetuses. *Adv Med Sci*, 2008; 53: 69–75
20. Hyett J, Moscoso G, Nicolaides K: Morphometric analysis of the great vessels in early fetal life. *Hum Reprod*, 1995; 10: 3045–48
21. Cartier MS, Doubilet PM: Fetal aortic and pulmonary artery diameters: sonographic measurements in growth-retarded fetuses. *Am J Roentgenol*, 1988; 151: 991–93
22. Szpinda M: Morphometric study of the great arteries of the thorax in human fetuses (in Polish). Habilitation thesis. Bydgoszcz: CM UMK; 2006; 1–143
23. Panagoulis E, Lolis E, Venieratos D: A morphometric study concerning the branching points of the main arteries in humans: relationships and correlations. *Ann Anat*, 2011; 193: 86–99
24. Bergman RA, Thompson SA, Afifi AK et al: *Compendium of Human Anatomic Variation: Text, Atlas, and World Literature*. Baltimore: Urban & Schwarzenberg; 1988
25. Pennington N, Soames RW: The anterior visceral branches of the abdominal aorta and their relationship to the renal arteries. *Surg Radiol Anat*, 2005; 27: 395–403
26. Lederle FA, Johnson GR, Wilson SE et al: Relationship of age, gender, race and body size to infrarenal aortic diameter. *J Vasc Surg*, 1997; 26: 595–601
27. Szpinda M, Brazis P, Elminowska-Wenda G, Wiśniewski M: Morphometric study of the aortic and great pulmonary arterial pathways in human fetuses. *Ann Anat*, 2006; 188: 25–31
28. Szpinda M: Morphometric study of the ascending aorta in human fetuses. *Ann Anat*, 2007; 189: 465–72
29. Szpinda M: Morphometric study of the brachiobicaortid trunk in human fetuses. *Ann Anat*, 2007; 189: 569–74
30. Lerona PT, Tewfink HH: Bifurcation level of the aorta: landmark for pelvic irradiation. *Radiology*, 1975; 115: 735–37