

Available online at [www.sciencedirect.com](http://www.sciencedirect.com)

ScienceDirect

journal homepage: [www.elsevier.com/locate/radcr](http://www.elsevier.com/locate/radcr)

## Case Report

# Left ventricular diverticulum: A case report and review of the literature ☆☆☆

Tran Quang Luc, PhD<sup>a,1</sup>, Pham Duy Hien, Assoc. Prof.<sup>b,1</sup>, Tran Phan Ninh, PhD<sup>b,1</sup>,  
 Le Thi Mai Lan, MD<sup>b,1</sup>, Ngo Van Hung, MD<sup>b,1</sup>, Doan Van Ngoc, PhD<sup>c,1</sup>,  
 Nguyen Van Kien, MD<sup>a,1</sup>, Nguyen Van Sang, PhD<sup>d,e,f,1,\*</sup>

<sup>a</sup>Department of Radiology, Viet Tri general hospital, Phu Tho, Vietnam

<sup>b</sup>Department of Radiology, Vietnam National Children's Hospital, Ha Noi, Vietnam

<sup>c</sup>Department of Radiology, VNU University of Medicine and Pharmacy, Ha Noi, Vietnam

<sup>d</sup>Department of Radiology, E Hospital, Ha Noi, Vietnam

<sup>e</sup>Department of Radiology, Medlatec Hospital, Ha Noi, Vietnam

<sup>f</sup>Department of Radiology, Thai Nguyen Pharmacy and Medical University, Thai Nguyen, 250000, Vietnam

## ARTICLE INFO

## Article history:

Received 8 April 2022

Revised 15 April 2022

Accepted 18 April 2022

## Keywords:

Left ventricular diverticulum

Congenital cardiac malformation

CT angiography

Echocardiography

## ABSTRACT

Left ventricular diverticulum is a rare congenital left ventricular outpouchings. The disease is often diagnosed during childhood because it is frequently associated with midline thoracoabdominal defects and other congenital cardiac anomalies. Most cases are asymptomatic, often discovered incidentally. Some complications have been reported including infarction, arrhythmia, heart failure. The most severe complication is rupture of the diverticulum, which can cause a patient's death. Therefore, this congenital defect should be detected early to assess potential risks for appropriate treatment. In this article, we report a case of a 3-month-old boy with left ventricular diverticulum diagnosed with Doppler ultrasound and cardiac MSCT. Complete resection was undertaken. The patient remained asymptomatic with good heart function 2 months after surgery.

© 2022 The Authors. Published by Elsevier Inc. on behalf of University of Washington.

This is an open access article under the CC BY-NC-ND license

(<http://creativecommons.org/licenses/by-nc-nd/4.0/>)

Congenital left ventricular diverticulum (LVD) is a rare congenital anomaly with a prevalence of 0.4% or 3 in 750 cardiac death autopsies [1–3]. A left ventricular diverticulum is defined as an enlarged structure containing the endocardium, myocardium, and pericardium and displays normal systolic contraction [4,5]. The left ventricular diverticulum is often diagnosed during early childhood because it is frequently as-

sociated with other cardiac and midline thoracoabdominal anomalies. Most cases are asymptomatic and often discovered incidentally on physical examination for other causes [1,2]. The lesions are usually benign, some complications have been recorded including embolism, arrhythmia, heart failure, and ruptured diverticulum [2]. Therefore, it is important to detect early, evaluate and initiate appropriate treatment. Imaging

☆ Acknowledgments: Self-financed.

☆☆ Competing Interests: The authors do not report any conflicts of interest.

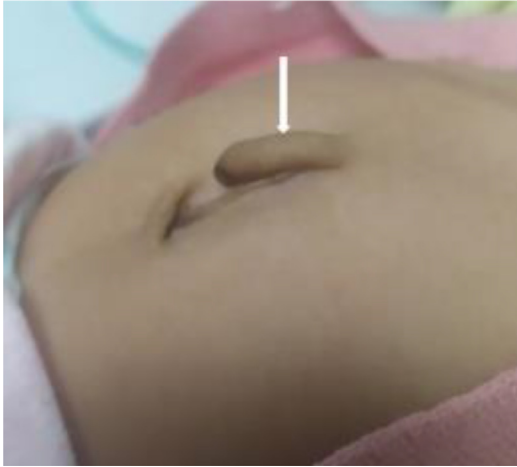\* Corresponding author. Department of Radiology, Medlatec Hospital, Ha Noi 100000, Vietnam

E-mail address: [dr.nguyensang@gmail.com](mailto:dr.nguyensang@gmail.com) (N. Van Sang).

<sup>1</sup> These authors contributed equally to this article as co-first authors.

<https://doi.org/10.1016/j.radcr.2022.04.036>

1930-0433/© 2022 The Authors. Published by Elsevier Inc. on behalf of University of Washington. This is an open access article under the CC BY-NC-ND license (<http://creativecommons.org/licenses/by-nc-nd/4.0/>)



**Fig. 1 – A tubular structure protruding from the abdominal wall, soft and contracting with the heartbeat (white arrow)**

facilities help diagnose the left ventricular diverticulum more easily. Due to the rare incidence, there is no consensus on the treatment of the left ventricular diverticulum. Currently, treatment depends on each patient.

In this article, we report a case of a 3-month-old boy with left ventricular diverticulum diagnosed with Doppler ultrasound and cardiac MSCT, who underwent successful surgical complete resection.

### Case presentation

A 3-month-old boy was admitted to the hospital by appointment, with the diagnosis of the left ventricular diverticulum

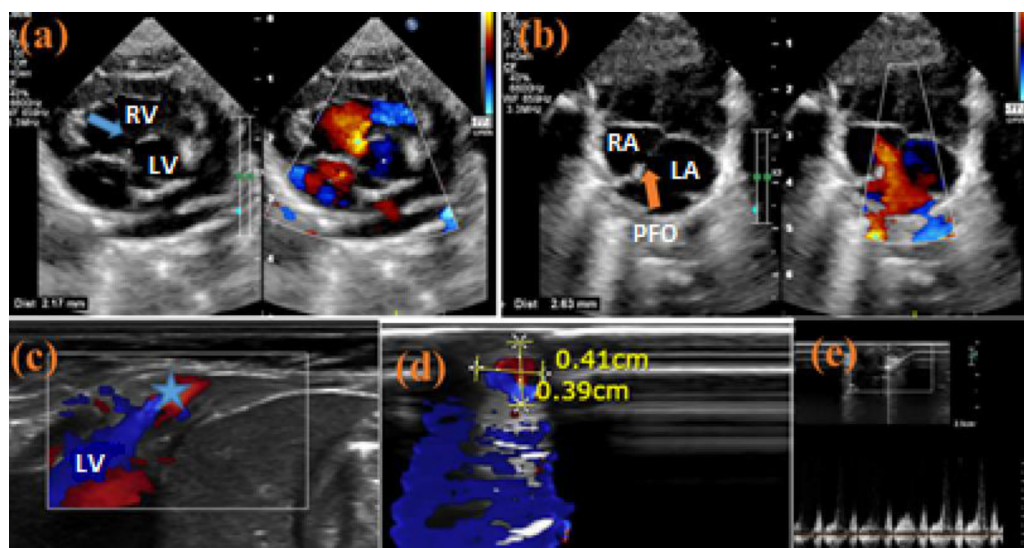
and ventricular septal defect at birth. The history of the patient included normal delivery, full-term birth, birth weight of 1.8 kg, and no abnormalities detected during pregnancy. At birth, he was found to have a tubular structure protruding from the abdominal wall above the umbilicus with 20 mm length, expanding and contracting with the heartbeat, soft in palpation, and compressible (Fig. 1).

Echocardiography 2 days after birth showed a perimembranous ventricular septal defect with a diameter of 2.2 mm, left-to-right shunt, PGmax 15 mmHg (Fig. 2). There was no ventricular outflow tract obstruction. Bilateral coronary arteries were normal. No atrial septal defect as well as no ductus arteriosus were found. Patent foramen ovale was 2.6 mm in diameter, with left-to-right shunt. The patient had a left-sided aortic arch, without coarctation of the aorta. There were no bilateral pulmonary artery anomalies found. X-ray images showed no abnormalities.

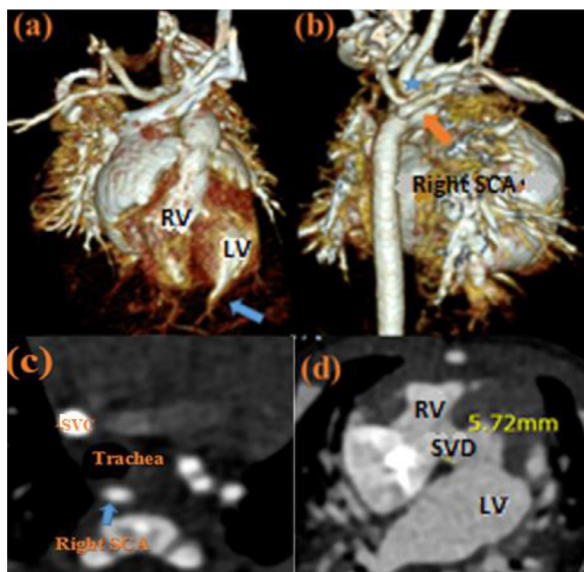
Cardiac MSCT at 5 days old showed a perimembranous ventricular septal defect. The size of the left ventricular diverticulum was  $3 \times 3 \times 40$  mm. Aberrant right subclavian artery coursed posterior to the trachea (Arteria lusoria). The common trunk of bilateral common carotid artery arose from the aortic arch (Fig. 3).

The patient didn't have any clinical symptoms such as cyanosis or dyspnea. The patient then was discharged from the hospital.

By appointment, when the patient was three months old, he had a re-examination. The clinical examination showed that his weight was 5 kg. He had no fever, no shortness of breath, no cyanosis. Echocardiography showed a perimembranous ventricular septal defect, left-to-right shunt, PGmax 93 mmHg. The chambers of the heart were slightly dilated. There was mild mitral regurgitation, left ventricular diverticulum, no atrial septal defect, no ductus arteriosus, small



**Fig. 2 – Ultrasound 2 days after birth: (A, B) Perimembranous ventricular septal defect with diameter 2.2 mm (blue arrow), PFO 2.6 mm (orange arrow); (C, D, E) Left ventricular diverticulum (blue star), with transverse section size  $4.1 \times 3.9$  mm and there was flow spectrum on Doppler ultrasound. RV: right ventricle; LV: left ventricle; RA: right atrial; LA: left atrial; PFO: patent foramen ovale. (Color version of figure is available online.)**



**Fig. 3 – MSCT images at 5 days old: (A, B) 3D reconstruction images showed left ventricular diverticulum (blue arrow); right SCA arose directly from the aortic arch distal to the left SCA (orange arrow); the common trunk of bilateral CCA (blue star); (C) right SCA coursed posterior to the trachea (Arteria lusoria); (D) perimembranous VSD with diameter 5.7 mm. SVC: superior vena cava; SCA: subclavian artery; CCA: common carotid artery; VSD: ventricular septal defect. (Color version of figure is available online.)**

patent foramen ovale with left-to-right shunt. Besides, ultrasound showed a long tubular structure originating from the apex of the left ventricle and extending to the upper umbilicus in the midline. The tube length was 50 mm and the largest transverse diameter was 5 mm. Doppler echocardiography displayed blood flow inside. Cardiac MSCT showed the diverticulum originating from the heart apex to the abdominal wall along the midline (Fig.4). The length of the diverticulum was 50.7 mm, the transverse diameter was 5 mm at the largest position, and 3.1 mm at the neck of the diverticulum. A perimembranous ventricular septal defect with a diameter of 4.4 mm was found (Fig.5A). There was no right brachiocephalic trunk. The common trunk of bilateral common carotid artery was the first branch of the aorta arch. The right SCA arose directly from the aortic arch distal to the left SCA, coursed posterior to the trachea without causing stenosis of the tracheal lumen (Figs.5B and C). No atrial septal defect, no ductus arteriosus was found.

The patient then underwent an operation. Intraoperative exploration showed a diverticulum of the left ventricle near the apex, about 5 mm in diameter, 60 mm long, protruding from the abdominal wall. The surgeon performed a left ventricular diverticulectomy and patched the ventricular septal defect at the same time.

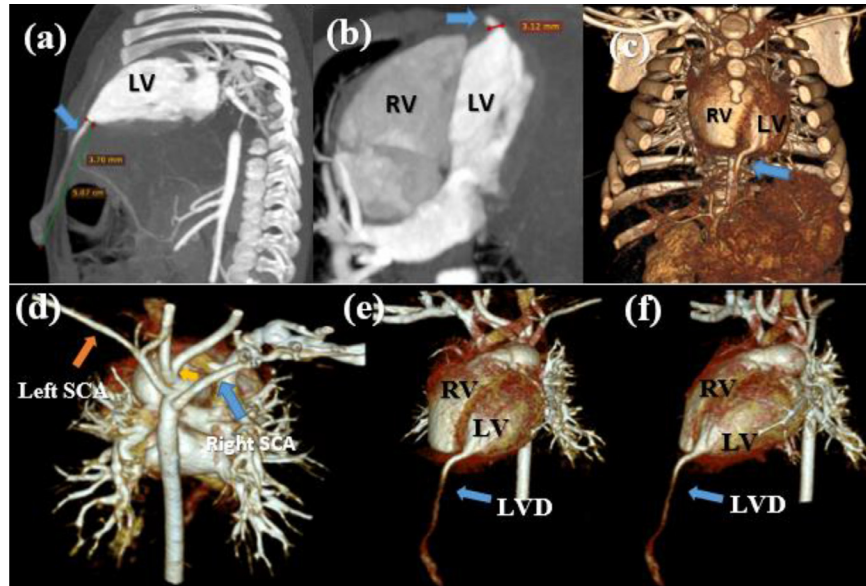
Histopathological diagnosis of the biopsy specimen revealed a diverticulum-like structure with 3 layers of the heart wall including the pericardium (the outer fibrous-connective layer), the middle muscular layer includes cardiac muscle

cells, the endocardium consists of loose connective tissue and elastic fibers bordered by a single layer of squamous epithelial cells (Fig. 6).

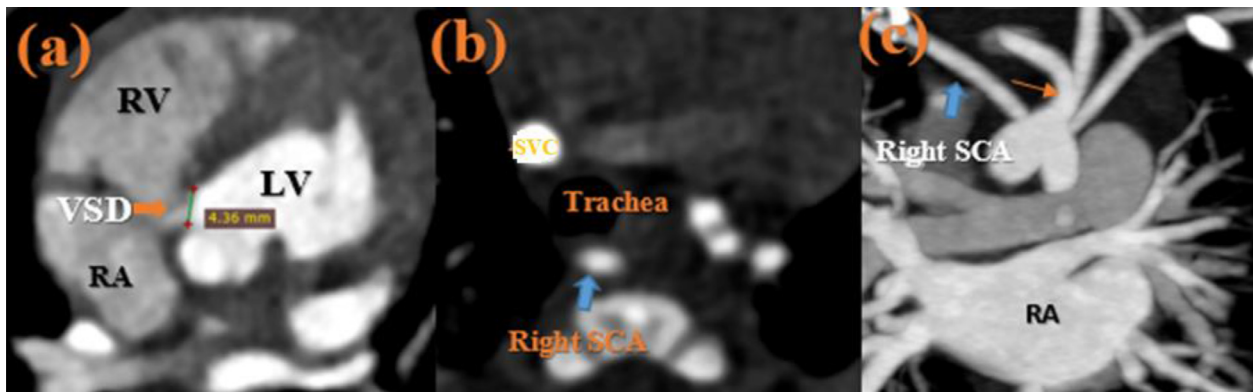## Discussion

The left ventricular diverticulum is a congenital anomaly of the left ventricle. It is defined as an outpouching structure of the left ventricle that contains all three layers of the heart wall including endocardium, myocardium, and pericardium, and displays synergistic contraction with the left ventricle. LVD is connected to the ventricle by a narrow neck (usually <1 cm) [4,6]. According to a meta-analysis study, there were 453 cases of left ventricular diverticulum from the first description in 1816 to January 2012 [3]. Some authors reported an incidence of 0.4% or 3 in 750 cases of cardiac death autopsies [4]. The cause was that a developmental disturbance in the mesoderm can occur between days 14 and 18 of the embryonic stage, shortly after differentiation into the ventral and parietal parts [4,7-9]. The diverticulum may then develop by the 4th week of the embryo, forming along the midline [4,8,9]. The development of a congenital left ventricular diverticulum may be due to a partial cessation of ventricular embryonic development [10]. This explains the common location of the diverticulum at the apex of the left ventricle [8]. Some authors divided the left ventricular diverticulum into muscle type and fiber type. Others divided it into 2 groups based on diverticulum location: the apical type, always associated with other congenital heart abnormalities, and the non-apical type [2,5,11]. The diverticulum can be congenital or acquired. Our case is congenital, muscular type, and apical type.

The left ventricular diverticulum is often diagnosed in childhood because it is frequently associated with other cardiac and thoracic-abdominal anomalies [1,12]. When left ventricular diverticulum is associated with congenital heart defects, midline congenital anomalies, substernal defects, diaphragmatic malformation, and partial absence of pericardium called Cantrell syndrome [13-15]. In addition, the left ventricular diverticulum may occur alone in 30% of cases. The size of the left ventricular diverticulum is usually <9 cm long and <1 cm wide. Most cases are asymptomatic and discovered incidentally during the physical examination for other causes, some of which can be detected prenatally by echocardiography [3,16]. In our case, the child was not diagnosed before birth. At birth, he was found to have a tube protruding from the abdominal wall, beating in rhythm. Afterwards, a general assessment revealed other congenital heart abnormalities: perimembranous ventricle septal defect, arteria lusoria, common trunk of bilaterally CCA. No diaphragmatic hernia, sternal abnormalities, midline malformations, or pericardial defects were found. In a report, a left ventricular diverticulum did not increase in size for more than 13 years, suggesting that the clinical course may be benign [4]. The majority of diverticula usually have few complications. A study showed that out of 453 cases, 2.9% had cerebral or peripheral vascular complications, 9.9% had arrhythmias, 6.8% had heart failure complications, 4.2% of cases had ruptured diverticulum and mainly in children <18 years old (90%) [3].



**Fig. 4 – MSCT images at 3 months old: (A) Sagittal MIP reconstruction images showed left ventricular diverticulum, protruding from the abdominal wall, coursed along the midline; Axial MIP reconstruction images (B) and 3D reconstruction images (C, D, E) showed that the LVD originated from the heart apex; the common trunk of bilateral CCA as the first branch and the left SCA as the second branch of Aorta arch.**



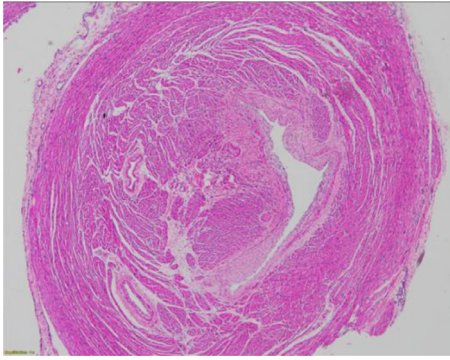
**Fig. 5 – Cardiac MSCT images: (A, B) Axial images showed perimembranous VSD with diameter 4.4 mm; right SCA (blue arrow) coursed posterior to the trachea without causing stenosis of trachea lumen; (C) Coronal MIP image showed the common trunk of bilateral CCA and the aberrant right SCA. (Color version of figure is available online.)**

LVD is often discovered incidentally during an examination of other organs, based on echocardiography, cardiac magnetic resonance, and cardiac MSCT. On echocardiography, a tubular structure or a sac communicating with the ventricles is seen, usually originating from the heart apex, with flow signal inside, contraction according to the left ventricular rhythm [5]. On cardiac MSCT, diverticula may have different shapes and sizes, but most are tubular structures, communicating with the ventricles. On MRI, the diverticulum has the same signal as the ventricle, with synergistic contraction of the ventricular muscle. Some small diverticula may collapse during ventricular systole [5,8,17]. No signal change or abnormal enhancement, no necrosis or fibrosis is seen [8]. The imaging tools in

addition to evaluating the diverticulum also evaluate the comorbidities such as congenital heart or other co-morbidities.

It is necessary to differentiate left ventricular diverticulum from other left ventricular outpouchings (left ventricular bulge or pseudoaneurysm), based on location, structure under 3 layers of the ventricle, no contraction, or paradoxical contraction compared with ventricular muscle [2,12].

Due to the rarity of the left ventricular diverticulum, there are few guidelines for clinicians on treatment, whether surgical or conservative [18–20]. For small diverticula that do not increase in size, priority is given to follow-up. According to a follow-up study of 10 non-operative patients, 2 with spontaneous remission, and 8 were asymptotically alive after



**Fig. 6 – The pathology image showed a tubular structure with three layers of the heart wall.**

a median follow-up of 8.4 years [4]. Some authors have suggested immediate surgical resection, to prevent complications [18]. In our case, the diverticulum increased in size and was accompanied by a ventricular septal defect, so we surgically removed the diverticulum and patched the ventricular septal defect.

## Conclusions

Left ventricular diverticulum is a type of congenital left ventricular outpouchings, rarely symptomatic and often incidentally discovered. Most often there are no complications, some can cause embolisms, arrhythmias, heart failure, or even rupture of the diverticulum, which is dangerous for the patient. Imaging techniques such as echocardiography and CT angiography are helpful for early diagnosis. Treatment, including surgery and conservation, depends on the clinical symptoms, the size of the diverticulum and the ability to observe complications.

## Patient consent

Informed consent for patient information to be published in this article was obtained.

## Ethical Statement

Appropriate written informed consent was obtained for publication of this case report and accompanying images.

## Author contributions

All authors contributed to this article as co-first authors. All authors have read the manuscript and agree to the contents.

## REFERENCE

- [1] Fang Y, An Q, Yu T, Luo S. Partial resection of large congenital left ventricular diverticulum in an infant: a case report. *BMC Surg* 2020;20(1):146 PMID: 32605556; PMCID: PMC7325025. doi:10.1186/s12893-020-00808-6.
- [2] Halpern L, Garabedian C, Worrall NK. Congenital ventricular diverticulum or aneurysm: a difficult diagnosis to make. *Case Rep Cardiol*. 2018;2018:5839432 PMID: 30534448; PMCID: PMC6252185. doi:10.1155/2018/5839432.
- [3] Ohlow MA, von Korn H, Lauer B. Characteristics and outcome of congenital left ventricular aneurysm and diverticulum: analysis of 809 cases published since 1816. *Int J Cardiol* 2015;185:34–45 Epub 2015 Mar 5. PMID: 25782048. doi:10.1016/j.ijcard.2015.03.050.
- [4] Makkuni P, Kotler MN, Figueredo VM. Diverticular and aneurysmal structures of the left ventricle in adults: report of a case within the context of a literature review. *Tex Heart Inst J* 2010;37(6):699–705 PMID: 21224951; PMCID: PMC3014120.
- [5] Pedraza-Jiménez R, Alanís-Naranjo JM, Morelos-Guzmán M. Divertículo ventricular congénito izquierdo aislado en adulto: un hallazgo inusual en infarto de miocardio asociado a cocaína. *Cardiovasc Metab Sci* 2021;32(2):105–9.
- [6] Lee YY, Son JS, Park HW, Lee R. A case of isolated congenital left ventricular diverticulum in a child. *J Cardiovasc Imaging* 2022;30(2):142–5. doi:10.4250/jcvi.2021.0148. PMID: 35505506; PMCID: PMC9058637.
- [7] Albrecht G. Beitrag zur morphologie und formalen genese kongenitaler herzdivertikel [morphology and formal etiology of congenital heart diverticula]. *Zentralbl Allg Pathol* 1972;116(1):42–7 German PMID: 4628554.
- [8] Yang CH, Wu VC, Hung KC, Lin FC. Early detection of left ventricular diverticulum by transthoracic echocardiography. *J Med Ultrasound* 2017;25(4):232–4 Epub 2017 Sep 8. PMID: 30065498; PMCID: PMC6029325. doi:10.1016/j.jmu.2017.08.004.
- [9] Tsaruk O, Ryzhyk V, Ilnytska K. Congenital aneurysm/diverticulum of the left ventricle in the newborn. *Galician Medical Journal* 2020;27(4):E2020415. doi:10.21802/gmj.2020.4.15.
- [10] Costa LAL, Guimarães Filho HA, Melo Júnior CF, Araujo Júnior E. Prenatal diagnosis of congenital left ventricular diverticulum. *Radiol Bras*. 2018;51(2):128–9 PMID: 29743746; PMCID: PMC5935413. doi:10.1590/0100-3984.2016.0129.
- [11] Malakan Rad E, Awad S, Hijazi ZM. Congenital left ventricular outpouchings: a systematic review of 839 cases and introduction of a novel classification after two centuries. *Congenit Heart Dis*. 2014;9(6):498–511 Epub 2014 Aug 27. PMID: 25159202. doi:10.1111/chd.12214.
- [12] Jamshidi R, Hornberger LK, Karl TR. Left ventricular aneurysm in a child with severe combined immunodeficiency syndrome. *Ann Thorac Surg* 2009;88(5):1678–80 PMID: 19853138. doi:10.1016/j.athoracsur.2009.03.094.
- [13] Williams AP, Marayati R, Beierle EA. Pentalogy of Cantrell. *Semin Pediatr Surg*. 2019 Apr;28(2):106–110. doi: 10.1053/j.sempedsurg.2019.04.006. Epub 2019 Apr 9. PMID: 31072457; PMCID: PMC6559797.
- [14] Jrad M, Affes M, Behi S, Laabidi A, Mizouni H. Case Report: congenital left ventricular diverticulum: a pediatric case report [version 1; peer review: 2 approved with reservations]. *F1000Research* 2016;5:2628. doi:10.12688/f1000research.9936.1.
- [15] Mărginean C, Mărginean CO, Gozar L, Meliț LE, Suciș H, Gozar H, et al. Cantrell syndrome-a rare complex congenital anomaly: a case report and literature review. *Front Pediatr*

- 2018;6:201 PMID: 30065917; PMCID: PMC6056637. doi:[10.3389/fped.2018.00201](https://doi.org/10.3389/fped.2018.00201).
- [16] Szychta W, Brzezińska-Rajszyś G, Szumowski Ł, Kowalczyk-Domagala M, Miszczak-Knecht M, Bieganowska K. Left ventricular diverticula in a 2-year-old child with a life-threatening ventricular arrhythmic manifestation – Treatment strategy and review of the literature. *J Cardio Case Rep* 2019;2(4):1–4. doi:[10.15761/JCCR.1000126](https://doi.org/10.15761/JCCR.1000126).
- [17] Tilahun T, Kedir E, Eshetu B. Fatal left ventricular aneurysm in a 13 years old male child: a case report. *Ethiop J Health Sci* 2021;31(4):903–6 PMID: 34703191; PMCID: PMC8512945. doi:[10.4314/ejhs.v31i4.26](https://doi.org/10.4314/ejhs.v31i4.26).
- [18] Yao M, Wang R, Ye W, Ren C. Surgical treatment of congenital left ventricular diverticulum. *J Thorac Dis* 2021;13(1):291–8 PMID: 33569209; PMCID: PMC7867842. doi:[10.21037/jtd-20-3510](https://doi.org/10.21037/jtd-20-3510).
- [19] Shauq A, Agarwal V, Crawley C. Congenital left ventricular diverticulum. *Heart Lung Circ* 2006;15(4):272–4 Epub 2006 Apr 19. PMID: 16621715. doi:[10.1016/j.hlc.2006.02.013](https://doi.org/10.1016/j.hlc.2006.02.013).
- [20] Ohlow MA. Congenital left ventricular aneurysms and diverticula: definition, pathophysiology, clinical relevance and treatment. *Cardiology* 2006;106(2):63–72 Epub 2006 Apr 12. PMID: 16612072. doi:[10.1159/000092634](https://doi.org/10.1159/000092634).