




## Case Report

# A rare case of long-term survival from metachronous bilateral adrenal metastasis of lung adenocarcinoma after combined surgical removal and immunochemotherapy

Nami Tomiyama,<sup>1</sup> Taku Naiki,<sup>1</sup>  Aya Naiki-Ito,<sup>2</sup> Tatsuya Kawai,<sup>3</sup> Toshiki Etani,<sup>1</sup>   
Masakazu Gonda,<sup>1</sup> Maria Aoki,<sup>1</sup> Toshiharu Morikawa,<sup>1</sup> Yosuke Sugiyama<sup>4</sup> and Takahiro Yasui<sup>1</sup> 

Departments of <sup>1</sup>Nephro-urology, <sup>2</sup>Pathology and Tumor Biology, and <sup>3</sup>Radiology, Nagoya City University, Graduate School of Medical Sciences, and <sup>4</sup>Department of Pharmacy, Nagoya City University Hospital, Nagoya, Japan

## Abbreviations & Acronyms

<sup>18</sup>F-FDG = <sup>18</sup>F-fluorodeoxy-glucose  
AM = adrenal metastasis  
Bev = bevacizumab  
CBDCA = carboplatin  
CEA = carcinoembryonic antigen  
CT = computed tomography  
Doc = docetaxel  
FDG-PET/CT = <sup>18</sup>F-FDG uptake on positron emission tomography/computed tomography  
HE = hematoxylin–eosin  
NSCLC = non-small cell lung cancer  
PEM = pembrolizumab  
Ram = ramucirumab

**Introduction:** The prognosis of adrenal metastasis from non-small cell lung cancer is very poor. A recent report described the efficacy of the surgical removal of adrenal metastasis when solitary. However, metachronous bilateral adrenal metastasis is extremely rare, and a treatment strategy has not been established.

**Case presentation:** Herein, we describe a 52-year-old Asian male who presented with a right adrenal metastasis of non-small cell lung cancer 8 months after immunochemotherapy and surgical resection of the lung. He underwent combined systemic treatment and a laparoscopic right adrenalectomy; however, after 9 months, a metachronous left adrenal metastasis emerged. A subsequent laparoscopic left adrenalectomy and systemic treatment led to long-term progression-free survival.

**Conclusion:** The appropriate surgical indication and combined systemic treatment of a metachronous bilateral adrenal metastasis in non-small cell lung cancer may extend the prognosis.

**Key words:** adrenalectomy, long-term survival, lung adenocarcinoma, metachronous bilateral adrenal metastasis.

**Correspondence:** Taku Naiki M.D., Ph.D., Department of Nephro-Urology, Nagoya City University, Graduate School of Medical Sciences, Kawasumi 1, Mizuho-cho, Mizuho-ku 467-8601, Nagoya, Japan. Email: naiki@med.nagoya-cu.ac.jp

**How to cite this article:** Tomiyama N, Naiki T, Naiki-Ito A *et al.* A rare case of long-term survival from metachronous bilateral adrenal metastasis of lung adenocarcinoma after combined surgical removal and immunochemotherapy. *IJU Case Rep.* 2022; 5: 474–478.

This is an open access article under the terms of the [Creative Commons Attribution-NonCommercial License](#), which permits use, distribution and reproduction in any medium, provided the original work is properly cited and is not used for commercial purposes.

Received 14 June 2022; accepted 26 July 2022.

Online publication 2 August 2022

## Keynote message

We treated a case of bilateral metachronous adrenal metastasis of lung adenocarcinoma that successfully achieved long-term survival by a combination of adrenalectomy and immunochemotherapy. This indicates the prognosis can be improved by an appropriate judgment with regard to surgical indication and systemic treatment.

## Introduction

NSCLC frequently metastasizes to the adrenal gland. Most AM are multiple and the prognosis is poor. However, improved imaging modalities allows the detection of solitary AM in early disease at initial diagnosis or follow-up.<sup>1–3</sup> Increasing cases of the surgical removal of AM have gradually been reported, and some patients with isolated AM achieve long-term survival after adrenalectomy.<sup>5–9,11–18</sup> However, there is a lack of established evidence comparing adrenalectomy with non-surgical treatment, and clinical prognostic factor for disease relapse after surgical treatment are poorly understood. In addition, metachronous bilateral AM is extremely rare.<sup>2</sup> We herein describe long-term survival in a case of metachronous bilateral AM of NSCLC after a combination of surgical removal and systemic immunochemotherapy.

## Case report

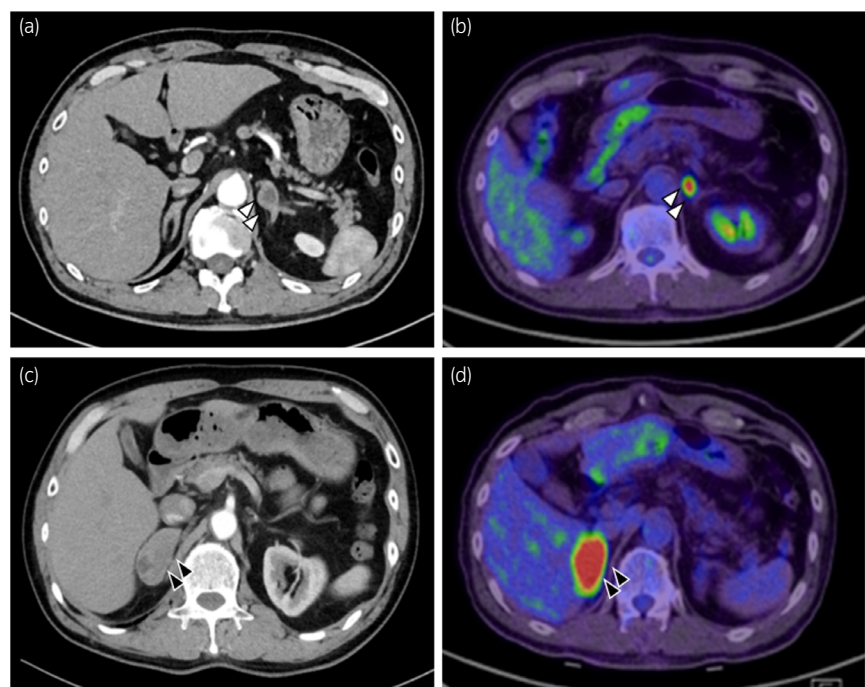
A 52-year-old Asian man was referred to our department due to a left adrenal mass on CT following treatment for poorly differentiated adenocarcinoma in the left lung. He underwent a surgical resection of the left upper lobe of the lung. The pathological stage was T3aN0M0 (stage IIB), and four cycles of adjuvant chemotherapy (cisplatin, vincristine) were undertaken.

Abnormalities in vital signs or significant findings suspicious of Cushing syndrome were not observed on an initial visit. Except for an elevated CEA level of 23.9 mg/dL, a serum biomarker of lung adenocarcinoma, which became normalized soon after lung surgery, no significant findings were observed in the blood examination, including for adrenal hormones. Contrast-enhanced CT revealed a 15 × 12-mm-sized substantial mass in the left adrenal cortex with <sup>18</sup>F-FDG uptake on PET-CT (Fig. 1a,b). Clinically, the mass was assumed to be an AM of lung adenocarcinoma, therefore, after informed consent, the patient underwent two courses of chemotherapy (CBDCA, PEM). However, the tumor did not completely regress, therefore, a laparoscopic left adrenalectomy (Fig. 2e) was performed. Pathological findings revealed atypical cells with anisokaryosis and pleomorphism infiltrating and forming nests in the adrenal cortex (Fig. 2f) as found in the primary lung adenocarcinoma (Fig. 2a–d). The adrenal tumor was weakly positive for TTF-1 (Fig. 2g) and negative for vimentin (Fig. 2h) by immunohistochemistry, consistent with characteristics of the primary tumor; its surgical margin was negative. The patient's serum CEA level normalized to 4.6 mg/dL soon after the left adrenalectomy (Fig. 3), and an additional four cycles of systemic treatment of immunochemotherapy (CBDCA, PEM, and Bev) were performed. However, 9 months after surgery, the serum CEA level had increased to 22.2 mg/dL. A 60 × 24-mm-sized mass in the right adrenal cortex was observed with <sup>18</sup>F-FDG uptake on PET/CT (Fig. 1c,d); this was suspected to be an asynchronous AM. Therefore, a laparoscopic right adrenalectomy (Fig. 2i) and steroid supplementation were undertaken without any comorbidities observed. Pathological findings revealed a right AM of a poorly differentiated adenocarcinoma of lung origin (Fig. 2j) that stained negative for TTF-1 (Fig. 2k) and negative for vimentin (Fig. 2l). After the second adrenalectomy, the patient received 20 mg/day of oral

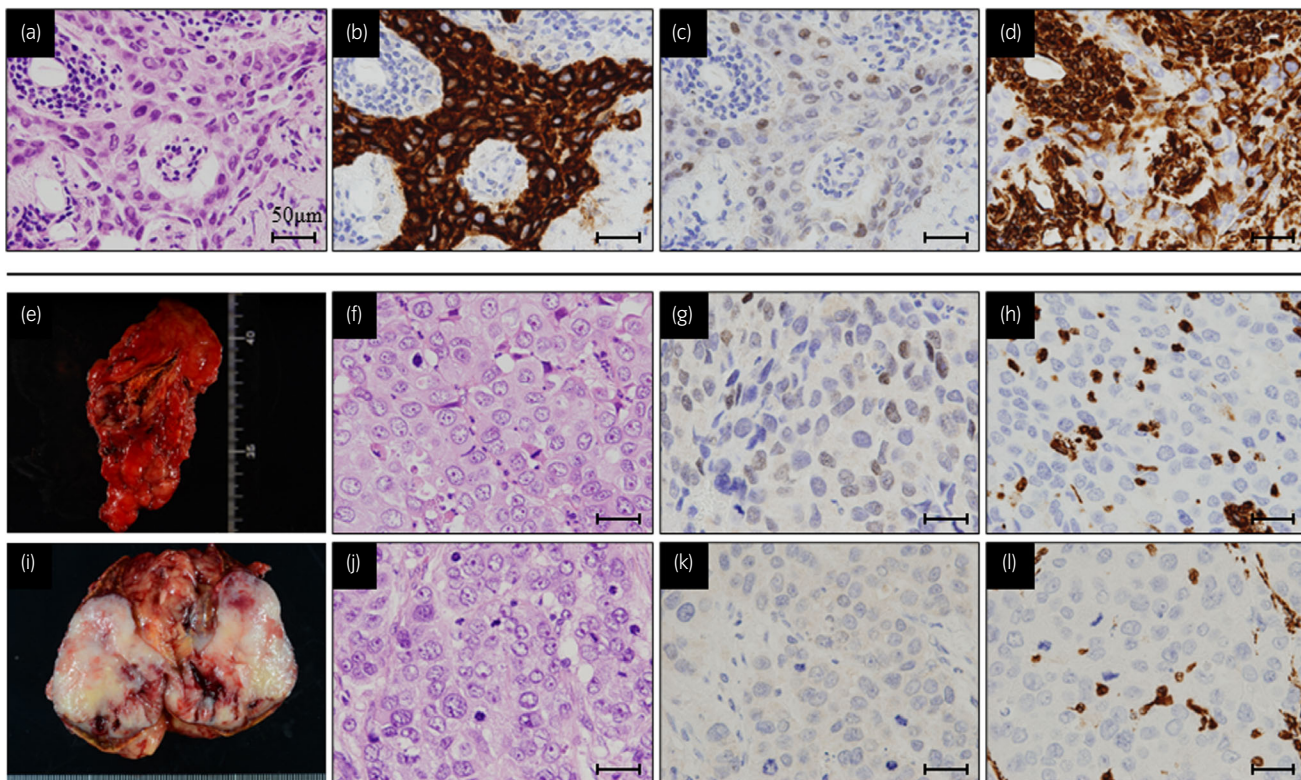
hydrocortisone. After an additional four cycles of immunochemotherapy (Ram, Doc), he was monitored as an outpatient, and was in remission for more than 4 years after the last surgery without any adrenal insufficiencies.

## Discussion

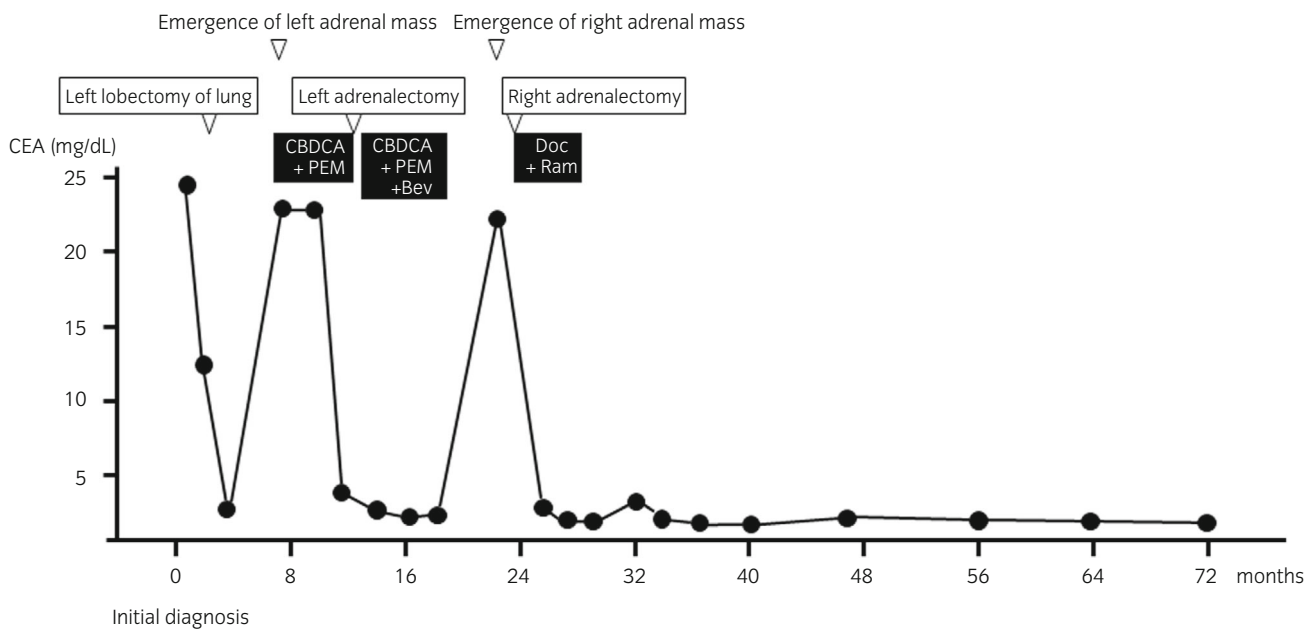
Unilateral AM identified with initial treatment of NSCLC were generally classified as synchronous metastases; metastases not present when initial treatment was started were categorized as metachronous. Up to 4% of patients with operable NSCLC are estimated to have a synchronous unilateral AM. However, no consensus exists for the management of isolated AM of NSCLC.<sup>11</sup> Recently, in an analysis of a limited series or several case reports, the long-term survival of patients who underwent a surgical resection of isolated AM, including laparoscopic procedures, was published.<sup>5,9,12,17,18</sup> Patients showed an average 5-year survival of 25%.<sup>3</sup> However, metachronous bilateral AM, as in our case, was rare. In an analysis of 43 patients who underwent the surgical removal of a solitary AM of NSCLC, only one case in 11 metachronous AM of NSCLC showed a recurrence in the contralateral adrenal gland.<sup>18</sup> In view of the surgical strategy for AM of NSCLC, no unified guidelines exist on whether a radical or partial adrenalectomy should be performed. In the clinical course of our case, a partial adrenalectomy of the left AM could have been completed the first time. Therefore, an AE1/3 immunostain of the left adrenal tumor specimen was performed (Fig. 4). As a result, the dissemination of multiple tumor cells positive for AE1/3 (Fig. 4c,d), was recognized, apart from the mass, as not being detected by HE staining (Fig. 4a,b). Therefore, it is reasonable to select a radical adrenalectomy from the viewpoint of cancer control. In addition, an intraoperative renal capsule injury led to a high risk of retroperitoneal dissemination after the surgical removal of



**Fig. 1** Contrast-enhanced CT (a) revealed a 15 × 12-mm-sized substantial mass in the left adrenal cortex with positive accumulation on FDG-PET/CT (b) (white arrowheads). CT showed a 60 × 24-mm-sized mass in the right adrenal cortex (c) with positive accumulation on FDG-PET/CT (d) (Black arrowheads).



**Fig. 2** Pathological findings of surgical resection of left upper lobe of the lung. HE staining (a) revealed a poorly differentiated adenocarcinoma; immunohistochemical staining was positive for AE1/3 (b), TTF-1 (c), and negative for vimentin (d). Pathological findings of surgical resection of left adrenal gland (e). HE staining (f) revealed metastasis of a poorly differentiated adenocarcinoma that originated from the lung; immunohistochemical staining was weakly positive for TTF-1 (g), and negative for vimentin (h). Pathological findings of surgical resection of right adrenalectomy (i). HE staining (j) revealed metastasis of a poorly differentiated adenocarcinoma that originated from the lung; immunohistochemical staining was negative for TTF-1 (k) and vimentin (l).

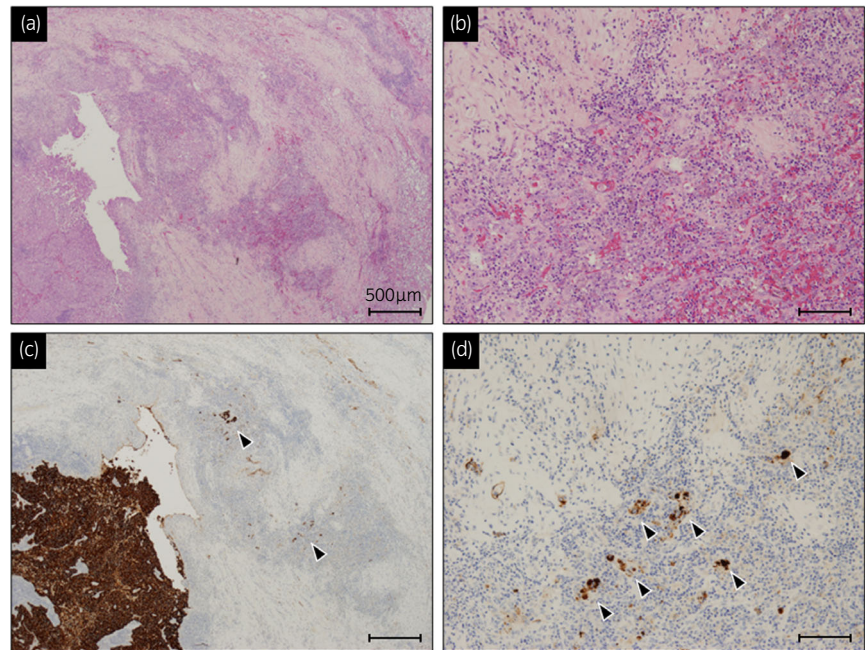


**Fig. 3** Clinical course and transition of serum CEA level in this case.

AM.<sup>4</sup> Therefore, reflecting on the clinical course of our case and findings, a radical wide resection of the mass, including

the adrenal gland, should be considered first to control this rare malignant entity.





**Fig. 4** The pathological analysis by immunochemical staining of AE1/3 of a left adrenal tumor specimen. The dissemination of multiple tumor cells (black arrowheads) with positive staining of AE1/3 (c, d) was recognized, apart from the mass, that could not be detected by HE staining (a, b).

In the treatment of AM of NSCLC, surgical removal without systemic treatment is not usually recommended, although the evidence is unclear. Additional treatment after surgical removal did not have a positive effect on prognosis.<sup>8</sup> However, cases were limited, and the retrospective nature of the study and selection bias may have led to an overestimation of efficacy. From a combination treatment point of view, the addition of systemic chemotherapy after adrenalectomy, rather than chemotherapy alone, could prolong survival for patients with AM of NSCLC.<sup>7</sup> In a retrospective analysis of 37 patients with AM that mainly originated from the lung, more than 6 months of disease-free survival with systemic treatment after radical surgery of the primary lesion could be a favorable prognostic factor compared with that of less than 6 months.<sup>13</sup> Undoubtedly the pathogenesis of AM of NSCLC is a very aggressive one; thus, a combination of sequential treatment of surgical removal following systemic immunochemotherapy might be needed to control the disease, as in our case. Further prospective trials are required in future to assess such combination strategic approaches in patients with AM of NSCLC.

## Conclusion

We experienced a case of bilateral metachronous AM of NSCLC that was controlled by surgical resections and systemic treatment. This suggests that the prognosis of this disease can be extended by the appropriate surgical indication combined with systemic treatment.

## Author contributions

Nami Tomiyama: Conceptualization; data curation; writing – original draft. Taku Naiki: Conceptualization; writing – review and editing. Aya Naiki-Ito: Data curation. Tatsuya Kawai: Data

curation. Toshiki Etani: Data curation. Masakazu Gonda: Data curation. Maria Aoki: Data curation. Toshiharu Morikawa: Data curation. Yosuke Sugiyama: Data curation. Takahiro Yasui: Supervision; writing – review and editing.

## Conflict of interest

The authors declare no conflict of interest.

## Approval of the research protocol by an Institutional Reviewer Board

The ethics committees of Nagoya City University Graduate School of Medical Sciences gave approval for this study (#1574) and written informed consent was obtained in accordance with the World Medical Association Helsinki Declaration.

## Informed consent

The patient gave written informed consent for the publication of this article and associated images.

## Registry and the Registration No. of the study/trial

Not applicable.

## References

- Zhang RM, Pan CW, Shen ZJ *et al.* [Surgical treatment of 486 cases of adrenal gland diseases: a retrospective study]. *Zhonghua Wai Ke Za Zhi* 2007; **45**: 1694–6. (In Chinese.)
- Lam KY, Lo CY. Metastatic tumours of the adrenal glands: a 30-year experience in a teaching hospital. *Clin. Endocrinol.* 2002; **56**: 95–101.

- 3 Kitamura S, Fujinaga T, Ohkawa T *et al.* [A case of metastatic adrenal cancer: with a statistical analysis based on annals of the pathological autopsy cases in Japan in the past 5 years]. *Nihon Hinyokika Gakkai Zasshi* 1982; **73**: 1324–32. (In Japanese.)
- 4 Ishidoya S, Kaiho Y, Arai Y. Characteristics and surgical treatments for patients with metastatic adrenal tumor. *Nihon Naibunpi Gakkai Zasshi* 2013; **30**: 45–9.
- 5 Nakanishi S, Hori D, Maeda S, Hatayama T. [Open adrenalectomy for adrenal metastases from lung cancer – usefulness and problem of laparoscopic adrenalectomy]. *Hinyokika Kiyo* 2006; **52**: 757–60. (In Japanese.)
- 6 Ikeda S, Yokota S, Hoshino T. The 54th Annual Meeting of the Japan Lung Cancer Society, 2013 Nov 21–22; Tokyo.
- 7 Raz DJ, Lanuti M, Gaissert HC, Wright CD, Mathisen DJ, Wain JC. Outcomes of patients with isolated adrenal metastasis from non-small cell lung carcinoma. *Ann. Thorac. Surg.* 2011; **92**: 1788–92; discussion 1793.
- 8 Mercier O, Fadel E, Mussot S *et al.* Faut-il opérer les métastases surrénales isolées des cancers bronchopulmonaires non à petites cellules? [Is surgery required for patients with isolated adrenal metastasis of non-small cell lung carcinoma?]. *Presse Med* 2007; **36**: 1743–52. (In French.)
- 9 Shibata M, Tada Y, Seki M *et al.* The two case of laparoscopic adrenalectomy for diagnosed adrenal metastasis. *Matsuyama R. C. Hosp. J. Med* 2012; **37**: 39–43.
- 11 Luketich JD, Burt ME. Does resection of adrenal metastases from non-small cell lung cancer improve survival? *Ann. Thorac. Surg.* 1996; **62**: 1614–6.
- 12 Kita M, Tamaki G, Okuyama M, Saga Y, Kakizaki H. Adrenalectomy for metastatic adrenal tumors. *Hinyokika Kiyo* 2007; **53**: 761–6.
- 13 Kim SH, Brennan MF, Russo P, Burt ME, Coit DG. The role of surgery in the treatment of clinically isolated adrenal metastasis. *Cancer* 1998; **82**: 389–94.
- 14 Twomey P, Montgomery C, Clark O. Successful treatment of adrenal metastases from large-cell carcinoma of the lung. *JAMA* 1982; **248**: 581–3.
- 15 Paul CA, Virgo KS, Wade TP, Audisio RA, Johnson FE. Adrenalectomy for isolated adrenal metastases from non-adrenal cancer. *Int. J. Oncol.* 2000; **17**: 181–7.
- 16 Bretcha-Boix P, Rami-Porta R, Mateu-Navarro M, Hoyuela-Alonso C, Marco-Molina C. Surgical treatment of lung cancer with adrenal metastasis. *Lung Cancer* 2000; **27**: 101–5.
- 17 Porte H, Siat J, Guibert B *et al.* Resection of adrenal metastases from non-small cell lung cancer: a multicenter study. *Ann. Thorac. Surg.* 2001; **71**: 981–5.
- 18 Lucchi M, Dini P, Ambrogio MC *et al.* Metachronous adrenal masses in resected non-small cell lung cancer patients: therapeutic implications of laparoscopic adrenalectomy. *Eur. J. Cardiothorac. Surg.* 2005; **27**: 753–6.

## Editorial Comment

### Editorial Comment on A rare case of long-term survival from metachronous bilateral adrenal metastasis of lung adenocarcinoma after combined surgical removal and immunochemotherapy

In clinical practice, urologists encounter adrenal gland metastasis from other malignancies occasionally. Most cases are presented with unilateral metastatic lesions in the adrenal gland, although limited cases are demonstrated with bilateral adrenal metastasis. Usually, unilateral resection of the adrenal gland with metastatic lesion could be indicated in case the patient only has unilateral adrenal gland metastasis and clinically permitted general condition and acceptable prognosis due to adrenal function preservation even after unilateral adrenal surgical removal. Based on experience, patients with lung or gastric cancer are frequently consulted by the urology department for adrenal metastasis treatment. Recently, both cancers have been attempted to be treated with immunotherapy and combined immunochemotherapy using a molecular target drug.<sup>1,2</sup> The national cancer comprehensive network guideline for nonsmall cell lung cancer has defined to use immunotherapy or immunochemotherapy drugs due to exhaustive gene expression analysis. For instance, described genetic abnormalities include sensitizing EGFR mutation, ALK rearrangement, ROS1 rearrangement, BRAF V600E mutation, NTRK gene fusion, and more than certain PD-L1 expression percentage. Each genetic abnormality corresponds to one to six recommended treatment regimens orderly.<sup>3</sup> Therefore, lung cancer could be positioned as a systematized disease regarding the standardization of genetic examination

for personalized medicine treatment decision. From the perspective of clinical sample acquisition for genetic testing, adrenal metastasectomy is worthwhile for respiratory and oncology physicians who are mainly responsible for the patients. Besides lung cancer, other cancers have also started to be treated using the same methods.

In this case study, the patient underwent combined systemic lung cancer treatment and laparoscopic right adrenalectomy. Subsequent laparoscopic left adrenalectomy and systemic treatment led to the 4-year progression-free survival.<sup>4</sup>

The case study reminds urologists to have courage to conduct resection of both sides of the adrenal glands to achieve a cancer-free condition with permanent adrenal hormone replacement after screening the patient's background, general conditions, and drug compliance.

## Acknowledgment

I thank editage, an English correction company, for the English corrections.

Manabu Kato M.D., Ph.D. 

Department of Urology, Aichi Cancer Center Hospital,  
Nagoya, Japan

katouuro@clin.medic.mie-u.ac.jp

DOI: 10.1002/iju5.12529

This is an open access article under the terms of the [Creative Commons Attribution](#) License, which permits use, distribution and reproduction in any medium, provided the original work is properly cited.

## Conflict of interest

The authors declare no conflict of interest.