

ORAL PRESENTATION

Open Access

# Ungated cine first-pass CMR for concurrent imaging of myocardial perfusion defects and wall motion abnormalities

Behzad Sharif<sup>1\*</sup>, Rohan Dharmakumar<sup>1</sup>, Reza Arsanjani<sup>1</sup>, Louise E Thomson<sup>2</sup>, Noel Bairey Merz<sup>2</sup>, Daniel S Berman<sup>2</sup>, Debiao Li<sup>1</sup>

From 16th Annual SCMR Scientific Sessions  
San Francisco, CA, USA. 31 January - 3 February 2013

## Background

Combined assessment of wall motion from cine imaging and perfusion defects from first-pass perfusion (FPP) imaging has been shown to have a high diagnostic performance for detection of acute ischemia. In this setting, a single ungated CMR scan capable of simultaneously capturing perfusion deficits and wall motion abnormality can be useful for rapid diagnosis of ongoing acute ischemia. We propose an accelerated FPP technique with ungated continuous acquisition capable of generating cardiac-phase resolved FPP images thereby enabling concurrent imaging of wall motion and perfusion deficits.

## Methods

FPP imaging without magnetization preparation using a steady state acquisition has been described before [1] and seen recent interest [2,3], wherein the focus has been on acquiring one image during the quiescent phase. Canines with reversible ischemia were studied (N=5; >90% LAD stenosis for 4, no stenosis for 1). Resting FPP data was acquired on a 3T scanner (Siemens Verio) using an ungated RF-spoiled GRE sequence with continuous golden-angle radial acquisition of 1 slice (called "cine FPP"; resolution: 1.5x1.5x6 mm, 30 sec scan, 13000 projections, flip=14°). All scans were performed 7±2 minute post occlusion and the mean heart rate (HR) was 98 bpm. Image reconstruction was performed using a regularized iterative SENSE scheme (temporal resolution: 61 ms). For comparison, a conventional gated SR-prepared FLASH "standard FPP" scan was also acquired.

## Results

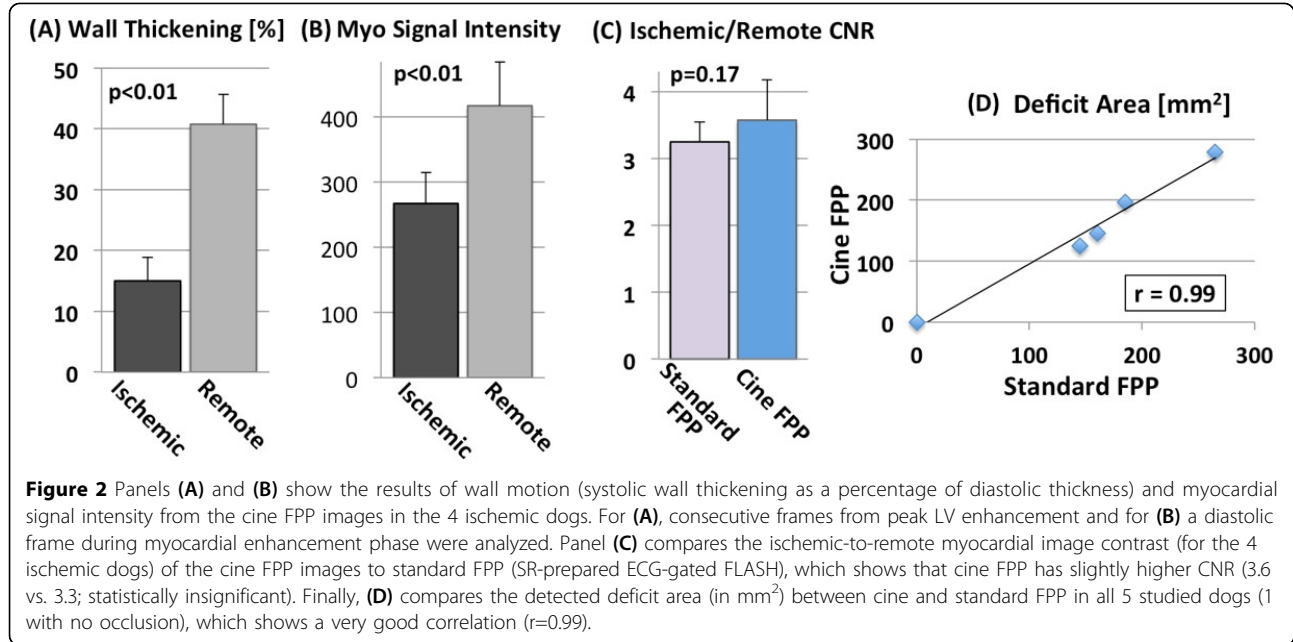
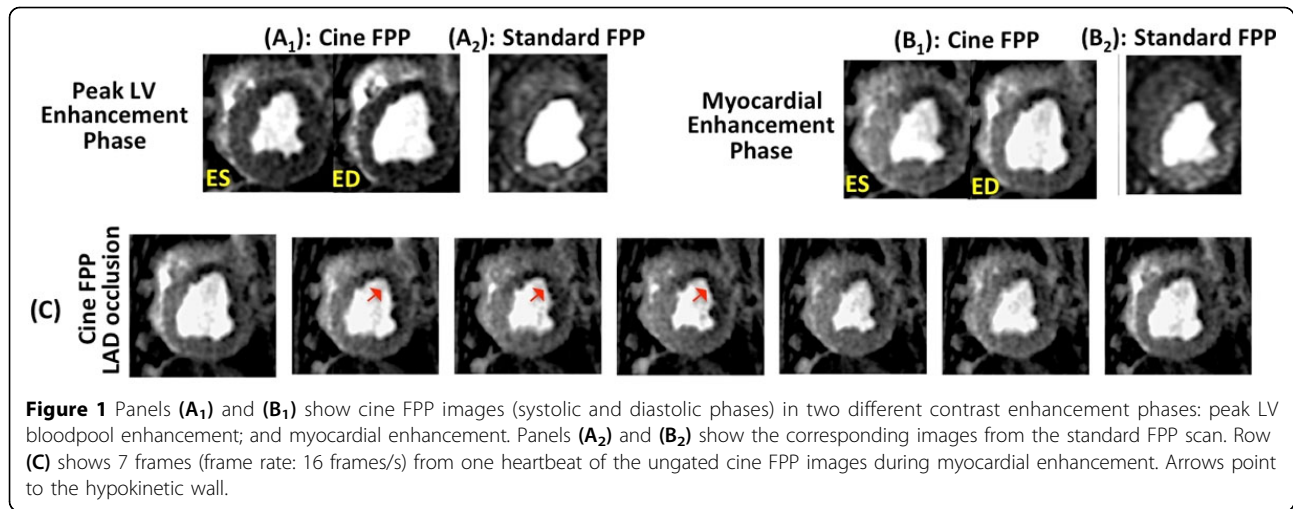
The top row of Fig. 1 shows cine FPP images (systolic/diastolic) in peak LV and myocardial enhancement phases, along with the corresponding images from the standard FPP scan. Fig. 1(C) shows 7 frames (16 frames/s) from the cine FPP in the myocardial enhancement phase. Arrows point to hypokinesia. Figs. 2(A)-(B) show the result of wall motion and myocardial signal intensity analysis from the cine FPP images. Fig. 2(C) compares the myocardial contrast properties of the cine FPP images to standard FPP, showing similar ischemic-to-remote CNR. Finally, 2(D) compares the detected deficit area between cine and standard FPP, showing a positive correlation ( $r=0.99$ ).

## Conclusions

We have demonstrated, for the first time, the feasibility and effectiveness of ungated cardiac-phase resolved (cine) FPP imaging for concurrent imaging of myocardial wall motion and perfusion in an animal model with flow-limiting stenosis. The presented method may improve the feasibility of detecting acute myocardial ischemia using CMR because of its reduced scan time (single scan for both cine and FPP) and reduced complexity (no cardiac gating). It may also enhance the accuracy and speed of diagnosis by virtue of concurrent (inherently fused) imaging of wall motion and FPP. The presented results demonstrate that the method is capable of imaging at high HRs with high spatial and sufficient temporal resolution. While the current method is limited to imaging a single slice during a breathhold, it can potentially be extended to 3D through spatio-temporal acceleration.

<sup>1</sup>Biomedical Imaging Research Institute, Cedars-Sinai Medical Center, Los Angeles, CA, USA

Full list of author information is available at the end of the article



## Funding

Grant sponsors: American Heart Association Postdoctoral Fellowship Award 11POST7390063; National Institutes of Health grants nos. NHLBI HL38698, HL091989.

doi:10.1186/1532-429X-15-S1-O1

Cite this article as: Sharif *et al.*: Ungated cine first-pass CMR for concurrent imaging of myocardial perfusion defects and wall motion abnormalities. *Journal of Cardiovascular Magnetic Resonance* 2013 **15**(Suppl 1):O1.

## Author details

<sup>1</sup>Biomedical Imaging Research Institute, Cedars-Sinai Medical Center, Los Angeles, CA, USA. <sup>2</sup>Heart Institute, Cedars-Sinai Medical Center, Los Angeles, CA, USA.

Published: 30 January 2013

## References

- Judd: *MRM* 1995, **34**.
- DiBella: *MRM* 2012, **67**.
- Giri: *ISMRM* 2012, 3890.