



Different follow-up OCT analyses of traumatic optic neuropathy. A case report

Alicia López-de-Eguileta, Alfonso Casado*

Department of Ophthalmology, University Hospital Marqués de Valdecilla-IDIVAL, Santander, Spain

ARTICLE INFO

Keywords:

Traumatic optic neuropathy
Optical coherence tomography
Ganglion cell layer
Retinal nerve fiber layer

ABSTRACT

Purpose: Optical coherence tomography (OCT) is established as a promising technology for assessing the optic nerve atrophy progression after trauma. However, reports on the effectiveness and sensitivity of ganglion cell layer (GCL) and Bruch's membrane opening-minimum rim width (BMO-MRW) for studying this damage course over time are still lacking.

Observations: A 53-year-old man with severe optic nerve trauma had repeated OCT scans of the retinal nerve fiber layer (RNFL), GCL and BMO-MRW during 12 months after the injury. There was gradual damage in all measurements. Interestingly, BMO-MRW was the first analysis affected whilst GCL showed the greatest damage over time.

Conclusions: Our outcomes suggest that OCT might be able to assess axonal loss after traumatic optic neuropathy. BMO-MRW measurement might be more sensitive than other analyses in the first two weeks after trauma and GCL might better monitor belated damage. Thus, it might be possible to combine all these sets of measurements to increase diagnostic sensitivity and specificity.

1. Introduction

Optical coherence tomography (OCT) technology has demonstrated to be useful for assessing optic nerve and macular thickness in vivo after a traumatic optic neuropathy (TON), using retinal nerve fiber layer (RNFL) and macular thickness measurement respectively.¹⁻⁴ Comparing both analyses, RNFL was documented to be the first damaged structure.⁵ However, the advances in technology allow the assessment of macular and optic nerve damage using ganglion cell layer (GCL) and Bruch's membrane opening-minimum rim width (BMO-MRW), respectively. Those measures have showed to be useful in glaucoma management,⁶⁻¹¹ but were never studied before in similar cases.

Our purpose was to evaluate longitudinally RNFL, BMO-MRW and GCL 12 months following one case with TON, starting the next day of the trauma. Similarly, we analyzed the progressive optic nerve atrophy with these measurements setting which is altered first in the course of optic nerve disease.

This case followed the principles of the Declaration of Helsinki and informed consent was obtained from the participant.

2. Case report

A 53-year-old man attended the emergency room due to a strong trauma to the left part of the face, and reported progressive and severe visual loss through the left eye (OS).

Presenting visual acuity was 20/20 (Snellen) in the right eye and light perception in the OS. Slit-lamp examination revealed no abnormal findings and dilated fundoscopic examination disclosed a normal optic nerve with no apparent cupping in both eyes at the first moment but it developed severe optic disc pallor on OS during the follow-up. A pupillary examination showed a relative afferent defect in OS. Systemic, neurological and neuro-imaging explorations were unremarkable. He was treated with oral prednisone tapering in five weeks, without improvement, and was diagnosed with TON.

After the screening examination, OCT scans were obtained sequentially after the accident: weekly during the first month, biweekly during the second month, once the third month, and one last time one year after. The main purpose was to evaluate GCL, BMO-MRW and RNFL measurements following TON, to compare with each other for detection

* Corresponding author. Ophthalmology Department, Hospital Marqués de Valdecilla. Av. Valdecilla, 25, 39008, Santander, Cantabria, Spain.
E-mail address: casadorjo@hotmail.es (A. Casado).

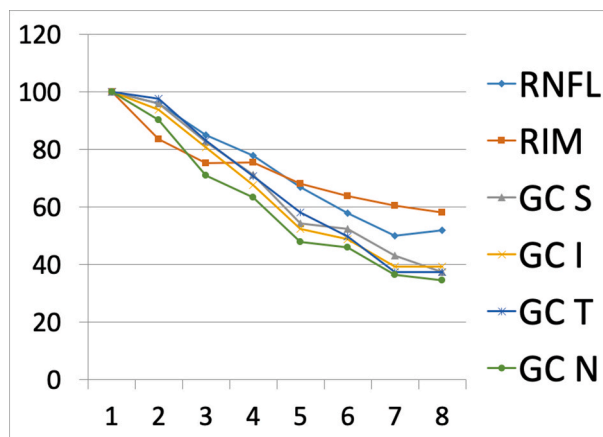


Fig. 1. Optical coherence tomography (OCT) values of percentages of different measures during follow-up. X-numbers represented the number of the visit. Retinal nerve fiber layer (RNFL); Bruch’s membrane opening-minimum rim width (RIM); ganglion cell layer (GC); Superior (S), Inferior (I), Temporal (T), Nasal (N).

of progressive axonal loss and to find out which set of measurements is altered first.

The patient underwent scanning by Spectralis OCT (Heidelberg Engineering, Dossenheim, Germany) and Spectralis OCT Glaucoma Module Premium (GMP). GMP edition provides RNFL protocol (RNFL-GMP), BMO overview and BMO rim analysis that measures neuroretinal rim tissue using the minimum distance from BMO to the internal limiting membrane.

As represented in Fig. 1, nasal sector of GCL showed the highest damage during the follow-up, saving the first week after the injury. At that moment, the strongest reduction was observed in BMO-MRW measure (12.4% of reduction) whilst the only test that showed color map damage was RNFL, as displayed in Fig. 2.

Six weeks after trauma, RNFL and BMO-MRW reduction analyses were 42% and 36% respectively, while GCL thickness reduction ranged between 54% and 48%. Accordingly, based on the values after trauma, RNFL, GCL and BMO-MRW thickness reduction at 12th week were 48%, 63–66 and 41.7%, respectively. Thus, the sequence of examinations showed a marked and progressive decrease in all measures, especially in nasal sector of GCL since the second week after the injury.

3. Discussion

Several studies have provided further evidence of direct employment of RNFL to assess axonal injury for glaucoma disease, optic nerve inflammation, demyelinating and compressive optic neuropathies.⁷⁻⁹ More recently, macular thickness measure was described as indicator of neural damage,^{10,11} because retinal ganglion cells’ bodies and dendrites accounts for up to 40% of the thickness in the macular area in retina.¹²

Regarding to TON, many studies have documented RNFL loss after eye trauma.¹³⁻¹⁶ Specifically, they concluded OCT shows RNFL loss earlier than scanning laser polarimetry (SLP), starting to decrease 20 days after the trauma.⁴ Macular thickness thinning has been reported lately. In one case, it was observed in conjunction with thinning of RNFL thickness⁴ whilst in another study, RNFL thickness reduction was greater and 2 weeks earlier than macular thinning.⁵

In the present study, in addition to RNFL, we analyze BMO-MRW and CGL measurements, reporting that a sequential progressive decrease occurred after trauma in all the tests. Aforementioned studies showed that the RNFL damage started 20 days after trauma (Medeiros) or even more (). Nevertheless, herein we report that the damage could be demonstrated since the very first week after trauma using color map of Spectralis OCT GMP RNFL and number values of BMO-MRW. Thus, these techniques could be used to depict early damage in these cases, and establish a visual prognosis and suggest a possible treatment as soon as possible.

In glaucoma studies, OCT-derived BMO-MRW analysis have provided significantly greater sensitivity¹⁷ and specificity⁶ than RNFL. Similarly, we report that the thinning was greater in BMO-MRW analysis than RNFL. However, GCL thickness showed the highest reduction, especially in nasal sector, during the follow-up, saving the first week. Hence, GCL might be useful to assess and follow the damage after optic nerve trauma. Nevertheless, this is only a case report and prospective studies should be conducted to properly assess this finding.

4. Conclusions

These outcomes suggest all these scans might be useful to monitor the axonal loss after TON. However, BMO-MRW and color map of Spectralis OCT GMP RNFL might be used in the first week to detect early damage whilst GCL might assist during the follow-up.

Patient consent is signed allowing us to publish his pictures.

Funding

No funding or grant support

Authorship

All authors attest that they meet the current ICMJE criteria for Authorship.

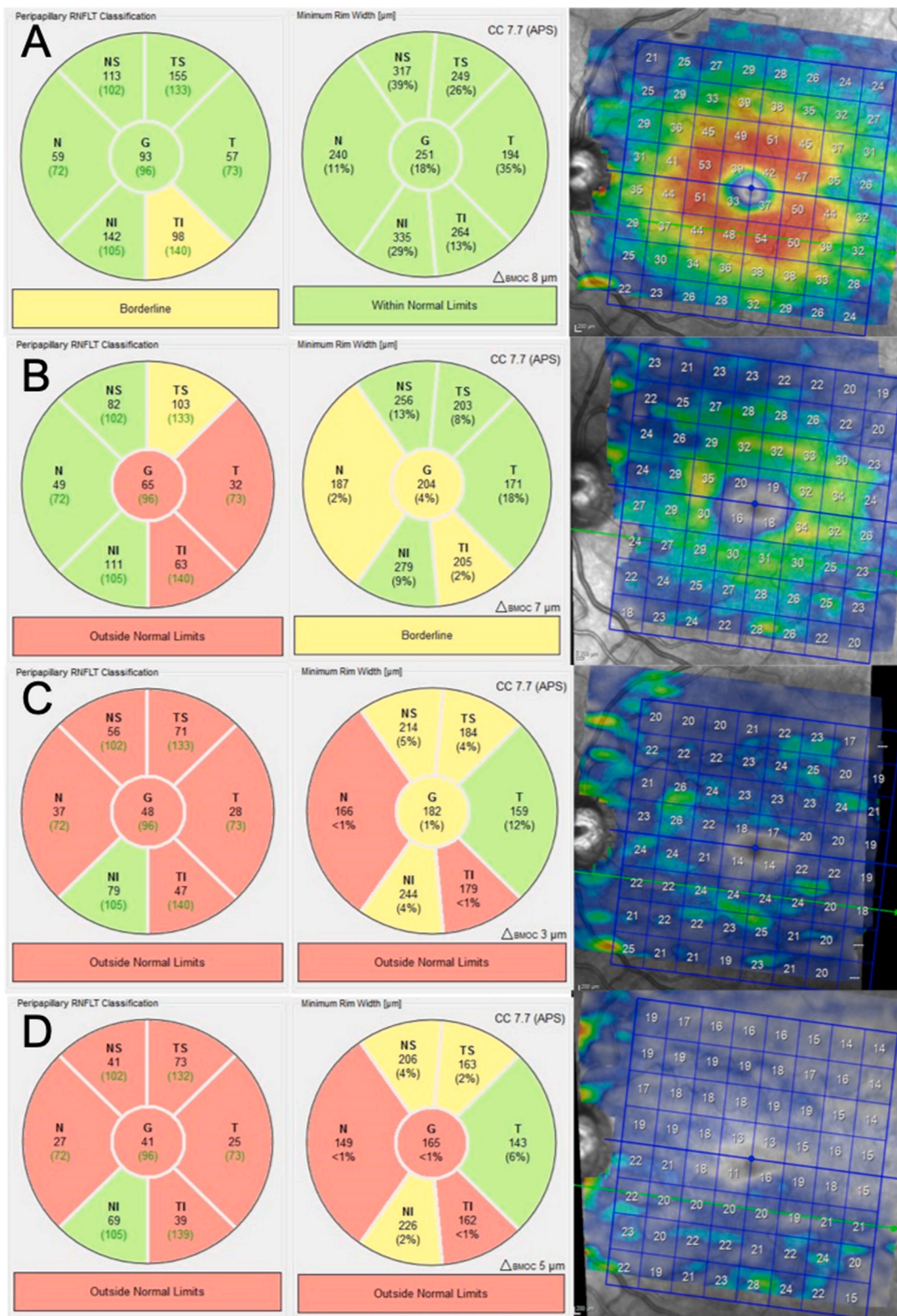


Fig. 2. Left eye Optical coherence tomography (OCT) follow-up during one year. Left column: retinal nerve fiber layer (RNFL), Middle column: Bruch’s membrane opening-minimum rim width (BMO-MRW), Right column: ganglion cell layer (GCL). A: (first week) color map RNFL showed temporal inferior sector damage, whilst color map BMO-MRW and GCL are preserved. B: (second month) color map RNFL showed damage in temporal sectors, BMO-MRW showed an inceptive nasal, central and temporal inferior damage and there was a manifest damage in GCL. C: (third month): color map RNFL reveal general injury in red, BMO-MRW had damage progression in almost all sectors and GCL showed some remnant of living cells in groups of green. D: (one year): color map RNFL remained similar, as BMO-MRW did, but there was even more GCL loss in the color map. (For interpretation of the references to color in this figure legend, the reader is referred to the Web version of this article).

Declaration of competing interest

The following authors have no financial disclosures: ALE, AC.

Acknowledgements

None.

References

- Huang D, Swanson EA, Lin CP, et al. Optical coherence tomography. *Science*. 1991; 254(5035):1178–1181.
- Moura FC, Medeiros FA, Monteiro ML. Evaluation of macular thickness measurements for detection of band atrophy of the optic nerve using optical coherence tomography. *Ophthalmology*. 2007;114(1):175–181.
- Medeiros FA, Moura FC, Vessani RM, Susanna Jr R. Axonal loss after traumatic optic neuropathy documented by optical coherence tomography. *Am J Ophthalmol*. 2003; 135(3):406–408.
- Vessani RM, Cunha LP, Monteiro ML. Progressive macular thinning after indirect traumatic optic neuropathy documented by optical coherence tomography. *Br J Ophthalmol*. 2007;91(5):697–698.
- Cunha LP, Costa-Cunha LV, Malta RF, Monteiro ML. Comparison between retinal nerve fiber layer and macular thickness measured with OCT detecting progressive axonal loss following traumatic optic neuropathy. *Arq Bras Oftalmol*. 2009 Sep-Oct; 72(5):622–625.
- Rebolleda G, Casado A, Oblanca N1, Muñoz-Negrete FJ. The new Bruch's membrane opening minimum rim width classification improves optical coherence tomography specificity in tilted discs. *Clin Ophthalmol*. 2016;10:2417–2425.
- Costa-Cunha LV, Cunha LP, Malta RF, Monteiro ML. Comparison of Fourier-domain and time-domain optical coherence tomography in the detection of band atrophy of the optic nerve. *Am J Ophthalmol*. 2009;147(1):56–63.
- Gao L, Liu Y, Li X, Bai Q, Liu P. Abnormal retinal nerve fiber layer thickness and macula lutea in patients with mild cognitive impairment and Alzheimer's disease. *Arch Gerontol Geriatr*. 2015;60:162–167.
- Kirbas S, Turkyilmaz K, Anlar O, Tufekci A, Durmus M. Retinal nerve fiber layer thickness in patients with Alzheimer disease. *J Neuro Ophthalmol*. 2013;33:58–61.
- Greenfield DS, Bagga H, Knighton RW. Macular thickness changes in glaucomatous optic neuropathy detected using optical coherence tomography. *Arch Ophthalmol*. 2003;121(1):41–46.
- Marziani E, Pomati S, Ramolfo P, Cigada M, Giani A, Mariani C, et al. Evaluation of retinal nerve fiber layer and ganglion cell layer thickness in Alzheimer's disease using spectral-domain optical coherence tomography. *Invest Ophthalmol Vis Sci*. 2013;54(9):5953–5958.
- Hinton DR, Sadun AA, Blanks JC, Miller CA. Optic-nerve degeneration in Alzheimer's disease. *N Engl J Med*. 1986;315:485–487.
- Kuo MT, Lai IC, Teng MC. Serial follow-up in traumatic optic neuropathy using scanning laser polarimetry and visual field testing. *Chang Gung Med J*. 2005;28(8): 581–586.
- Miyahara T, Kurimoto Y, Kurokawa T, Kuroda T, Yoshimura N. Alterations in retinal nerve fiber layer thickness following indirect traumatic optic neuropathy detected by nerve fiber analyzer, GDx-N. *Am J Ophthalmol*. 2003;136(2):361–364.
- Medeiros FA, Susanna Jr R. Retinal nerve fiber layer loss after traumatic optic neuropathy detected by scanning laser polarimetry. *Arch Ophthalmol*. 2001;119(6): 920–921.
- Meier FM, Bernasconi P, Stürmer J, Caubergh MJ, Landau K. Axonal loss from acute optic neuropathy documented by scanning laser polarimetry. *Br J Ophthalmol*. 2002; 86(3):285–287.
- Chauhan BC, O'Leary N, Almobarak FA, et al. Enhanced detection of open-angle glaucoma with an anatomically accurate optical coherence tomography-derived neuroretinal rim parameter. *Ophthalmology*. 2013;120:535–543.