



Case report

Laparoscopic dorsal subsegmentectomy 8: Exploit the 3d technology to plan liver resection, and predict intraparenchymal pedicles. A case report. (With video explanation)

F. Banchini^{a,*}, A. Romboli^a, N. Rizzi^b, E. Luzietti^a, L. Conti^a, P. Capelli^a

^a Department of General Surgery, Guglielmo da Saliceto Hospital, Piacenza, Italy

^b Department of Surgery at Università degli Studi di Parma, Italy

ARTICLE INFO

Keywords:

Three-dimensional
3D
Liver
Metastases
Laparoscopy
Hepatectomy
MILS

ABSTRACT

Introduction: Laparoscopic liver surgery is spreading, encouraged by technical and technological improvement. Both the obligated narrow space and the difficulty to modify it lead to a more complex approach to the lesions located in the posterosuperior portion of the liver. Surgical strategies such as the Caudal approach or the Diamond technique could ameliorate surgical procedure, but these areas remain a challenge and are still classified as complex.

Clinical case: We discuss the case of a 68 year old man with metachronous liver metastasis in the dorsal part of segment 8. We used portal phase CT-scan Dicom data to create Three-dimensional reconstruction, which was able to show the more distal branches of intraparenchymal structures. The reconstructed images were subsequently used to plan laparoscopic liver resection.

Discussion: The capability of three-dimensional reconstruction to create a realistic image allows us to use ultrasound as a navigation tool. Exploiting these two technologies together, we arrived to regulate the resection stages by recognizing previously marked structures and searching them at every intervention phase. The strategy performed demonstrates both a high level of precision and the capability to predict intraparenchymal structures.

Conclusion: The advantages obtained from three-dimensional reconstruction are numerous in terms of either anatomical comprehension and technical precision, suggesting a potential improvement in surgical skill. Three-dimensional technology should be encouraged and spread to understand, in every single aspect, the potential of its use.

1. Introduction

Laparoscopic liver resections (LLR) are becoming increasingly popular, encouraged by the spread of consensus conferences pushing for their use [1]. The lesions in the posterosuperior areas are still classified as complex [2,3] and, for this reason, performed only in centers with high volumes and high experience. The application of technical strategies, such as the caudal approach [4] or the diamond technique [5], has increased the knowledge of how to perform these operations safely. Still, the diffusion remains poor and restricted to anterior segments. The advantage of LLR has become evident by extending surgical indication even in child b hepatocarcinoma [6–8], suggesting an impetus for its widespread use.

The presence of narrow spaces, difficult to modify, still makes

laparoscopy a challenge and ultrasound interpretation more complex than in open surgery. The patient-specific anatomy remains essential to perform liver resection, which is intensified in laparoscopic surgery, avoiding making complex or problematic resections that would be simple in open surgery.

Indeed, the comprehension of patient-specific anatomy becomes a pivotal point in order to understand the capability and the modality to perform surgery.

Interpretation of two-dimensional images, based on CT scan and MRI slices, is not able to put in evidence peripheral structures, but now it may be overcome with three-dimensional reconstructions.

In the following clinical case, we discuss how to exploit three-dimensional reconstruction to plan liver resection, predicting intraparenchymal resected structures.

* Corresponding author at: Guglielmo da Saliceto Hospital, Via Taverna 49, 29100 Piacenza, Italy.

E-mail address: filippobanchini@virgilio.it (F. Banchini).

<https://doi.org/10.1016/j.ijscr.2021.106516>

Received 30 September 2021; Accepted 13 October 2021

Available online 18 October 2021

2210-2612/© 2021 Published by Elsevier Ltd on behalf of IJS Publishing Group Ltd. This is an open access article under the CC BY-NC-ND license

(<http://creativecommons.org/licenses/by-nc-nd/4.0/>).

2. Clinical case

We present the case of a 68y/o man with history of mild hypertension, who had been submitted to sigmoid laparoscopic resection for a pT3N0 G1 adenocarcinoma three years before. During the follow-up, single liver metastasis of 3,5 cm was discovered in the dorsal part of segment 8. The multidisciplinary discussion indicated liver resection and dorsal subsegmentectomy eight was planned.

3. Methods

Portal phase CT-scan was used to create three-dimensional reconstruction with InVesalius software. In a semiautomatic manner, the reconstruction creates the portal and hepatic vein ramification till the third order or more, the lesion and the liver. We overlaid the CT scan's axial, coronal and sagittal images to the three-dimensional reconstruction, creating the hypnotized resection area (Fig. 1).

To make the interpretation more accessible, we compared the resection area to a cube, in which the lower vertex could correspond to an intraparenchymal structure, both visible on three-dimensional reconstruction and during the intraoperative ultrasound (Fig. 2).

The first author executed both the intervention and the three-dimensional reconstruction, assisted by two other operators in April 2021. The patient was placed in left lateral decubitus with the right arm raised. A laparoscopic column and a computer, with 3D reconstruction available for consultation, were positioned at the patient's back. Five trocars were placed in a semicircular arrangement in the right upper quadrant, and supplementary access was made in the left quadrant for the Pringle maneuver. The procedure (more details in the video) started with the section of round and falciform ligaments, exposition of the right margin of the vein cava, the origin of the right hepatic vein, and complete mobilization of the right liver. This maneuver allows the rotation of the liver and anteriorization of segment 8. A preliminary ultrasound was done to identify the site of the lesion and mark, on the liver surface, the edges of the hypothetical cube, allowing us to join the deep vertex corresponding to the branch of the right hepatic vein chosen for landmark. The dissection was conducted with intermitted clamping of 10 + 5 min. In the beginning, the dissection followed the two faces descending from the marked edges. In this stage, we encountered and dissected three structures previously hypothesized. The vein corresponding to the cubic vertex was joined and dissected (Fig. 3). This point was used as a marker for changing the direction plan from vertical to

horizontal. We enlarged the lateral dissection to facilitate the dissection of the horizontal plan, where we found two more predicted pedicles and one small missed one (showed in the video). Ultrasound demonstrated the correct distance at the bottom of the lesion. The dissection of the horizontal plan was done, and the two portal pedicles predicted were recognized and sectioned with a stapler device. The dissection was curved to join the distal superficial edge of the dissection area, where two more predicted vessels were found. Total intervention time was 240 min, and blood loss was less than 150 cc. The postoperative course was uneventful, and the patient was discharged after six days. At the moment, the patient is in good condition and under folfox chemotherapy.

4. Discussion

The diffusion of 3d technology is progressively increasing, and its advantage becomes more evident in the visualization of solid organs and the distribution of inside structures. Its realistic effect puts the surgeon at a big advantage, allowing a sort of conceptual evolution in which the necessity of mental reconstruction of the organ inside structures becomes realistic with a high level of precision. In this way, the surgeon could overtake this effort, focusing his concentration on the real anatomical distribution of the structures, even the smallest and most peripheral ones. This capability brings the surgeon near the concept of surgical spearing of the cone unit [9] in liver surgery, understanding the inner structures and their realistic position. Never the less the surgical procedure moves from “dissect-and-find” to “dissect-to-find” the structures, even for the smallest pedicles.

Moreover, when ultrasound is performed, the possibility to compare it in real-time with 3d reconstruction allows a better interpretation. Together, they become strategical instruments to arrange the intraparenchymal structures in the space. As proposed in our description, we used ultrasound to verify and search the inside anatomy and recognize the markers structures overlapping with the hypothesized cube's vertex by exploiting this principle. The application of 3d reconstruction allows us to make closer two different technical concepts of “cone unit resection” with “the diamond technique” dissection.

Exploiting the 3d technology, the surgeon can concentrate on the specific anatomy of the patient organ and arrive to predict the stages of a procedure. Gathering all these technical and instrumental patterns could progress to the “Precision Surgery” [10] concept with many advantages for both the patient and the surgeon. As recently demonstrated by Zhang

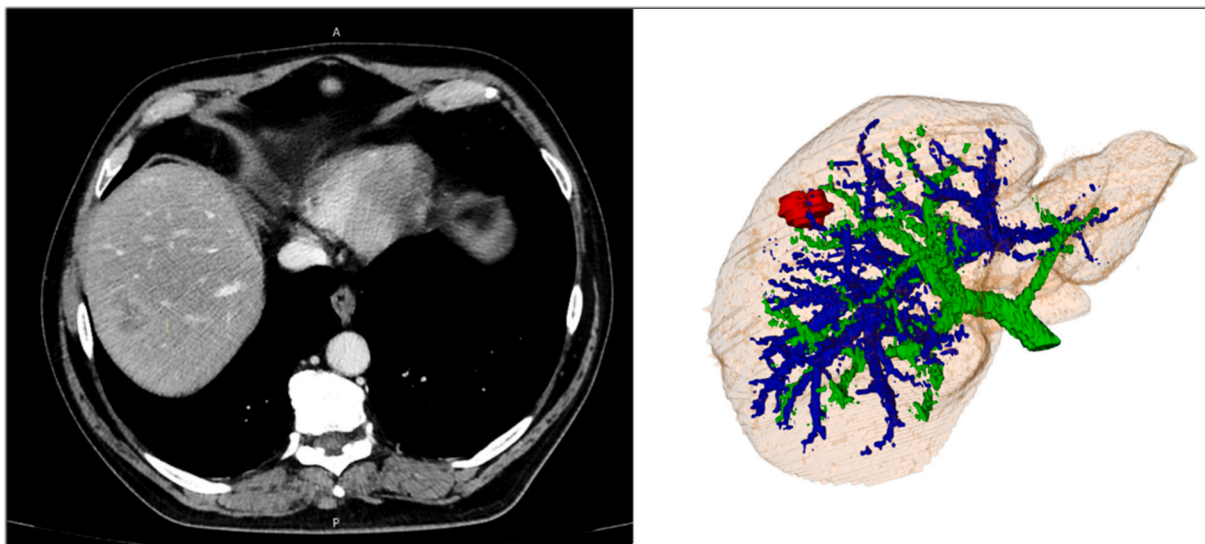


Fig. 1. Ct scan with three-dimensional reconstruction: In green portal branches; in blue hepatic veins; in red liver metastases. (For interpretation of the references to colour in this figure legend, the reader is referred to the web version of this article.)

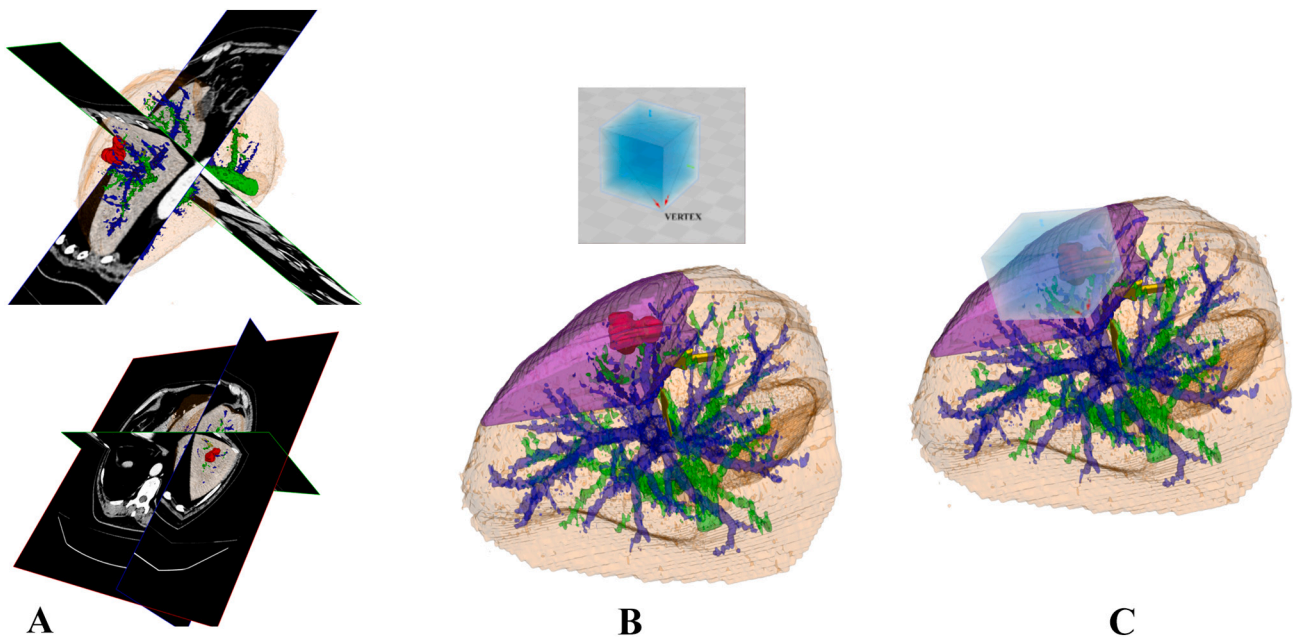


Fig. 2. A) Three-dimensional reconstruction with overlaid coronal axial and sagittal Ct scan images around the metastases; B) volume of resection area as presented in A and cubic image with vertex corresponding to the marked vein (yellow arrows); C) overlapped cubic image corresponding to internal marked position (yellow arrows). (For interpretation of the references to colour in this figure legend, the reader is referred to the web version of this article.)

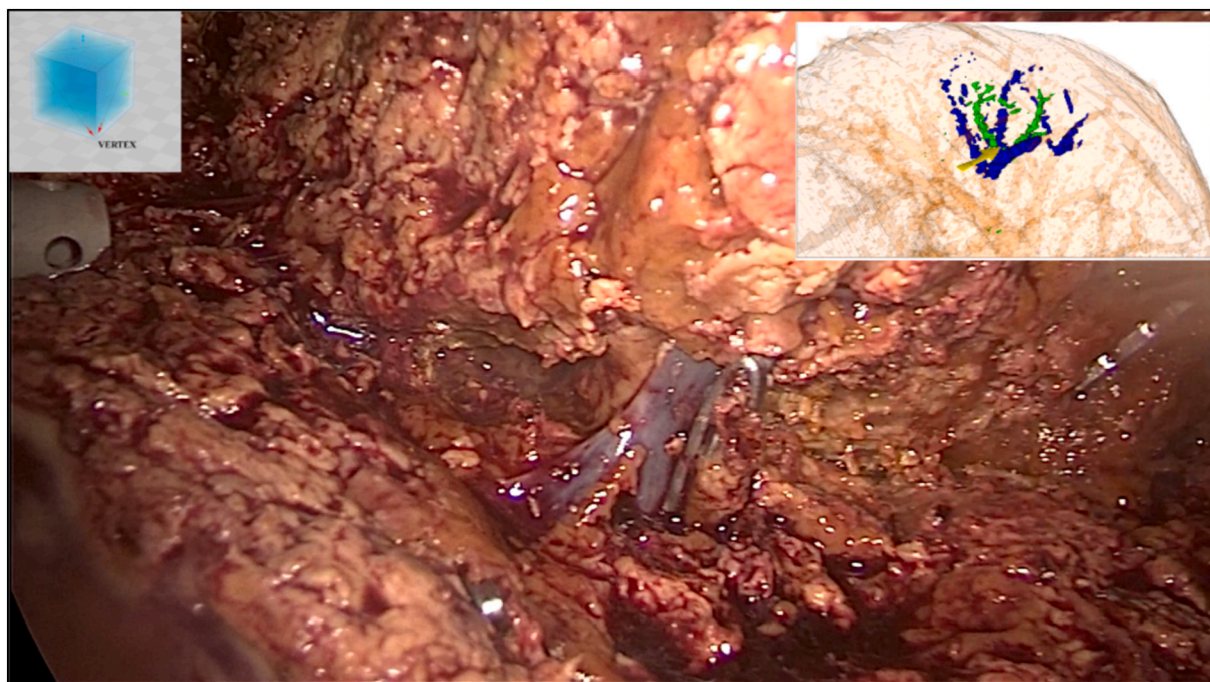


Fig. 3. Intraoperative image showing the marked hepatic vein corresponding to the vertex of hypothesized cubic image and three-dimensional reconstruction.

[11] in a randomized trial, the use of 3d reconstruction can reduce the complication rate in terms of blood loss and biliary fistula, suggesting the real advantage of this technology.

Considering our experience and the recent growing diffusion in the literature, 3d technology should be a topic to spread and implement for the countless advantages it can bring.

5. Conclusion

The advantages that we could obtain from 3d reconstruction are

numerous in terms of anatomical comprehension, technical precision, and reduction in complications. Understanding the strategies to improve and facilitate 3d use must be disseminated and encouraged.

The case report follows both the SCARE and PROCESS Guidelines [12–14].

Supplementary data to this article can be found online at <https://doi.org/10.1016/j.ijscr.2021.106516>.

Sources of funding

No found sources.

Ethical approval

No ethical approval is required, because it is a single case report and the patient signed consent form for publication.

Consent

Written informed consent was obtained from the patient for publication of this case report and accompanying images. All reported images and discussion protect anonymity.

Registration of research studies

Not applicable.

Guarantor

Filippo Banchini.

Provenance and peer review

Not commissioned, externally peer-reviewed.

CRedit authorship contribution statement

Banchini Filippo: Conceptualization, Methodology, Software, Resources, Writing - Original Draft, Writing - Review & Editing, Visualization, Supervision, Project administration.

Romboli Andrea: Data collection, revision, approval of final manuscript.

Rizzi Nicolas: Data collection, revision, approval of final manuscript.

Luzietti Enrico: Data collection, revision, approval of final manuscript.

Conti Luigi: Data collection, revision, approval of final manuscript.

Capelli Patrizio: Data collection, revision, approval of final manuscript.

Declaration of competing interest

The authors report no declarations of interest.

References

- [1] G. Wakabayashi, From Louisville to Morioka: where is now MILS? *Updat. Surg.* 67 (2015) 101–104, <https://doi.org/10.1007/s13304-015-0310-7>.
- [2] J.Y. Cho, H.-S. Han, G. Wakabayashi, O. Soubrane, D. Geller, N. O'Rourke, J. Buell, D. Cherqui, Practical guidelines for performing laparoscopic liver resection based on the second international laparoscopic liver consensus conference, *Surg. Oncol.* 27 (2018) A5–A9, <https://doi.org/10.1016/j.suronc.2017.12.003>.
- [3] Maastricht University Medical Center, The ORANGE SEGMENTS - Trial: An International Multicentre Randomized Controlled Trial of Open Versus Laparoscopic Parenchymal Preserving Postero-superior Liver Segment Resection, *clinicaltrials.gov*, 2020. <https://clinicaltrials.gov/ct2/show/NCT03270917>. (Accessed 30 December 2020).
- [4] O. Soubrane, L. Schwarz, F. Cauchy, L.O. Perotto, R. Brustia, D. Bernard, O. Scatton, A conceptual technique for laparoscopic right hepatectomy based on facts and oncologic principles: the caudal approach, *Ann. Surg.* 261 (2015) 1226–1231, <https://doi.org/10.1097/SLA.0000000000000737>.
- [5] F. Cipriani, V.G. Shelat, M. Rawashdeh, E. Francone, L. Aldrighetti, A. Takhar, T. Armstrong, N.W. Pearce, M., Abu hilal, laparoscopic parenchymal-sparing resections for nonperipheral liver lesions, the diamond technique: technical aspects, clinical outcomes, and oncologic efficiency 221 (2015) 265–272, <https://doi.org/10.1016/j.jamcollsurg.2015.03.029>.
- [6] G. Berardi, Laparoscopic vs open resection for hepatocellular carcinoma in patients with child-pugh class B liver cirrhosis: an international multicenter propensity score matched analysis, *J. Am. Coll. Surg.* 229 (2019) S177, <https://doi.org/10.1016/j.jamcollsurg.2019.08.390>.
- [7] F. Cipriani, C. Fantini, F. Ratti, R. Lauro, H. Tranchart, M. Halls, V. Scuderi, L. Barkhatov, B. Edwin, R.I. Troisi, I. Dagher, P. Reggiani, G. Belli, L. Aldrighetti, M. Abu Hilal, Laparoscopic liver resections for hepatocellular carcinoma. Can we extend the surgical indication in cirrhotic patients? *Surg. Endosc.* 32 (2018) 617–626, <https://doi.org/10.1007/s00464-017-5711-x>.
- [8] H. Fuji, S. Seo, R. Toda, T. Yoh, Y. Ikeno, K. Fukumitsu, T. Ishii, K. Taura, E. Hatano, T. Kaido, S. Uemoto, Optimal introduction of laparoscopic liver resection for Child-Pugh B, *Asian J. Endosc. Surg.* 12 (2019) 287–293, <https://doi.org/10.1111/ases.12634>.
- [9] K. Takasaki, Glissonian pedicle transection method for hepatic resection: a new concept of liver segmentation 5 (1998) 286–291, <https://doi.org/10.1007/s005340050047>.
- [10] J. Dong, Z. Huang, Precise liver resection-new concept of liver surgery in 21st century, *Zhonghua Wai Ke Za Zhi.* 47 (2009) 1601–1605.
- [11] J. Zhang, J. Dawa, D. Suolang, Y. Lei, J. Wang, D. Basang, The application of preoperative three-dimensional reconstruction visualization digital technology in the surgical treatment of hepatic echinococcosis in Tibet 8 (2021), 715005, <https://doi.org/10.3389/fsurg.2021.715005>.
- [12] R.A. Agha, A.J. Fowler, A. Saeta, I. Barai, S. Rajmohan, D.P. Orgill, R. Afifi, R. Al-Ahmadi, J. Albrecht, A. Alsawadi, J. Aronson, M.H. Ather, M. Bashashati, S. Basu, P. Bradley, M. Chalkoo, B. Challacombe, T. Cross, L. Derbyshire, N. Farooq, J. Hoffman, H. Kadioglu, V. Kasivisvanathan, B. Kirshtein, R. Klappenbach, D. Laskin, D. Miguel, J. Milburn, S.R. Mousavi, O. Muensterer, J. Ngu, I. Nixon, A. Noureldin, B. Perakath, N. Raison, K. Raveendran, T. Sullivan, A. Thoma, M. A. Thorat, M. Valmasoni, S. Massarut, A. D'cruz, B. Vasudevan, S. Giordano, G. Roy, D. Healy, D. Machado-Aranda, B. Carroll, D. Rosin, The SCARE statement: consensus-based surgical case report guidelines, *Int. J. Surg.* 34 (2016) 180–186, <https://doi.org/10.1016/j.ijsu.2016.08.014>.
- [13] R.A. Agha, M.R. Borrelli, R. Farwana, K. Koshy, A.J. Fowler, D.P. Orgill, H. Zhu, A. Alsawadi, A. Noureldin, A. Rao, A. Enam, A. Thoma, M. Bashashati, B. Vasudevan, A. Beamish, B. Challacombe, R.L. De Wilde, D. Machado-Aranda, D. Laskin, D. Muzumdar, A. D'cruz, T. Manning, D. Healy, D. Pagano, P. Goel, P. Ranganathan, P.S. Pai, S. Raja, M.H. Ather, H. Kadioazlu, I. Nixon, I. Mukherjee, J. Gómez Rivas, K. Raveendran, L. Derbyshire, M. Valmasoni, M. Chalkoo, N. Raison, O. Muensterer, P. Bradley, R. Coppola, R. Afifi, D. Rosin, R. Klappenbach, R. Wynn, S. Giordano, S. Basu, S. Surani, P. Suman, M. Thorat, V. Kasi, The SCARE 2018 statement: updating consensus Surgical CAse REport (SCARE) guidelines, *Int. J. Surg.* 60 (2018) 132–136, <https://doi.org/10.1016/j.ijsu.2018.10.028>.
- [14] R.A. Agha, T. Franchi, C. Sohrabi, G. Mathew, A. Kerwan, A. Thoma, A.J. Beamish, A. Noureldin, A. Rao, B. Vasudevan, B. Challacombe, B. Perakath, B. Kirshtein, B. Ekser, C.S. Pramesh, D.M. Laskin, D. Machado-Aranda, D. Miguel, D. Pagano, F. H. Millham, G. Roy, H. Kadioglu, I.J. Nixon, I. Mukherjee, J.A. McCaul, J. Chi-Yong Ngu, J. Albrecht, J.G. Rivas, K. Raveendran, L. Derbyshire, M.H. Ather, M. A. Thorat, M. Valmasoni, M. Bashashati, M. Chalkoo, N.Z. Teo, N. Raison, O. Muensterer, P.J. Bradley, P. Goel, P.S. Pai, R.Y. Afifi, R.D. Rosin, R. Coppola, R. Klappenbach, R. Wynn, R.L. De Wilde, S. Surani, S. Giordano, S. Massarut, S. G. Raja, S. Basu, S.A. Enam, T.G. Manning, T. Cross, V.K.L. Karanth, V. Kasivisvanathan, Z. Mei, S.C.A.R.E. The, Guideline: updating consensus Surgical CAse REport (SCARE) guidelines, *Int. J. Surg.* 84 (2020) 226–230, <https://doi.org/10.1016/j.ijsu.2020.10.034>.