

## Letter to the Editor



## Case report and ten-year follow-up of episodic ataxia type 2 due to a novel variant in CACNA1A

Dear Editor,

Episodic ataxias (EA) include a group of autosomal dominant disorders characterized by paroxysmal attacks of imbalance and incoordination. Currently, there are nine recognized forms of episodic ataxia (EA1–EA9) [1,2], with causative genes known for 6 of them. Particularly, pathogenic variants in *KCNA1*, *CACNA1A*, *CACNB4*, *SLC1A3*, *UBR4* and *FGF14* genes have been described for EA1, EA2, EA5, EA6, EA8 and EA9 respectively.

EA2 is the most common episodic ataxia syndrome, characterized by paroxysmal attacks of ataxia, vertigo and nausea, sometimes associated with dysarthria, diplopia, tinnitus, dystonia, headache and hemiplegia [3,4]. These symptoms may last from minutes to days. Onset is typically in childhood or early adolescence and frequency of attacks may range from once or twice a year to three or four times a week. Attacks can be provoked by psychological stress or exertion. Between attacks, patients are asymptomatic, but they commonly develop interictal signs that may include nystagmus and ataxia [3,4]. Patients with EA2 respond well to acetazolamide treatment [5].

In 2009, we evaluated a 17-years old Italian boy who presented, since childhood, recurrent episodes of ataxia, nausea and incoordination, induced by exertion and, sometimes, psychological stress. The episodes occurred with a mean frequency of five times per month and lasted for 30-45 minutes. Between attacks, he was asymptomatic. There was no family history of neurological disorders. Past history revealed only congenital nystagmus. In the interictal neurological examination, the patient presents nystagmus horizontally beating on lateral gaze. No other oculomotor findings could be observed.

Brain MRI was unremarkable, particularly cerebellar atrophy was not present.

Suspecting Episodic Ataxia type 2, a genetic test was proposed. Informed consent was obtained for genetic testing in accordance with the Institution's ethics committee board requirements. DNA was extracted from peripheral blood by standard techniques. All exons and flanking introns of *CACNA1A* were amplified from the proband. We used denaturing high performance liquid chromatography (DHPLC) in combination with direct Sanger sequencing to identify specific nucleotide changes or small indels. In the proband, a single heterozygous nucleotide substitution was detected in exon 5 (c.758 A > G; reference

transcript NM\_001127221.1), substituting a histidine for an arginine (p.His253Arg; reference protein sequence NP\_001120693.1) in the putative protein. This variant was not present in GnomAD. In addition, the variant was absent in the proband's parents, suggesting a *de novo* origin, and it was classified as "likely pathogenic" according to ACMG criteria. The patient was started on acetazolamide 250 mg twice a day, with clinical improvement: attacks were less severe and their frequency decreased to one every six months. Since then, he has been evaluated regularly every year. After ten years of follow up, he still reports benefits from acetazolamide treatment, being the frequency of his attacks rare and the ictal symptoms mild. His neurological assessment is unmodified, compared to the very first one. A recently performed brain MRI was unchanged, without signs of cerebellar atrophy.

EA2 is a rare disorder due to mutations of *CACNA1A* gene, coding for the  $\alpha 1$  subunit of the P/Q-type voltage-gated  $\text{Ca}^{2+}$  channel (CaV2.1). The  $\alpha 1$  subunit has four domains (I–IV), each formed by six transmembrane hydrophobic segments (S1–S6). Segments S5 and S6 of each domain line the pore region and play a critical role for ion selectivity and permeation of the  $\text{Ca}^{2+}$  channel [6,7]. *CACNA1A* mutations are distributed along the entire gene (Fig. 1), but missense mutations generally involve S5–S6 segments and their borders [8]. Molecular analysis of *CACNA1A* gene, in our proband, identified the presence of the novel c.758G > A variant at the heterozygous state and causing the p.His253Arg substitution in the putative protein.

According to ACMG criteria [9], this previously unreported sequence variation fulfills one strong, two moderate, and one supporting criteria (PS2 + PM1 + PM5 + PP3) [10].

In conclusion, we have characterized a novel missense variant within the *CACNA1A* gene in a typical sporadic EA2 phenotype, with episodes of ataxia and incoordination triggered by exertion, which started in childhood and it is responsive to acetazolamide. Long term treatment showed effectiveness by improving the clinical course and without any adverse effect. Based on clinical evidence and the criteria set by the American College of Medical Genetics and Genomics [9], we conclude that the novel variant can be classified as "likely pathogenic".

EA2 is a rare disorder, however it should be considered in undiagnosed attacks of dizziness, vertigo and ataxia, even without family history, particularly in patients with inter-ictal nystagmus.

<https://doi.org/10.1016/j.ensci.2021.100334>

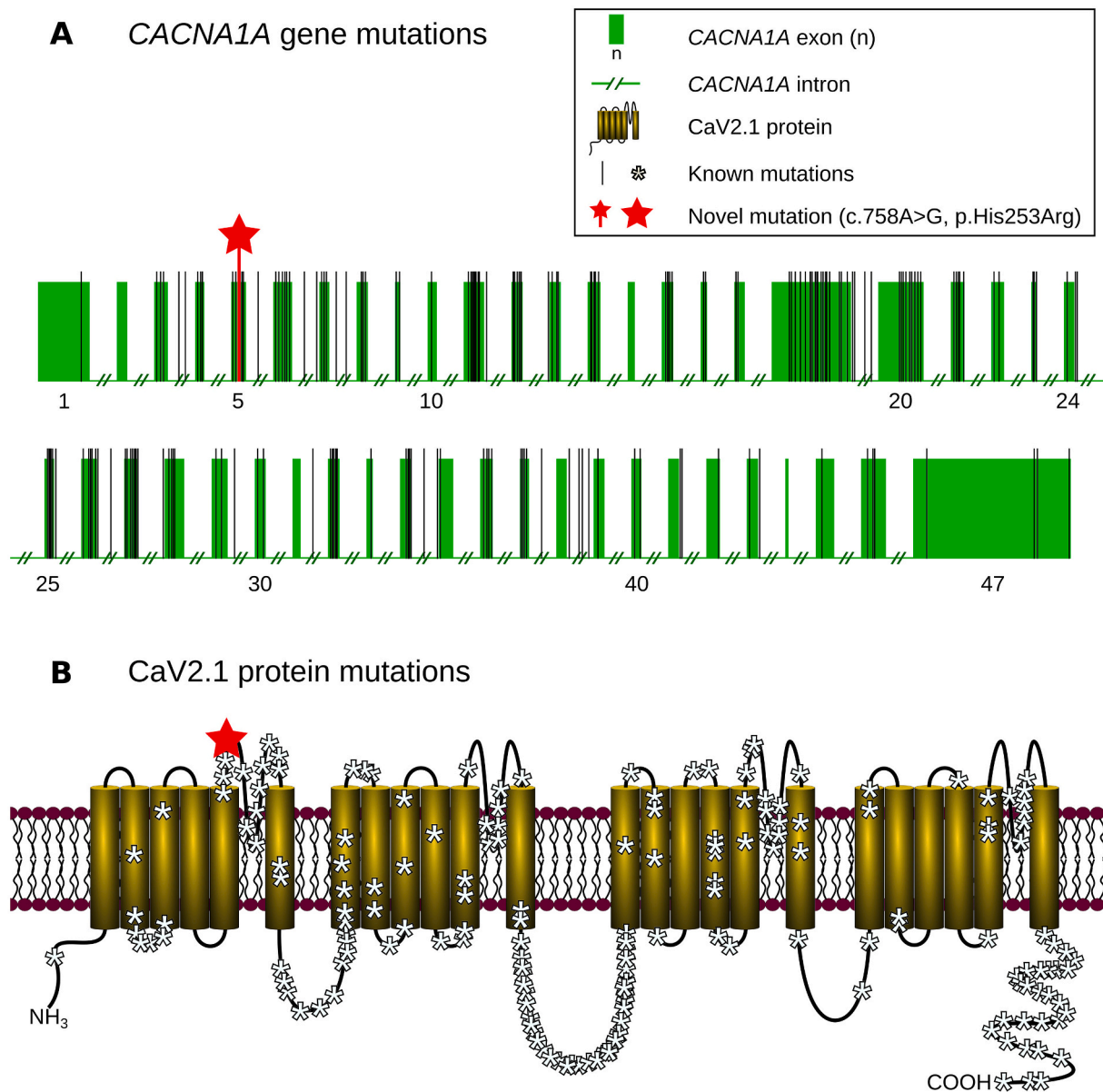
Received 25 December 2020; Received in revised form 23 February 2021; Accepted 6 March 2021

Available online 13 March 2021

2405-6502/© 2021 The Author(s).

Published by Elsevier B.V. This is an open access article under the CC BY-NC-ND license

(<http://creativecommons.org/licenses/by-nc-nd/4.0/>).



**Fig. 1.** CACNA1A gene and CaV2.1 protein mutations.

a. CACNA1A gene structure with green boxes indicating exons and black vertical strips representing identified pathogenic mutations. The red star shows the novel mutation (c.758A > G, p.His253Arg).

b. CaV2.1 protein structure displaying the localization of known mutations (white asterisks) and novel mutation (red star as above).

All mutations from previous literature reports and all “pathogenic” and “likely pathogenic” mutations reported on ClinVar database were included.

#### Funding

This research did not receive any specific grant from funding agencies in the public, commercial, or not-for-profit sectors.

#### Declaration of Competing Interest

None.

#### Acknowledgments

We would like to thank the proband and his family for participating in this study.

#### References

- [1] J.C. Jen, J. Wan, Episodic ataxias, *Handb. Clin. Neurol.* 155 (2018) 205–215.
- [2] V. Humbertclaude, G. Remerand, J. Hadjadj, F. Rejou, C. Coubes, L. Pinson, P. Meyer, A. Roubertie, FGF14-related episodic ataxia: delineating the phenotype of Episodic Ataxia type 9, *Ann. Clin. Transl. Neurol.* 7 (2020) 565–572.
- [3] J. Jen, G.W. Kim, R.W. Baloh, Clinical spectrum of episodic ataxia type 2, *Neurology* 62 (2004) 17–22, <https://doi.org/10.1212/01.WNL.0000101675.61074.50>.
- [4] R.W. Baloh, Q. Yue, J.M. Furman, S.F. Nelson, Familial episodic ataxia: clinical heterogeneity in four families linked to chromosome 19p, *Ann. Neurol.* 41 (1997) 8–16, <https://doi.org/10.1002/ana.410410105>.
- [5] M. Strupp, A. Zwergal, T. Brandt, Episodic ataxia type 2, *Neurotherapeutics* 4 (2007) 267–273, <https://doi.org/10.1016/j.nurt.2007.01.014>.
- [6] D. Pietrobon, CaV2.1 channelopathies, *Pflugers Arch.* 460 (2010) 375–393, <https://doi.org/10.1007/s00424-010-0802-8>.
- [7] W.A. Catterall, Structure and regulation of voltage-gated Ca<sup>2+</sup> channels, *Annu. Rev. Cell Dev. Biol.* 16 (2000) 521–555, <https://doi.org/10.1146/annurev.cellbio.16.1.521>.

- [8] E. Mantuano, L. Veneziano, M. Spadaro, P. Giunti, S. Guida, M.G. Leggio, et al., Clusters of non-truncating mutations of P/Q type Ca<sup>2+</sup> channel subunit Ca(v)2.1 causing episodic ataxia 2, *J. Med. Genet.* 41 (2004), <https://doi.org/10.1136/jmg.2003.015396> e82.
- [9] S. Richards, N. Aziz, S. Bale, D. Bick, S. Das, J. Gastier-Foster, et al., Standards and guidelines for the interpretation of sequence variants: a joint consensus recommendation of the American College of Medical Genetics and Genomics and the Association for Molecular Pathology, *Genet Med* 17 (2015) 405–424, <https://doi.org/10.1038/gim.2015.30>.
- [10] A.M. van den Maagdenberg, E.E. Kors, E.R. Brunt, W. van Paesschen, J. Pascual, D. Ravine, et al., Episodic ataxia type 2. Three novel truncating mutations and one novel missense mutation in the CACNA1A gene, *J. Neurol.* 249 (2002) 1515–1519, <https://doi.org/10.1007/s00415-002>.

Lorenzo Verriello<sup>a,\*1</sup>, Paola Carrera<sup>b,1</sup>, Giada Pualetto<sup>a</sup>,  
Andrea Bernardini<sup>c</sup>, Mariarosaria Valente<sup>c,d</sup>, Gian Luigi Gigli<sup>c,e</sup>

<sup>a</sup> Neurology Unit, Department of Neurosciences, Santa Maria della Misericordia University Hospital, Udine, Italy

<sup>b</sup> Laboratory of Clinical and Molecular Biology and Unit of Genomics for Diagnosis of Genetic Diseases, IRCCS Ospedale San Raffaele, Milano, Italy

<sup>c</sup> Clinical Neurology Unit, Department of Neurosciences, Santa Maria della Misericordia University Hospital, Udine, Italy

<sup>d</sup> Department of Medicine (DAME), University of Udine, Italy

<sup>e</sup> Department of Mathematics, Informatics and Physics (DMIF), University of Udine, Italy

\* Corresponding author.

E-mail address: [lorenzo.verriello@asufc.sanita.fvg.it](mailto:lorenzo.verriello@asufc.sanita.fvg.it) (L. Verriello).

---

<sup>1</sup> Co-first authors.