

## MSK Ultrasound Bites: Tips and Tricks

# Utilizing Diagnostic Musculoskeletal Ultrasound in the Evaluation of Cubital Tunnel Syndrome and Ulnar Nerve Pathology

Robert C. Manske, PT, DPT, MEd, SCS, ATC, CSCS, FAPTA, Michael Voight, PT, DHSC, SCS, OCS, ATC, CSCS, FAPTA, Phil Page, PT, PhD, ATC, CSCS, FACSM, Chris Wolfe, PT, DPT, OCS, Cert MDT

Keywords: Cubital Tunnel Syndrome, Ulnar Nerve, Musculoskeletal Ultrasound, Rehabilitation, Diagnostic Imaging

<https://doi.org/10.26603/001c.115363>

---

## International Journal of Sports Physical Therapy

Vol. 19, Issue 4, 2024

---

Cubital Tunnel Syndrome (CTS), is a frequently encountered condition in clinical settings, typically arising from static or dynamic compression of the ulnar nerve. CTS is characterized by the irritation of the ulnar nerve within the cubital tunnel and is a common neuropathic condition that can significantly impact functional abilities and quality of life. This article explores the utility of diagnostic musculoskeletal ultrasound (MSK-US) in the evaluation of the cubital tunnel and the ulnar nerve. The cubital tunnel syndrome, a common entrapment neuropathy of the ulnar nerve, often presents diagnostic challenges. Traditionally, nerve conduction studies and electromyography have been the primary diagnostic tools used to diagnose CTS. Given the superficial nature of the ulnar groove and its adjacent structures, MSK-US imaging known for its non-invasive nature and high-resolution imaging capabilities, has become an increasingly valuable tool in the assessment and management of various musculoskeletal conditions. This article reviews the technical aspects of MSK-US, its advantages in visualizing the ulnar nerve and related structures, and its implications in clinical practice for rehabilitation providers. By integrating MSK-US in the evaluation of CTS, rehabilitation professionals can enhance diagnostic accuracy, tailor interventions, and improve patient outcomes.

## INTRODUCTION

Cubital tunnel syndrome (CTS), characterized by the entrapment of the ulnar nerve at the elbow, is a prevalent condition causing symptoms that include but are not limited to pain, numbness, and muscle weakness in the affected limb. It often results in sensory disturbances and motor deficits, significantly affecting patients' daily activities and livelihood. The diagnosis of CTS relies on a thorough understanding of the ulnar nerve and its sensory and motor branch distribution. However, the clinical identification of ulnar nerve pathology is often complex due to anatomical variations, a wide array of differential diagnoses, and diverse clinical presentations. Untreated or inadequately managed injury to the ulnar nerve may lead to severe complications, including persistent sensory impairments, muscle weakness, and joint contractures.<sup>1</sup> Therefore, early and accurate diagnosis is crucial for effective management and rehabilitation. Electromyography (EMG) and nerve conduction studies (NCS) have traditionally been the mainstay in the diagnosis of ulnar nerve pathology. While effective, they also have limitations including cost, accessibility, and patient discomfort. MSK-US imaging is emerging as a valuable diagnostic tool, particularly in cases where the diagnosis of ulnar nerve pathology is uncertain.<sup>2</sup> The integration of MSK-US imaging into the diagnostic process offers clinicians a real-time, dynamic approach to

correlate imaging findings with clinical symptoms directly. This article aims to provide an in-depth exploration of the application of ultrasound imaging in the diagnosis of ulnar neuropathy at the elbow, underscoring its significance as a non-invasive, real-time, and highly informative diagnostic modality.

## EPIDEMIOLOGY, RISK FACTORS, AND PATHOPHYSIOLOGY

Ulnar neuropathy at the elbow is a condition with diverse etiologies and mechanisms of injury. The ulnar nerve is vulnerable to compression at several anatomical locations in the vicinity of the elbow, predominantly at the ulnar groove and beneath the humeroulnar aponeurotic arcade.<sup>2</sup> However, entrapment can also occur at various other points, including the medial intermuscular septum of the arm, the arcade of Struthers, the cubital tunnel, and between the flexor carpi ulnaris (FCU) and flexor digitorum superficialis (FDS) muscles.<sup>2</sup>

Ulnar neuropathy at the elbow is estimated to affect up to 5.9% of the general population, as highlighted in recent studies.<sup>3,4</sup> Research has identified several risk factors associated with the development of ulnar neuropathy. A significant correlation has been observed between smoking and the onset of ulnar neuropathy, as indicated by epidemiological data.<sup>4</sup> Furthermore, demographic factors such as ad-

vancing age and male sex have been identified as potential risk factors for the development of ulnar neuropathy.<sup>5</sup> Occupational factors, particularly hand-arm vibration exposure in specific jobs, have also been implicated in ulnar neuropathy development.<sup>6</sup>

The pathophysiological mechanisms underlying dynamic ulnar nerve compression at the elbow are not entirely known. An intriguing aspect is the congenital absence of the ulnar groove retinaculum, potentially accounting for increased ulnar nerve mobility outside the ulnar groove upon elbow flexion.<sup>7</sup> Additionally, a shallow bony ulnar groove might contribute to instability.<sup>8</sup> Although ulnar nerve instability is frequently observed in asymptomatic individuals, its exact relationship to symptomatic presentations remains ambiguous.<sup>9</sup> Notably, while often asymptomatic, ulnar nerve instability can be implicated in pain syndromes due to friction and increased pressure.

Furthermore, the hypermobility of the ulnar nerve, particularly during flexion, renders it susceptible to damage from direct trauma or pressure.<sup>2</sup> The notion of “frictional neuritis” suggests that the subluxing or dislocating ulnar nerve may become irritated against bony irregularities, particularly in arthritic or post-traumatic joints.<sup>10</sup> Additionally, it has been proposed that complete ulnar nerve dislocation might paradoxically act as a protective mechanism against nerve strain.<sup>11</sup>

## DIAGNOSIS AND ULTRASOUND SCANNING TECHNIQUES

The diagnosis of ulnar neuropathy at the elbow is a multifaceted process that hinges on a comprehensive patient history, physical examination, electrophysiological testing, and MSK-US examination. Clinical manifestations of ulnar nerve entrapment typically include medial elbow pain, tingling, and numbness in the area supplied by the ulnar nerve, primarily affecting the fourth and fifth digits. These symptoms are often exacerbated by elbow flexion, such as during phone use, leaning on an elbow, or sleeping with the elbow bent beyond 90 degrees.<sup>2</sup> Difficulties in fine motor tasks, such as typing or opening bottles, are also reported, although overt motor symptoms like muscle atrophy or weakness may not be initially present.

Diagnostic provocative tests, including the Tinel test at the ulnar groove and the elbow flexion test with wrist extension, are valuable in confirming ulnar nerve entrapment. Enhancing these tests with additional shoulder internal rotation can improve their sensitivity and specificity.<sup>12</sup> Impairment in two-point discrimination in the ring and small fingers may also be present. Clinical examination may reveal the snapping of the dislocating ulnar nerve beneath the fingertips anterior to the medial epicondyle during elbow flexion.

Electrodiagnostic testing, including motor and sensory nerve conduction studies and needle examination, plays a crucial role in diagnosing ulnar nerve entrapment, pinpointing the site of entrapment, and determining the severity of the condition.<sup>13</sup> Despite their utility, electrodiagnostic studies have limitations in visualizing the morphology

of the ulnar nerve and its surrounding tissues. Imaging examinations, like MSK-US or magnetic resonance imaging (MRI), become indispensable, especially in cases with ambiguous diagnoses or secondary causes of compression.<sup>14</sup>

## TECHNICAL ASPECTS

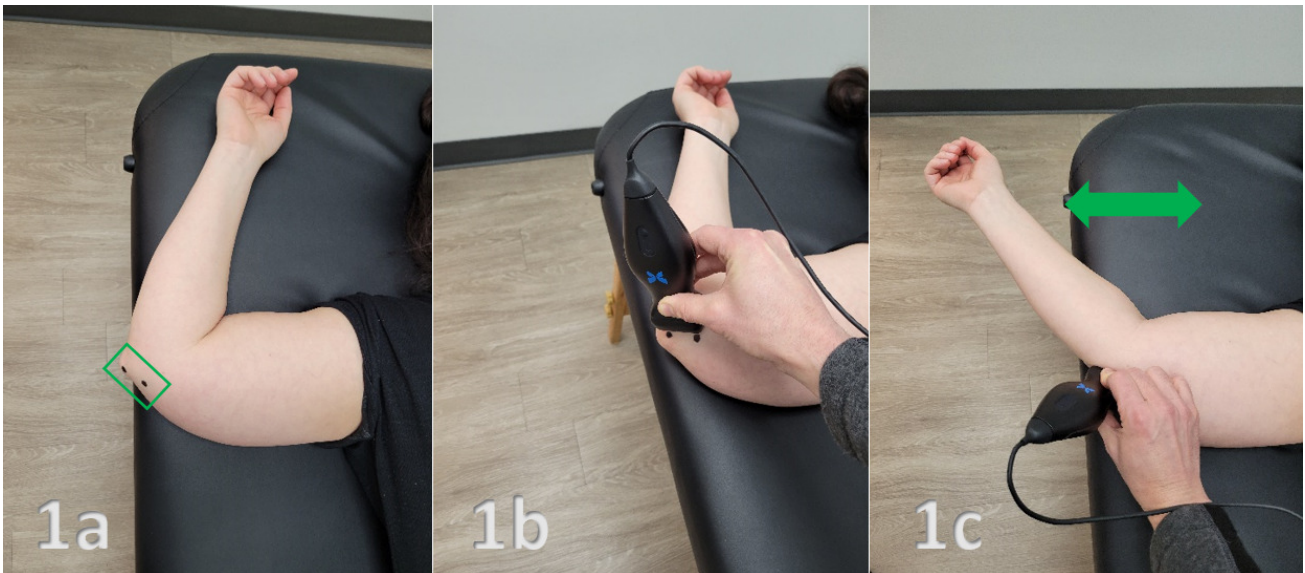
MSK-US involves the use of high-frequency sound waves to create detailed images of muscles, ligaments, nerves, and other soft tissues. Its high resolution allows for the visualization of the ulnar nerve and its surrounding structures with exceptional clarity. MSK-US offers several advantages over traditional diagnostic methods:

1. **Dynamic Imaging:** MSK-US enables the observation of the ulnar nerve in motion, helping to identify pathological changes during different arm positions.
2. **Accessibility and Cost-effectiveness:** Compared to MRI, MSK-US is more accessible and cost-effective, making it a practical choice in various clinical settings.
3. **Patient Comfort:** Being non-invasive and painless, MSK-US enhances patient comfort and compliance.
4. **Immediate Feedback:** Real-time imaging allows for immediate evaluation and diagnosis, facilitating quicker decision-making in treatment planning.

## CONCLUSION

MSK-US is a valuable tool in the evaluation of CTS and ulnar nerve pathology. Its non-invasive nature, coupled with the ability to provide dynamic and detailed visualization of the nerve, makes it an excellent adjunct to clinical examination and traditional nerve conduction studies. The integration of MSK-US aids in the early detection of ulnar nerve pathologies, which is crucial for timely intervention and preventing progression to chronic stages. Rehabilitation providers, equipped with knowledge and skills in MSK-US, can significantly enhance their diagnostic and therapeutic approach to ulnar nerve pathology, ultimately improving patient outcomes.

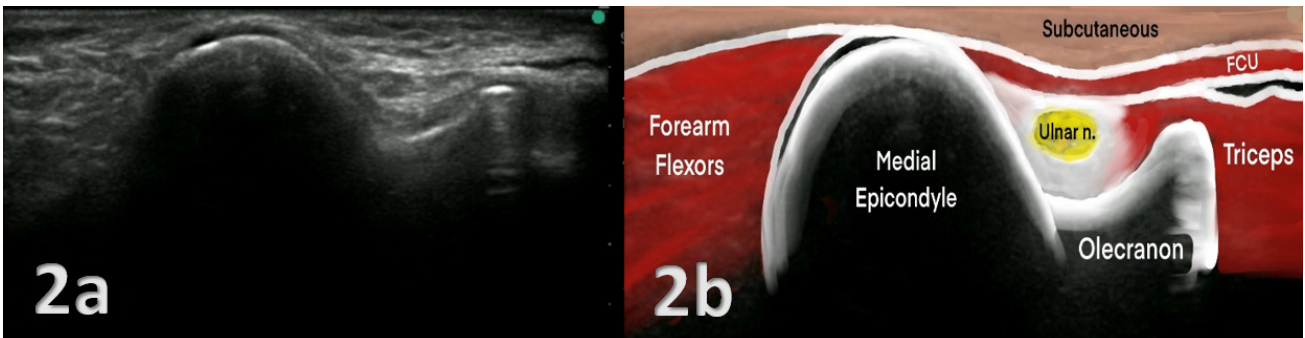
© The Author(s)



**Figure 1a: Patient Position:** Supine with the involved arm abducted to 90 degrees, elbow flexed to 60-90 degrees and maintained in full external rotation.

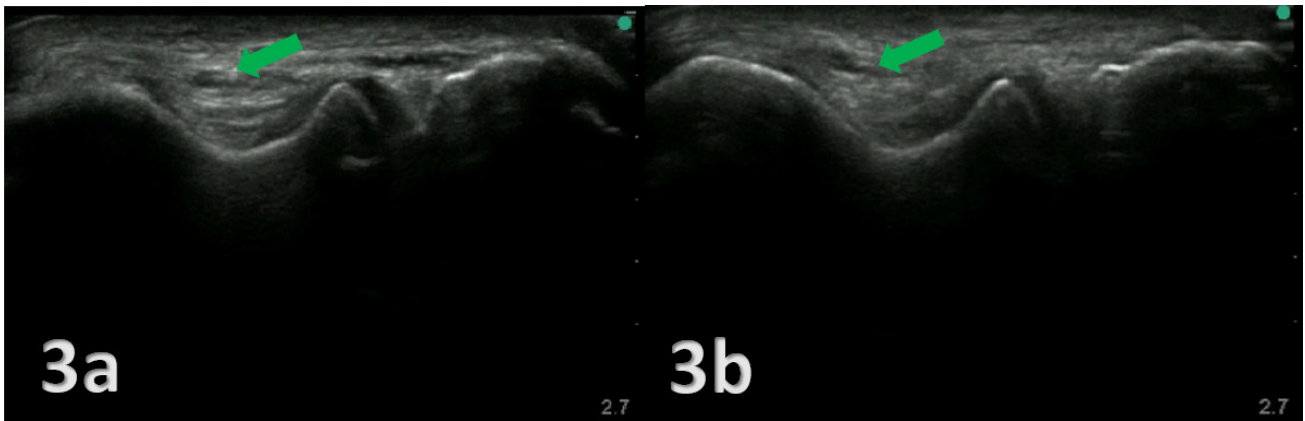
**Figure 1a and 1b: Transducer Placement:** The transducer is placed in a Short Axis (SAX) position. The green box outlines the SAX position of the transducer in Figure 1a. The two black dots over the medial epicondyle and olecranon indicate the placement for the lateral and medial aspects of the transducer in both Figures 1a and 1b. A common pitfall is to place the transducer in a Long Axis (LAX) position directly into the ulnar groove.

**Figure 1c: Transducer Placement with a Dynamic Assessment of a Subluxing Ulnar Nerve:** With the transducer in place, the arm can be flexed and extended. This exam becomes a dynamic assessment showing the subluxing ulnar nerve in real time.



### NORMAL VIEW IN SHORT AXIS (SAX)

**Figures: 2a and 2b:** The ulnar nerve is positioned within the ulnar groove, resembling a trough, situated on the epicondyle side. Unlike other nerves in different locations that appear hyperechoic, the ulnar nerve here exhibits a hypoechoic quality. Within this groove, you'll also find the medial head of the triceps. The stability of the ulnar groove is ensured by the intermuscular septum of the flexor carpi ulnaris.



### SUBLUXING ULNAR NERVE

**Figures 3a and 3b:** To assess ulnar nerve dislocation, dynamic imaging of the elbow was conducted, ranging from full extension to full flexion. Special care was taken to reduce transducer pressure on the nerve, minimizing its impact on nerve movement. The observed ulnar nerve (green arrow) is categorized as a partial dislocation and is characterized by the ulnar nerve shifting over the tip of the medial epicondyle during elbow flexion, while a complete dislocation is defined as the nerve moving anteriorly beyond the tip of the medial epicondyle.



This is an open-access article distributed under the terms of the Creative Commons Attribution 4.0 International License (CCBY-NC-4.0). View this license's legal deed at <https://creativecommons.org/licenses/by-nc/4.0> and legal code at <https://creativecommons.org/licenses/by-nc/4.0/legalcode> for more information.

## REFERENCES

1. Staples JR, Calfee R. Cubital tunnel syndrome: current concepts. *J Am Acad Orthop Surg*. 2017;25(10):215-224. doi:10.5435/jaaos-d-15-00261
2. Mezian K, Jacisko J, Kaiser R, et al. Ulnar neuropathy at the elbow: From ultrasound scanning to treatment. *Front Neurol*. 2021;12(5):1-17.
3. An TW, Evanoff BA, Boyer MI, Osei DA. The prevalence of cubital tunnel syndrome: a cross-sectional study in a U.S. Metropolitan Cohort. *J Bone Joint Surg Am*. 2017;99:408-416.
4. Frost P, Johnsen B, Fuglsang-Frederiksen A, Svendsen SW. Lifestyle risk factors for ulnar neuropathy and ulnar neuropathy-like symptoms. *Muscle Nerve*. 2013;48(4):507-515. doi:10.1002/mus.23820
5. Uzunkulaoğlu A, Ikbali Afsar S, Karataş M. Association between gender, body mass index, and ulnar nerve entrapment at the elbow: a retrospective study. *J Clin Neurophysiol*. 2016;33(6):545-548. doi:10.1097/wmp.0000000000000288
6. Jačisko J, Sobotová K, Mezian K. The utility of ultrasound examination in cubital tunnel syndrome caused by heterotopic ossification. *Med Ultrason*. 2020;22:117-118. doi:10.11152/mu-2419
7. Michelin P, Leleup G, Ould-Slimane M, Merlet MC, Dubourg B, Duparc F. Ultrasound biomechanical anatomy of the soft structures in relation to the ulnar nerve in the cubital tunnel of the elbow. *Surg Radiol Anat*. 2017;39(11):1215-1221. doi:10.1007/s00276-017-1879-y
8. Rosenberg ZS, Beltran J, Cheung Y, Broker M. MR imaging of the elbow: normal variant and potential diagnostic pitfalls of the trochlear groove and cubital tunnel. *Am J Roentgenol*. 1995;164(2):415-418. doi:10.2214/ajr.164.2.7839980
9. Cornelson SM, Sclocco R, Kettner NW. Ulnar nerve instability in the cubital tunnel of asymptomatic volunteers. *J Ultrasound*. 2019;22(3):337-344. doi:10.1007/s40477-019-00370-9
10. Bordes SJ, Jenkins S, Bang K, Turgut M, Iwanaga J, Loukas M, et al. Ulnar nerve subluxation and dislocation: a review of the literature. *Neurosurg Rev*. 2020;44:793-798.
11. Leis AA, Smith BE, Kosiorek HE, Omejec G, Podnar S. Complete dislocation of the ulnar nerve at the elbow: a protective effect against neuropathy? *Muscle Nerve*. 2017;56:242-246.
12. Ochi K, Horiuchi Y, Tanabe A, Waseda M, Kaneko Y, Koyanagi T. Shoulder internal rotation elbow flexion test for diagnosing cubital tunnel syndrome. *J Shoulder Elbow Surg*. 2012;21(6):777-781. doi:10.1016/j.jse.2011.10.015
13. Dimberg EL. Electrodiagnostic evaluation of ulnar neuropathy and other upper extremity mononeuropathies. *Neurol Clin*. 2012;30(2):479-503. doi:10.1016/j.ncl.2011.12.003
14. Gans P, Van Alfen N. Nerve ultrasound showing Martin–Gruber anastomosis. *Muscle Nerve*. 2017;56(5):E46-E47. doi:10.1002/mus.25746