

CASE REPORT

Bilateral renal lymphoma: rapid recovery from an acute kidney injury after open renal biopsy

Taku Mitome¹, Kazuhiro Furuya¹, Masashi Imano¹, Kimito Osaka¹, Yumiko Yokomizo¹, Narihiko Hayashi¹, Noboru Nakaigawa¹, Shoji Yamanaka² & Masahiro Yao¹

¹Department of Urology, Yokohama City University Graduate School of Medicine, Yokohama, Kanagawa, Japan

²Department of Pathology, Yokohama City University Hospital, Yokohama, Kanagawa, Japan

Correspondence

Taku Mitome, Department of Urology, Yokohama City University Graduate School of Medicine, 3-9 Fukuura, Kanazawa-ku, Yokohama 236-0004, Japan. Tel: +81 45 787 2679; Fax: +81 45 786 5775; E-mail: e053053a@yahoo.co.jp

Funding Information

No sources of funding were declared for this study.

Received: 26 May 2015; Revised: 13 August 2015; Accepted: 27 August 2015

Clinical Case Reports 2016; 4(1): 5–8

doi: 10.1002/ccr3.401

Background

Renal lymphoma as an initial lesion is relatively rare [1, 2]. Bilateral renal lymphoma frequently presents as an acute kidney injury (AKI) [3]. With systematic chemotherapy for renal lymphoma, patients usually recover kidney function. However, in the case we describe herein, the patient's kidney function greatly recovered after an open renal biopsy and before systematic chemotherapy. Here, we review and discuss this unique case.

Case Presentation

A 64-year-old Japanese man was referred to our clinic with gross hematuria, hypertension (blood pressure 180/75 mmHg), and kidney insufficiency (serum creatinine [Cr] 2.17 mg/dL). Doppler ultrasonography showed multiple-low echoic and hypovascular tumor lesions in bilateral kidney parenchyma. Plain computed tomography (CT) showed bilateral enlarged kidneys. Magnetic resonance imaging (MRI) demonstrated multiple bilateral renal tumor lesions, with a low intensity on T1- and T2-

Key Clinical Message

Renal lymphoma as an initial lesion is relatively rare. Bilateral renal lymphoma frequently presents as acute kidney injury. With systematic chemotherapy for the lymphoma, patients usually recover their kidney function. However, in the case we describe here, the patient's kidney function recovered greatly after an open renal biopsy. Here, we review and discuss this unique case.

Keywords

Acute kidney injury, bilateral renal lymphoma, open renal biopsy.

weighted images (Fig. 1). The serum soluble interleukin-2 receptor was elevated to 870 U/mL (normal range 145–519 U/mL).

After hospitalization, the AKI worsened rapidly and the patient underwent hemodialysis (Fig. 2). ¹⁸F-2-fluoro-2-deoxyglucose positron emission tomography/computed tomography) FDG-PET/CT showed intense uptake in bilateral kidneys, a para-aortic lymph node, and the right atrial appendage. We suspected malignant lymphoma and performed an open right kidney biopsy for a histopathologic diagnosis.

We performed an ultrasonography-guided right renal biopsy. The kidney was hard and massively swelled, and the tumor lesions could not be distinguished from the normal renal parenchyma. We freed the entire kidney from Gerota's fascia and made 1-cm incisions in the renal capsule and obtained first- and second-cuneiform specimens which were insufficient for diagnosis because of the inadequate number of infiltrating lymphocytes. The third tissue specimen enabled the diagnosis: non-Hodgkin's lymphoma (diffuse large B-cell lymphoma/Barkitt lymphoma) (Fig. 3). A bone marrow biopsy revealed no evidence of bone marrow involvement.

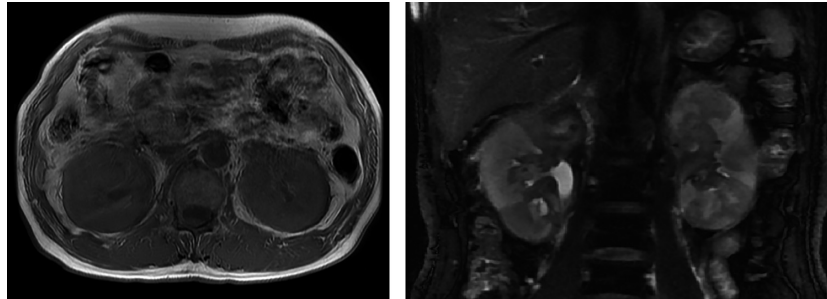


Figure 1. MRI showing kidney enlargement and bilateral renal multiple tumors, with low intensity on T1- and T2-weighted images.

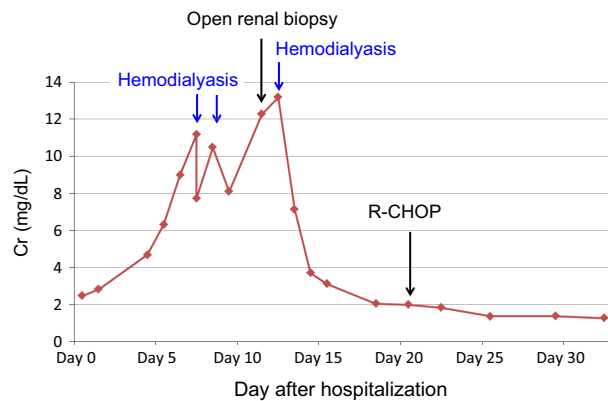


Figure 2. Clinical course of the patient’s Cr levels after admission.

After the open renal biopsy, the AKI was unexpectedly getting better and the patient was withdrawn from hemodialysis (Fig. 2). He was treated with dose-adjusted systemic chemotherapy (the R-CHOP protocol: rituximab, cyclophosphamide, doxorubicin, vincristine, and prednisone). The patient was discharged after the 1st cycle of chemotherapy, and the systemic chemotherapy was continued.

Discussion

Renal involvement is common in hematologic malignancies and lymphomas, and it is observed in approximately

34% of patients in advanced stages of these cancers [4]. However, primary renal lymphoma (PRL) is relatively rare, with only a few well-documented cases reports in the literature [1, 2]. The term “PRL” is usually defined as when the disease is limited to the renal parenchyma and has not invaded from an adjacent lymphomatous mass [2]. PRL is a rare and uncertain entity because the renal parenchyma lacks lymphomatous tissue. Therefore, the status of PRL as a primary disease or the first manifestation of a rapidly progressive disease is controversial [2]. Malbrain et al. proposed the following diagnostic criteria for PRL: (1) renal failure as the initial presentation; (2) enlargement of the kidneys without obstruction and without other organ or nodal involvement; (3) the diagnosis is made only by renal biopsy; (4) absence of other causes of renal failure; and (5) the rapid improvement of renal function after radiotherapy or systemic chemotherapy [5]. Our patient’s case matched almost all of these criteria, but he could not be diagnosed as having PRL due to the involvement of the lymph node and the right atrial appendage.

Primary renal lymphoma was reported to occur in approximately 0.7% of extranodal malignant lymphomas [6]. There is no difference in its gender distribution, and the patients’ ages at onset have ranged from 2 to 90 years [7, 8]. The symptoms of PRL are abdominal pain, gross hematuria, fever, and weight loss [7, 8]. Imaging studies are useful for the diagnosis of renal lymphoma.

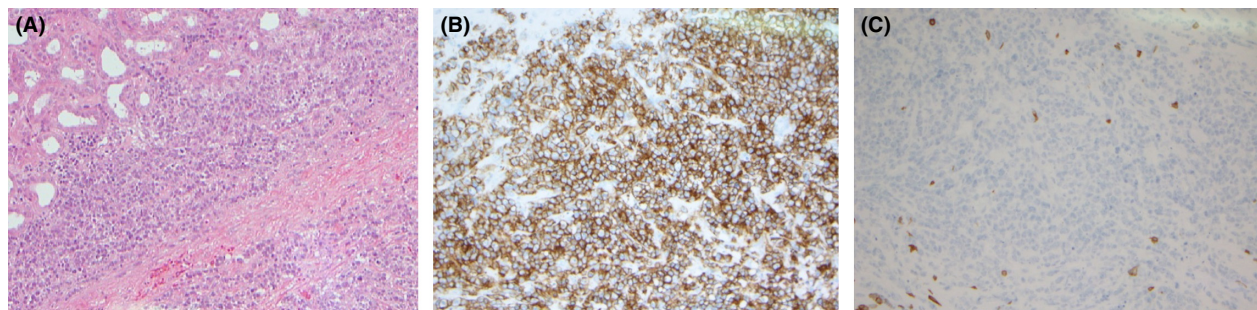


Figure 3. Histopathologic examination. (A) Renal biopsy showed diffuse interstitial infiltration by lymphocytes (hematoxylin-eosin stains [HE] ×100), (B) diffuse immunoreactivity of lymphocytes to CD10, (C) no immunoreactivity of lymphocytes to CD3 (HE ×200).

Ultrasonography and CT show kidney enlargement and hypovascular tumors. According to Cohan *et al.*, four patterns of renal lymphoma can be identified on CT: (1) the single-mass type; (2) the multiple-mass type; (3) invasion of the contiguous retroperitoneal-mass type; and (4) the perinephric-mass type [9].

MRI shows renal tumors with low or iso-intensity on T1-weighted images and low intensity on T2-weighted images [10]. In histopathologic sections of renal lymphoma, many reports showed a diffuse large B-cell lymphoma of non-Hodgkin's lymphoma [3]. The prognosis of PRL is usually poor, with a 1-year mortality rate of 75% [11].

Many reported cases show renal insufficiency by lymphomatous infiltration of the kidney [3, 5, 6, 12]. According to Tornroth *et al.*, [3] acute renal failure or nephrotic-range proteinuria was the principal indication for percutaneous kidney biopsy in 48 (87%) of their 55 patients with bilateral renal lymphoma. They also proposed a mechanism of acute kidney injury in which an interstitial proliferation of lymphoma increases the interstitial pressure without much destruction of renal parenchymal elements [3]. Increased pressure, however, could cause renal insufficiency by tubular obstruction, compression of the peritubular capillaries with increased postglomerular vascular resistance, or modulation of the tubuloglomerular feedback mechanism [3]. In many reports, renal insufficiency by lymphomatous infiltration recovered rapidly after treatment [3, 11–14]. In our patient's case, hemodialysis and multiple incisions of the renal capsule for biopsy may have led to his kidney function recovery; the treatment also recovered his kidney function as described. To the best of our knowledge, the recovery of kidney function before systematic chemotherapy for a lymphoma has not been reported. In our patient, the dissection of the renal capsule, by chance, may have decreased in the renal internal pressure. This might be one of the factors which have recovered the kidney function. This case supported the theory of renal insufficiency by compression of the peritubular capillaries with increased postglomerular vascular resistance or moderation of the tubuloglomerular feedback mechanism by a lymphomatous infiltration of the kidney.

Both needle biopsies and open biopsies are used for the diagnosis of renal lymphoma [1, 12]. In our patient, since his AKI worsened rapidly and the flow cytometry for the current precise diagnosis of lymphoma required a substantial amount of malignant cells, we chose an open biopsy. In fact, we needed to cut out renal tissue specimens three times to obtain the final diagnosis, since lymphoma cells infiltrated heterogeneously into the renal parenchyma. Based on these observations, we recommended an open biopsy rather than a needle biopsy for the precise and accurate diagnosis if a renal lymphoma is suspected.

Conclusions

This case supported the theory that renal insufficiency by lymphomatous infiltration of kidney is caused by compression of peritubular capillaries with increased postglomerular vascular resistance, or modulation of the tubuloglomerular feedback mechanism. Rapid diagnosis and treatment initiation are essential to preserve renal function and improve the prognosis.

Consent

Informed consent was obtained from the patient for publishing this case report and accompanying images.

Conflict of Interest

We declare that there is no conflict of interests regarding the publication of this article.

References

1. Steven, C. C., and R. L. Brian. 2011. *Campbell-walsh urology*. 10th ed. vol. 2. Elsevier, Pp. 1471–1472.
2. Okuno, S. H., J. D. Hoyer, K. Ristow, and T. E. Witzig. 1995. Primary renal non-Hodgkin's lymphoma. An usual extranodal site. *Cancer* 75:2258–2261.
3. Tornroth, T., M. Heiro, N. Marcussen, and K. Franssila. 2003. Lymphomas diagnosed by percutaneous kidney biopsy. *Am. J. Kidney Dis.* 42:960–971.
4. Richmond, J., R. S. Sherman, H. D. Diamond, L. F. Craver. 1962. Renal lesions associated with malignant lymphomas. *J. Med.* 32:184–207.
5. Malbrain, M. L., G. L. Lambrecht, R. Daelemans, R. L. Lins, P. Hermans, P. Zachée. 1994. Acute renal failure due to bilateral lymphomatous infiltrates. Primary extranodal non-Hodgkin's lymphoma (p-EN-NHL) of the kidneys: does it really exist? *Clin. Nephrol.* 42:163–169.
6. Baldus, M., P. Klooker, S. Kress, R. Waldherr, P. Möller, H. Brass. 1996. Primary bilateral renal centrocytic non-Hodgkin's lymphoma as a cause of renal failure. *Nephron* 73:86–90.
7. Tsuchiya, N., T. Kawahara, Y. Amino, T. Someno, T. Kato, *et al.* 1997. Malignant lymphoma initially detected as a renal tumor: a case report. *Nishinohon J. Urol.* 59:19–21.
8. Uehara, M., H. Arai, N. Murosaki, M. Honda, G. R. Shrestha, T. Kanemiya. 2013. Primary renal malignant lymphoma in a hemodialysis patients: a case report. *Hinyoukika Kiyu.* 59:17–21.
9. Cohan, R. H., N. R. Dunnick, R. A. Leder, and M. E. Baker. 1990. Computed tomography of renal lymphoma. *J. Comput. Assist. Tomogr.* 14:933–938.

10. Imai, Y., S. Sone, S. Serizawa, S. H. Bae, N. Imai, M. Hasegawa, et al. 1995. Magnetic resonance imaging of renal lymphoma with computed tomography correlation. *Nippon Act Radiologica*. 55:562–568.
11. Porco, A. B., A. D'amico, G. Novella, P. Curti, V. Ficarra, S. Z. Antonioli, et al. 2002. Primary lymphoma of the kidney. Report of a case and update of the literature. *Arch. Italy Urol. Androl*. 74:44–47.
12. Al-Salam, S., A. Shaaban, M. Alketbi, N. U. Haq, S. Abouchacra. 2011. Acute kidney injury secondary to renal large B-cell lymphoma: role of early renal biopsy. *Int. Urol. Nephrol*. 43:237–240.
13. Yasunaga, Y., Y. Hoshida, M. Hashimoto, T. Miki, A. Okuyama, K. Aozasa. 1997. Malignant lymphoma of the kidney. *J. Surg. Oncol*. 64:207–211.
14. V'azquez-Alonso, F., I. Puche-Sanz, C. S'anchez-Ramos, J. Flores-Martín, J. Vicente-Prados, J. M. Cózar-Olmo. 2012. Primary renal lymphoma: long-term results of two patients treated with a chemotherapy + rituximab protocol. *Case Rep. Oncol. Med*. 2012:3 Article ID 726424. doi:10.1155/2012/726424