

## Advances in functional neuroimaging in dementias and potential pitfalls

Katherine Standley,<sup>1</sup> Charles Brock,<sup>1</sup> Michael Hoffmann<sup>2</sup>

<sup>1</sup>Neurology Department, University of South Florida; <sup>2</sup>Cognitive Neurology Division, Neurology Service, James A. Haley VA Hospital, Tampa, Florida, USA

### Abstract

Neuroimaging is continuously advancing at a rapid rate and has progressed from excluding relatively uncommon secondary causes (stroke, tumor) to assisting with early diagnosis and subtype of dementia. Structural imaging has given way to functional, metabolic and receptor imaging.

### Introduction

Neuroimaging is continuously advancing at a rapid rate and has progressed from excluding relatively uncommon secondary causes (stroke, tumor) to assisting with early diagnosis and subtype of dementia. Structural imaging has given way to functional, metabolic and receptor imaging. An emerging focus is the appreciation of human connectomics, networkopathies and their imaging counterparts. <sup>18</sup>Fluorodeoxyglucose positron emission tomography (<sup>18</sup>FDG-PET) brain, single photon emission computed tomography (SPECT) brain, PET Pittsburgh Compound B (PIB) and PET receptor (Dopa) imaging are becoming more widespread and gaining acceptance as part of the routine work up (Table 1). <sup>18</sup>FDG-PET brain in particular has been an important tool in assisting in the early diagnosis of mild cognitive impairment (MCI) type of case as well as in differentiating different types of dementia, with frontotemporal disorders (FTD) and Alzheimer's disease (AD) already being an Food and Drug Administration asserted indication for example.<sup>1</sup> Furthermore, basic neuroscience is increasingly delineating newer molecular phenotypes (beta amyloid, alpha synuclein and TDP-43) and subcategories which are particularly complex with FTD (TDP 43, tau, FUS, C90RF2). The pathologies take effect at the synaptic and neuronal level and are the earliest events in these disease states. Neuroimaging is increasingly able to decipher these earlier changes long before the clinical state even emerges or the extensive atrophy seen on structural scans. As late or end stages

are barely amenable to significant intervention, the earlier detection is key.

Currently PET brain imaging offers the most accurate diagnostic method for the 5 main dementia categories as well as a number of the subcategories<sup>2</sup> (Table 2). A number of patterns have emerged that reliably differentiate the major dementia subtypes. This is important for treatment and prognostic decision making. For example the posterior cortical atrophy syndrome (Benson syndrome), an AD variant progresses very slowly with largely retained cognitive function, at the same time dominated by complex visual impairments including visual agnosias and Balint's syndrome (Figure 1).<sup>3</sup> With FTD (frontotemporal hypometabolism) (Figure 2) and AD (temporal, parietal, posterior cingulate) the footprint of hypometabolism is relatively easily identified (Figure 3). However with Parkinson's disease with dementia (PDD) and Diffuse Lewy Body Disease (DLBD), the differentiating features even on PET scanning are less distinct and considerable overlap in the patterns are seen and consequently confusion may arise. This is particularly the case with PDD, DLBD and cortical basal ganglionic (CBG) disease. PDD and DLBD are particularly challenging as there is no clear PET pattern as for example with AD and FTD. This is perhaps not surprising as DLBD and AD share features at a clinical, neuroimaging, pathological and pharmacotherapeutic level.<sup>4</sup> Furthermore, Parkinson's disease (PD), PDD, DLBD and AD represent a pathological spectrum with loss of both cholinergic neurons and dopaminergic neurons as the most prominent neurotransmitter perturbation initially.<sup>5</sup> Adding to the complexity, there is overlap with AD and cognitive vascular disorders (CVD), the frontal variant of Alzheimer's and the frontal variant of FTD that present added diagnostic challenges in individual cases. Even more importantly, diagnosis and differentiation may not be possible by clinical means alone especially in the pre-symptomatic phase when no cognitive impairment exists particularly in the context of presumed high cognitive reserve. However intervention and treatment may yield the most significant results at this stage.<sup>6</sup>

In addition to the 4 most common dementia syndromes discussed, newer dementia etiologies continuously added and expand the diagnostic work up. Autoimmune dementias and the prefrontal atrophy secondary to chronic stimulation of the pain matrix (chronic pain syndrome) is also regarded as a neurodegenerative condition today. Brain atrophy and as such neurodegeneration has been associated with various chronic pain conditions including fibromyalgia, posttraumatic headache, complex regional pain syndrome (CRPS), and chronic back pain.<sup>7-10</sup> The potential cause and effect relationship of the atrophy with pain

Correspondence: Michael Hoffmann, Stroke Center, James A. Haley VA Hospital, 13000 Bruce B Downs Blvd, Tampa, Florida, 33612, USA. Tel. +1.81.9722000.7633 - Fax: +1.813.9785995. E-mail: michael.hoffmann1@va.gov

Key words: neuroimaging, dementia.

Acknowledgments: presented in part at the 2011 Annual Meeting of the Florida Society of Neurology Lake Buena Vista, Florida September 16-18, 2011

Contribution: KS, intellectual input and data gathering; CB, intellectual input; MH, intellectual input and manuscript writing.

Received for publication: 16 November 2011.

Accepted for publication: 23 February 2012.

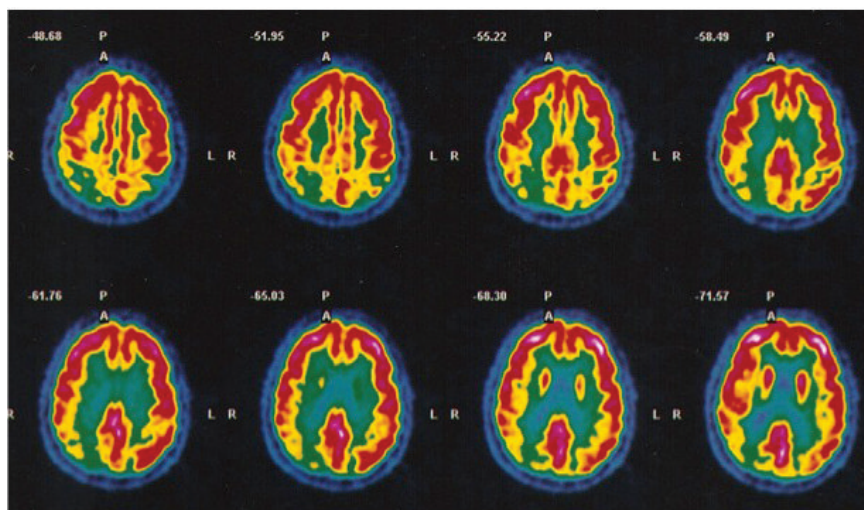
This work is licensed under a Creative Commons Attribution NonCommercial 3.0 License (CC BY-NC 3.0).

©Copyright K. Standley et al., 2012  
Licensee PAGEPress, Italy  
Neurology International 2012; 4:e7  
doi:10.4081/ni.2012.e7

continues to be elucidated. In relation to dementias, memory and pain processing share close anatomic relationships. Numerous functional neuroimaging studies using positron emission tomography (PET)<sup>11-13</sup> and functional magnetic resonance imaging (fMRI)<sup>14,15</sup> have demonstrated that the anterior cingulate cortex (ACC) and posterior cingulate cortex (PCC) have key roles in processing of pain perception.<sup>16</sup> Lesional studies have corroborated these findings.<sup>17,18</sup> The ACC has not been demonstrated to be involved in coding stimulus intensity or location but participates in both the affective and attentional components of pain sensation and response. Increased blood flow is also found in the posterior parietal and prefrontal cortices and is thought to reflect networks for attention and memory activated by painful stimulation. Memory and pain processing networks are physically close in the cingulate cortex. Episodic memory retrieval is predominately in the caudal portion of the PCC while pain processing occurs in the rostral portion of the PCC.<sup>19</sup> Given that patients with Alzheimer's disease and other neurodegenerative dementias are noted to report less pain and may receive less analgesics that comparable normal peers, consideration has been provoked that the dementia related neurodegeneration process may be affecting pain processing pathways. However, studies have demonstrated heightened magnitude and duration of activity in the ACC and other pain processing areas during pain stimuli in Alzheimer's disease patients.<sup>20</sup> As such

**Table 1. Spectrum of current functional imaging modalities.**

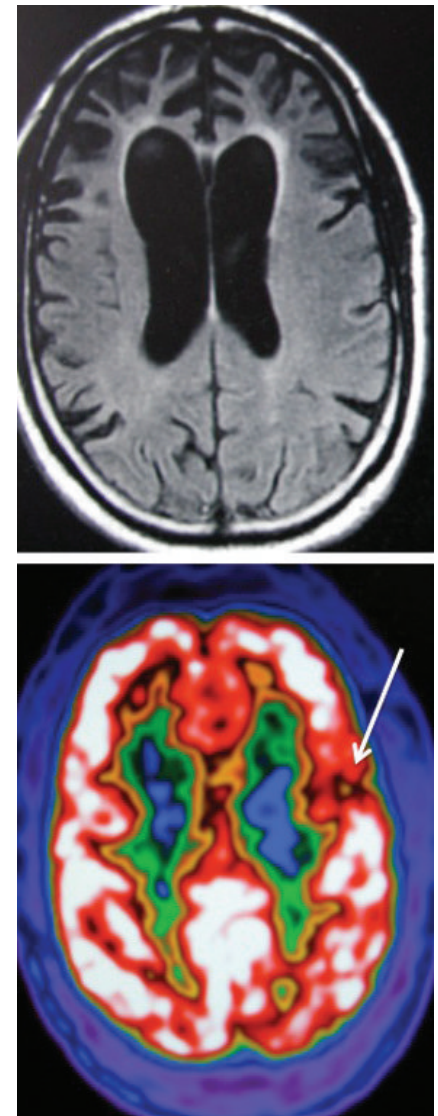
Magnetic resonance imaging multimodality
Magnetic resonance imaging (routine series) T1/T2 fluid attenuated inversion recovery, gradient echo sequence, magnetic resonance angiogram largely to detect degree of concomitant vascular disease, atrophy pattern and other secondary pathologies
Magnetic resonance imaging - diffusion tensor imaging Fiber tract pathology especially in traumatic brain injury, multiple sclerosis
Magnetic resonance imaging - quantitative atrophy estimation At least 5 different patterns of the major dementia syndromes (Seeley WW <i>et al.</i> ) <sup>22</sup>
Magnetic resonance imaging - perfusion Perfusion as a reflection of hypometabolism, similar to single photon emission computed tomography (perfusion) and positron emission tomography (metabolism) patterns of abnormality
Magnetic resonance spectroscopy Biochemical analysis, choline, lactate particularly useful in brain tumor diagnosis
Single photon emission computed tomography
Hypoperfusion (in vascular or hypometabolism)
Hyperperfusion for example with ictal foci
Position emission tomography brain
Frontotemporal disorders
Alzheimer's disease
Diffuse lewy body disease
Parkinson's
Progressive supranuclear palsy
Huntington's
Cortical basal ganglionic cognitive vascular disorders
Intrinsic state connectivity maps
Default mode
Saliency network
Parkinson's (increased connectivity of the basal ganglionic and thalamocortical loops)
Cortical basal ganglionic
Cognitive vascular disorders ?
Quantitative electroencephalographic and magnetoencephalographic
Alzheimer's disease - reduced connectivity of alpha and beta in frontotemporal and frontoparietal regions
Frontotemporal disorders - uncertain
Parkinson's - increased connectivity of alpha and beta locally and globally
Diffuse lewy body disease - reduced connectivity alpha range locally and globally



**Figure 1. <sup>18</sup>FDGPET brain: posterior cortical atrophy syndrome with marked posterior cortical hypometabolism.**

the perception of pain is not diminished in Alzheimer's, and should raise awareness of clinical care providers to insure adequate analgesia for dementia patients with painful conditions.

PET brain scan imaging and cerebrospinal fluid (CSF) biomarkers are becoming increasingly important to diagnose dementia syndromes especially in the setting of overlap syndromes.<sup>21,22</sup> Learning to identify metabolic uptake patterns by cartographic analysis as well as semi-quantitative methods may be crucial for correct diagnosis in the face of conflicting clinical as well as neuro-radiological findings. The four major neurodegenerative diseases include AD, DLBD, FTD and CVD in approximate order of frequency. AD and FTD



**Figure 2. FTD end stage with extensive bifrontal cortical atrophy (top) and <sup>18</sup>FDGPET brain of early non fluent aphasia subtype (down), demonstrating left inferior frontal hypometabolism (arrow) in context of normal structural MRI scan.**

(Figure 2) have distinct and easily identifiable patterns and CVD is guided primarily by stroke related imaging. The situation with DLDB can be difficult due to the overlap of neuropathologies. A correct diagnosis is nevertheless vital to guide care for the patient. Refining the diagnosis may assist with appropriate treatment and in avoiding serious side effects not the least of which include neuroleptic sensitivity such as neuroleptic malignant syndrome or catatonia. People with DLDB generally respond better to acetylcholinergic (ACh) therapy in terms of improved alertness, less fluctuation in cognition and memory than do people with AD.<sup>4</sup> The complex clinical and neuroradiological patterns of the dementia syndromes no doubt foster misdiagnosis. The neuroradiological findings of DLDB may be initially confused the diagnosis of AD diagnosis. Hallucinations, a hallmark of DLDB can occur with AD as well as other dementias. A recent report of a specific 5HT - 2A antagonist specific for visual hallucinations with DLDB is further reason for precise diagnostic accuracy translating into therapeutic effectiveness.<sup>23</sup> There are already several recognized metabolic features of PET scanning that have been identified with DLDB, namely i) diffuse glucose hypometabolism in entire cortex including the occipital region typical feature of DLDB and distinctive from AD, ii) lateral occipital hypometabolism (Figure 3) which may have the highest sensitivity and iii) posterior cingulate preserved metabolism or posterior cingulate island sign, (PCIS) which may have the highest specificity<sup>24-26</sup> (Figure 4). However, the so called PCIS appears to reflect the much more pronounced occipital hypometabolism relative to the also reduced (but to a lesser extent) or sometimes normal metabolism of the posterior cingulate cortex.<sup>22</sup>

With AD on the other hand, hypometabolism is seen very early in the medial portions of the parietal lobes as well as the posterior cingulate region. The difficulty posed by the fluctuating symptomatology adds to the diagnostic dilemma. In addition, the uncertainty of hallucination origin, whether drug induced, due to DLDB or AD is a frequent frustration shared by both patients and physicians treating these conditions. The advent of biomarker assisted diagnosis has already initiated new diagnostic criteria for AD that enable a *pre-mortem* diagnosis that is heavily reliant on positive CSF and PET findings.<sup>27</sup> The trend of clinical, PET and CSF diagnostic features rendering increased diagnostic accuracy will likely translate similarly in the DLDB-Parkinsonism complex as it has already done for example with

MCI and AD.<sup>28</sup> With the advent of MR perfusion scanning giving similar information to PET brain scanning, this modality may become more desirable in view of its availability and lack of radiation.<sup>29</sup> A continuously expanding therapeutic armamentarium for DLDB both in terms of receptors<sup>23</sup> for symptom alleviation as well as disease modifying therapies<sup>30</sup> all bode for precise diagnostic accuracy.

### Emerging imaging modalities: default mode network or intrinsic connectivity networks imaging and other (molecular) networks

The Default Mode Network (DMN) can be imaged by functional MRI (resting state without activation procedures) and reflects the basal or default mode activity of the brain. It links particular brain regions that includes the posterior cingulate, the precuneus, lateral parietal, lateral temporal, medial frontal areas. DMN impaired connectivity has already been shown in AD, FTD, schizophrenia, epilepsy, autism later life depression.<sup>31</sup> The DMN is active during rest and becomes less active during cerebral task engagement. It is implicated in the pathophysiology of AD as the distribution of the DMN is similar to the fibrillar amyloid deposition in patients with AD (amyloid PET scanning).<sup>32</sup> The A-beta deposition overlaps considerably with the DMN and the tau deposition overlaps with the DMN component that is concerned with episodic memory.<sup>33</sup> It has been surmised that over-activity of DMN (posterior cingulate, later parietal, medial

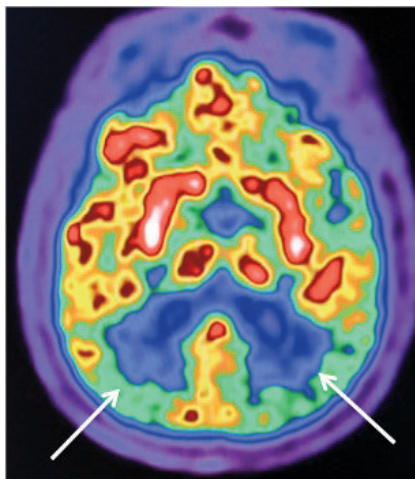


Figure 3. Transaxial <sup>18</sup>FDGPET brain revealing bilateral predominantly occipital hypometabolism (arrows) in a patient with DLDB.

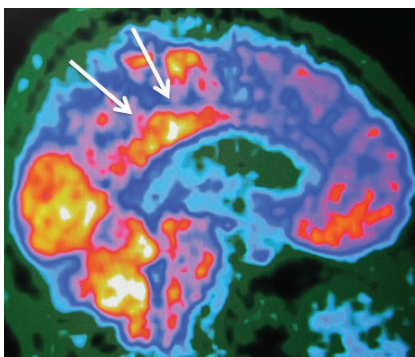


Figure 4. Sagittal <sup>18</sup>FDGPET brain revealing preserved mid to posterior cingulate metabolism (arrows) with temporoparietal hypometabolism.

Table 2. Positron emission tomography brain patterns in dementias.

Dementia subtype	<sup>18</sup> Fluorodeoxyglucose positron emission tomography hypometabolism pattern
Alzheimer	Relatively symmetric parietotemporal, medial temporal, posterior cingulate, frontal association cortex to lesser degree
Alzheimer's disease variant (Posterior cortical atrophy syndrome)	Occipital hypometabolism predominates
Frontotemporal disorders behavioral variant	Frontal and anterior temporal hypometabolism
Parkinson's disease with dementia	Temporo-parietal, may be similar to AD
Diffuse lewy body disease	Occipital and temporal hypometabolism
Cognitive vascular disorders	Cortical and subcortical, singular or multifocal, correlating with structural imaging abnormality
Corticobasal degeneration	Global reduction in metabolism as well as asymmetric prefrontal, premotor, sensorimotor superior temporal, parietal hypometabolism with thalamic hypometabolism contralateral to limb apraxia
Huntington's	Caudate nucleus hypometabolism, frontal association cortex to a lesser degree
Progressive supranuclear palsy	Caudate nucleus, putamen, thalamus, pons, superior and anterior frontal cortex

Note that FDG PET increases diagnostic accuracy beyond that derived from clinical evaluation.<sup>1</sup>

frontal) in younger life may lead to a metabolic impairment predisposing people to amyloid deposition in later life.<sup>34</sup>

The DMN is known to subserve several key memory processes including episodic encoding, retrieval, autobiographical, metamemory processes, moral decision making and theory of mind. Petrella *et al.* reported lower connectivity in DMN in patients with MCI who subsequently were diagnosed with AD over a 2-3 years period.<sup>32</sup> This type of functional connectivity MRI (fc-MRI), is an attractive tool because MRI scanners with blood oxygen level dependent (BOLD) capability are widely available and fc-MRI is non invasive, radiation free, can be repeated multiple times and have short acquisition time of 5-8 min.<sup>35</sup>

The quest for neuroimaging biomarkers for diagnosing pre-clinical disease may soon be realized albeit with perhaps a complementary role played by FDG-PET, Pittsburgh compound B PET (PiB PET), PET neurotransmitter imaging and fc-MRI of the DMN and perhaps other networks such as the salience (for FTD) and attentional networks.<sup>36-39</sup> With intrinsic connectivity networks the pattern for AD and FTD is fairly clear. However for the PDD and DLDB the pattern is less obvious and there may also be hyperactivity in the BG as opposed to the usual underactivity seen in the other neurodegenerative conditions (Table 3).

### Neurotransmitter and neurotransmitter receptor position emission tomography (and sometimes single photon emission computed tomography) imaging

In the hopes of guiding therapy more accurately, the cholinergic (nicotinic receptors) and dopaminergic systems have been investigated in this regard. An increase in 11C nicotinic binding sites as well as associated cognitive improvement were reported after 3 months of rivastigmine for AD patients.<sup>36</sup> At times neurodegenerative conditions coexist and unraveling the most pertinent neurotransmitter systems at fault is useful. This has been shown for acetylcholine involvement in Parkinsons with and without dementia by 11C methyl - 4- piperidyl acetate (MP4A). In this study, the dopaminergic system was also measured using 18F fluorodopa (FDOPA) which revealed decreased uptake in the striatum and MP4A was decreased in the Parkinson's group with dementia.<sup>37</sup>

### Cortical atrophy patterns

Cortical atrophy patterns are generally discernible at a later stage of the process and perhaps the least sensitive (Table 4). Nevertheless, a recent pivotal study showed 5 different neurodegenerative syndromes and their atrophy patterns corresponding to 5 dif-

**Table 3. Intrinsic connectivity network patterns in dementias.**

Dementia subtype	Intrinsic connectivity pattern
Alzheimer	Default mode network shows reduced connectivity
Frontotemporal lobe disorder behavioral variant	Salience network shows reduced connectivity
Parkinson's	Basal Nuclei-thalamocortical loops show increased connectivity
Diffuse lewy body disease	Uncertain at present but may show ascending brainstem projection system
Cortical basal ganglionic	Uncertain

**Table 4. Atrophy patterns in dementia subtypes.**

Dementia subtype	Atrophy pattern
Alzheimer	Temporoparietal, medial hippocampus, precuneus
Frontotemporal disorders behavioral variant	Frontotemporal
Parkinson's with dementia	Temporoparietal
Diffuse lewy body disease	Parietal atrophy but no hippocampal atrophy. Caudate atrophy currently debatable
Vascular cognitive disorder (vascular cognitive impairment, vascular dementia)	Nil specific, subcortical leukoariosis as opposed to periventricular rimming leukoariosis is frequent
Progressive supranuclear palsy	Midbrain atrophy (Hummingbird, Penguin signs)
Cortical basal ganglionic	Pronounced fronto-parietal atrophy, often asymmetric, corpus callosum atrophy

ferent intrinsic functional connectivity networks.<sup>39</sup> In particular the salience network has been shown to correlate with frontotemporal lobe dementia.<sup>40</sup> This relatively novel approach of brain analysis, called connectomics by some is showing promising results. Assessment of brain connectomics is regarded as an area of priority in future cognitive research (The Human Connectome Project).<sup>41</sup>

### The importance of considering cognitive reserve status by functional imaging in conjunction with cognitive or neuropsychological testing

No direct relationship exists between the extent of pathology and clinical manifestation of the underlying disease or damage for that matter.

Katzman *et al.*, reported on 10 elderly normal women with advanced AD pathology supported this premise, speculating that their brains had more cognitive reserve.<sup>42</sup> Cognitive reserve is considered to include: i) brain reserve capacity (correlate - hardware, brain size, neural count or synapse count; ii) cognitive reserve (correlate - software). Attempting to cope with brain damage using cognitive compensatory approaches. Higher education, bilingualism, literacy and participation in hobbies for example, allow people to withstand brain damage better.

Cognitive reserve in turn has been divided into: i) Neural reserve: cerebral networks less susceptible to disruption due to greater inherent efficiency; ii) neural compensation: post brain damage, additional or nonconventional networks are deployed to compensate for brain damage.<sup>43</sup>

Functional imaging studies support the neural reserve and neural compensation reflecting individual compensatory differences to pathology. For example, two people with the same cognitive impairment may have markedly different degrees of underlying AD pathology. This is clearly important for the diagnosis of preclinical Alzheimer's disease, as mild cognitive impairment (MCI) patients may have both minimal pathology or more extensive pathology. The cognitive reserve (CR) hypothesis, is used to describe this variability and is considered an important part of the assessment therefore. Clinical evaluation alone cannot be relied on and biomarkers (whether CSF analysis of tau and amyloid beta 1-42 or metabolic imaging) will be part of the work up.<sup>44</sup>

Since the proposal of the CR hypothesis, this has been recently supported using the PiB and <sup>18</sup>F-DG PET in relation to education in mild AD. In this study, 12 high educated (15 or more years) and 13 low educated patient with the same degree of cognitive deterioration were evaluated with PET brain scanning using both [<sup>11</sup>C] PiB and <sup>18</sup>F-Fluorodeoxyglucose as ligands. The high-educated people showed increased PiB uptake in the lateral frontal cortex as well as lower glucose metabolic rate in the temporoparietal cortical regions compared to low educated people.

### How may we utilize the various imaging modalities today and in the near future?

A likely hierarchical approach to using surrogate neuroimaging in cognitive patients may be as follows may take the following format: i) Resting State Network Imaging (DMN,

Salience and others) by f-MRI; ii) beta amyloid accumulation assessed by PET brain PIB (also CSF assays); iii) the subsequent synaptic dysfunction assessed by FDG-PET brain; iv) finally, neuronal loss follows, as assessed by volumetric MRI.

## Conclusion

Since the revised AD criteria now include biomarker testing, neuroimaging (particularly PET) has gained acceptance. However, the conditions with most ambiguous results on PET scanning (PDD and DLDB), certain neuroradiological identification such as the PCIS may be an important feature in improving confidence in the discrimination between AD and DLBD in clinical overlap syndromes and support differing therapeutics. For all the other conditions, PET reliably discerns the differing syndromes. The advent of ICN imaging looks promising to enable an even earlier and more precise diagnosis of the ever expanding array of dementia syndromes.

## References

- Foster NL, Heidebrink JL, Clark CM, et al. FDG PET improves accuracy in distinguishing frontotemporal dementia and Alzheimer's disease. *Brain* 2007;130:2616-35.
- Berti V, Pupi A, Mosconi L. PET/CT in diagnosis of dementia. *Ann NY Acad Sci* 2011;1288:81-92.
- Migliaccio R, Agosta F, Rascovsky K, et al. Clinical syndromes associated with posterior atrophy: early age at onset AD spectrum. *Neurology* 2009;73:1571-8.
- McKeith I. Lewy body diseases. Clinical aspects of dementia with Lewy bodies. In: *Handbook of Clinical Neurology*, 3rd edition. London: Elsevier; 2008. pp 307-319.
- Klein JC, Eggers C, Kalbe E, et al. Neurotransmitter changes in dementia with Lewy bodies and Parkinson disease dementia in vivo. *Neurology* 2010;74:885-92.
- Stern Y. Cognitive reserve. *Alzheimer Dis Assoc Disorders* 2006;20:112-7.
- Robinson ME, Craggs JG, Price DD, et al. Gray matter volumes of pain-related brain areas are decreased in fibromyalgia syndrome. *J Pain* 2011;12:436-43.
- Obermann M, Nebel K, Schumann C, et al. Gray matter changes related to chronic posttraumatic headache. *Neurology* 2009;73:978-83.
- Geha PY, Baliki MN, Harden RN, et al. The brain in chronic CRPS pain: abnormal gray-white matter interactions in emotional and autonomic regions. *Neuron* 2008;60:570-81.
- Apkarian AV, Sosa Y, Sonty S, et al. Chronic back pain is associated with decreased prefrontal and thalamic gray matter density. *J Neurosci* 2004;24:10410-5.
- Rainville P, Duncan GH, Price DD, et al. Pain affect encoded in human anterior cingulate but not somatosensory cortex. *Science* 1997;277:968-71.
- Coghill RC, Sang CN, Maisog JM, Iadarola MJ. Pain intensity processing within the human brain: a bilateral, distributed mechanism. *J Neurophysiol* 1999;82:1934-43.
- Casey KL. Concepts of pain mechanisms: the contribution of functional imaging of the human brain. *Prog Brain Res* 2000;129:277-87.
- Kwan CL, Crawley AP, Mikulis DJ, Davis KD. An fMRI study of the anterior cingulate cortex and surrounding medial wall activations evoked by noxious cutaneous heat and cold stimuli. *Pain* 2000;85:359-74.
- Sawamoto N, Honda M, Okada T, et al. Expectation of pain enhances responses to nonpainful somatosensory stimulation in the anterior cingulate cortex and parietal operculum/posterior insula: an event-related functional magnetic resonance imaging study. *J Neurosci* 2000;20:7438-45.
- Nielsen FA, Balslev D, Hansen LK. Mining the posterior cingulate: segregation between memory and pain components. *Neuroimage* 2005;27:520-32.
- Foltz EL, White LE. The role of rostral cingulotomy in pain relief. *Int J Neurol* 1968;6:353-73.
- Talbot JD, Villemure JG, Bushnell MC, Duncan GH. Evaluation of pain perception after anterior capsulotomy: a case report. *Somatosens Mot Res* 1995;12:115-26.
- Vogt BA, Derbyshire S, Jones AK. Pain processing in four regions of human cingulate cortex localized with co-registered PET and MR imaging. *Eur J Neurosci* 1996;8:1461-73.
- Cole LJ, Farrell MJ, Duff EP, et al. Pain sensitivity and fMRI pain-related brain activity in Alzheimer's disease. *Brain* 2006;129:2957-65.
- Mirzaei S, Knoll P, Koehn H, Bruecke T. Assessment of diffuse Lewy body disease by 2-[18F] fluoro-2-deoxy-D-glucose positron emission tomography (FDG PET). *BMC Nucl Med* 2003;3:1.
- De Meyer G, Shapiro F, Vanderstichele H, et al. Diagnosis independent Alzheimer disease biomarker signature in cognitively normal elderly people. *Arch Neurol* 2010;67:949-56.
- Ballanger B, Strafella AP, van Eimeren T, et al. Serotonin 2 A Receptors and Visual hallucinations in Parkinsons Disease. *Arch Neurol* 2010;67:416-21.
- Lim SM, Katsifis A, Villemagne V, et al. The 18 F FDG PET cingulate island sign and comparison to 123I beta CIT SPECT for diagnosis of dementia with Lewy bodies. *J Nucl Med* 2009;50:1638-45.
- Ishii K, Soma T, Kono AK, et al. Comparison of regional brain volume and glucose metabolism between patients with mild dementia with Lewy bodies and those with mild Alzheimer's disease. *J Nucl Med* 2007;48:704-11.
- Fujishiro H, Iseki E, Murayama N, et al. Diffuse occipital hypometabolism on [18F]-FDG PET scans in patients with idiopathic REM sleep behavior disorder: prodromal dementia with Lewy bodies? *Psychogeriatrics* 2010;10:144-52.
- Dubois B, Feldman HH, Jcava C, et al. Revising the definition of Alzheimer's disease: a new lexicon. *Lancet Neurology* 2010;9:1118-27.
- Landua SM, Havey D, Madson CM, et al. Comparing predictors of conversion and decline in mild cognitive impairment. *Neurology* 2010;75:230-8.
- Hu WT, Wang Z, Lee VM, et al. Distinct cerebral perfusion patterns in FTLN and AD. *Neurology* 2010;75:881-8.
- Emre M, Tsolaki M, Bonuccelli U, et al. Memantine for patients with Parkinson's disease dementia or dementia with Lewy bodies: a randomized, double blind, placebo controlled trial. *Lancet Neurol* 2010;9:969-77.
- Small SA, Schobel SA, Buxton RB, et al. A pathophysiological framework of hippocampal dysfunction in ageing and disease. *Nat Rev Neurosci* 2011;12:585-601.
- Petrella JR, Sheldon FC, Prince SE, et al. Default mode network connectivity in stable vs progressive mild cognitive impairment. *Neurology* 2011;76:511-7.
- Pievani M, de Haan W, Wu T, et al. Functional network disruption in the degenerative dementias. *Lancet Neurol* 2011;10:829-43.
- Andres-Hanna JR, Reidler JS, Sepulcre J, et al. Functional - anatomic fractionation of the brain's default mode network. *Neuron* 2010;65:550-62.
- Galvin JE, Price JL, Yan Z, et al. Resting bold fMRI differentiates dementia with Lewy bodies vs Alzheimer disease. *Neurology* 2011;76:1797-803.
- Kadir A, Darreh-Shori T, Almkvist O, et al. Changes in brain 11C nicotine binding sites in patients with mild Alzheimer's disease following rivastigmine treatment as assessed by PET. *Psychopharmacol* 2007;191:1005-14.
- Hilker R, Thomas AV, Klein JC, et al.

- Dementia in Parkinsons disease: functional imaging of cholinergic and dopaminergic pathways. *Neurology* 2005;65:1716-22.
38. Seeley WW, Crawford RK, Zhou J, et al. Neurodegenerative disease target large scale human brain networks. *Neuron* 2009;62:42-52.
  39. Seeley WW, Menon V, Schatzberg AF, et al. Dissociable intrinsic connectivity networks for salience processing and executive control. *J Neurosci* 2007;27:2349-56.
  40. Sprons O, Tononi G, Koetter R. The human connectome: a structural description of the human brain. *PLoS Comput Biol* 2005;1:e42.
  41. Katzman R, Aronson M, Fuld P, et al. Development of dementing illnesses in an 80 year old volunteer cohort. *Ann Neurol* 1989;25:307-24.
  42. Stern Y. Cognitive reserve. *Neuropsychologia* 2009;47:2015-28.
  43. Stern Y, Zarahn E, Hilton HJ, et al. Exploring the neural basis of cognitive reserve. *J Clin Exp Neuropsychology* 2003;5:691-701.
  44. Kemppainen NM, Aalto S, Karrasch M, et al. Cognitive reserve hypothesis: Pittsburgh compound B and fluorodeoxyglucose position emission tomography in relation to education in mild Alzheimer's disease. *Ann Neurol* 2008; 63:112-8.