

Immunoreactivity of p21, MMP-1 and CB2 receptor proteins in cutaneous canine mast cell tumours: an association with the three-tier grading system

Kamila Bulak¹, Anna Kycko², Anna Śmiech¹✉, Wojciech Łopuszyński¹

¹Department of Pathomorphology and Forensic Veterinary Medicine,
University of Life Sciences in Lublin, 20-612 Lublin, Poland

²Department of Pathology, National Veterinary Research Institute, 24-100 Puławy, Poland
anna.smiech@up.lublin.pl

Received: July 22, 2023

Accepted: November 22, 2023

Abstract

Introduction: Mast cell tumours (MCTs) arise in the dermis and subcutaneous tissues in animals and humans and are one of the most common neoplasms of the skin in dogs. Cannabinoid type 2 receptor (CB2R), cyclin-dependent kinase inhibitor (p21) and matrix metalloproteinase 1 (MMP-1) are potential targets for novel anti-tumour therapeutic strategies. This study evaluated by immunohistochemical means the reactivity of p21, MMP-1 and CB2R proteins in association with a three-tier grading system in cutaneous canine MCTs. **Material and Methods:** Formalin-fixed, paraffin-embedded canine MCTs were processed for histochemical analysis and immunohistochemical staining using antibodies against p21, MMP-1 and CB2R. The results were analysed statistically. **Results:** The strongest p21 immunolabelling was detected in grade 3 MCTs, while grade 1 tumours showed mild or no detectable p21 immunoreactivity (P-value < 0.001). Strong immunolabelling of MMP-1 was the most common in grade 1 tumours (P-value < 0.001) and CB2R was significantly less frequent in grade 3 tumours than in grade 1 (P-value < 0.001) and grade 2 (P-value < 0.001). **Conclusion:** High immunoreactivity of MMP-1 can be a marker of grade 1 MCTs in dogs, whereas p21 protein overexpression can be a marker of grade 3 canine MCTs. Strong CB2R immunoreactivity with simultaneous underexpression of p21 and high immunoreactivity of MMP-1 proteins may indicate that the use of cannabinoids in grade 1 MCTs in dogs is practicable.

Keywords: mast cell tumour, MMP-1 protein, p21 protein, CB2 receptor protein, cannabinoid.

Introduction

Mast cell tumours (MCTs) have been characterised as the effect of a haematopoietic disorder affecting both humans and animals and resulting in the malignant transformation of mast cells of various organs (28). These tumours arise predominantly in the dermis and subcutaneous tissues, and in dogs, they are frequently malignant and are the most common form of skin neoplasm (27). This type of neoplasm provides good material for research in the areas of carcinogenesis and anti-cancer treatment because of its high incidence in dogs.

One of the widely explored therapeutic options is the use of cannabinoids. The presence of cannabinoid receptors in the skin has been demonstrated in animals and humans; therefore, one of the potential therapeutic targets in MCT research might be the endocannabinoid

system (4). According to various studies, phytocannabinoids derived from *Cannabis sativa* plants have potential anti-inflammatory, pro-apoptotic and anti-proliferative effects (9). In recent years, there has been increasing evidence of cannabinoid-induced analgesic effects, which has led to cannabis extracts occasionally being used as part of palliative treatment for cancer patients. Cannabinoids act *via* cannabinoid receptors, and those used in such a way primarily interact with cannabinoid receptor type 2 (CB2R) (30). They have promising therapeutic potential and fewer and milder adverse psychotropic effects than those that may accompany CB1 receptor-based therapies (9).

One of the apoptosis-related proteins which have been extensively investigated in the context of anti-cancer therapy is the cyclin-dependent kinase inhibitor (p21). Scientific research has proved that the p21 protein is characterised by functional duality and that its ability

to inhibit apoptosis results in an oncogenic effect (18). Increased activity of the p21 protein makes cells more susceptible to the ageing process, which in turn may contribute to the growth of unfavourable mutations and, consequently, to neoplastic transformation (1, 5). The p21 protein protects cells from excessive apoptosis caused by chemotherapeutic drugs. Reducing the expression of the gene encoding the p21 protein increases the sensitivity of cancer cells to chemotherapy (12).

The extracellular matrix is present in all tissues as an amorphous structure with a unique composition. In order to maintain homeostasis, it is constantly remodelled by matrix metalloproteinases (MMPs) (3). These proteinases are characterised by low activity in physiological conditions and high activity in pathologically changed or inflamed tissues. Cytokines, growth factors and stimulants from neoplastic cells are responsible for the increase in MMP activity (25). In tumour development, the degradation of collagen as a result of the MMP-1 activity promotes cell migration. Moreover, MMPs have the potential to stimulate angiogenesis, and thus to spread neoplastic cells *via* the haematogenous route to distant organs (17). The excessive activity of collagenases may be related to the stage of tumour advancement (6).

The current knowledge on p21, MMP-1 and CB2 immunoreactivity in dogs is limited and based on few studies. These three proteins are considered potential targets for novel anti-tumour therapeutic strategies. The aim of this study was to evaluate by immunohistochemical means the reactivity of the p21, MMP-1 and CB2R proteins in association with a three-tier grading system in cutaneous canine MCTs. Our results were compared with those of previously published studies and a literature review was performed.

Material and Methods

Histopathology and MCT grading. The material for the study involved a selection of archival formalin-fixed, paraffin-embedded tissues from solitary canine cutaneous MCTs removed surgically with clear margins. A selection of 15 tumour samples with a grade 1 MCT, 15 tumour samples with a grade 2 MCT and 15 tumour samples with a grade 3 MCT was made for subsequent immunohistochemical analyses. The tissue sections were stained with haematoxylin and eosin for histopathology. In order to visualise the metachromatic cytoplasmic granules, a routine toluidine blue staining was used as an additional method to identify mast cells (22).

The grade of MCT malignancy was assessed according to the criteria of Patnaik *et al.* (19), taking into account depth of infiltration, cellular and nuclear atypia, granularity, number of nucleoli, multinucleation and the mitotic count. Grade 1 MCTs are well demarcated from adjacent tissues, and their neoplastic cells are monomorphic and have a centrally located nucleus and

abundant cytoplasmic granules. In grade 2 MCTs, cells often infiltrate the subcutaneous tissue, are arranged in strands or large clusters, and have poorly granular cytoplasm, clearly visible single nucleoli and a low mitotic count (0–2 per high-power field – HPF). Grade 3 MCTs infiltrate the subcutaneous tissue and often have apical ulceration, and their cells exhibit marked nuclear pleomorphism, lack cytoplasmic granules, and are markedly enlarged. They have double or multiple nuclei, numerous clearly visible nucleoli, atypical mitotic figures, and a high mitotic count (3–6 per HPF).

Immunohistochemistry. For immunohistochemistry (IHC), 4- μ m-thick tissue sections were attached to SuperFrost Plus slides (Thermo Fisher Scientific, Waltham, MA, USA). After deparaffinisation and rehydration, endogenous peroxidase activity was quenched with a peroxidase suppressor for 10 min. Heat-induced antigen retrieval was performed in a water bath for 30 min using an ethylenediaminetetraacetic acid buffer (pH 8.0) to expose the CB2 receptor, p21 and MMP-1 proteins. Next, the tissues were permeabilised in 3% bovine serum albumin–phosphate-buffered saline (PBS) solution for 30 min at room temperature, then incubated with primary antibodies for 1 h at room temperature in a humidified chamber. The primary antibodies used in this study, all canine-specific, were as follows: anti-CB2R (Cat. No. TA317640; OriGene Technologies, Rockville, MD, USA), anti-p21 (Cat. No. M7202; clone SX118, Agilent Dako, Santa Clara, CA, USA) and anti-MMP-1 (Cat. No. ABIN2777120; antibodies-online, Aachen, Germany), diluted 1:200, 1:50 and 1:500, respectively. Tris-buffered saline, (Sigma-Aldrich, St. Louis, MO, USA) was used instead of the primary antibody to obtain the negative control for the IHC test. Tissue sections were then washed in PBST (0.1% Tween 20 in PBS solution), and the IHC reaction was carried out by an indirect method using an UltraVision Quanto Detection System (Cat. No. TL-060-QHD; Thermo Fisher Scientific, Waltham, MA, USA) with 3,3'-diaminobenzidine as the chromogen substrate to mark the reaction sites. Tissues were counterstained with haematoxylin (Novocastra; Leica Biosystems, Deer Park, IL, USA) and prepared for mounting. Microscopic slides were examined using an Eclipse E600 light microscope (Nikon Instruments, Tokyo, Japan). Photographs were taken with a digital camera (Nikon DS-Fi1; Nikon Instruments, Tokyo, Japan).

The number of positive cells in the immunohistochemical reaction and the total stained area were determined semi-quantitatively. Marker immunoreactivity was examined only for mast cells, as under a light microscope, these cells can be easily distinguished from other inflammatory cells (such as eosinophils) based on morphology and size. Marker immunoreactivity was measured above a fixed threshold applied to all images to distinguish specific staining from background using NIS-Elements BR-2.20 imaging software (Nikon Europe, Prague, Czech Republic). The

stained cells were categorised into 0 (negative), + (weakly positive), ++ (moderately positive), and +++ (strongly positive) groups. Three different experienced pathologist observers manually quantified each image. Positive or negative status for CB2R/p21/MMP-1 was assessed in three random fields of view (400× HPF, 2.37 mm²), and the total percentage score was obtained after evaluating at least 900 neoplastic mast cells in each tumour.

The statistical analysis was carried out in IBM SPSS Statistics 28.0 software (IBM, Armonk, NY, USA). The associations were evaluated through Pearson's χ^2 test. Subsequently, Fisher's *post hoc* test with Bonferroni correction was used. Also, Cramer's V test was used to measure the strength of association. Differences with P-value <0.05 were considered significant.

Results

The histopathological examination divided the MCTs into three groups displaying three levels of cell-differentiation: grade 1 tumours showed a high degree of cell differentiation, grade 2 tumours had an intermediate degree of cell differentiation, and grade 3 tumours were characterised by a low degree of differentiation with distinct cellular atypia and a tendency to form multinucleated cells (Fig. 1 A–C). Grade 1 tumours were

stained intensely with toluidine blue, while with increasing tumour grade, the intensity of the staining was weaker and the granular character of the cytoplasm was less visible (Fig. 1 D–F).

Immunoreactivity for the MMP-1 protein was denoted by brown cytoplasmic staining. The intensity of the immunohistochemical reaction was strong in grade 1, moderate in grade 2 and weak in grade 3 tumours (Fig. 3 A–C). The immunolabelling of p21, visible in the nuclei, was the strongest in grade 3 tumours and gradually weaker with increasing tumour differentiation in lower-grade tumours (Fig. 5 A–C). The cytoplasmic immunohistochemical reaction for CB2R protein was marked in grade 1 tumours and decreased with increasing grade of the tumours (Fig. 7 A–C). There was a significant association (strong for MMP-1 and p21, and moderate for CB2R) between the intensity of the reaction and the three-tier grading system (P-value <0.001). Grade 1 MCTs showed mild or no detectable p21 immunoreactivity (P-value <0.001). In contrast to p21, MMP-1 and CB2 displayed marked or moderate immunoreactivity in grade 1 and grade 2 tumours (Figs 2, 4 and 6). Strong reaction intensity for MMP-1 was more common in grade 1 tumours (P-value <0.001) and for CB2R was significantly less frequent in grade 3 tumours than in grade 1 and grade 2 tumours (P-value <0.001) (Fig. 6). In grade 2 tumours strong immunoreactivity for the MMP-1 protein was as frequent as for the CB2R protein (P-value = 1.000).

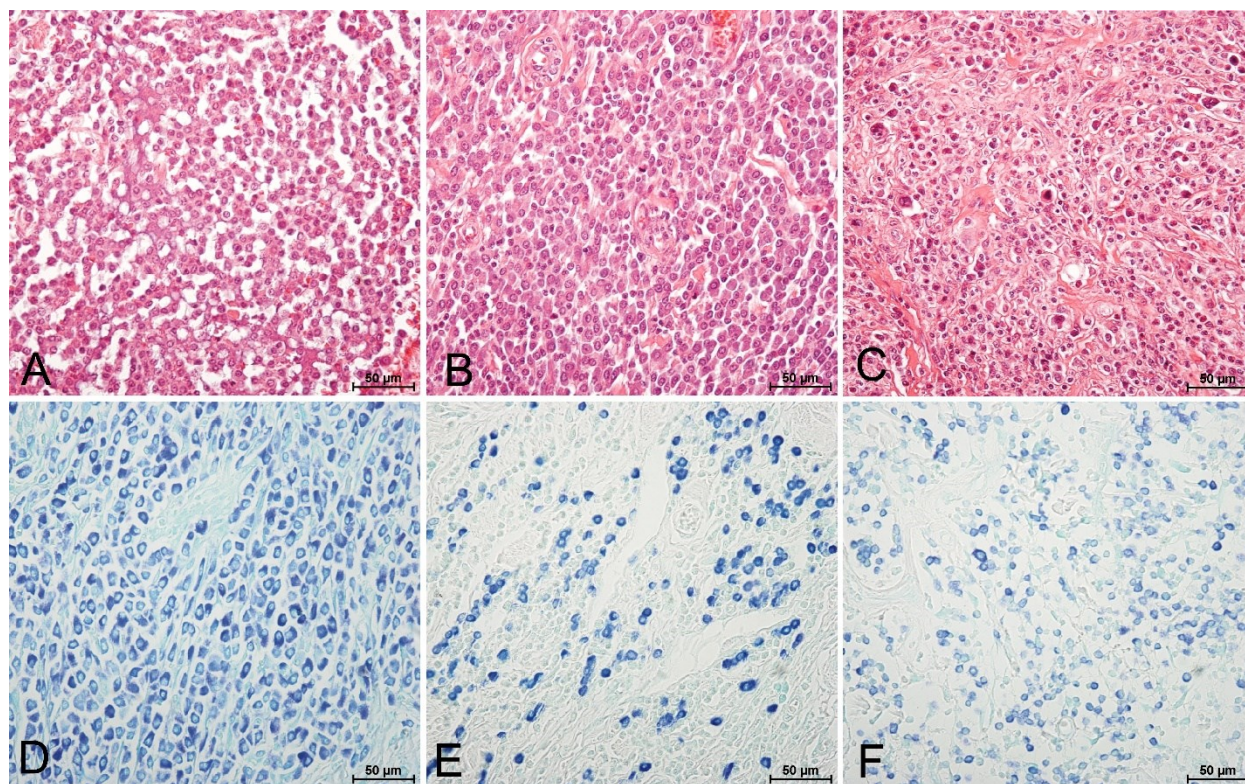


Fig. 1. Staining of mast cell tumours (MCTs). A – Haematoxylin & eosin (H&E) staining visualising a high degree of cell differentiation in a grade 1 MCT; B – H&E staining visualising an intermediate degree of cell differentiation in a grade 2 MCT; C – H&E staining visualising poorly differentiated neoplastic cells in a grade 3 MCT; D – Intense toluidine blue staining visualising intracytoplasmic granules of neoplastic mast cells in a grade 1 MCT; E – Toluidine blue staining visualising individual cells in a grade 2 MCT; F – Weak toluidine blue staining visualising a grade 3 MCT

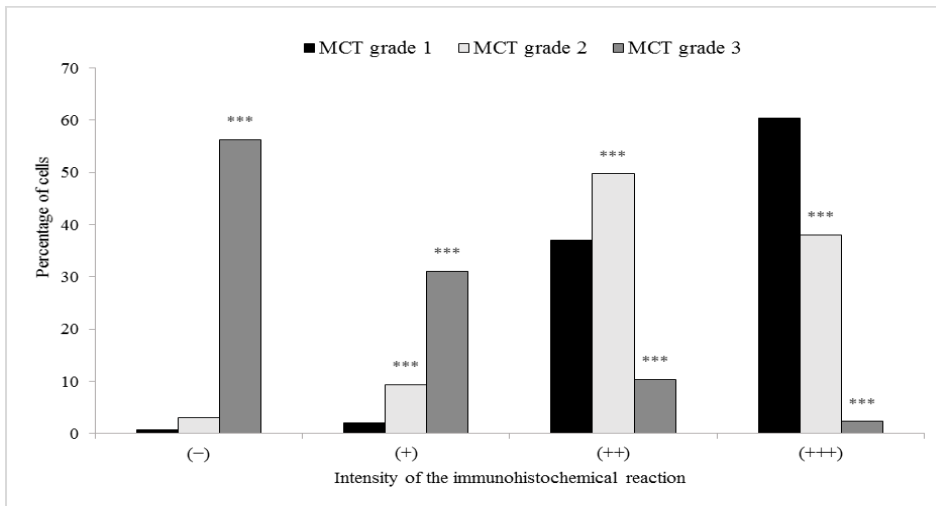


Fig. 2. Frequency of immunoreactivity for matrix metalloproteinase 1 (MMP-1) receptor protein in grade 1, 2 and 3 mast cell tumours (MCTs). * – P-value < 0.05; ** – P-value < 0.01; *** – P-value < 0.001 compared to grade 1 MCTs; (-) – no reaction; (+) – weak reaction; (++) – moderate reaction; (+++) – strong reaction

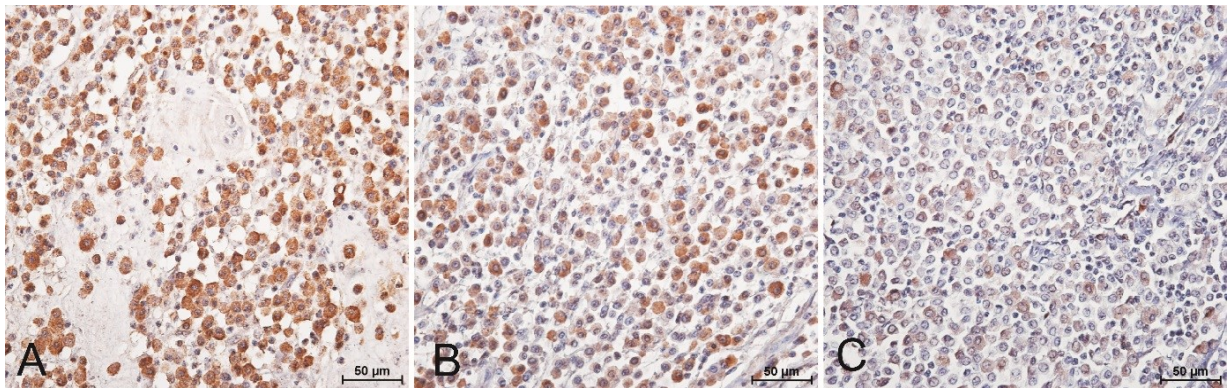


Fig. 3. Immunohistochemistry with anti-matrix metalloproteinase 1 (MMP-1) primary antibody with positive reaction visible as brown staining. A – strong cytoplasmic reaction in a grade 1 mast cell tumours (MCTs); B – moderate cytoplasmic reaction in a grade 2 MCT; C – weak cytoplasmic reaction in a grade 3 MCT

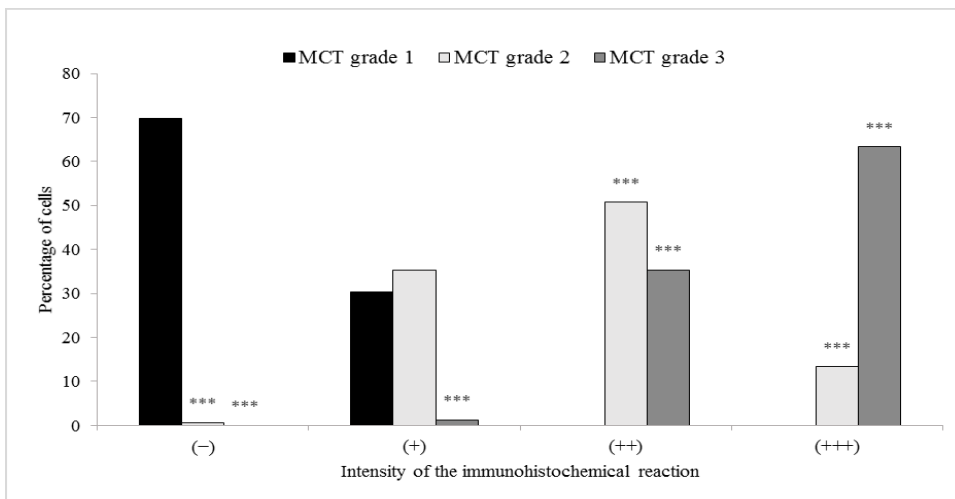


Fig. 4. Frequency of immunoreactivity for p21 protein in grade 1, 2 and 3 mast cell tumours (MCTs). * – P-value < 0.05; ** – P-value < 0.01; *** – P-value < 0.001 compared to grade 1 MCTs; (-) – no reaction; (+) – weak reaction; (++) – moderate reaction; (+++) – strong reaction

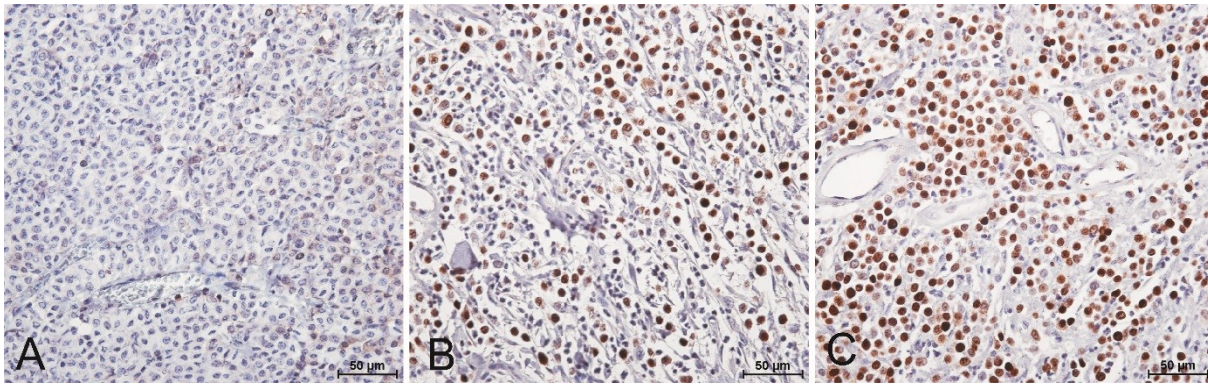


Fig. 5. Immunohistochemistry with primary anti-p21 antibody with positive reaction visible as brown staining. A – weak nuclear reaction in a grade 1 mast cell tumour (MCT); B – moderate nuclear reaction in a grade 2 MCT; C – strong nuclear reaction in a grade 3 MCT

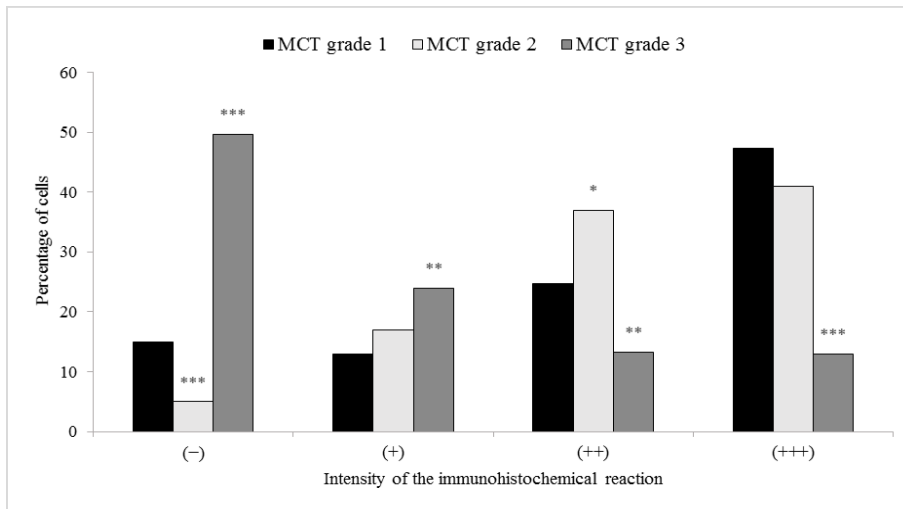


Fig. 6. Frequency of immunoreactivity for cannabinoid type 2 receptor proteins in grade 1, 2 and 3 mast cell tumours (MCTs). * – P-value < 0.05; ** – P-value < 0.01; *** – P-value < 0.001 compared to grade 1 MCTs; (-) – no reaction; (+) – weak reaction; (++) – moderate reaction; (+++) – strong reaction

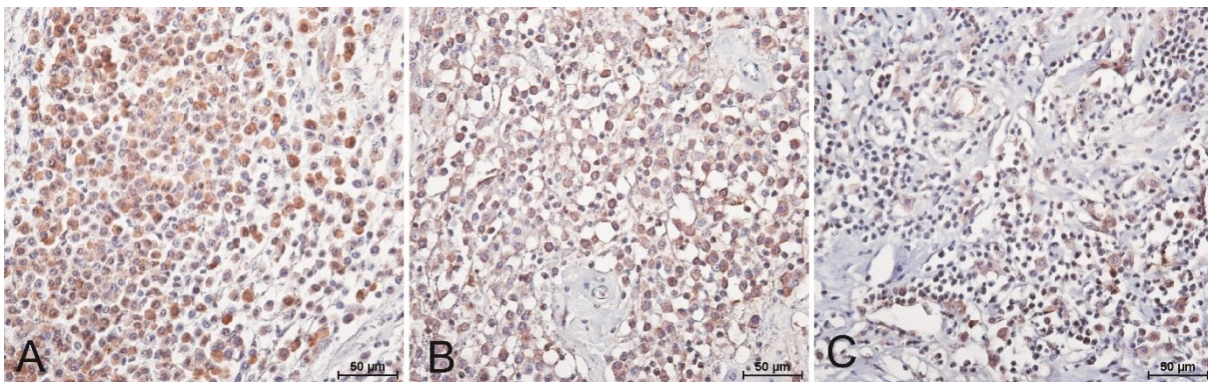


Fig. 7. Immunohistochemistry with primary anti-cannabinoid type 2 receptor antibody with positive reaction visible as brown staining. A – moderate to strong cytoplasmic reaction in a grade 1 mast cell tumour (MCT); B – moderate cytoplasmic reaction in a grade 2 MCT; C – weak cytoplasmic reaction in a grade 3 MCT

Discussion

The skin, as well as the mucous membranes of the respiratory tract, digestive tract and genitourinary organs, are particularly rich in mast cells (28). Besides immune modulation and presentation of antigens, participation in angiogenesis and tissue remodelling are

also functions of mast cells (2, 26). The effect of a wide spectrum of stimuli affecting mast cells may be the excessive and uncontrolled growth of mast cells, referred to as mast cell tumours. Tumours of this kind account for 16–21% of skin neoplasms in dogs (27). Macroscopically, MCTs are often confused with and misdiagnosed as oedema, inflammation or non-

neoplastic lesions, leading to inappropriate treatment regimens and impacting prognosis negatively. In the tumour microenvironment, excessive production of chemokines by malignant mast cells induces stimulation of eosinophils, resulting in peripheral eosinophilia. In turn, the stem cell factor released by eosinophils supports further activation of mast cells. The paraneoplastic hypereosinophilia which accompanies MCTs positively correlates with higher recurrence rates (11). Eosinophils have the ability to secrete pro-inflammatory tissue-degrading mediators, including collagenases that facilitate the degradation of type I, II and III collagen. The immunoreactivity of MMPs in eosinophils has not been detected, but a positive correlation between the number of eosinophils and the degree of degraded type I collagen has been proved (20). In our study, MMP-1 was detected in the cytoplasm of the cells comprising the neoplastic cellular masses. This proteinase, also termed collagenase-1, has been described to be mainly expressed by fibroblasts, while increased expression of MMP-1 has been reported in various inflammatory and neoplastic diseases (13). Di Girolamo *et al.* (10) proved that collagenase-1 protein is also expressed by mast cells. In our study, significantly higher (P-value <0.001) cytoplasmic immunoreactivity of the MMP-1 protein was revealed in grade 1 and grade 2 tumours. According to the literature, most MMPs are secreted as inactive proenzymes which are activated in the extracellular matrix (13). Mast cell degranulation, which releases mast cell proteases, can increase MMPs' activity, leading to MCT microenvironment destabilisation. Well-differentiated mast cells can therefore increase MCT severity by activation of MMPs (15). Comparing the results of other authors' studies with ours, it can be assumed that well-differentiated tumours have the capability to intensively recruit collagenases in the tumour microenvironment. Collagenases enable the onset of tumour cell migration and angiogenesis, and thus promote tumour growth in the early phase of its progression (13). This conclusion is also supported by the results of a study by Daniel *et al.* (7), who reported that dogs with MCTs with a low intratumoral collagen index had a shorter survival time than dogs with MCTs with a high intratumoral collagen index. Our study demonstrated that matrix metalloproteinase 1 is present in canine MCTs and appears to be related to the degree of histological malignancy of the tumours. Stromal cells, in combination with matrix components such as type I collagen, can interact with tumour cells to regulate MMP-1 production. This expanded knowledge about MMP-1 production and regulation could help in the development of new treatments not only for MCTs.

Expression of the p21 protein in the examined tumours was detected in the nuclei of the neoplastic cells. The comparative analysis revealed that the p21 protein showed significantly higher (P-value <0.001) immunoreactivity in the grade 3 tumours compared to the well-differentiated ones. Similar results were obtained by Wu *et al.* (29), who reported an increase in

the p21 nuclear immunoreactivity accompanying a decrease in cell differentiation in canine MCTs. The p21 protein is an inhibitor of cyclin-dependent kinases and plays an important role in cell-cycle regulation. According to previous research, during the induction of stress by various factors, the overexpression of p21 caused by p53 activation may lead to a chronic state of cell senescence (1). Considering that detection of senescent cells could enable tumour staging in clinical practice (14), the degree of immunoreactivity of the p21 protein appears to be a useful marker in canine MCT diagnosis and monitoring of treatment. In our research, the increased immunoreactivity of the p21 protein in MCTs with the histological grade 3 may indicate an intensification of the senescence process. It should be emphasised that the formation of foci of necrosis within the tumour is the result of tissue compression by the continuous proliferation of neoplastic cells. The process of senescence of tumour cells may indicate the tendency of the tumour mass to form necrotic foci. The presence of necrotic foci in MCT histopathology has usually been considered a negative prognostic factor (8, 27). Furthermore, the weak p21 immunoreactivity in grade 1 and grade 2 tumours obtained in our study may indicate that the tumour mass consisted mainly of proliferating cells, which in turn might be associated with a better prognosis with an application of anti-proliferating chemotherapy. As demonstrated by Manzoor *et al.* (16), there is a positive correlation between increased p21 protein activity and the tumour diameter, histological uniformity of tumour cells and presence of lymph node metastases. Our and other authors' results confirm the hypothesis that the immunoreactivity of the p21 protein may be a marker of the malignancy stage of MCTs (16, 29). It may also be constructive to suggest that p21 expression might be monitored together with that of another important cancer marker, the p53 protein. In tumour cells that have lost the expression of p53 protein, or contain an altered form of p53, p21 levels are dramatically reduced or absent (1). Given that p21 appears to mediate several of the growth-regulatory functions of p53, its expression is predicted to reflect the functional status of p53 in tumours more precisely than p53 accumulation.

The immunohistochemical analysis of the CB2 receptor in the examined MCTs revealed the significantly higher (P-value <0.001) CB2R immunoreactivity in grade 1 and grade 2 tumours. The results are consistent with those in the recent report by Rinaldi *et al.* (23), who demonstrated an expression of cannabinoid receptors in canine MCTs using the two-tier Kiupel classification for tumour grading, where the CB2 receptor was overexpressed in low-grade tumours. The Kiupel classification scheme is considered more specific in detecting aggressive clinical courses of the disease, whereas the three-tier Patnaik grading system applied to MCTs in the present scientific study provides more detailed histological characteristics of the examined tumours (24). Regardless of the classification, according

to both the investigation by Rinaldi *et al.* (23) and the present one, the least differentiated MCTs displayed the lowest level of CB2R expression. Cannabinoid type 2 receptors have been previously found to be expressed in non-neoplastic mast cells; therefore, CB2R proves to be another marker of MCT differentiation. The evidence regarding the differential immunoreactivity of CB2R suggests that manipulating inflammatory cell function by exerting the anti-carcinogenic effect of endocannabinoids and cannabinoids on them may result in a new approach to MCT treatment. This possibility will grow closer or recede as more of the ongoing investigation of this activity in these compounds is reported. Apart from tumour growth inhibition, the phytocannabinoids could potentially modulate inflammatory responses by regulating underlying mechanisms for eosinophil and mast cell recruitment in the canine MCT microenvironment and may have anti-inflammatory effects. Moreover, given that cannabinoids have been established to reduce MMP activity *via* upregulation of the tissue inhibitor of matrix metalloproteinase 1 (21), the high expression of both MMP-1 and CB2R makes grade 1 and grade 2 MCTs interesting targets for possible cannabinoid-based therapy. It is worth mentioning that the mechanism of action of cannabinoids and phytocannabinoids still remains unknown, and it is possible that the use of these compounds will accelerate tumour growth. There is no evidence yet of a beneficial effect of cannabinoids and phytocannabinoids on the clinical form of MCTs in dogs.

By reviewing the literature data, it can be concluded that there is little research so far that includes the immunoreactivity of markers (p21, MMP-1 and CB2R) in mast cell tumours in dogs. The results of our study attribute high immunoreactivity to MMP-1 protein and p21 protein in MCTs, and suggest that MMP-1 can be a marker of grade 1 and p21 of grade 3 canine MCTs. Moreover, the positive immunoreactivity of CB2R with the simultaneous low or absent immunoreactivity of p21 and high immunoreactivity of MMP-1 may be considered an indicator to encourage the usage of cannabinoids in grade 1 MCTs in dogs. Nuclear p21 immunoreactivity and cytoplasmic MMP-1/CB2R immunoreactivity in canine cutaneous MCTs require more case studies based on breed, the presence or absence of metastases, the degree of ulceration, and the primary tumour location. Our study demonstrates nevertheless that the applied method of comparing histological evidence of immunoreactivity with tumour grading can be used for analyses in the future, when the Patnaik and Kiupel MCT grading systems should also be compared because canine cutaneous MCTs are currently classified using both. Moreover, the assessment of the immunoreactivity of MMP-1 and p21 proteins in MCTs may have prognostic significance in the future in clinical trials in the field of veterinary oncology. The estimation of CB2R expression together with monitoring of other tumour markers could enable precise treatment regimens to be designed and improve the quality of life of animals

with MCTs through the early introduction of cannabinoids. The limitation of the study was the availability of only formalin-fixed, paraffin-embedded archival tissues to assess the expression of the selected protein markers. An investigation of possible relations between MMP-1, p-21 and CB2R in canine MCTs would require a genomic and transcriptomic approach relying on fresh biological material. Nevertheless, this work may have brought attention to a field for further research in the context of comparative oncology of MCTs in animals and humans. Since mast cell tumours are more common in animals than in humans, animal tissue has the potential to become an MCT research model in humans.

Conflict of Interests Statement: The authors declare that there is no conflict of interests regarding the publication of this article.

Financial Disclosure Statement: The performed study was funded by the statutory activity of University of Life Sciences in Lublin, Poland.

Animal Rights Statement: None required.

References

- Al Bitar S., Gali-Muhtasib H.: The Role of the Cyclin Dependent Kinase Inhibitor p21^{cip1/waf1} in Targeting Cancer: Molecular Mechanisms and Novel Therapeutics. *Cancers* 2019, 11, 1475, doi: 10.3390/cancers11101475.
- Blackwood L., Murphy S., Buracco P., De Vos J.P., De Fornel-Thibaud P., Hirschberger J., Kessler M., Pastor J., Ponce F., Savary-Bataille K., Argyle D.J.: European consensus document on mast cell tumours in dogs and cats. *Vet Comp Oncol* 2012, 10, e1–e29, doi: 10.1111/j.1476-5829.2012.00341.x.
- Bonnans C., Chou J., Werb Z.: Remodelling the extracellular matrix in development and disease. *Nat Rev Mol Cell Biol* 2014, 15, 786–801, doi: 10.1038/nrm3904.
- Campora L., Miragliotta V., Ricci E., Cristino L., Di Marzo V., Albanese F., Federica Della Valle M., Abramo F.: Cannabinoid receptor type 1 and 2 expression in the skin of healthy dogs and dogs with atopic dermatitis. *Am J Vet Res* 2012, 73, 988–995, doi: 10.2460/ajvr.73.7.988.
- Capparelli C., Chiavarina B., Whitaker-Menezes D., Pestell T.G., Pestell R.G., Hulit J., Andò S., Howell A., Martinez-Outschoorn U.E., Sotgia F., Lisanti M.P.: CDK inhibitors (p16/p19/p21) induce senescence and autophagy in cancer-associated fibroblasts, "fueling" tumor growth via paracrine interactions, without an increase in neo-angiogenesis. *Cell Cycle* 2012, 11, 3599–3610, doi: 10.4161/cc.21884.
- Coussens L.M., Fingleton B., Matrisian L.M.: Matrix metalloproteinase inhibitors and cancer: trials and tribulations. *Science* 2002, 295, 2387–2392, doi: 10.1126/science.1067100.
- Daniel J., Barra C.N., Pulz L.H., Kleeb S.R., Xavier J.G., Catão-Dias J.L., Nishiya A.T., Fukumasu H., Strefezzi R.F.: Intratumoral collagen index predicts mortality and survival in canine cutaneous mast cell tumours. *Vet Dermatol* 2019, 30, 162–e48, doi: 10.1111/vde.12726.
- De Nardi A.B.D., Horta R.D.S., Fonseca-Alves C.E., Paiva F.N.D., Linhares L.C.M., Firmo B.F., Sueiro F.A.R., Oliveira K.D.D., Lourenço S.V., Strefezzi R.D.F., Brunner C.H.M., Rangel M.M.M., Jark P.C., Castro J.L.C., Ubukata R., Batschinski K., Sobral R.A., Cruz N.O.D., Nishiya A.T., Fernandes S.C., Cunha S.C.D.S.,

- Gerardi D.G., Challoub G.S.G., Biondi L.R., Laufer-Amorim R., Paes P.R.D.O., Lavelle G.E., Huppés R.R., Grandi F., Vasconcellos C.H.D.C., Anjos D.S.D., Luzo Á.C.M., Matera J.M., Vozdova M., Dagli M.L.Z.: Diagnosis, Prognosis and Treatment of Canine Cutaneous and Subcutaneous Mast Cell Tumors. *Cells* 2022, 11, 1–37, doi: 10.3390/cells11040618.
9. Dhopeswarkar A., Mackie K.: CB2 Cannabinoid receptors as a therapeutic target – what does the future hold? *Mol Pharmacol* 2014, 86, 430–437, doi: 10.1124/mol.114.094649.
 10. Di Girolamo N., Wakefield D.: *In vitro* and *in vivo* expression of interstitial collagenase/MMP-1 by human mast cells. *Dev Immunol* 2000, 7, 131–142, doi: 10.1155/2000/82708.
 11. Galiotta V., Parisi F., Cocumelli C., Pierini A., Poli A., Scaramozzino P., Spallucci V., Millanta F.: Preliminary Assessment of Tumor-Associated Tissue Eosinophilia (TATE) in Canine Mast Cell Tumors: Prevalence and Prognostic Relevance and Its Association with Neoangiogenesis. *Animals* 2023, 13, 283, doi: 10.3390/ani13020283.
 12. Gartel A.L., Tyner A.L.: The Role of the Cyclin-dependent Kinase Inhibitor p21 in Apoptosis. *Mol Cancer Ther* 2002, 1, 639–649.
 13. Johansson N., Ahonen M., Kähäri V.M.: Matrix metalloproteinases in tumor invasion. *Cell Mol Life Sci* 2000, 57, 5–15, doi: 10.1007/s000180050495.
 14. Kim E.M., Jung C.-H., Kim J., Hwang S.-G., Park J.K., Um H.-D.: The p53/p21 Complex Regulates Cancer Cell Invasion and Apoptosis by Targeting Bcl-2 Family Proteins. *Cancer Res* 2017, 77, 3092–3100, doi: 10.1158/0008-5472.CAN-16-2098.
 15. Komi D.E.A., Redegeld F.A.: Role of Mast Cells in Shaping the Tumor Microenvironment. *Clin Rev Allergy Immunol* 2020, 58, 313–325, doi: 10.1007/s12016-019-08753-w.
 16. Manzoor S., Saif R., Sadia H., Firyal S., Tayyab M., Mansha M., Mahmood A.K., Hashmi A.S., Awan A.R., Wasim M.: Molecular expression of cyclin dependent kinase inhibitor (p21) in canine tumors. *J Anim Plant Sci* 2019, 29, 1127–1134.
 17. Page-McCaw A., Ewald A.J., Werb Z.: Matrix metalloproteinases and the regulation of tissue remodeling. *Nat Rev Mol Cell Biol* 2007, 8, 221–233, doi: 10.1038/nrm2125.
 18. Parveen A., Akash M.S., Rehman K., Kyunn W.W.: Dual Role of p21 in the Progression of Cancer and Its Treatment. *Crit Rev Eukaryot Gene Expr* 2016, 26, 49–62, doi: 10.1615/CritRevEukaryotGeneExpr.v26.i1.60.
 19. Patnaik A.K., Ehler W.J., MacEwen E.G.: Canine cutaneous mast cell tumor: morphologic grading and survival time in 83 dogs. *Vet Pathol* 1984, 21, 469–474, doi: 10.1177/030098588402100503.
 20. Rajamäki M.M., Järvinen A.K., Sorsa T., Maisi P.: Collagenolytic Activity in Bronchoalveolar Lavage Fluid in Canine Pulmonary Eosinophilia. *J Vet Intern Med* 2002, 16, 658–664, doi: 10.1111/J.1939-1676.2002.TB02404.X.
 21. Ramer R., Hinz B.: Inhibition of cancer cell invasion by cannabinoids via increased expression of tissue inhibitor of matrix metalloproteinases-1. *J Natl Cancer Inst* 2008, 100, 59–69, doi: 10.1093/jnci/djm268.
 22. Ribatti D.: The Staining of Mast Cells: A Historical Overview. *Int Arch Allergy Immunol* 2018, 176, 55–60, doi: 10.1159/000487538.
 23. Rinaldi V., Boari A., Ressel L., Bongiovanni L., Crisi P.E., Cabibbo E., Finotello R.: Expression of cannabinoid receptors CB1 and CB2 in canine cutaneous mast cell tumours. *Res Vet Sci* 2022, 152, 530–536, doi: 10.1016/j.rvsc.2022.09.013.
 24. Sabattini S., Scarpa F., Berlato D., Bettini G.: Histologic grading of canine mast cell tumor: is 2 better than 3? *Vet Pathol* 2015, 52, 70–73, doi: 10.1177/0300985814521638.
 25. Stamenkovic I.: Extracellular matrix remodelling: the role of matrix metalloproteinases. *J Pathol* 2003, 200, 448–464, doi: 10.1002/path.1400.
 26. Theoharides T.C., Alysandratos K.D., Angelidou A., Delivanis D.A., Sismanopoulos N., Zhang B., Asadi S., Vasiadi M., Weng Z., Miniati A., Kalogeromitros D.: Mast cells and inflammation. *Biochim Biophys Acta* 2012, 1822, 21–33, doi: 10.1016/j.bbadis.2010.12.014.
 27. Welle M.M., Bley C.R., Howard J., Rüfenacht S.: Canine mast cell tumours: a review of the pathogenesis, clinical features, pathology and treatment. *Vet Dermatol* 2008, 19, 321–339, doi: 10.1111/j.1365-3164.2008.00694.x.
 28. Willmann M., Hadzizufovic E., Hermine O., Dacasto M., Marconato L., Bauer K., Peter B., Gamperl S., Eisenwort G., Jensen-Jarolim E., Müller M., Arock M., Vail D.M., Valent P.: Comparative oncology: The paradigmatic example of canine and human mast cell neoplasms. *Vet Comp Oncol* 2019, 17, 1–10, doi: 10.1111/vco.12440.
 29. Wu H., Hayashi T., Inoue M.: Immunohistochemical Expression of p27 and p21 in Canine Cutaneous Mast Cell Tumors and Histiocytomas. *Vet Path* 2004, 41, 296–299, doi: 10.1354/vp.41-3-296.
 30. Yang Y., Vyawahare R., Lewis-Bakker M., Clarke H.A., Wong A.H.C., Kotra L.P.: Bioactive Chemical Composition of Cannabis Extracts and Cannabinoid Receptors. *Molecules* 2020, 25, 3466, doi: 10.3390/molecules25153466.