

Total endoscopic management of a large bladder leiomyoma

Jaisukh Kalathia, Santosh Agrawal, Saurabh Sudhir Chipde, Rajeev Agrawal

Department of Urology and Kidney Transplantation, Sri Aurobindo Institute of Medical Sciences, Indore, Madhya Pradesh, India

Abstract

Leiomyoma of the urinary bladder is a very rare entity and represents <0.5% of all bladder tumours, with only 250 cases reported worldwide to date. We report a case of leiomyoma of the bladder 55-year-old female presented with chief complaints lower abdomen pain since 1 year associated with intermittency, burning, frequency and hesitancy in micturition. Bimanual examination of the patient revealed a mass on the right side near the bladder neck. USG suggested a well circumscribed polypoidal soft tissue lesion seen projecting in urinary bladder lumen and attached to the posterior wall and base of bladder with no internal vascularity. On cystoscopic examination, large smooth sessile growth arising from the right postero-lateral wall was noted with right ureteric orifice not visualized. Magnetic resonance imaging showed Large well defined rounded soft tissue lesion close to anterior surface of the cervix and vagina which was isointense to the skeletal muscles on T1 and T2 images with small focal irregular cystic areas of necrosis seen. It could be urinary bladder neoplasm or sub serosal cervical fibroid. Transurethral resection of tumor was performed. The pathologic diagnosis was leiomyoma of the bladder. We discuss the diagnosis and management of leiomyoma of the bladder and briefly review the literature.

Key Words: Leiomyoma, polypoidal, TURBT

Address for correspondence:

Dr. Santosh Agrawal, Department of Urology and Kidney Transplantation, Sri Aurobindo Institute of Medical Sciences, Indore, Madhya Pradesh, India.

E-mail: santro4you@yahoo.com

Received: 25.05.2015, **Accepted:** 01.07.2015

INTRODUCTION

Mesenchymal tumors of the bladder are relatively rare and heterogenous group of neoplasms, which constitute 1–5% of all bladder tumors. Leiomyoma is the most common type that accounts for around 0.43% of all bladder tumors.^[1] The incidence of bladder leiomyoma is 3 times higher in women than in men.^[2] Typically, it occurs in the 4th and 5th decades of life. The patients complain of nonspecific urinary symptoms or pelvic pain.^[3]

We are presenting a case of an elderly woman presented with chronic pelvic pain and irritative urinary symptoms. On

imaging, a large mass was found in urinary bladder, occupying three-fourth of its lumen. We opted for the minimally invasive endoscopic approach to treat this tumor. The histology showed benign leiomyoma. On follow-up, there was no recurrence. We are describing here the various presentations and treatment modalities of this rare bladder tumor.

CASE REPORT

A 55-year-old female came with complaints of on and off right lower quadrant abdominal pain for 1-year. The patient also had urinary complaints such as intermittency, burning,

Access this article online	
Quick Response Code:	Website: www.urologyannals.com
	DOI: 10.4103/0974-7796.164858

This is an open access article distributed under the terms of the Creative Commons Attribution-NonCommercial-ShareAlike 3.0 License, which allows others to remix, tweak, and build upon the work non-commercially, as long as the author is credited and the new creations are licensed under the identical terms.

For reprints contact: reprints@medknow.com

How to cite this article: Kalathia J, Agrawal S, Chipde SS, Agrawal R. Total endoscopic management of a large bladder leiomyoma. *Urol Ann* 2015;7:527-9.

and frequency. She denied any episodes of fever, chills, gross hematuria, or dysuria. Her past medical and surgical history were insignificant. The per abdominal examination was normal, but on bimanual pelvic examination a mass on the right side near the bladder neck area was palpable.

Ultrasonography (USG) suggested a well-circumscribed polypoidal soft tissue lesion projecting in urinary bladder lumen and attached to the posterior wall and base of the bladder with no internal vascularity [Figure 1a]. Intravenous pyelography demonstrated a large filling defect in the bladder and normal functioning kidneys [Figure 1b]. To know the detailed anatomy, magnetic resonance imaging (MRI) was done, which showed a large, well-defined rounded, soft tissue lesion of size 67.6 mm × 51 mm at posteroinferior aspect of urinary bladder, close to anterior surface of the cervix and vagina. The mass was isointense to the skeletal muscles on T1 and T2 images. It also showed small focal irregular cystic areas of necrosis [Figure 1c]. The finding was suggestive of a benign lesion, probably leiomyoma. The urine cytology smear showed large numbers of squamous cells; few degenerated cells and bacteria, but atypical cells were not seen.

On cystoscopy, a large smooth sessile growth arising from the right posterolateral wall was noted [Figure 2]. The right ureteric orifice was not visualized. Transurethral resection (TUR) of the lesion was performed, and resected specimens were sent for histopathological examination. At the completion of the resection, the previously palpable pelvic mass could no longer be appreciated by bimanual examination.

On postoperative day I, the patient's urine was clear, the Foley catheter was removed, and the patient was discharged on oral antibiotics. The histopathological examination showed spindle cells in sheets and fascicles oriented in different planes. There was no epithelial lining seen. There was no atypia, mitotic activity or other indices of malignancy. The impression of leiomyoma was made [Figure 3]. On follow-up at 3 months, the patient was asymptomatic, and USG was normal.

DISCUSSION

The benign bladder tumors consist of leiomyomas, fibromyomas, rhabdomyomas, fibromas, and osteomas. Among these, the most common histological type of benign bladder tumor is leiomyoma, which is commonly found in middle-aged females.^[2] These lesions may be endovesical (63%), extravescical (30%), or intramural (7%).^[4] Endovesical mass has been mostly recognizable due to its characteristic bulging into the bladder lumen, which induces the irritative symptoms and forces the patient to seek medical treatment.

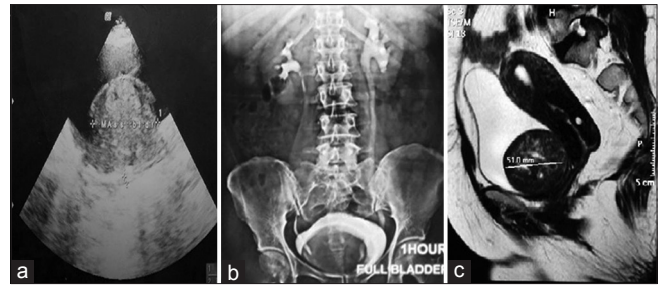


Figure 1: (a) Ultrasonography showing well-circumscribed polypoidal soft tissue lesion projecting in the urinary bladder lumen. (b) Intravenous pyelography demonstrated a large filling defect in the bladder. (c) The bladder mass isointense to the skeletal muscles on T1 and T2 images

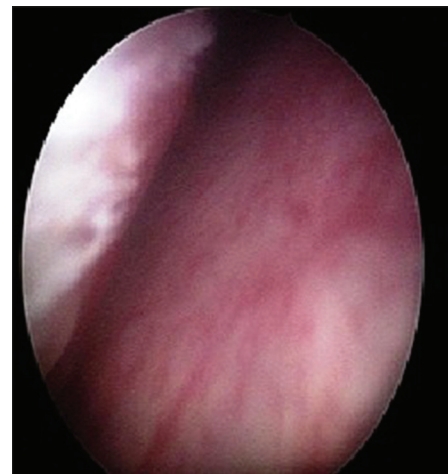


Figure 2: Cystoscopic finding: A large smooth sessile growth arising from the right posterolateral wall of the bladder

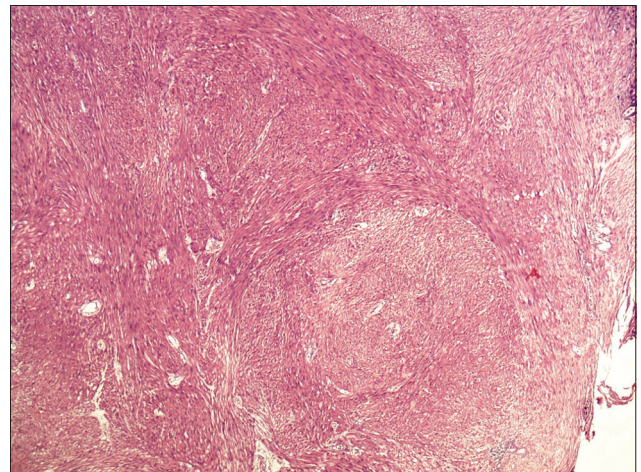


Figure 3: The histopathological examination showed spindle cells in sheets and fascicles forming nodules and oriented in different planes

Leiomyoma is usually presented with obstructive, irritative symptoms, or with hematuria.^[5,6] Goluboff *et al.*, reviewed the English literature and indicated that obstructive symptoms were the most frequent (49%) presenting complaint, whereas

Knoll *et al.*, observed irritative symptoms as the most frequent presentation of bladder leiomyoma.^[5,6]

The radiological imaging such as intravenous urography or cystourethrogram usually reveals a smooth filling defect in the bladder. Abdominal ultrasound may be helpful in differentiating the cystic lesion from a solid one.^[6] The pelvic ultrasound or contrast computed tomography may reveal a submucosal solid mass in the bladder, and it can confirm the origin of the tumor in the bladder wall and its relationship to the uterus and vagina.^[7] The transvaginal ultrasound may be a useful alternative in female patients.^[8] It was once proposed that MRI by itself could confirm this diagnosis, but it cannot differentiate mesenchymal tumors from the more common transitional cell tumors, and the histopathological study is always necessary to confirm the diagnosis.^[9,10] The cystoscopy can distinguish intramural leiomyoma from an endovesical tumor.

The endovesical form usually causes irritative or obstructive symptoms that result in detection as seen in our case.

There are many theories that have been proposed for the causation of this tumor such as a hormonal-related lesion, embryonic rests' tumor, postinflammatory myomatous metaplasia, localized infection, and "wandering" fibroid resembling a parasitic uterine leiomyoma. The female predominance at a reproductive age suggests hormonal influence more than the other possibilities. The differential diagnosis is essential between benign and malignant tumor when the neoplasm is poorly determined or extends beyond the wall of the bladder. The sections of the mass are composed of benign smooth muscle cells in sheets and forming nodules and oriented in different planes. The lack of atypia, nuclear pleomorphism, mitosis, and necrosis rule-out the rare diagnosis of atypical cellular leiomyoma, or leiomyosarcoma.

As most tumors are well-encapsulated, total enucleation by TUR is the treatment of choice.^[11] Silva-Ramos *et al.*,

performed a pooled analysis of leiomyomas. A laparotomy was performed (62.2%), with enucleation (32.2%), partial cystectomy (27.8%), and total cystectomy (2.2%). A TUR was performed (30%), and a transvaginal resection (5.6%). Two patients underwent conservative treatment.^[12] In this case, the treatment was TUR of leiomyoma. The follow-up of the cases published in the literature has shown no evidence of recurrence up to 20 years after surgery or malignant transformation.

CONCLUSION

The bladder leiomyoma is a rare benign lesion, which may occur in the urinary tract with an acceptable cure rate using minimally invasive intervention.

REFERENCES

1. Gómez Vegas A, Silmi Moyano A, Fernández Lucas C, Blázquez Izquierdo J, Delgado Martín JA, Corral Rosillo J, *et al.* Leiomyoma of the lower urinary tract. *Arch Esp Urol* 1991;44:795-8.
2. Chassagne S, Bernier PA, Haab F, Roehrborn CG, Reisch JS, Zimmern PE. Proposed cutoff values to define bladder outlet obstruction in women. *Urology* 1998;51:408-11.
3. McLucas B, Stein JJ. Bladder leiomyoma: A rare cause of pelvic pain. *Am J Obstet Gynecol* 1985;153:896.
4. Roy MK, Joarder RH, Suruzzaman M, Kundu KK, Hossain MA, Alam MM, *et al.* Leiomyoma of the urinary bladder. *Mymensingh Med J* 2005;14:209-11.
5. Goluboff ET, O'Toole K, Sawczuk IS. Leiomyoma of bladder: Report of case and review of literature. *Urology* 1994;43:238-41.
6. Knoll LD, Segura JW, Scheithauer BW. Leiomyoma of the bladder. *J Urol* 1986;136:906-8.
7. Illescas FF, Baker ME, Weinerth JL. Bladder leiomyoma: Advantages of sonography over computed tomography. *Urol Radiol* 1986;8:216-8.
8. Fernández Fernández A, Mayayo Dehesa T. Leiomyoma of the urinary bladder floor: Diagnosis by transvaginal ultrasound. *Urol Int* 1992;48:99-101.
9. Park JW, Jeong BC, Seo SI, Jeon SS, Kwon GY, Lee HM. Leiomyoma of the urinary bladder: A series of nine cases and review of the literature. *Urology* 2010;76:1425-9.
10. Sundaram CP, Rawal A, Saltzman B. Characteristics of bladder leiomyoma as noted on magnetic resonance imaging. *Urology* 1998;52:1142-3.
11. Brande SD, Katz S. Non-epithelial tumors of the ureters and urinary bladder, in *Uropathology*. In: Hill GS, editor. Churchill Livingstone; 1989. p. 861-72.
12. Silva-Ramos M, Massó P, Versos R, Soares J, Pimenta A. Leiomyoma of the bladder. Analysis of a collection of 90 cases. *Actas Urol Esp* 2003;27:581-6.