



Reestablishing Lacrimal Drainage by Canaliculorhinostomy after Dacryocystectomy: A Viable Option in Symptomatic Patients

Shruthi Tara¹, Neha Panickar², Derin Puthur²

¹Department of Orbit and Oculoplasty, Sankara Eye Hospital, Coimbatore, India

²Department of Ophthalmology, Sankara Eye Hospital, Coimbatore, India

Purpose: To evaluate the outcome and efficacy of a modified technique of canaliculo-dacryocystorhinostomy (canaliculo-DCR) in the complete absence of lacrimal sac, as a means to reestablish lacrimal drainage in postdacryocystectomy (post-DCT) patients.

Methods: A retrospective, nonrandomized interventional study including 15 proven and established post-DCT patients with intact canaliculi of at least 7 to 8 mm. The patients presented with bothersome tearing to the oculoplastic clinic from January 2017 to January 2018. Patients were operated by a single surgeon (ST). Procedure involved creating a bony ostium of optimum size, internal membranectomy and the nasal mucosal flap anchored appropriately to create a passage in line with the common canaliculus. Adjunctively bicanalicular intubation and mitomycin-C were used.

Results: Of the 15 patients who were operated (10 female and five male patients), 14 (93.33%) had functionally and anatomically patent lacrimal passage after the modified canaliculo-DCR, one (6.66%) was symptomatically better with partial regurgitation of clear fluid. Three (20%) had tube prolapse after 1st month postoperatively, which although significant, was not related to the technique. They were repositioned as an office procedure and retained thereafter till removal, no other tube related or mitomycin-C related sequelae was seen. No intraoperative complication was encountered.

Conclusions: With a success rate of 93.33% and a resultant patent lacrimal tear drainage passage and trivial complication such as tube prolapse, we can conclude, this technique of modified canaliculo-DCR in post-DCT patients is a safe and effective procedure with promising results, thereby avoiding cumbersome methods and maintenance of Jones tube while at the same time providing symptomatic relief to the patients.

Key Words: Canaliculo-dacryocystorhinostomy, Dacryocystectomy, Epiphora, Lacrimal drainage

Dacryocystectomy (DCT) first described by Woolhouse,

was the procedure of choice in the 18th century for chronic dacryocystitis and lacrimal fistulas until external dacryocystorhinostomy (DCR) was popularized [1]. Although presently it is solely indicated as the surgery of choice for malignant tumors of the lacrimal sac and other relative indications [1], it is still widely practiced for treating chronic dacryocystitis in otherwise uncomplicated scenarios especially in developing countries [2], thus leaving the unde-

Received: September 9, 2021 Final revision: March 9, 2022

Accepted: April 18, 2022

Corresponding Author: Shruthi Tara, MBBS DO. Department of Orbit and Oculoplasty, Sankara Eye Hospital, Sathy Road, Sivanandapuram, Coimbatore 641035, India. Tel: 91-422-2666450, E-mail: shruthitarav@gmail.com

© 2022 The Korean Ophthalmological Society

This is an Open Access journal distributed under the terms of the Creative Commons Attribution Non-Commercial License (<http://creativecommons.org/licenses/by-nc/4.0/>) which permits unrestricted non-commercial use, distribution, and reproduction in any medium, provided the original work is properly cited.

serving patients teary eyed. Epiphora in such patients can be disturbing and discomforting, thereby affecting the quality of life in some patients.

Many surgical techniques have been described to restore lacrimal drainage in common canaliculus (CC) block due to various causes, wherein the lacrimal sac flap was present and hence anchored to the nasal mucosal flap as in conventional DCR after internal membranectomy [3-5]. Microanastomosis of the canaliculus and trephination have been reported in the past with varied outcomes [4,5], wherein the anastomosis was technically challenging. Periosteal fixation was also attempted with mixed success rates and small sample size [6].

In this study, we describe a modified technique of canaliculi-DCR to restore the patency in CC block following DCT with complete absence of the lacrimal sac or its remnants. To the best of our knowledge this procedure has so far not been described earlier.

Materials and Methods

Study design

This is an interventional nonrandomized study including 15 proved and established post-DCT patients operated elsewhere, who presented with bothersome tearing to the Oculoplasty clinic between January 2017 to January 2018. These subjects had undergone DCT in view of chronic dacryocystitis, as a mere prerequisite before getting operated for cataract. While a detailed medical and surgical history was taken, these patients underwent a complete general ocular examination along with thorough lacrimal workup which included meticulous syringing to determine the point of block and nasal endoscopic examination. Furthermore, a Bowman's probe was gently inserted through the intact punctum until soft stop was felt and length of the probe inserted was measured to determine the length of the intact canaliculus prior to the surgery. Intact canaliculus of at least 7 to 8 mm was seen in all the subjects.

The study design adhered to the ethical principles outlined in the Declaration of Helsinki as amended in 2013 and was commenced after the approval of the Institutional Ethical Committee of Sankara Eye Hospital Committee. All patients were operated by a single surgeon (ST) after obtaining a written informed consent from the patients.

Surgical procedure

Patients were operated either under local or monitored anesthesia care. Skin incision was placed based on the old scar to give best possible cosmesis. Scar tissue was negotiated and excised. Incision was made anterior to the anterior lacrimal crest, residual periosteum was retracted, and lacrimal fossa entered. An adequately sized bony ostium was created as per standard guidelines (Fig. 1A) [7]. Complete absence of lacrimal sac was confirmed at this stage, if any sac remnant was found, it was excluded from the study.

Gentle attempt was made to negotiate the Bowman's probe into the CC without undue force through both upper and lower punctum and a sharp dissection was carried out at the block over the tented probe (Fig. 1B). An internal membranectomy was performed using no. 11 blade, and residual fibrosed tissue was excised. Cotton tipped applicator dipped in 0.2 mg/mL of mitomycin-C (MMC) was placed between the newly created canalicular opening and nasal mucosa for 3 minutes to prevent fibrosis [8]. An adequately large sized anterior nasal flap was fashioned, bicanalicular silicone intubation was performed (Fig. 1C) and secured with a single square knot in the nasal cavity. The nasal mucosal flap was then sutured to the tissues above the created CC opening (Fig. 2A), secured by a large

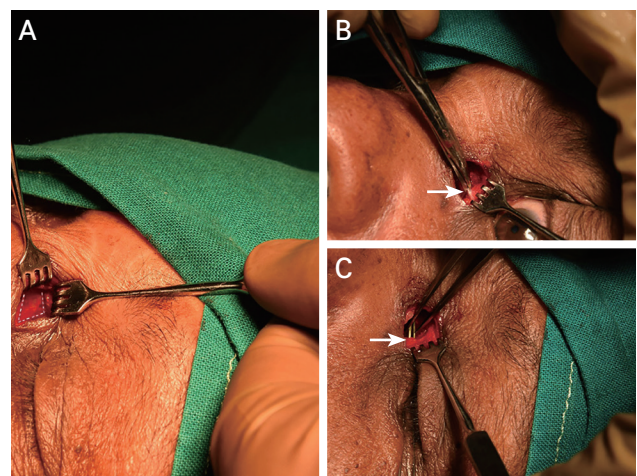


Fig. 1. An adequately sized bony ostium (A) exposing a wide nasal mucosa, (B) showing sharp dissection over the tented and occluded common canaliculus (CC) area (the arrow indicates the tenting of the occluded CC), and (C) showing probes of bicanalicular intubation set, passed without resistance into the created opening at the occluded CC area (arrow). Written informed consent for publication of the research details and clinical images was obtained from the patient.

broad bite of orbicularis fibers above the CC with 6-0 vicryl, care taken not to include the common canaliculus. Three such sutures are placed along the entire breadth of the nasal mucosal flap (Fig. 2B). Skin was meticulously closed with 6-0 monofilament polypropylene suture.

Postoperative period and follow-up

Postoperatively all patients received topical steroids and antibiotic combination which was tapered over a period of 4 weeks. Nasal decongestant drops and topical antibiotic ointment over the surgical wound for 10 days after surgery was prescribed to all the patients. Silicon intubation was left in place for 12 weeks and removed by transcanalicular approach by a gentle rotation of the knot [8]. The patients were followed up for a minimum period of 1 year postsurgery.

Outcome measures

Main outcome measures were anatomical and functional success and complications. Anatomical success was defined as patent lacrimal passage on irrigation by fluoresce-

in-stained saline with visualization of free flow of the dye via nasal endoscope (Fig. 2C). Functional success was defined as resolution of epiphora [8].

Results

A total of 15 patients, all of which were proven and established post-DCT performed elsewhere for primary acquired nasolacrimal duct obstruction (PANDO) were included in the study [9]. The study group involved 10 female (66.67%) and five male patients (33.33%). The only presenting complaint from all patients was bothersome epiphora (100%) which interrupted the normal life style, as described by the patients. Of the 15 patients, 10 (66.67%) were operated under local anesthesia and five (33.33%) were operated under monitored anesthesia care in view of anxiety and low pain threshold. Sedation was considered for extremely apprehensive patients. Intraoperative period was uneventful.

Fourteen patients (93.33%) had functionally and anatomically patent lacrimal passage while one patient (6.66%) was symptomatically better with partial regurgitation of clear fluid from the opposite punctum. This may be attributed to repeated DCT procedures prior to our intervention and significant fibrosis which was noted intraoperatively. Three out of 15 patients (20%) had tube prolapse of significance 1 month postsurgery but, not related to the surgical technique. They underwent tube repositioning as an office procedure and retained them well thereafter till removal at the end of 3 months. No punctual cheese-wiring was noted. The ostia of the 14 patients (93.33%) were large and patent, 1 year after surgery (Fig. 2C) while one patient (6.66%) showed narrow ostium with partial regurgitation from the opposite punctum but, was symptomatically better and denied any further intervention to restore complete anatomical patency. None in our series had any repeat procedures done. None in our series showed any nasal mucosal synechiae or mucosal necrosis due to MMC. Thus, the overall success rate of this modified technique of canaliculo-DCR was noted to be 93.33%.

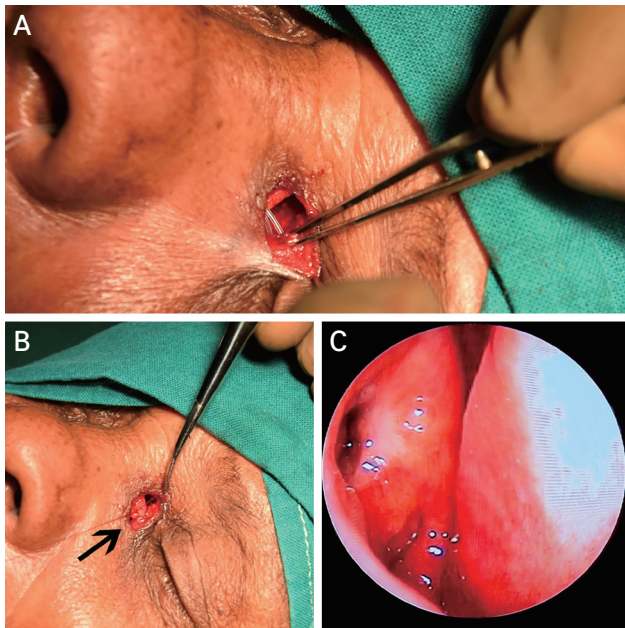


Fig. 2. Surgical steps. (A) The forceps grasping the anchoring site for the nasal mucosa which includes a thick tissue of orbicularis. (B) Image of securing the broad based nasal mucosal flap (arrow). (C) Endoscopic image of large ostium at last follow-up with freely flowing dye. Written informed consent for publication of the research details and clinical images was obtained from the patient.

Discussion

DCT, first described by Woolhouse, is now primarily in-

indicated for the management of lacrimal sac tumors and other relative indications [1]. Despite being largely replaced by DCR in the management of chronic dacryocystitis, DCT continues to be widely practiced in developing countries [2], wherein the primary goal is to eradicate cataract in patients with coexisting dacryocystitis, and is preferred by the general ophthalmologists as an easier alternative to DCR due to lack of experience.

DCT for classical PANDO with no comorbidities is rather unfortunate for a patient who can otherwise be treated by DCR with favorable outcomes, thereby leaving them teary eyed and reducing the quality of life. Epiphora in these patients can be attributed to the secondary distal canalicular block resulting from the fibrosis, requiring further management for those seeking symptomatic relief.

Several surgical techniques have been described to restore patency of lacrimal passage in CC block due to various causes, wherein the lacrimal sac flap was present and hence anchored to the nasal mucosal flap as in conventional DCR after internal membranectomy [3]. An advantage of having a residual sac and hence a predictable success rate post operatively is absent with CC block following a complete DCT. Here, our indication was limited only to patients who underwent successful DCT with no sac remnant whatsoever.

Conjunctivodacryocystorhinostomy with placement of Jones tube created a conduit for direct drainage of tears from the conjunctiva to the nasal cavity, even in the absence of lacrimal sac [4,10-14]. Although it promised anatomical patency and reestablished lacrimal tear drainage, it required lifelong maintenance of repositioning or replacement of the tube [4], which could be eliminated in select cases with absent lacrimal sac like in our series.

Doucet and Hurwitz [15] in 1982 described canaliculo-DCR as an alternative to Jones tube for failed lacrimal surgery, of which a few of their patients had no sac remnant. In these cases, direct anastomosis between the CC and nasal mucosa was facilitated by creating anterior and posterior canalicular and nasal flaps whereas, in our study the nasal mucosal flap was directly anchored in line with the CC opening without the creation of canalicular flaps.

In another procedure discussed by Lee et al. [4], microsurgical anastomosis of the CC to the nasal mucosa was done in patients with canalicular obstruction in the absence of lacrimal sac. A success rate of 87.5% was reported with an almost similar sample size of 14. However, a clear men-

tion of how the anastomosis was created is lacking and it was said to be a technically challenging procedure [4].

Our study described a modified technique of canaliculo-DCR as a useful alternative in such cases. It involved creation of an adequately sized ostium followed by internal membranectomy and anchoring of the large nasal mucosal flap to the soft tissue, including a generous bite of the orbicularis muscle overlying the CC with adjunctive use of MMC and bicanicular intubation. Intraoperative MMC application is found to be effective in increasing the success rate of DCR surgery by inhibiting scarring and cicatrix formation through wound modulation, with no significant complications resulting from its use [16]. Bicanicular intubation is considered useful in high-risk cases to ensure patency [17], and was considered in this study in view of the past surgical history.

An overall success rate of 93.33% in reestablishing the lacrimal tear drainage and a trivial complication such as tube prolapse which although significant (20%) and not related to the surgical technique, was reported. This was easily repositioned as an office procedure. One out of 15 patients (6.66%) was symptomatically better with partial regurgitation of clear fluid; this probably was due to multiple sac procedures prior to our intervention and presence of significant fibrosis, which was noted intraoperatively. Furthermore, there were no other complications both intraoperatively and postoperatively, and no adverse effects of the adjuncts used. Despite good results, the possible limitations of this study include the small sample size, the lack of long-term follow-up and the contributing effect of MMC and silicon intubation which remains ambiguous. Also, it is indicated only in patients with an intact canaliculus of at least 7 mm length.

With an adequate follow-up period of 1 year within which the osteotomy reaches its final size [8], we can conclude that this technique of modified canaliculo-DCR in post-DCT patients is a safe and effective procedure with promising results. It avoids the use of Jones tube and its lifelong maintenance that follows, while improving the quality of life in patients with persistent epiphora. This simple yet effective surgical alternative thereby proves that unrelenting tearing due to CC block post-DCT is not the end of the road. However, there is scope for larger case series for definitive conclusion on the same.

Conflicts of Interest: None.

Acknowledgements: None.

Funding: None.

References

1. Ali MJ. Dacryocystectomy: goals, indications, techniques and complications. *Ophthalmic Plast Reconstr Surg* 2014; 30:512-6.
2. Nair AG, Kamal S, Agarwal A. Indian survey on practice patterns of lacrimal & eyelid disorders (iSUPPLE): report 3: cataract and nasolacrimal duct obstruction. *Saudi J Ophthalmol* 2017;31:145-9.
3. Grover AK, Gupta AK, Rastogi A. Modified canaliculo-dacryocystorhinostomy. *Indian J Ophthalmol* 1991;39:159-61.
4. Lee JH, Young SM, Kim YD, et al. Canaliculorhinostomy: indications and surgical results. *Am J Ophthalmol* 2017;181: 134-9.
5. Sisler HA, Allarakhia L. New minitrephine makes lacrimal canalicular rehabilitation an office procedure. *Ophthalmic Plast Reconstr Surg* 1990;6:203-6.
6. Saxena RC. Anastomotic surgery after the operation of dacryocystectomy. *Indian J Ophthalmol* 1975;23:16-9.
7. Ali MJ, Naik MN, Honavar SG. External dacryocystorhinostomy: tips and tricks. *Oman J Ophthalmol* 2012;5:191-5.
8. Kamal S, Ali MJ, Naik MN. Circumostial injection of mitomycin C (COS-MMC) in external and endoscopic dacryocystorhinostomy: efficacy, safety profile, and outcomes. *Ophthalmic Plast Reconstr Surg* 2014;30:187-90.
9. Pornpanich K, Luemsamran P, Leelaporn A, et al. Microbiology of primary acquired nasolacrimal duct obstruction: simple epiphora, acute dacryocystitis, and chronic dacryocystitis. *Clin Ophthalmol* 2016;10:337-42.
10. Liarakos VS, Boboridis KG, Mavrikakis E, Mavrikakis I. Management of canalicular obstructions. *Curr Opin Ophthalmol* 2009;20:395-400.
11. Jones LT. Conjunctivodacryocystorhinostomy. *Am J Ophthalmol* 1965;59:773-83.
12. Lim C, Martin P, Bengler R, et al. Lacrimal canalicular bypass surgery with the Lester Jones tube. *Am J Ophthalmol* 2004;137:101-8.
13. Rose GE, Welham RA. Jones' lacrimal canalicular bypass tubes: twenty-five years' experience. *Eye (Lond)* 1991;5(Pt 1): 13-9.
14. Steele EA. Conjunctivodacryocystorhinostomy with Jones tube: a history and update. *Curr Opin Ophthalmol* 2016;27: 439-42.
15. Doucet TW, Hurwitz JJ. Canaliculodacryocystorhinostomy in the management of unsuccessful lacrimal surgery. *Arch Ophthalmol* 1982;100:619-21.
16. Liao SL, Kao SC, Tseng JH, et al. Results of intraoperative mitomycin C application in dacryocystorhinostomy. *Br J Ophthalmol* 2000;84:903-6.
17. Hwang SW, Khwarg SI, Kim JH, et al. Bicanalicular double silicone intubation in external dacryocystorhinostomy and canaliculoplasty for distal canalicular obstruction. *Acta Ophthalmol* 2009;87:438-42.