



# Clinical Signs of Base of Skull Fracture in the South Indian Population

Harsh Jain<sup>1</sup> Shambhavi Ranjan<sup>1</sup> Krishnamurthy Ganesh<sup>1</sup>

<sup>1</sup>Department of Neurosurgery, Sri Ramachandra Institute of Higher Education and Research, Chennai, Tamil Nadu, India

Address for correspondence Harsh Jain, MBBS, Sri Ramachandra Institute of Higher Education and Research, Chennai 600116, Tamil Nadu, India (e-mail: harshjain@outlook.com).

Asian J Neurosurg 2024;19:484–489.

## Abstract

**Objective** The clinical signs of base of skull fracture (BSF) are often ambiguous and difficult to identify, but are often used to make decisions on early medical interventions. This study aimed to assess the prevalence of the clinical signs of BSF, their dependency to diagnose this injury and to assess the correlation between the presence of these clinical signs and the severity of head injury and patient outcome.

**Materials and Methods** A cross-sectional study was conducted in a tertiary care hospital in South India over a period of 3 years (2020–2023). Patients older than 18 years, with radiological or surgical evidence of BSF were monitored for developing the clinical signs including Battle's signs, raccoon's sign, otorrhea, and rhinorrhea. The presence of these clinical signs was correlated with demographical characteristics, patient presentation, complications, and their outcome.

**Results** A total of 292 patients were included in the study. The mean age of the cohort was  $36.27 \pm 18.68$  years. A total of 55 (18.8%) showed at least one of the four signs of BSF. Raccoon's sign was seen in 9.5% cases, Battle's sign in 5.5%, otorrhea in 5.5%, and rhinorrhea in 2.4% cases. Patients with frontal ( $p = 0.021$ ) or ethmoid (0.049) fractures and ENT bleeding ( $p = 0.022$ ) were significantly more likely to present with at least one sign of BSF. The patients who presented with clinical signs were more likely to have a complication during the course of the hospital stay ( $p = 0.024$ ) than those without clinical signs, including cranial nerve palsy ( $p < 0.001$ ) and cerebrospinal fluid leak ( $p < 0.001$ ). The outcome of the patient did not change based on the presence of clinical signs ( $p = 0.926$ ).

**Conclusion** These study results indicate a limited diagnostic value of BSF clinical signs in the South Indian population. Thus, other modalities should be considered for the diagnosis when suspected. These results also discourage the use of the nasal route in all patients with suspected head injury and emphasize that during the nasal aspiration procedure, the use of a rigid device is fundamental to avoid false passage of the aspiration tube from the nasal to the intracranial region.

## Keywords

- ▶ raccoon
- ▶ battle
- ▶ BSF
- ▶ fracture
- ▶ clinical signs
- ▶ base of skull

article published online  
June 10, 2024

DOI <https://doi.org/10.1055/s-0044-1787778>.  
ISSN 2248-9614.

© 2024. Asian Congress of Neurological Surgeons. All rights reserved.

This is an open access article published by Thieme under the terms of the Creative Commons Attribution-NonDerivative-NonCommercial-License, permitting copying and reproduction so long as the original work is given appropriate credit. Contents may not be used for commercial purposes, or adapted, remixed, transformed or built upon. (<https://creativecommons.org/licenses/by-nc-nd/4.0/>)

Thieme Medical and Scientific Publishers Pvt. Ltd., A-12, 2nd Floor, Sector 2, Noida-201301 UP, India

## Introduction

A base of skull fracture (BSF) is a break in continuity of one or more of the temporal, occipital, sphenoid, frontal, and ethmoid bones of the skull. Most BSFs, ~70%, are caused by high-velocity blunt trauma such as motor vehicle collisions, motorcycle crashes, pedestrian injuries, falls, and assaults.<sup>1</sup> It is estimated that nearly 1.5 to 2 million people are injured and 1 million succumb to death every year in India. Road traffic injuries are the leading cause (60%) of traumatic brain injuries followed by falls (20–25%) and violence (10%).<sup>2</sup>

As the bones at the base of the skull are very fragile and located close to the dura mater, meningeal lesions and liquor fistulas are frequent consequences of this type of fracture. Other possible complications include cranial nerve palsies, cerebrovascular lesions, and orbital and intracranial lesions.<sup>3,4</sup>

Previous studies indicate that BSF can be recognized based on clinical features which vary depending on the degree of the associated brain and cranial nerve injury. Patients may present with altered mental status, nausea, and vomiting.<sup>5,6</sup> They may cause bruising behind the ears (Battle's sign), bruising around the eyes (raccoon eyes), or bleeding behind the ear drum (hemotympanum). Oculomotor deficits due to injuries to cranial nerves III, IV, and VI may be present. Patients may also present with facial droop due to compression or injury to cranial nerve VII. Hearing loss or tinnitus suggests damage to cranial nerve VIII.<sup>7</sup>

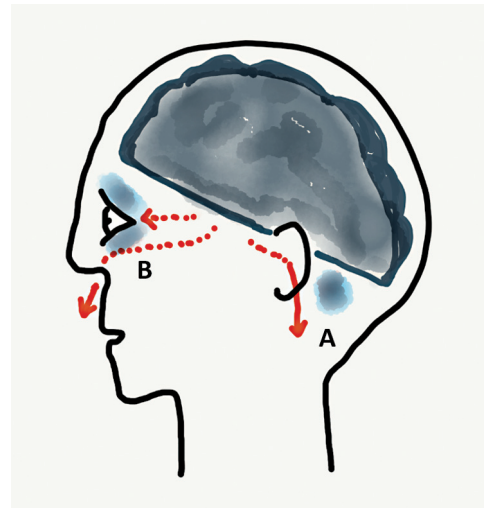
Advanced trauma care manuals emphasize the presence of these BSF signs as parameters for decisions about possible treatment strategies.<sup>8</sup> However, the signs do not always manifest early. In addition, the specificity of these signs is questionable, as their presence does not always confirm BSF and the absence of these clinical findings does not exclude this lesion. This discrepancy and the great emphasis of clinical practice recommendations on the relationship among the presence of clinical signs, diagnosis of BSF, and interventions in the initial care of trauma patients gave rise to concerns that resulted in the current research study.<sup>5</sup>

BSFs can be managed conservatively or may require surgery depending on the severity of the injury. Patients with BSFs require admission for observation. Those with intracranial hemorrhage require emergent neurosurgical evaluation. Otherwise, skull base fractures are often managed expectantly.<sup>1,9</sup> Surgical management is necessary for cases complicated by intracranial bleeding requiring decompression, vascular injury, significant cranial nerve injury, or persistent cerebrospinal fluid (CSF) leak.

This study aims to assess the performance of the clinical signs of BSF for diagnosis of this injury and to verify the correlation between the presence of these clinical signs and the severity of head injury and patient outcome.

## Materials and Methods

This was an observational cross-sectional study which included patients who presented to our hospital with a BSF over a 3-year period between 2020 and 2023. Head-injured patients were observed for clinical signs of BSF. The sample population



**Fig. 1** Mechanism of Battle's sign (A) and raccoon's sign (B). (Image courtesy: Wikipedia.)

included all patients, aged 18 years or older, with blunt head injury who were treated at the hospital within 24 hours after the head injury. Patients without radiological or surgical evidence of BSF, who died or who were discharged in less than 24 hours posttrauma were excluded from the study. The clinical signs of BSF considered in the study were raccoon's sign, Battle's sign, otorrhea (CSF leak from ear), and rhinorrhea (CSF leak from nose), as described in the Abbreviated Injury Scale (AIS) 2005, Update 2015. The AIS is used to describe the injuries resulting from a trauma and to determine their severity. BSF is diagnosed by direct visualization by a neurosurgeon during surgery or via computed tomography of the skull (tomographic sections <5 mm) (→ Fig. 1).

The presence of fracture lines in the bones of the orbit, ethmoid, sphenoid, and base of processes of the occipital bone and the temporal bone was considered positive results.<sup>1,4,9</sup> Head injury severity was estimated using the Glasgow coma scale (GCS) score, calculated during the neurosurgeon's first evaluation (mild: GCS score = 13–15; moderate: GCS score = 9–12; severe: GCS score = 3–8). The researchers and assistants were previously trained to examine the patients and fill out the research data registration tool. All patients included in the study were monitored from the admission to the emergency department until the detection of clinical signs of BSF or discharge. We calculated the prevalence of the clinical signs of BSF and further studied its distribution with relation to the bone fractured, associated intracranial bleed, and GCS at presentation. We obtained approval for the study from the institution's research ethics committee. The participants or legal caregivers, if the patient was unable to express himself/herself, signed the free and informed consent form.

Descriptive statistics were reported to compare patients with and without clinical signs of BSF. Mean and standard deviations were reported for continuous variables and frequencies for categorical variables. Comparison of means and proportions between groups were done using two-tailed "t" test, chi-square test, or Fisher's exact test as appropriate. An  $\alpha$

**Table 1** Demographic characteristics and presentation of the study population

Characteristics	Total, N = 292	With clinical signs, N = 55 (18.8%)	Without clinical signs	p-Value
Age (y), mean ± SD	36.27 ± 18.68	35.64 ± 19.03	36.42 ± 18.64	0.779
Sex, male, n (%)	233 (79.8%)	45 (81.8%)	188 (80.7%)	0.678
GCS, mean	12.37 ± 3.44	12.65 ± 3.47	12.31 ± 3.43	0.504
Presenting symptoms, n (%)				
Seizures	13 (4.4%)	4 (7.3%)	9 (3.8%)	0.260
Vomiting	123 (42.1%)	20 (36.4%)	103 (43.5%)	0.337
Headache	33 (11.3%)	5 (15.2%)	28 (11.8%)	0.565
Loss of consciousness	211 (72.3%)	41 (74.5%)	170 (71.7%)	0.674
Altered sensorium	94 (32.2%)	25 (45.5%)	69 (29.2%)	0.021
Bleeding through ear and nose	156 (53.4%)	37 (67.3%)	119 (50.2%)	0.022
Severity of brain injury				
Severe	43 (14.7%)	8 (14.5%)	35 (14.8%)	0.508
Moderate	87 (29.8%)	13 (23.6%)	74 (31.2%)	
Minor	162 (55.5%)	34 (61.8%)	128 (54.0%)	

Abbreviations: GCS, Glasgow coma scale; SD, standard deviation.

value <0.05 was considered statistically significant. All analyses were performed using SPSS.

## Results

A total of 292 patients admitted to the neurosurgical intensive care unit were included in the study after obtaining informed consent. The mean age of the cohort was 36.27 ± 18.68 years; most patients were male, 233 (79.8%). Road traffic accidents (43.5%) were the most common source of injury, followed by patients with a fall (40.7%). A total of 55 (18.8%) showed at least one of the four signs of BSF.

The characteristics of the study population, along with the presenting symptoms are summarized in ►Table 1. There was no significant difference in age, sex, GCS, and symptoms at presentation (all  $p > 0.05$ ) between those with and those without clinical signs of BSF except patients with bleeding

through the ear or nose ( $p = 0.022$ ) were more likely to present with at least one of the clinical signs. Mild head injury was the most frequent injury (51.0%), followed by moderate head injury (29.1%) according to the GCS, as summarized in ►Table 1. It did not vary between the two groups ( $p = 0.508$ ).

The prevalence of clinical signs under study, raccoon's sign, Battle's sign, otorrhea, rhinorrhea, and cranial nerve palsies is summarized in ►Table 2. Fifty-five patients (18.8%) presented at least one of four investigated signs of BSF, with maximum presenting with raccoon's sign (9.5%). Cranial nerve palsy was a common presenting sign, with a prevalence of 15.8%, with the facial nerve being most affected.

►Table 3 summarizes the skull base bone fractured in the 292 patients. Patients with frontal ( $p = 0.021$ ) or ethmoid ( $p = 0.049$ ) fractures were significantly more likely to present with at least one of the four clinical signs of BSF. Among the associated intracranial bleeds, contusion was the most prevalent, followed by subarachnoid hemorrhage. None of the intracranial bleeds was associated with the presence of clinical signs of BSF (all  $p > 0.05$ ).

The correlation between severity of brain injury, based on GCS at presentation and the presence of clinical signs of BSF was studied. Severity of brain injury was classified as mild (GCS > 12), moderate (GCS > 8 but < 13), and severe (GCS < 8). There was no significant correlation between the severity of brain injury and presence of clinical signs of BSF with a  $p$ -value of 0.508. The results are summarized in ►Table 1.

Patients with clinical signs of BSF were significantly more likely to develop a complication in the hospital course ( $p = 0.024$ ) than those without clinical signs. Cranial nerve palsy ( $p < 0.001$ ) and CSF leak ( $p < 0.001$ ) were particularly common complications. The results are summarized in ►Table 4.

The correlation between the presence of clinical signs of BSF and the patient outcome, based on Glasgow outcome score (GOS) was studied (►Table 5). The two were not found

**Table 2** Prevalence of clinical signs and cranial nerve palsy

Clinical sign	Prevalence, N (%)
Raccoon's sign	28 (9.5%)
Battle's sign	9 (3.1%)
Otorrhea	16 (5.5%)
Rhinorrhea	7 (2.4%)
Total	55 (18.8%)
Cranial nerve palsy	46 (15.8%)
VII	31 (67.4%)
III	12 (26.1%)
IX	1 (2.2%)
VI	2 (4.4%)

**Table 3** Distribution of the skull base bone fractured and associated intracranial bleeds

Characteristic	Total, N = 292	With clinical signs, N = 55 (18.8%)	Without clinical signs	p-Value
Occipital fracture	50 (17.1%)	5 (9.1%)	40 (19.0%)	0.079
Temporal fracture	193 (66.1%)	37 (67.3%)	156 (65.8%)	0.838
Frontal fracture	62 (21.2%)	18 (32.7%)	44 (18.6%)	0.021
Sphenoid fracture	30 (10.3%)	8 (14.5%)	22 (9.3%)	0.247
Ethmoid fracture	6 (2.1%)	3 (5.5%)	3 (1.3%)	0.049
Subarachnoid hemorrhage	83 (28.4%)	15 (27.3%)	68 (28.7%)	0.833
Subdural hematoma	94 (32.2%)	19 (34.5%)	75 (31.6%)	0.678
Intracerebral hemorrhage	17 (5.8%)	3 (5.5%)	14 (5.9%)	0.897
Extradural hemorrhage	65 (22.3%)	16 (24.6%)	49 (20.7%)	0.176
Contusion	99 (33.9%)	21 (38.2%)	78 (32.9%)	0.457

**Table 4** Prevalence of complication developed by the patients during the course of hospital stay

Complication	Total, N = 292	With clinical signs, N = 55 (18.8%)	Without clinical signs	p-Value
Any complication	120 (41.1%)	30 (54.5%)	90 (38.0%)	0.024
Intubation	57 (19.5%)	9 (16.4%)	48 (20.3%)	0.512
Ventilator	54 (18.5%)	8 (16.4%)	45 (19.0%)	0.652
Tracheostomy	30 (10.3%)	46 (83.6%)	216 (91.1%)	0.099
Meningitis	1 (0.3%)	1 (1.8%)	0 (0.0%)	0.038
Cranial nerve palsy	43 (14.7%)	16 (29.1%)	27 (11.4%)	<0.001
Hearing loss	6 (2.1%)	2 (3.6%)	4 (1.7%)	0.359
Cavernous sinus thrombosis	1 (0.3%)	0 (0.0)	1 (0.4%)	0.629
Vertigo	11 (3.8%)	1 (1.8%)	10 (4.2%)	0.399
Higher mental function deficit	12 (4.1%)	1 (0.3%)	11 (4.6%)	0.342
Motor deficits	39 (13.4%)	9 (16.4)	30 (12.7%)	0.467
Sensory deficits	3 (1.0%)	1 (1.8%)	2 (0.8%)	0.519
CSF leak	25 (8.6%)	22 (40%)	3 (1.3%)	<0.001

Abbreviation: CSF, cerebrospinal fluid.

**Table 5** Outcome of patients based on Glasgow outcome score

Glasgow outcome score	Total, N = 292	With clinical signs, N = 55 (18.8%)	Without clinical signs	p-Value
1	2 (0.7%)	0 (0.0%)	2 (0.8%)	0.926
2	8 (2.7%)	2 (3.6%)	6 (2.5%)	
3	33 (11.3%)	7 (12.7%)	26 (11.0%)	
4	45 (15.4%)	9 (16.4%)	36 (15.2%)	
5	204 (69.9%)	37 (67.3%)	167 (70.5%)	

to have a correlation which was statistically significant with a *p*-value of 0.926.

## Discussion

A total of 292 patients with BSF were included in this cross sectional study with a preponderance of male patients (79.8%) in the fourth decade of life ( $36.3 \pm 18.7$  years).

Clinical signs of BSF, including Battle's sign (5.5%), raccoon's sign (9.5%), otorrhea (5.5%), and rhinorrhea (2.4%) were seen in 18.8% of the patients in our study, which is very low when compared with the existing data.<sup>3,4</sup> Previous studies show that the clinical signs of BSF typically manifest within 48 hours posttrauma, which is similar to our observations in the current study.<sup>6,10</sup> In those studies, the prevalence of Battle's and raccoon's sign is as high as 92.8% patients with

BSF which is in stark contrast to our findings,<sup>3</sup> though the prevalence of CSF leak (otorrhea and rhinorrhea), in our study, is similar to the reported values in the previous studies.<sup>11</sup> This may be explained to some extent by the patient pool and geographic location of the study. This study was conducted in the southern part of India, which is known to have a relatively darker skin color as it lies close to the tropics, making it hard to identify color changes (raccoon's sign and Battle's sign) over the skin. This finding is further supported by the fact that the prevalence of CSF leak (otorrhea and rhinorrhea) in our study is similar to the other studies in diverse regions of the world.

In our study, temporal bone (66.1%) was the most commonly fractured bone and had the maximum prevalence of clinical signs (67.3%). Patients with frontal ( $p=0.021$ ) or ethmoid (0.049) fractures were significantly more likely to present with at least one of the four clinical signs of BSF. Those with ear or nose bleeding ( $p=0.022$ ) were more likely to present with at least one of the clinical signs.

Further, we observed cranial nerve palsies were seen in 15.8% of the cases with the most common affected nerve being the facial nerve (67.4%), in contrast to the literature, which states olfactory nerve as the most commonly affected.<sup>7,12</sup> This can possibly be due to the high prevalence of temporal bone fracture (66.1%) in our study and its close proximity to the facial nerve anatomically.

In the current study, 21% patients with mild head injury presented with clinical signs, while they were observed in only 18.6% of patients with severe head injury. Analysis did not reveal a significant ( $p=0.508$ ) correlation between the severity of head injury and the clinical signs. This is in contrast to the existing data, which show a positive correlation between the two.<sup>3</sup>

The patients who presented with clinical signs were more likely to have a complication during the course of the hospital stay ( $p=0.024$ ) than those without clinical signs. Cranial nerve palsy ( $p<0.001$ ) and CSF leak ( $p<0.001$ ) were particularly common complications. Based on the GOS, the outcome of the patient did not change based on the presence of clinical signs ( $p=0.926$ ).

Existing data also indicate that patients with clinical signs of BSF usually have significant impact on the skull and therefore have a high probability of intracranial injuries.<sup>6</sup> As seen in our study, 219 (75.0%) patients had associated intracranial injuries with BSF, with contusions (33.9%) being the most prevalent. The presence of these intracranial bleeds was not significantly associated with the presence of clinical signs under study.

Although the clinical signs are not ideal clinical markers of BSF, their presence does correlate with the base of skull bone fractured and complications that the patient may develop, and therefore should be closely monitored. Our analysis of the indicators showed that they are of little clinical relevance in the initial evaluation, as prevalence of the BSF signs is very low in the South Indian population. Early diagnosis of BSF is vital as initial care due to the risk of false passage when using the nasal route to perform procedures at a time when the result of the computed

tomography is not yet available.<sup>13,14</sup> This study concluded that the limited visualization of BSF signs in the South Indian population limit the value of BSF signs in the initial care of trauma patients. In addition to this observation, 237 (81.2%) displayed no signs of BSF during the course of their hospital stay. The absence of signs did not indicate a low possibility of this lesion. Therefore, even without evidence of BSF, health care workers should pay attention to head-injured patients and consider them as probable cases of BSF until the outcome of computed tomography excludes the possibility of this lesion.

The present study has several limitations; first, the sample size is known to have a significant influence on the results. Although our case load is significantly larger than most available studies, larger studies, primarily in the Southeast Asia region, are required to assess the dependability of the clinical signs of BSF. Second, different settings contribute to a different case mix, different quality of care and policies which can lead to bias and alter the results. Finally, we only observed the patients for the clinical signs during their stay in the hospital. Although a vast majority develop clinical signs within 48 hours postinjury, some may develop it later, which we may have missed due to the lack of follow-up postdischarge.

Our study strongly supports that the presence of clinical signs increases the likelihood of BSF and is a good marker for severity of head injury and intracranial injuries, but in the South Indian population, they cannot be relied upon to clinically diagnose BSF. Thus, these signs should be considered as independent markers of head injury severity and not necessarily be used to diagnose BSF clinically, especially in the South Indian population.

## Conclusion

These study results indicate a limited diagnostic value of BSF clinical signs in the South Indian population. Thus, other modalities such as radiological scans should be considered for the diagnosis when suspected. Further, patients with ENT bleed following head trauma are more likely to have clinical signs and such patients are eventually prone to developing complications. These results also discourage the use of the nasal route in all patients with suspected head injury and emphasize that during the nasal aspiration procedure, the use of a rigid device is fundamental to avoid false passage of the aspiration tube from the nasal to the intracranial region, which is possible in patients presenting BSF in the South Indian population.

### Funding

None.

### Conflict of Interest

None declared.

## References

- 1 Bagnon KL, Hudgins PA. Skull base fractures and their complications. *Neuroimaging Clin N Am* 2014;24(03):439–465, vii–viii

- 2 Rutland-Brown W, Langlois JA, Thomas KE, Xi YL. Incidence of traumatic brain injury in the United States, 2003. *J Head Trauma Rehabil* 2006;21(06):544–548
- 3 Solai CA, Domingues CA, Nogueira LS, de Sousa RMC. Clinical signs of basilar skull fracture and their predictive value in diagnosis of this injury. *J Trauma Nurs* 2018;25(05):301–306
- 4 Simon LV, Newton EJ. Basilar skull fractures. In: *StatPearls*. Treasure Island (FL): StatPearls Publishing; 2023
- 5 Galvagno SM Jr, Nahmias JT, Young DA. Advanced Trauma Life Support® Update 2019: management and applications for adults and special populations. *Anesthesiol Clin* 2019;37(01):13–32
- 6 Pretto Flores L, De Almeida CS, Casulari LA. Positive predictive values of selected clinical signs associated with skull base fractures. *J Neurosurg Sci* 2000;44(02):77–82, discussion 82–83
- 7 Naidu B, Vivek V, Visvanathan K, Shekhar R, Ram S, Ganesh K. A study of clinical presentation and management of base of skull fractures in our tertiary care centre. *Interdiscip Neurosurg* 2021; 23:100906
- 8 Association for the Advancement of Automotive Medicine (AAAM) The Abbreviated Injury Scale (AIS): 2005, Update 2015. Illinois, PA: Des Plaines; 2015
- 9 Archer JB, Sun H, Bonney PA, et al. Extensive traumatic anterior skull base fractures with cerebrospinal fluid leak: classification and repair techniques using combined vascularized tissue flaps. *J Neurosurg* 2016;124(03):647–656
- 10 Ferreras J, Junquera LM, García-Consuegra L. Intracranial placement of a nasogastric tube after severe craniofacial trauma. *Oral Surg Oral Med Oral Pathol Oral Radiol Endod* 2000;90(05): 564–566
- 11 Wright W, Rigamonti D. Nervous system trauma. In: Irani DN, ed. *Cerebrospinal Fluid in Clinical Practice*. Philadelphia: WB Saunders; 2009:249–256
- 12 Kim SH, Kim SW. Sixth and twelfth cranial nerve palsies following basal skull fracture involving clivus and occipital condyle. *J Korean Neurosurg Soc* 2012;51(05):305–307
- 13 Gianelli Castiglione A, Bruzzone E, Burrello C, Pisani R, Ventura F, Canale M. Intracranial insertion of a nasogastric tube in a case of homicidal head trauma. *Am J Forensic Med Pathol* 1998;19(04): 329–334
- 14 Potapov AA, Gavrilov AG, Kravchuk AD, et al. Basilar skull fractures: clinical and prognostic aspects [in Russian]. *Zh Vopr Neurokhir Im N N Burdenko* 2004;(03):17–23; discussion 23–24