

Multiple spontaneous hemorrhages after commencing warfarin therapy

SAGE Open Medical Case Reports
Volume 6: 1–4
© The Author(s) 2018
Reprints and permissions:
sagepub.co.uk/journalsPermissions.nav
DOI: 10.1177/2050313X18778380
journals.sagepub.com/home/sco



Nobuhiro Akuzawa¹  and Masahiko Kurabayashi²

Abstract

A 94-year-old Japanese woman with renal dysfunction was admitted to our hospital for congestive heart failure caused by atrial fibrillation with rapid ventricular response. Considering the risk of stroke, warfarin was commenced. However, she developed shock following brachial and retroperitoneal hemorrhage 4 days after starting warfarin despite not being over-anticoagulated. She recovered after receiving blood transfusion and intravenous vitamin K2. Bleeding during warfarin administration occurs more frequently in older individuals with lower glomerular filtration rates, especially within the first 30 days of warfarin treatment. Physicians should therefore check for unexpected bleeding after commencing warfarin and be prepared to reverse anticoagulation.

Keywords

Glomerular filtration rate, retroperitoneal hemorrhage, reversal of anticoagulation, warfarin

Date received: 13 December 2017; accepted: 30 April 2018

Introduction

Warfarin, an oral vitamin K antagonist, is used for primary and secondary prevention of atrial and venous thromboembolism resulting from prosthetic heart valves, atrial fibrillation (AF), and venous thromboembolism.^{1,2} However, warfarin users require routine coagulation monitoring because of its narrow therapeutic range and interactions between warfarin and diet or other medications. Bleeding associated with over-anticoagulation can occur in patients taking warfarin, the annual frequency of this complication reportedly being 15%–20%, including 1%–3% of fatal bleeding events.² Direct oral anticoagulants (DOACs), including dabigatran, rivaroxaban, apixaban, and edoxaban, have advantages such as monitoring-free therapy and few medicine–medicine or dietary interactions; however, they still carry a risk of bleeding.^{1,3} In addition, because the kidneys excrete DOACs to some extent, drug accumulation leading to over-anticoagulation can occur, especially in patients with decreased renal function.⁴ Accordingly, warfarin is still the standard option for oral anticoagulant therapy.

We herein present the rare phenomenon of a patient developing shock as a result of spontaneous bleeding within the right biceps brachii muscle and retroperitoneal region 4 days after starting oral warfarin despite her international ratio of

prothrombin time (PT-INR) being 2.22. The patient recovered with red blood cell transfusion and intravenous vitamin K administration and was discharged from our hospital 5 weeks after hemorrhage with no residual consequences.

Case presentation

A 94-year-old Japanese woman was admitted to our hospital because of dyspnea for the previous 2 days. She had no relevant history except for hypertension and non-valvular AF, for which she had been prescribed candesartan and bisoprolol for the past 5 years. She was a non-smoker and non-drinker and was independent regarding activities of daily living. Two days before admission, she had spontaneously

¹Department of General Medicine, National Hospital Organization Shibukawa Medical Center, Shibukawa, Japan

²Department of Medicine and Biological Science, Graduate School of Medicine, Gunma University, Maebashi, Japan

Corresponding Author:

Nobuhiro Akuzawa, Department of General Medicine, National Hospital Organization Shibukawa Medical Center, 383 Shiroy, Shibukawa 377-0280, Gunma, Japan.

Email: akuzawa_nobuhiro@yahoo.co.jp



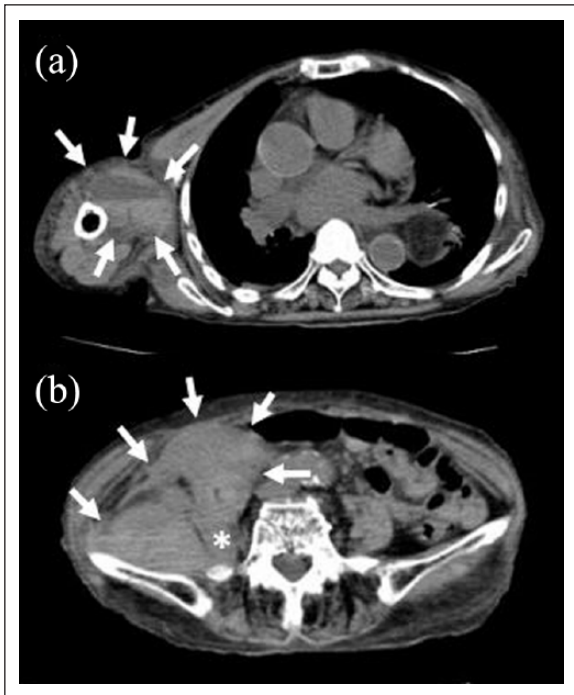


Figure 1. Plain computed tomography (CT) images of the right biceps brachii and abdomen on Day 12. (a) An intramuscular hematoma containing fluid–fluid levels (surrounded by white arrows) is visible in the right biceps brachii. The patient’s right arm was pulled down to obtain these images because severe pain prevented her from lifting it. (b) A massive hematoma (surrounded by white arrows) is visible in the retroperitoneal space at the height of the aortic bifurcation and adjacent to the ileum and right iliopsoas muscle (asterisk).

developed exertional dyspnea that had subsequently worsened, leading to admission to our hospital.

On admission, her blood pressure 102/70 mmHg. Her heart rate was 120 bpm and irregular. She was short of breath on room air, with blood O₂ saturation of 92% and partial O₂ pressure of 61.0 torr. Physical examination showed coarse crackles over the lungs bilaterally and pretibial edema. A chest radiograph showed bilateral pulmonary congestion and an electrocardiogram AF with rapid ventricular response. Laboratory tests showed a low hemoglobin (Hb) concentration of 116 g/L (normal: 116–148 g/L), estimated glomerular filtration rate (eGFR) of 24.1 mL/min/1.73 m², high blood urea nitrogen concentration of 9.39 mg/dL (normal: 2.86–7.14 mmol/L), creatinine (Cr) concentration of 137.0 μmol/L (normal: 40.7–69.8 μmol/L), and plasma brain natriuretic peptide concentration of 366.2 pg/mL (normal: <18.4 pg/mL), all of these finding being abnormal. Transthoracic echocardiography showed diffuse hypokinesis of the left ventricle with a calculated left ventricular ejection fraction of 40%. Oxygen therapy, continuous intravenous infusion including low-dose dopamine, carperitide, unfractionated heparin, and intravenous injection of furosemide were begun. Oral verapamil, torsemide, and spironolactone were added

to her medications. Her general status improved after hospitalization; unfractionated heparin was discontinued on Day 5 because of nasal bleeding. Other intravascular medication and oxygen therapy were ceased on Day 7. Her CHA₂DS₂-VASc (Congestive Heart Failure, Hypertension, Age ≥75 years, Diabetes, Stroke/Transient Ischemic Attack, Vascular disease, Age 65–74 years, Sex) score was 4; thus, thromboprophylaxis was reconsidered.⁵ After obtaining her consent, oral warfarin (2 mg/day) was introduced on Day 8. The PT-INR and activated partial prothrombin time (APTT) on Day 8 were 1.02 and 30.2 s, respectively.

On Day 12, her PT-INR was 2.22 and she had no bruises; nevertheless, her blood pressure suddenly decreased to 70/50 mmHg, after which she developed painful swelling of the right upper arm, right hip pain, cold sweats, and tachycardia (120 bpm). After intravenous infusion of 1 L of Ringer’s solution, her blood pressure increased to 90/60 mmHg. However, her Hb concentration had dropped to 80 g/L, and plain whole-body computed tomography (CT) revealed a hematoma in the right biceps brachii (Figure 1(a)) and retroperitoneal hematoma adjacent to the right iliopsoas muscle and ileum (Figure 1(b)). Warfarin was discontinued. Angiography was not performed because of the risk of renal failure due to contrast medium. She initially refused infusion of any blood products for religious reasons, but subsequently consented to transfusion of two units of packed red blood cells. Dopamine (10 μg/kg/min) and 20 mg of vitamin K₂ (Vit-K₂) were also administered intravenously, after which her blood pressure increased to 120/70 mmHg. Her blood Hb concentration and PT-INR 6 h after Vit-K₂ administration were 86 g/L and 1.48, respectively, and another two units of packed red blood cells were transfused. On Day 13, her PT-INR had normalized, Hb had increased to 94 g/L, and follow-up CT showed no enlargement of the hematomas. Her serum Cr concentration had increased to 352.7 μmol/L by Day 16, but the hematomas had become much smaller on CT and her serum Cr (131.7 μmol/L) had improved by Day 23. She was discharged from our hospital on Day 28. One month after discharge, her Hb concentration had recovered to 117 g/L. A platelet aggregation test using collagen, adenosine diphosphate and epinephrine for screening for hemorrhagic diathesis, PT, APTT, and serum fibrinogen were all normal. During 6 months of outpatient follow-up without anticoagulation, no remarkable events occurred. She was lost to follow-up thereafter.

Discussion

Scores for CHADS₂ (Congestive Heart Failure, Hypertension, Age, Diabetes, Stroke/Transient Ischemic Attack) and its updated version, CHA₂DS₂-VASc, are used to predict the risk of stroke in patients with non-valvular AF and determine whether anticoagulation therapy is indicated.⁵ The 2016 European Society of Cardiology (ESC) guidelines for management of AF recommend using CHA₂S₂-VASc scores to

estimate stroke risk in patients with AF and state that anticoagulant therapy is indicated in patients with CHA₂DS₂-VASc scores of 1 or more for men and 2 or more for women.⁶ However, when deciding about thromboprophylaxis, the risk of stroke needs to be weighed against that of major bleeding. Accordingly, some bleeding risk scores have been advocated. In particular, HAS-BLED (*Hypertension, Abnormal Renal/Liver Function, Stroke, Bleeding History, Labile International Normalized Ratio, Elderly (>65 years), Drugs/Alcohol Concomitancy*) scores highlight risk factors that can be managed to reduce the bleeding risk, have good predictive value, and correlate with intracerebral hemorrhage.⁵ It has been reported that HAS-BLED scores of 1 or 2 are associated with an annual hemorrhage risk of 2%–4%, whereas scores of more than 3 indicate a high annual risk of hemorrhage (>4%).^{7,8} In the present case, the CHA₂DS₂-VASc and HAS-BLED scores were 3 and 2, respectively, and met the criteria for introducing anticoagulant therapy and indicated intermediate risk of hemorrhage. Thus, anticoagulation therapy was indicated; nevertheless, our patient developed multiple hemorrhages soon after starting warfarin despite not being over-anticoagulated. High bleeding risk scores are not always associated with over-anticoagulation.⁸ A recent study has reported that major bleeding is likely to occur during the first 30 days of warfarin treatment, especially in older patients with low eGFR rates.⁹ Interestingly, the increase in major bleeding rates is reportedly largely attributable to gastrointestinal bleeding, intracranial bleeding rates not being affected by renal function in that study. These findings conflict with those of another study that showed an increased risk of stroke, probably due to a transient hypercoagulable state, during the first 30 days of warfarin treatment.¹⁰ In any case, physicians should be aware that older individuals with renal dysfunction have an increased risk of bleeding soon after starting warfarin. DOACs may be substituted for warfarin in patients with mild or moderate renal dysfunction (eGFR = 15–60 mL/min) because they may be associated with lower incidences of stroke, systemic embolism, and major bleeding events than warfarin.¹¹ Benefits of DOACs in patients with end-stage kidney disease (ESKD, eGFR <15 mL/min) are still unclear; however, the Food and Drug Administration (FDA) has approved use of rivaroxaban and apixaban in patients on hemodialysis.¹² Therefore, warfarin is still the oral anticoagulant of choice in patients with ESKD despite its higher bleeding risk. Interestingly, a recent study investigating effects of warfarin on patients with AF aged ≥65 years with chronic kidney disease (CKD, eGFR <50 mL) and AF has reported that both vitamin K antagonists and DOACs increase risk of ischemic stroke and hemorrhage,¹³ suggesting that new criteria for anticoagulation therapy in older patients with AF and CKD are required. When warfarin-associated bleeding occurs, (1) three-factor prothrombin complex concentrate (PCC; factors II, IX, and X), (2) four-factor PCC (II, VII, IX, and X), (3) recombinant factor VIIa, (4) factor VIII inhibitor-bypassing agents, or (v) fresh frozen

plasma can be used to reverse the anticoagulation. Intravenous administration of vitamin K is also effective but takes 4–6 h to normalize PT-INR. Of these, four-factor PCC reverses anticoagulation the most rapidly.²

That the risk of bleeding increases with increasing CHADS₂ or CHA₂DS₂-VASc scores in patients with AF taking warfarin is a major and paradoxical problem.¹ Age and hypertension are included in both CHADS₂/CHA₂DS₂-VASc and HAS-BLED scores. A study based on a large Danish population registry suggested a net clinical benefit for all patients receiving warfarin therapy regardless of their CHADS₂ and HAS-BLED scores;¹⁴ however, recent studies have found an annual risk of major bleeding during warfarin therapy of 4.5%–5.0%.^{15,16} The risk of bleeding in these studies is higher than previously reported (1%–3%)² and cannot be overlooked. In addition, HAS-BLED scores may not accurately determine the risk of bleeding in patients who have not taken vitamin K antagonists because HAS-BLED score includes the item “Labile International Normalized Ratio.”⁷ Frailty may also increase the risk of major or life-threatening bleeding while taking warfarin;¹⁷ however, HAS-BLED scores do not include frailty. How frailty increases risk of bleeding during warfarin therapy is unclear; however, recent studies have reported a significant positive relationship between regular physical activity (RPA) and warfarin dose requirement and that RPA reduces risk of major hemorrhage by 38%.^{18,19} Exercise induces a significant increase in CYP2C9 activity in the liver microsomes of rats;²⁰ thus, pharmacokinetic changes induced by exercise may decrease bleeding risk during warfarin therapy. Frailty is an important factor in bleeding during warfarin therapy in older individuals. A recent study has reported a 70% prevalence of anticoagulation therapy among Canadian octogenarians with AF,²¹ suggesting high rates of anticoagulation treatment of older patients with AF in Western countries. Therefore, the importance of evaluating risk of bleeding before anticoagulation therapy is increasing.

Limitations of our case report include our failure to investigate lesions that may have caused hemorrhage by contrast-enhanced CT and a lack of data for all clotting factors. However, our findings should alert physicians to the potential risk of bleeding during anticoagulation therapy in older individuals.

In conclusion, we here present a rare case of retroperitoneal and right biceps brachii hemorrhage 4 days after starting warfarin without the patient being over-anticoagulated. This patient’s blood clotted normally after administration of intravenous vitamin K. It should be noted that severe bleeding can occur in the absence of over-anticoagulation in older individuals taking warfarin and that this risk is higher in patients with low eGFR.

Acknowledgements

We thank Dr Trish Reynolds, MBBS, FRACP, from Edanz Group (www.edanzediting.com/ac) for editing a draft of this manuscript.

Declaration of conflicting interests

The author(s) declared no potential conflicts of interest with respect to the research, authorship, and/or publication of this article.

Ethical approval

Our institution does not require ethical approval for reporting individual cases or case series.

Funding

The author(s) received no financial support for the research, authorship, and/or publication of this article.

Informed consent

Written informed consent was obtained from the patient(s) for their anonymized information to be published in this article.

ORCID iD

Nobuhiro Akuzawa  <https://orcid.org/0000-0002-1204-1294>

References

- Eikelboom J and Merli G. Bleeding with direct oral anticoagulants vs warfarin: clinical experience. *Am J Med* 2016; 34: 3–8.
- Zareh M, Davis A and Henderson S. Reversal of warfarin-induced hemorrhage in the emergency department. *West J Emerg Med* 2011; 12: 386–392.
- Yao X, Abraham NS, Sangaralingham LR, et al. Effectiveness and safety of dabigatran, rivaroxaban, and apixaban versus warfarin in nonvalvular atrial fibrillation. *J Am Heart Assoc* 2016; 5: e003725.
- Hughes S, Szeki I, Nash MJ, et al. Anticoagulation in chronic kidney disease patients—the practical aspects. *Clin Kidney J* 2014; 7: 442–449.
- Camm AJ, Lip GY, De Caterina R, et al. 2012 focused update of the ESC guidelines for the management of atrial fibrillation: an update of the 2010 ESC guidelines for the management of atrial fibrillation. Developed with the special contribution of the European Heart Rhythm Association. *Eur Heart J* 2012; 33: 2719–2747.
- Kirchhof P, Benussi S, Kotecha D, et al. 2016 ESC guidelines for the management of atrial fibrillation developed in collaboration with EACTS. *Eur Heart J* 2016; 37: 2893–2962.
- Pisters R, Lane DA, Nieuwlaat R, et al. A novel user-friendly score (HAS-BLED) to assess 1-year risk of major bleeding in patients with atrial fibrillation: the Euro heart survey. *Chest* 2010; 138: 1093–1100.
- Lip GY, Frison L, Halperin JL, et al. Comparative validation of a novel risk score for predicting bleeding risk in anticoagulated patients with atrial fibrillation: the HAS-BLED (hypertension, abnormal renal/liver function, stroke, bleeding history or predisposition, labile INR, elderly, drugs/alcohol concomitantly) score. *J Am Coll Cardiol* 2011; 57: 173–180.
- Jun M, James MT, Manns BJ, et al. The association between kidney function and major bleeding in older adults with atrial fibrillation starting warfarin treatment: population based observational study. *BMJ* 2015; 350: h246.
- Azoulay L, Dell’Aniello S, Simon TA, et al. Initiation of warfarin in patients with atrial fibrillation: early effects on ischaemic strokes. *Eur Heart J* 2014; 35: 1881–1887.
- Kimachi M, Furukawa TA, Kimachi K, et al. Direct oral anticoagulants versus warfarin for preventing stroke and systemic embolic events among atrial fibrillation patients with chronic kidney disease. *Cochrane Database Syst Rev* 2017; 11: CD011373.
- Fanikos J, Burnett AE, Mahan CE, et al. Renal function considerations for stroke prevention in atrial fibrillation. *Am J Med* 2017; 130: 1015–1023.
- Kumar S, de Lusignan S, McGovern A, et al. Ischaemic stroke, haemorrhage, and mortality in older patients with chronic kidney disease newly started on anticoagulation for atrial fibrillation: a population based study from UK primary care. *BMJ* 2018; 360: k342.
- Olesen JB, Lip GY, Lindhardsen J, et al. Risks of thromboembolism and bleeding with thromboprophylaxis in patients with atrial fibrillation: a net clinical benefit analysis using a “real world” nationwide cohort study. *Thromb Haemost* 2011; 106: 739–749.
- Barnes GD, Gu X, Haymart B, et al. The predictive ability of the CHADS2 and CHA2DS2-VASc scores for bleeding risk in atrial fibrillation: the MAQI(2) experience. *Thromb Res* 2014; 134: 294–299.
- Forslund T, Wettermark B, Wändell P, et al. Risks for stroke and bleeding with warfarin or aspirin treatment in patients with atrial fibrillation at different CHA2DS2VASc scores: experience from the Stockholm region. *Eur J Clin Pharmacol* 2014; 70: 1477–1485.
- Steffel J, Giugliano RP, Braunwald E, et al. Edoxaban versus warfarin in atrial fibrillation patients at risk of falling: ENGAGE AF-TIMI 48 Analysis. *J Am Coll Cardiol* 2016; 68: 1169–1178.
- Rouleau-Mailloux E, Shahabi P, Dumas S, et al. Impact of regular physical activity on weekly warfarin dose requirement. *J Thromb Thrombolysis* 2016; 41: 328–335.
- Shendre A, Beasley TM, Brown TM, et al. Influence of regular physical activity on warfarin dose and risk of hemorrhagic complications. *Pharmacotherapy* 2014; 34: 545–554.
- Chien KJ, Horng CT, Chao HR, et al. The influence of running exercise training on pharmacokinetics of meloxicam in rats. *Life Sci J* 2013; 10: 951–955.
- Lefebvre MC, St-Onge M, Glazer-Cavanagh M, et al. The effect of bleeding risk and frailty status on anticoagulation patterns in octogenarians with atrial fibrillation: the FRAIL-AF study. *Can J Cardiol* 2016; 32: 169–176.