

Transcatheter reduction in size of large undesirable fenestrations following extracardiac conduit Fontan surgery with off-label use of Occlutech atrial flow regulator

Bhushan Shivaji Sonawane, Kothandam Sivakumar

Department of Pediatric Cardiology, Madras Medical Mission, Chennai, Tamil Nadu, India

ABSTRACT

Fontan surgery streamlines the systemic venous return through the pulmonary circulation before filling the systemic ventricle in univentricular hearts. The venous congestion leads to effusions, lowers cardiac output, and affects organ perfusion. Fenestrations in the Fontan circuit improve forward flow through the ventricles, lower venous pressures, and reduce perioperative morbidity. When large fenestrations cause profound hypoxia and effort intolerance, there are no current techniques to reduce their size. Atrial flow regulators with a predetermined orifice were used off-label in three borderline patients with large undesirable fenestrations following extracardiac conduit Fontan surgeries. This resulted in improved oxygenation without marked elevation of venous pressures, while retaining the patency of the decompressive fenestration.

Keywords: Cardiac output, hypoxia, right-to-left shunt, univentricular heart, venous congestion

INTRODUCTION

Fontan surgery palliates patients with complex congenital heart diseases with functional single ventricle. This surgery creates a critical bottleneck with obligatory upstream congestion and downstream decreased flow, leading to reduced preload to the ventricle.^[1] Fenestration in the Fontan conduit provides a right-to-left shunt, improves ventricular preload, and reduces early postoperative morbidity at the cost of systemic hypoxia. An ideally titrated fenestration maintains a tolerable systemic venous pressure, without causing significant effort limiting hypoxia.^[2] Patients with patent fenestrations have preserved preload reserve, reduced afterload, lower heart rates, and stable hemodynamics.^[3] A relatively large fenestration will significantly reduce the pulmonary flows and is undesirable. If a large fenestration is made during the initial surgery, there are no reliable interventional techniques to reduce the size of the

fenestration. In patients with borderline hemodynamics, complete closure of fenestration will lead to systemic venous congestion. Atrial flow regulator (AFR, Occlutech International, Helsingborg, Sweden) is a novel device that creates a fenestration in the atrial septum of a predefined diameter to relieve right atrial hypertension in pulmonary hypertension and left atrial hypertension in diastolic heart failure.^[4,5] Three patients with large Fontan fenestrations underwent reduction using 4-mm regulator devices as an off-label indication, resulting in the reduction of the shunt through the fenestration, but still maintaining its patency.

Patient 1

A 14-year-old male, diagnosed as mitral and aortic atresia, hypoplastic left heart syndrome, underwent neonatal Stage I Norwood procedure, followed by

Access this article online	
Quick Response Code: 	Website: www.annalspc.com
	DOI: 10.4103/apc.APC_52_20

This is an open access journal, and articles are distributed under the terms of the Creative Commons Attribution-NonCommercial-ShareAlike 4.0 License, which allows others to remix, tweak, and build upon the work non-commercially, as long as appropriate credit is given and the new creations are licensed under the identical terms.

For reprints contact: reprints@medknow.com

How to cite this article: Sonawane BS, Sivakumar K. Transcatheter reduction in size of large undesirable fenestrations following extracardiac conduit Fontan surgery with off-label use of Occlutech atrial flow regulator. *Ann Pediatr Card* 2020;13:260-3.

Address for correspondence: Dr. Kothandam Sivakumar, Department of Pediatric Cardiology, Madras Medical Mission, 4A Dr. J J Nagar, Mogappair, Chennai - 600 037, Tamil Nadu, India. E-mail: drkumarsiva@hotmail.com

Submitted: 29-Mar-2020

Revised: 07-May-2020

Accepted: 16-May-2020

Published: 29-Jun-2020

bidirectional Glenn shunt at 5 months of age. The next palliation was stenting of narrowed left pulmonary artery (LPA) in the vice between the dilated neo-ascending aorta and descending aorta. He underwent Norwood Stage III-fenestrated extracardiac conduit Fontan surgery and tricuspid valve ring annuloplasty at 4 years. He had Class II dyspnea and hypoxia after minimal exertion. His medications included warfarin, frusemide, spironolactone, carvedilol, and lisinopril. Oxygen saturations dropped below 70% on minimal exertion. There was no significant cardiomegaly on X-ray chest. The Fontan fenestration shunted vigorously from conduit to the right atrium, with a mean gradient of 6 mmHg across the fenestration. The repaired tricuspid valve showed a mean gradient of 8 mmHg. A compliant balloon interrogation of the fenestration demonstrated the waist diameter with insignificant increase in Fontan pressures [Table 1]. The 7.5-mm fenestration was reduced with a 4-mm AFR, resulting in improved oxygen saturations [Figure 1]. Follow-up evaluation at 10 months revealed patent fenestration and improved effort tolerance.

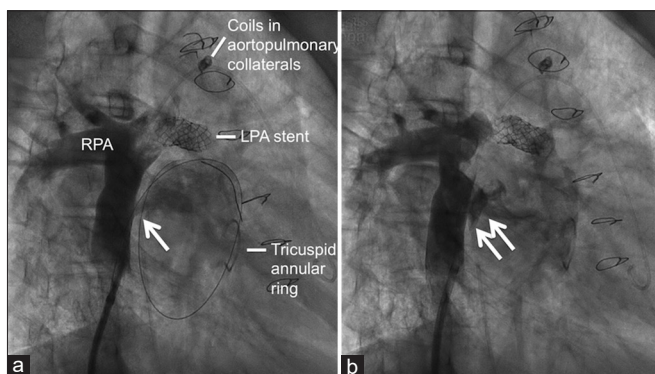


Figure 1: Conduit angiogram in the right anterior oblique view (a) showing fenestration in Fontan circuit and a guidewire placed through this fenestration (single arrow). Previously deployed coils in aortopulmonary collaterals, left pulmonary artery stent, and surgical tricuspid annuloplasty ring are seen. The fenestration was restricted (b) with atrial flow regulator device (double arrow). RPA: Right pulmonary artery

Patient 2

A 15-year-old male with single ventricle and pulmonary atresia had ductal stenting in infancy, coil closure of a hypertensive noncommunicating aortopulmonary collateral to the left lower lobe from descending thoracic aorta, bidirectional Glenn shunt at 2 years of age, device closure of decompressing levoatriocardial vein at 5 years along with the deployment of additional coils in aortopulmonary collateral to obliterate residual flows, and finally fenestrated extracardiac conduit Fontan surgery at 9 years. He presented with progressive exercise intolerance and hypoxia. Following balloon interrogation, the 9-mm fenestration was reduced with 4-mm AFR, resulting in improved oxygen saturations [Table 1]. At 36-month follow-up, AFR was patent with improved symptoms and oxygen saturation of 92%, while receiving bosentan, sildenafil, warfarin, frusemide, spironolactone, and lisinopril [Figure 2].

Patient 3

A 15-year-old male with Fallot’s tetralogy, pulmonary atresia, hypoplastic pulmonary arteries, and borderline hypoplastic left ventricle received bidirectional Glenn shunt with pulmonary artery pericardial augmentation in infancy, followed by fenestrated extracardiac Fontan

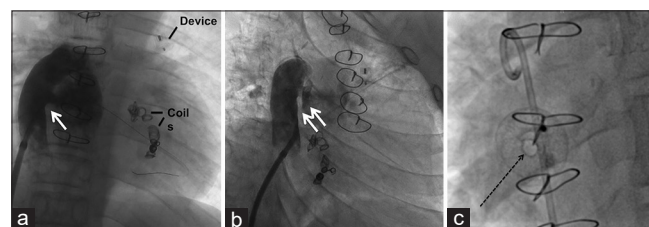


Figure 2: A large fenestration (single arrow) leads to the right-to-left shunt from an extracardiac conduit Fontan circuit (a) shown by a conduit angiogram in the anteroposterior view. Previously placed devices in the levoatriocardial vein and coils in aortopulmonary collaterals are seen. Following the reduction of fenestration with atrial flow regulator device (double arrow), conduit angiogram (b) demonstrates reduced right-to-left shunt. A magnified enface view (c) compares the lumen of the orifice of atrial flow regulator (dotted arrow) with a 5 Fr pigtail placed within the conduit

Table 1: Patient details, hemodynamics, and follow-up

Years of Fontan	Diagnosis	Age (years)	Wt (kg)	PCV (%)	SpO ₂ (%)	Fontan pressures (mmHg)	Atrial pressure (mmHg)	Balloon waist (mm)	Postballoon pressure increase (mmHg)	Post- AFR (mmHg)	Years after Fontan (years)	Post- AFR NYHA class	Post- AFR SpO ₂ (%)	Follow- up after AFR (months)
2008	HLHS Post LPA stent, TV repair	14	34 kg	46.1	72	16	9	7.5	1	16	11	II	92	10
2013	Single V, PA, MAPCA	13	37 kg	46.9	78	13	4	9	3	14	4	II	92	36
2009	TOF PA LV hypoplasia	15	40 kg	64.7	79	13	9	8	3	15	10	II	90	9

Wt: Weight at the time of catheterization, PCV: Packed cell volume, SpO₂: Pulse oximeter saturation, AFR: Atrial flow regulator, NYHA: New York Heart Association, HLHS: Hypoplastic left heart syndrome, LPA: Left pulmonary artery, TV: Tricuspid valve, Single V: Single ventricle, PA: Pulmonary atresia, MAPCA: Major aortopulmonary collateral arteries, TOF: Tetralogy of Fallot, LV: Left ventricle, AFR: Atrial flow regulator

procedure at 6 years. Evaluation of severe hypoxia done 1 year after surgery showed severely stenosed LPA, which was stented with 6-mm Hippocampus stent (Medtronic, Minneapolis, MN, USA) at another center. He worsened in effort tolerance and hypoxia with oxygen saturation of 79%. The outgrown LPA stent showed a gradient of 3 mmHg from the central Fontan pressures of 15 mmHg. The stent was serially dilated with larger ultra-high-pressure balloons to a final diameter of 14 mm, which abolished the gradient, but oxygenation remained at 80% [Figure 3]. Following a balloon interrogation of the fenestration, it was reduced from 8 mm with a 4-mm AFR, resulting in improved oxygen saturations [Table 1]. At a 9-month follow-up, his effort tolerance and oxygenation had improved, and he was receiving frusemide, spironolactone, warfarin, and sildenafil.

DISCUSSION

The creation of a fenestration lowers Fontan pathway pressure, improves cardiac output, maintains oxygen delivery, and increases survival at the cost of hypoxia.^[2,6] Closure of Fontan fenestration typically improves oxygen saturations both at rest and during exercise, resulting in improved exercise ability but at the cost of elevated Fontan pressure, which may have detrimental effects in the long term.^[7] A small fenestration is hence desirable, especially in patients with suboptimal preoperative hemodynamics.

AFR provides an alternative to atrial septostomy by creating a controlled atrial septal fenestration in patients with severe pulmonary hypertension.^[5] In this indication,

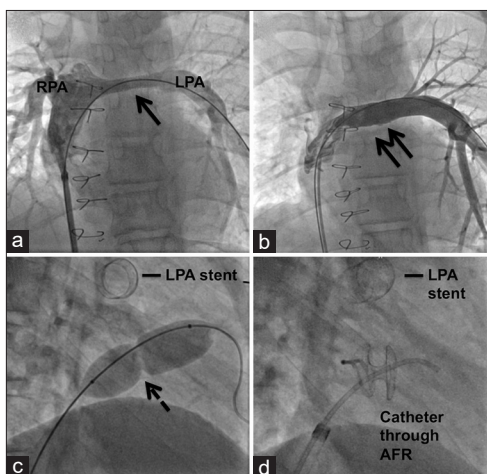


Figure 3: Conduit angiogram in the anteroposterior view (a) showing a small outgrown stent (single arrow) in the left pulmonary artery and a good-sized right pulmonary artery. Following serial dilatation of the stent (double arrow) to 14 mm (b), there is improved filling of the left lung. Balloon interrogation of the fenestration (c) showing waist (dotted arrow), which was reduced (d) by atrial flow regulator device

AFR improves cardiac index and systemic oxygen transport with minimal hypoxia.^[4] Its advantage lies in providing a predetermined orifice diameter from 4 to 10 mm. Its patency is maintained on simple antiplatelet medications, even though oral anticoagulation is often indicated in patients with Fontan fenestrations, to prevent paradoxical embolism from the chronically congested systemic veins.^[8] When fenestrated pericardial baffles are used in lateral tunnel Fontan surgery, reduction of fenestration size using an AFR is similar to its use in a native atrial septum or pericardial atrial septal patch.^[9]

Small AFR fenestrations do not maintain long-term patency in idiopathic pulmonary hypertension due to lack of a sustained pressure difference between the atria as well as not adopting routine oral anticoagulation.^[4] The persistent pressure gradient across the fenestration along with monitored anticoagulation could explain the patency in our patients. Documentation of their patency was primarily guided by an echocardiogram that is sensitive to detect the high-velocity flows and pulse oximetry that detects persistent hypoxia.

In our patients with extracardiac conduit Fontan circulation, reduction of large fenestration by AFR increased pulmonary flow and oxygen saturation with acceptable Fontan pressures, while maintaining the decompressive effect of a fenestration. The patency was retained at a follow-up ranging from 9 to 36 months with steady maintenance of oxygen saturation and function class. This report is the first in the literature to use AFR in predictably reducing fenestration orifice in extracardiac conduits made of polytetrafluoroethylene. The existing literature on transcatheter modification of Fontan fenestrations is limited to complete closure of fenestrations or creation of new fenestrations using stents or devices.^[7,10]

Fenestration in Fontan surgery is a trade-off between high venous pressures and hypoxia. Hypoxia is a reflector of the size of fenestration as well as high pulmonary artery pressures. Optimal medical treatment with pulmonary vasodilators and diuretics along with beta-blockers and afterload reducing agents should continue to remain the mainstay in the management of these patients.

CONCLUSION

Off-label use of AFR in patients with large Fontan fenestrations and hypoxia reduced the size of the fenestration and improved oxygenation. The device retained patency with routine oral anticoagulation in the mid-term follow-up; however, this needs documentation on long-term follow-up too. Patients who are unlikely to tolerate a complete closure of Fontan fenestration due to suboptimal hemodynamics are likely to benefit more with its use by controlling the orifice diameter.

Declaration of patient consent

The authors certify that they have obtained all appropriate patient consent forms. In the form the patient(s) has/have given his/her/their consent for his/her/their images and other clinical information to be reported in the journal. The patients understand that their names and initials will not be published and due efforts will be made to conceal their identity, but anonymity cannot be guaranteed.

Financial support and sponsorship

Nil.

Conflicts of interest

There are no conflicts of interest.

REFERENCES

- Gewillig M, Brown SC. The Fontan circulation after 45 years: Update in physiology. *Heart* 2016;102:1081-6.
- Bridges ND, Castenada AR. The fenestrated Fontan procedure. *Herz* 1992;17:242-5.
- Saiki H, Kuwata S, Iwamoto Y, Ishido H, Taketazu M, Masutani S, *et al.* Fenestration in the Fontan circulation as a strategy for chronic cardioprotection. *Heart* 2019;105:1266-72.
- Rajeshkumar R, Pavithran S, Sivakumar K, Vettukattil JJ. Atrial septostomy with a predefined diameter using a novel Occlutech atrial flow regulator improves symptoms and cardiac index in patients with severe pulmonary arterial hypertension. *Catheter Cardiovasc Interv* 2017;90:1145-53.
- Patel MB, Samuel BP, Girgis RE, Parlmer MA, Vettukattil JJ. Implantable atrial flow regulator for severe, irreversible pulmonary arterial hypertension. *EuroIntervention* 2015;11:706-9.
- Mavroudis C, Zales VR, Backer CL, Muster AJ, Latson LA. Fenestrated Fontan with delayed catheter closure. Effects of volume loading and baffle fenestration on cardiac index and oxygen delivery. *Circulation* 1992;86:II85-92.
- Pihkala J, Yazaki S, Mehta R, Lee KJ, Chaturvedi R, McCrindle BW, *et al.* Feasibility and clinical impact of transcatheter closure of interatrial communications after a fenestrated Fontan procedure: Medium-term outcomes. *Catheter Cardiovasc Interv* 2007;69:1007-14.
- Seipelt RG, Franke A, Vazquez-Jimenez JF, Hanrath P, von Bernuth G, Messmer BJ, *et al.* Thromboembolic complications after Fontan procedures: Comparison of different therapeutic approaches. *Ann Thorac Surg* 2002;74:556-62.
- Manuri L, Calaciura RE, De Zorzi A, Oreto L, Raponi M, Lehner A, *et al.* Atrial flow regulator for failing Fontan circulation: An initial European experience. *Interact Cardiovasc Thorac Surg* 2018;27:761-4.
- Lehner A, Schulze-Neick I, Haas NA. Creation of a defined and stable Fontan fenestration with the new Occlutech Atrial Flow Regulator (AFR®). *Cardiol Young* 2018;28:1062-6.