

Received: 2017.05.23
Accepted: 2017.08.29
Published: 2018.01.15

e-ISSN 1941-5923
© Am J Case Rep, 2018; 19: 52-56
DOI: 10.12659/AJCR.905452

Bullosis Diabeticorum: A Rare Presentation with Immunoglobulin G (IgG) Deposition Related Vasculopathy. Case Report and Focused Review

Authors' Contribution:
Study Design A
Data Collection B
Statistical Analysis C
Data Interpretation D
Manuscript Preparation E
Literature Search F
Funds Collection G

ABDEF 1 **Hardik Sonani**
EF 2 **Sohail Abdul Salim**
E 3 **Vishnu V. Garla**
E 4 **Anna Wile**
E 1 **Venkataraman Palabindala**

1 Department of Medicine, University of Mississippi Medical Center, Jackson, MS, U.S.A.
2 Department of Nephrology, University of Mississippi Medical Center, Jackson, MS, U.S.A.
3 Department of Endocrinology, University of Mississippi Medical Center, Jackson, MS, U.S.A.
4 Department of Dermatology, University of Mississippi Medical Center, Jackson, MS, U.S.A.

Corresponding Author: Hardik Sonani, e-mail: sonanihardik25@gmail.com
Conflict of interest: None declared

Patient: Male, 42
Final Diagnosis: Bullosis diabeticorum
Symptoms: Skin rash
Medication: —
Clinical Procedure: Debridement
Specialty: Metabolic Disorders and Diabetics

Objective: Rare co-existence of disease or pathology


Background: Bullosis diabeticorum (BD) is a condition characterized by recurrent, spontaneous, and non-inflammatory blistering in patients with poorly controlled diabetes mellitus. While etiopathogenesis remains unclear, roles of neuropathy, vasculopathy and UV light are hypothesized. Most literature reports negative direct and indirect immunofluorescence findings in diabetics with bullous eruptions. Porphyria cutanea tarda, bullous pemphigoid, epidermolysis bullosa, and pseudoporphyria are other differential diagnoses of bullous lesions, and they must be excluded.

Case Report: We present a 42-year-old African American male with long standing poorly controlled insulin dependent diabetes mellitus with blisters on his left hand and feet. The blisters were noticed three weeks prior to presentation and, thereafter, rapidly increased in size and spontaneously ruptured. Physical examination revealed a multitude of both roofed and unroofed bullous painless skin lesions. Hematoxylin and eosin (H&E) staining dramatized the dermal-epidermal blistering and re-epithelization process. Direct Immunofluorescence (DIF) was positive for 2 + IgG deposition in the already thickened basement membrane of the capillaries of the superficial vascular plexus. After debridement, his wounds greatly improved with over three months of aggressive wound care.

Conclusions: Primary immunologic abnormality likely plays no role in the onset of BD. To date, only one article has reported nonspecific capillary-associated immunoglobulin M and C3. This is the first case of BD with IgG deposition in the superficial capillary basement membrane. Positive findings on DIF suggest vasculopathy. Dermal microangiopathy, secondary to immunologic abnormality, is a possible underlying pathogenesis to bullae formation. Punch biopsy with DIF can be an additional diagnostic modality in the management of such cases.

MeSH Keywords: Blister • Diabetes Complications • Diabetic Angiopathies • Fluorescent Antibody Technique, Direct • Vasculitis

Full-text PDF: <https://www.amjcaserep.com/abstract/index/idArt/905452>

 1598

 1

 2

 19



Background

Bullous diabeticorum (BD) is a condition characterized by recurrent, spontaneous, and non-inflammatory blistering on patients with poorly controlled diabetes mellitus. Cases occur rapidly and are especially common in distal distributions. Bullous lesions in diabetic patients were first reported by Kramer in 1930 [1]. Cantwell and Martz further described BD in 1967 [2]. Bullous disease of diabetes occurs in about 0.5% of diabetics in the United States. BD has a male-to-female ratio of 2: 1 and an age range of 17 to 84 years [3]. One Indian study showed BD's prominence in 2% of the Indian diabetic population [4].

The exact etiology is unknown, but it is thought to be multifactorial [5]. The role of neuropathy, nephropathy, vasculopathy, and UV (ultraviolet) light are hypothesized [3]. Currently, there is no literature that accurately portrays the relationship between the occurrence of diabetic bulla and the degree of metabolic derangement or glycemic control. BD most likely arises in conjunction with the numerous complications of poorly controlled diabetes [3]. Usually acral distributions of blisters or bullous lesions suggest changes related to a susceptibility to trauma or peripheral neuropathy [6]. This case supports vasculopathy as a likely cause of bullous lesions in diabetics. Healing of bullous lesions occurs spontaneously after two to six weeks. Antibiotics and/or extensive wound care is warranted if secondary infections occur. However, aspiration of bullous lesions might help to prevent accidental rupture and subsequent complications.

BD is diagnosed by a system of elimination. In diabetics with bullous eruptions, most literature reports negative direct and indirect immunofluorescence microscopy findings [7]. Clinicians should consider microscopic investigations to rule out other differentials of diabetic bullae (e.g., see Table 1 for differential diagnoses) that typically are positive for various complement and immunoglobulin deposition along the dermo-epidermal junction [3]. We report the first case of BD with IgG (Immunoglobulin gamma) deposition in the superficial capillary basement membrane.

Table 1. Differential diagnosis.

1. Bullous pemphigoid
2. Epidermolysis bullosa
3. Epidermolysis bullosa acqvista
4. Porphyria cutanea tarda
5. Pseudoporphyria
6. Drug-induced bullous disorders

Case Report

A 42-year old African American male with long standing poorly controlled insulin dependent diabetes mellitus presented to the emergency department with blisters on his left hand and feet. The blisters were first noticed three weeks before his admittance to the hospital. The patient's past medical history, including end-stage renal disease and peripheral neuropathy, was significant to the case as well. The blisters rapidly increased in size and spontaneously ruptured. The patient denied any recent trauma, contact with pesticides, insect bites, UV light exposure, or long-distance travel. During physical examination, the patient was noted to have a multitude of both roofed and unroofed bullous, painless skin lesions (Figure 1A, 1B). His glycosylated hemoglobin (HbA1c) was 10.7% on admission. The patient was taking the following medications at home: aspirin 81 mg PO (per oral) daily, carvedilol 6.25 mg PO BID (two times a day), insulin lispro 0–11 units subcutaneous TID (three times a day), lisinopril 5 g PO daily, ramelteon 8 mg PO nightly, sevelamer 1600 mg PO TID.

Dermatology was consulted. The asymptomatic nature of bullous eruptions favored BD in uncontrolled diabetes. Bullous pemphigoid was less likely, given his age, lack of pain, and pruritus. Other differentials of bullous lesions were excluded with extensive investigations, including perilesional biopsy with direct immunofluorescence. Hematoxylin and eosin (H&E) staining (Figure 2A) dramatized the dermal-epidermal blistering and re-epithelization process. Furthermore, only a few inflammatory cells were found within the blister space. Rare neutrophils and lymphocytes were noted in the superficial dermis without deep infiltrate. Subsequently, DIF (Figure 2B) was positive for 2 + IgG deposition in the already thickened basement membrane of superficial capillaries of the superficial vascular plexus. Finally, dermatology confirmed diagnosis of BD.

He completed a six-week course of intravenous vancomycin (15 mg/kg once 24 hourly) and ceftazidime (1 g once 24 hourly) due to the presence of a local secondary superinfection. General surgery was consulted and performed a debridement of the skin wounds. He continued to have leukocytosis, and Infectious Disease (ID) was consulted. ID recommended four weeks of vancomycin and ceftazidime. He continued to spike fevers and had leukocytosis. His wounds had greatly improved throughout hospitalization, but were still significant. Upon discontinuation of antibiotics after a four-week course, he spiked a fever. He was then restarted on vancomycin and ceftazidime. This course ended when he was finished with three times debridement. The patient's wounds greatly improved with over three months of aggressive wound care.

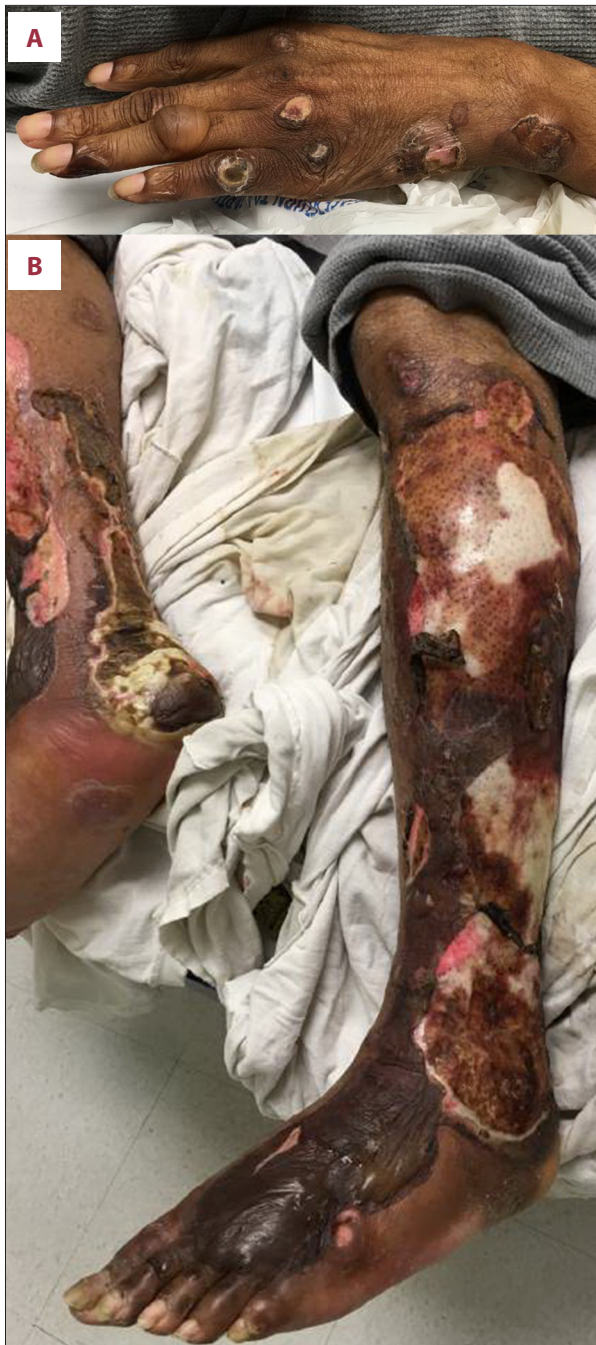

Figure 1. (A) Left hand: roofed and unroofed partial and full thickness blisters. (B) Both legs and feet: roofed and unroofed partial and full thickness blisters.

Discussion

In diabetic bullae, blisters occur suddenly, often overnight, without any apparent cause, and typically without known history of recent trauma.

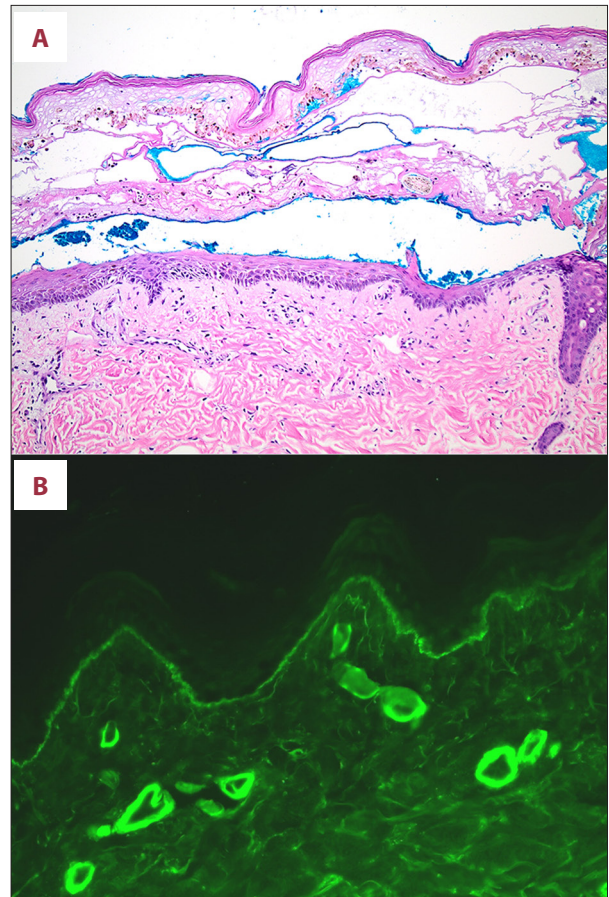


Figure 2. (A) H&E staining of a perilesional skin biopsy showing the dermal-epidermal blistering and re-epithelization process along with a few inflammatory cells within blister space. (B) Direct immunofluorescence of a perilesional skin biopsy positive for 2 + IgG deposition.

Characteristics of lesions

Blisters tend to be painless and non-pruritic, like those experienced in this case. Rarely, the blisters can cause mild discomfort. Tense and non-tender blisters on non-erythematous skin mainly characterize bullous lesions. In this case, extensive roofed and unroofed bullous lesions were noted on initial presentation. Sometimes blisters have a tendency to be large with irregular margins and flaccid that imitates burn lesions. As described in this case, site of bullae formation is mainly distal distributions in both extremities especially lower, but blisters rarely occur in non-acral sites [3].

Pathogenesis

The etiopathogenesis of BD is multifactorial. For example, among diabetics and non-diabetics, patients with known history of diabetes are shown to have a lower threshold for occurrence of blister due to suction. Other factors could be vibration,

high temperature, and long-standing pressure on the proximal lower extremities [8,9]. In individuals with nephropathy, UV exposure might contribute to the underlying mechanism of blister development [10]. There is no direct correlation between glycemic control and bullae formation. Many patients with nephropathy and/or neuropathy are reported to have diabetic bullae, as shown in this case. Due to hyaline deposition of capillary wall on biopsy findings, some researchers have started to speculate that vasculopathy might lead to induction of blister formation [3]. Interest in the skin manifestations of diabetic microangiopathy began in 1964 when Bauer et al. observed periodic acid-Schiff (PAS) positive capillary basement membrane thickening (CBMT) in necrobiosis lipoidica diabetorum (NLD) [11]. Kurwa et al. suggested that BD may also be caused by diabetic microangiopathy [12]. The positive findings with DIF from this case are in general agreement with this theory.

Workup

Light microscopy with H&E staining

Few case reports have described the separation of the sub-corneal, intra-epidermal, and sub-epidermal locations of a biopsy after H&E staining. Through electron microscopy, the separation at a sub-epidermal location is seen at the lamina lucida level [3]. Although there are no significant changes, a few literature reports describe that sometimes the epidermis shows abnormal accumulation of fluid (spongiosis), but there is no breakdown of cell layer (acantholysis) and degeneration of keratinocytes [13]. Blisters can be seen in various stages of healing during presentation because of re-epithelization. The bullae usually contain sterile proteinaceous fluid without any inflammatory components [3].

Immunofluorescence studies

Direct immunofluorescence is a useful supplement for the accurate diagnosis and classification of various autoimmune bullous disorders (see Table 1 for differential diagnosis). When clinical features and histopathology are inconclusive, the diagnosis can often be made based on DIF findings alone. A combination of the clinical features, histopathology, and DIF usually procures the best results [14]. As it is difficult to rule out all the differential diagnoses of BD clinically, immunofluorescence studies on skin biopsy may be needed. Porphyria cutanea tarda shows deposition of PAS-positive diastase resistant mucopolysaccharides and immunoglobulins in and around the superficial dermal blood vessels and at the basement membrane zone. Porphyrias typically exhibit caterpillar bodies [15]. In epidermolysis bullosa, immune mapping shows antibodies to the hemidesmosomal antigen and lamina densa protein (e.g., type IV collagen) at the dermo-epidermal junction [16]. Bullous pemphigoid and epidermolysis bullosa acquisita usually exhibit a linear band of immunoglobulin G deposit along

the dermo-epidermal junction [17]. A U-serrated pattern is typical of epidermolysis bullosa acquisita, whereas a N-serrated pattern is typical of pemphigoid [3].

Primary immunologic abnormality plays no role in BD. In patients with bullous eruptions of diabetes mellitus, findings from both direct and indirect immunofluorescence examinations of the skin are negative. One article has reported nonspecific capillary-associated immunoglobulin deposition in BD [18]. Our case has shown positive direct perivascular immunofluorescence in involved tissue with IgG deposition in superficial capillary basement membrane. This suggests microangiopathy, secondary to immunologic abnormality, as the underlying pathogenesis.

Treatment approach

Since the condition is self-limiting, there is no specific treatment. Blisters typically heal spontaneously within two to six weeks, but chances of recurrence are high either in the same or different sites. Although bullous lesions often are cured without scar formation, they can convert into ulceration [10]. There is also literature showing an association between osteomyelitis and bullous disease of diabetes [19]. Some lesions in our case had secondary infections needing debridement. To prevent possible secondary polymicrobial infection, patients with confirmed BD should be observed closely until lesions heal completely. Antibiotics only play a role if secondary infection is present. Although secondary infection may develop, patients with diabetic bullae have a better prognosis [3]. To prevent accidental rupture and subsequent complications, aspiration of blisters as well as immobilization may be required. Incision/debridement and possible split skin grafting may be helpful in the case of secondary tissue destructions [3].

Conclusions

BD requires meticulous clinical assessment and pathologic correlation to distinguish it from similar conditions. Positive findings of DIF are usually suggestive of underlying vasculopathy. Punch biopsy with DIF can be an additional diagnostic tool. These lesions require detailed assessment and standard diabetic wound care with early interventions to prevent secondary infections and ulcer development. Awareness of BD is crucial for early recognition and avoidance of unnecessary investigations and treatment.

Acknowledgements

We appreciate the helpful suggestions and comments from Neha Shaber and Nicki Lawson, for editing this paper.

Conflict of Interest

None.

References:

1. Kramer DW: Early or warning signs of impending gangrene in diabetes. *Med J Rec*, 1930; 132: 338–42
2. Cantwell AR Jr., Martz W: Idiopathic bullae in diabetics. *Bullosis diabeticorum*. *Arch Dermatol*, 1967; 96(1): 42–44
3. Poh-Fitzpatrick MB, Junkins-Hopkins JM, Elston DM: Bullous disease of diabetes. *Medscape*, updated 2015 [cited 27 Jul 2017]; Available from: <http://emedicine.medscape.com/article/1062235>
4. Mahajan S, Koranne RV, Sharma SK: Cutaneous manifestation of diabetes mellitus. *Indian J Dermatol Venereol Leprol*, 2003; 69: 105–8
5. Anand KP, Kashyap AS: Bullosis diabeticorum. *Postgrad Med J*, 2004; 80(944): 354
6. Aye M, Masson EA: Dermatological care of the diabetic foot. *Am J Clin Dermatol*, 2002; 3(7): 463–74
7. Basarab T, Munn SE, McGrath J, Russell Jones R: Bullosis diabeticorum. A case report and literature review. *Clin Exp Dermatol*, 1995; 20(3): 218–20
8. Bernstein JE, Levine LE, Medenica MM et al: Reduced threshold to suction-induced blister formation in insulin-dependent diabetics. *J Am Acad Dermatol*, 1983; 8(6): 790–91
9. Bello F, Samaila OM, Lawal Y, Nkoro UK: 2 cases of bullosis diabeticorum following long-distance journeys by road: A report of 2 cases. *Case Rep Endocrinol*, 2012; 2012: 367218
10. Larsen K, Jensen T, Karlsmark T, Holstein PE: Incidence of bullosis diabeticorum – a controversial cause of chronic foot ulceration. *Int Wound J*, 2008; 5(4): 591–96
11. Sawhney M, Tutakne MA, Rajpathak SD, Tiwari VD: Clinical study of diabetic dermoangiopathy. *Indian J Dermatol Venereol Leprol*, 1990; 56(1): 18–21
12. Kurwa A, Roberts P, Whitehead R: Concurrence of bullous and atrophic skin lesions in diabetes mellitus. *Arch Dermatol*, 1971; 103(6): 670–75
13. Toonstra J: Bullosis diabeticorum: Report of a case with a review of the literature. *J Am Acad Dermatol*, 1985; 13(5): 799–805
14. Mysorekar VV, Sumathy TK, Shyam Prasad AL: Role of direct immunofluorescence in dermatological disorders. *Indian Dermatol Online J*, 2015; 6(3): 172–80
15. Epstein JH, Tuffanelli DL, Epstein WL: Cutaneous changes in the porphyrias. A microscopic study. *Arch Dermatol*, 1973; 107(5): 689–98
16. Woodley DT, Gerald GK, Atha T et al: Normal and gene-corrected dystrophic epidermolysis bullosa fibroblasts alone can produce type VII collagen at the basement membrane zone. *J Invest Dermatol*, 2003; 121(5): 1021–28
17. Arbache ST, Nogueira TG, Delgado L et al: Immunofluorescence testing in the diagnosis of autoimmune blistering diseases: Overview of 10-year experience. *An Bras Dermatol*, 2014; 89(6): 885–89
18. James WD, Odom RB, Goette DK: Bullous eruption of diabetes mellitus: A case with positive immunofluorescence microscopy findings. *Arch Dermatol*, 1980; 116(10): 1191–92
19. Tunuguntla A, Patel KN, Peiris AN, Zakaria WN: Bullosis diabeticorum associated with osteomyelitis. *Tenn Med*, 2004; 97(11): 503–4