



Fistulas between the Esophagus and Adjacent Vital Organs in Esophageal Cancer

Sukki Cho, M.D.

¹Department of Thoracic and Cardiovascular Surgery, Seoul National University Bundang Hospital, Seongnam; ²Department of Thoracic and Cardiovascular Surgery, Seoul National University College of Medicine, Seoul, Korea

ARTICLE INFO

Received June 8, 2020

Revised July 3, 2020

Accepted July 4, 2020

Corresponding author

Sukki Cho

Tel 82-31-787-7132

Fax 82-31-787-4050

E-mail tubincho@snu.ac.kr

ORCID

<https://orcid.org/0000-0002-9309-8865>

¹This article was presented at the 6th Esophageal Cancer Symposium (lecture on November 16th, 2019, Samsung Medical Center, Seoul, Korea).

Esophageal fistulas may occur in an advanced stage or as a potentially life-threatening complication of treatment. They can be divided into esophageal-respiratory and esophageal-aorta fistulas. The diagnosis is confirmed with fluoroscopy using dilute barium oral contrast, followed by thin-section computed tomography, which defines the precise location and extent of the fistula. Flexible esophagoscopy and bronchoscopy are required for confirmation and anatomic assessment of the suspected fistula and provide additional information for treatment planning. Contamination is traditionally controlled by surgical exclusion, along with a jejunal feeding tube. Currently, fully covered self-expanding metal stents are the primary treatment option.

Keywords: Esophageal neoplasms, Fistula, Complications, Respiratory, Aorta

Introduction

Fistulas between the esophagus and adjacent vital organs occur infrequently, but they are challenging complications to manage in patients with esophageal cancer. They usually occur in the setting of advanced-stage disease or as a complication of surgical treatment or concurrent definitive chemoradiotherapy (CRT). Since this situation occurs in cases of unresectable esophageal cancer, the treatment is palliative, not curative; therefore, the objective of treatment is to save the patient's life from the threat posed by the fistula by non-surgical or minimally invasive treatment. A multidisciplinary approach is essential for accurate and precise diagnosis and treatment. In cases of esophageal cancer, fistulas most commonly occur between the esophagus and respiratory organs or cardiovascular organs; therefore, these conditions can be divided into esophageal-respiratory fistulas (ERFs) and aorto-esophageal fistulas (AEFs).

Anatomy of the esophagus

Unlike the other digestive organs, the esophagus does not have serosa; therefore, if cancer invades the muscle layer, it can easily invade the surrounding organs. As a result, vital organs such as the heart, aorta, trachea, bronchus, and lung can be easily invaded by advanced esophageal cancer (Fig. 1). The most commonly invaded organ is the trachea, as it is the nearest organ and has the fewest barriers, followed in order by the left main bronchus and aorta [1].

Mechanisms of fistula formation between the esophagus and other organs

Direct invasion

The cancer begins in the mucosal lining of the esophagus. As the cancer grows rapidly and extends deeply through the wall of the esophagus, it infiltrates into the normal surrounding areolar tissue. In ERFs, the cancer invades directly into the trachea through its membranous



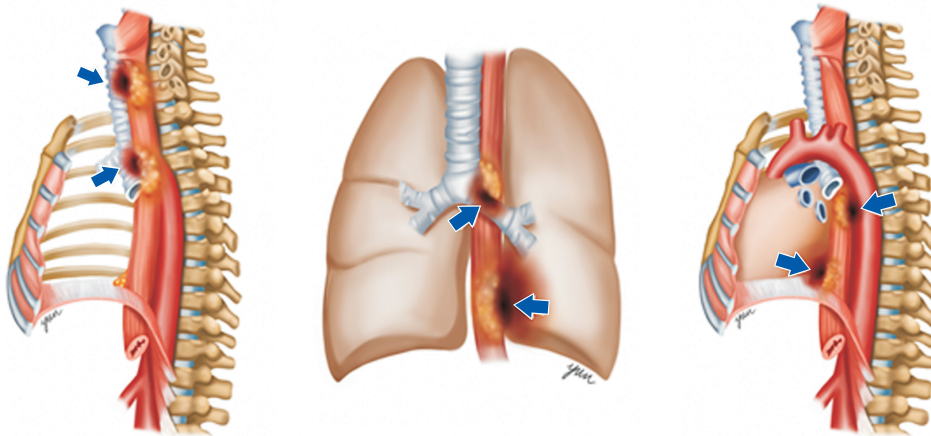


Fig. 1. The aorta, trachea, bronchus, and lung can be easily invaded by advanced esophageal cancer. Multiple arrows indicate fistulas between the esophagus and adjacent organs.

wall, followed by tumor necrosis, paving the way for ERF formation. The areolar tissue separating the esophagus from the trachea provides a tumor microenvironment supporting continued cancer growth and extension [2].

Metastatic lymph nodes

Because of their proximity to the trachea and esophagus, metastatic lymph nodes erode into the proximal airway, paving the way for ERFs when there is concomitant erosion into the adjoining esophagus [3].

Surgery

After reconstructive procedures such as esophagogastrotomy, tissue necrosis and inflammation associated with anastomotic rupture can result in a fistula running from the esophagus to the trachea or a gastric conduit to the lung.

Radiation

Radiation-induced tumor necrosis depends on the inherent radiosensitivity of the primary cancer. If the primary cancer is too radiosensitive, then the risk for fistulization by necrosis is high. The underlying mechanism involves an imbalance between tumor shrinkage and the normal tissue repair system [2].

Stent-induced

A stent may cause pressure necrosis, inflammation, and fibrosis of the esophageal mucosa. Direct erosion of an esophageal stent for relieving stenosis in the tracheobronchial tree increases the risk of a tracheoesophageal fistula.

Aorto-esophageal fistulas

The main causes of AEFs are ruptured or non-ruptured

aortic aneurysm, foreign body ingestion, and advanced esophageal malignancy. Their pathogenesis is related to esophageal ischemia secondary to blockade of the esophageal artery, increased pressure in the posterior mediastinum, inflammation of a resorption hematoma, mechanical compression by a large aneurysm and secondary erosion, or geometric changes in the aortic arch and descending aorta after stenting [4].

Risk factors for esophageal fistula

Previous studies of esophageal fistulas in patients with esophageal cancer showed that total circumferential lesions and high C-reactive protein (CRP) levels [5], young age, a tumor in the mid-thoracic esophagus, a necrotizing pattern [6], and the presence of stenosis and high carcinoembryonic antigen levels [7] are risk factors for fistula in cases of esophageal cancer.

The risk of a radiation-induced fistula is increased by concomitant use of chemotherapy with radiation therapy. Radiotherapy may hasten a fistula by lysing the tumor, especially in patients with bulky tumors that impinge on the trachea. Interestingly, induction chemotherapy followed by CRT has been reported to reduce the incidence of fistulas compared with CRT alone [8].

Diagnosis of esophageal fistulas

Symptom-based

The diagnosis of a fistula in patients with esophageal cancer is not difficult because of the accompanying symptoms when a fistula is present between the esophagus and adjacent organs. The saliva and food introduced through the esophagus cause inflammation in the organs connect-

ed to the esophagus. A connection of the esophagus with the trachea or bronchus results in constant cough and sputum, with the same pathophysiology as aspiration pneumonia. Therefore, computed tomography (CT) shows pneumonic infiltration, especially in the lower lobes, or the presence of consolidative lesions (Fig. 2). The symptoms associated with AEFs are mid-thoracic pain, dysphagia, and sentinel hemorrhage. After a symptom-free interval of hours to days, fatal exsanguination develops [9].

Image-based

Imaging tests can be chosen based on the patient's symptoms. Esophagogastroduodenoscopy (EGD) and chest CT are usually performed for all patients. If a fistula to the tra-

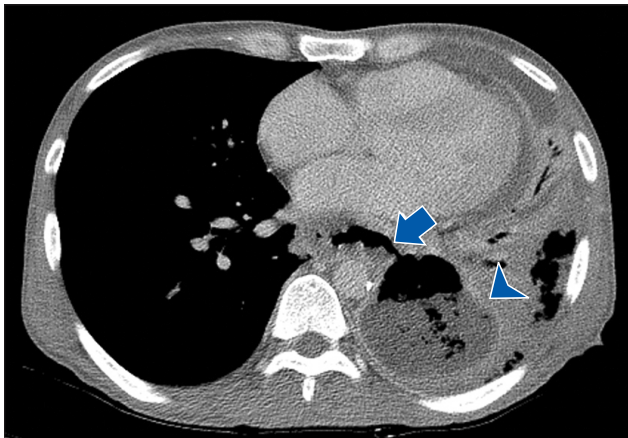


Fig. 2. Computed tomography shows a pneumonic infiltration and abscess in the left lower lobes. The arrow indicates the perforation of esophagus and communication to the lung, and the arrowhead indicates a lung abscess in the left lower lobe.

chea or bronchus is suspected, it is confirmed through flexible bronchoscopy, because the esophageal mucosal folds and tumor may obscure the origin of the fistula. Because the size of the fistula itself is not exactly proportional to the severity of symptoms, esophagography is sometimes performed. If respiratory fistula is suspected, barium should be used in the bronchus, as a small quantity of barium is harmless in the tracheobronchial tree. Flexible EGD and bronchoscopy are required to provide additional information for treatment planning in addition to the therapeutic benefit of clearing the contaminated airway (Fig. 3).

Details

Esophageal-respiratory fistulas

ERFs develop between the esophagus and the trachea, bronchus, and lung parenchyma. Malignancy accounts for 50% of cases of ERFs, and as many as 5% to 15% of patients with advanced esophageal cancer will develop ERFs [10-12]. The fistula site is tracheoesophageal in 52% to 57% of patients and bronchoesophageal in 37% to 40%, while the remaining 3% to 11% of cases involve peripheral communication with the lung parenchyma [13].

Case presentation

A 52-year-old man visited an outpatient clinic for progressive dysphagia and high fever. A chest X-ray showed a lung abscess in the left lower lobe (LLL) (Fig. 4A). Chest CT showed a huge mass in the distal esophagus with a connection to the LLL. Positron emission tomography-CT showed high maximum standardized uptake value of the

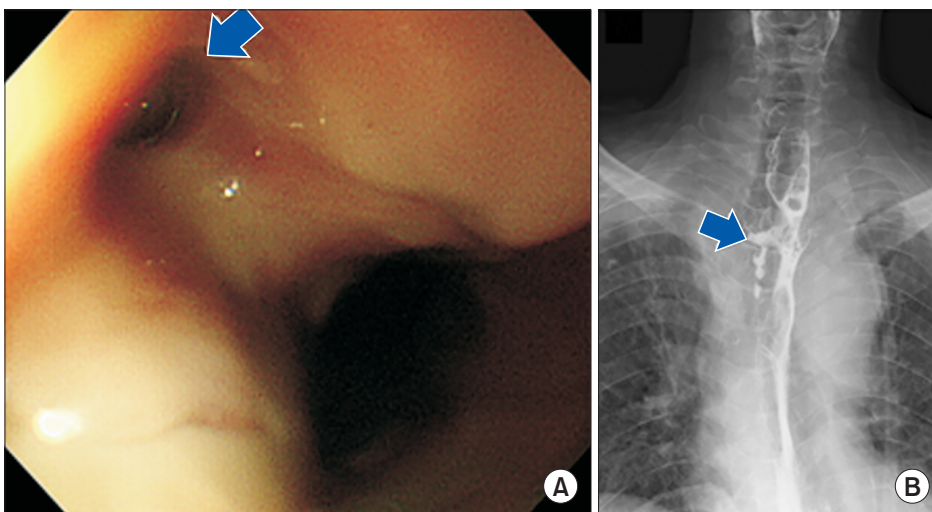


Fig. 3. Findings of EGD and esophagography. (A) On EGD, the arrow indicates a small hole in the anterior side of the upper esophagus. (B) On esophagography, the arrow indicates leakage of ingested dye into the trachea. EGD, esophagogastroduodenoscopy.

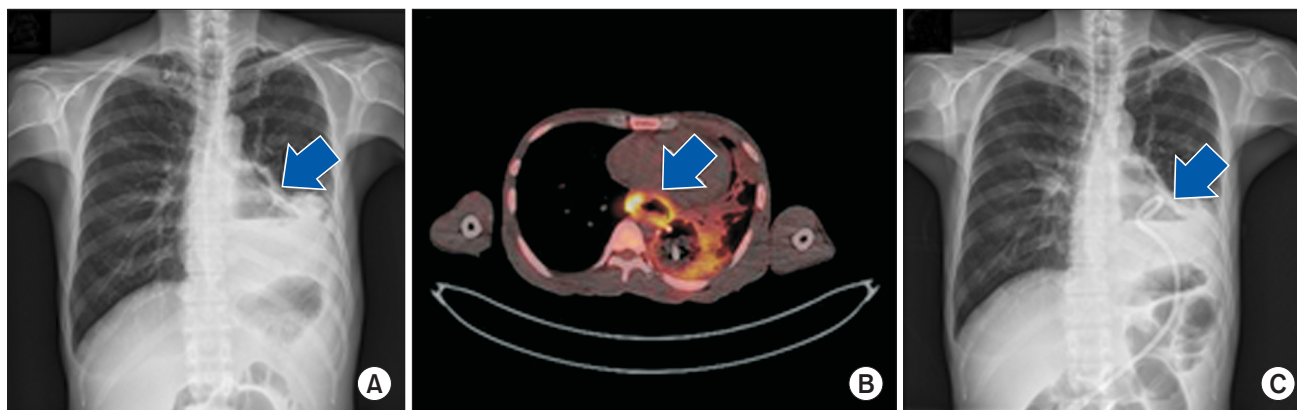


Fig. 4. Chest X-ray and PET/CT findings of a patient with advanced esophageal cancer who had an ERF. (A) The arrow indicates a lung abscess in the left lower lobe. (B) On PET/CT, a fistula is seen to have developed by rupture of a huge tumor of esophageal cancer, in which PET showed the highest metabolism anywhere in the esophagus. (C) For infection control, percutaneous catheter drainage was performed before surgery. PET, positron emission tomography; CT, computed tomography; ERF, esophageal-respiratory fistulas.

esophageal mass and no distant metastasis (Fig. 4B). To control inflammation of LLL, percutaneous catheter drainage was performed preoperatively (Fig. 4C). Surgical treatment was performed, involving a left lower lobectomy with en bloc esophageal resection with cervical esophagogastrotomy. The pathology findings were pathologic stage T4bN0M0 disease with a lung abscess. Seven days postoperatively, a massive air leak developed, and chest CT and portable bronchoscopy showed a bronchopleural fistula at the bronchial stump. Three days after the bronchopleural fistula formed, the cervical anastomotic site ruptured. Twenty days after rupture of the cervical anastomotic site, the patient died from septic shock.

The main cause of dehiscence of the bronchial stump of the LLL was ERF-induced severe inflammation of the left pleural cavity, which was not completely controlled; furthermore, pneumonia of the left upper lobe, systemic inflammation, and hypoxia had negative effects on the anastomosis between the esophagus and stomach. It would have been better if the surgery had been performed into 2 stages. For infection control, the first stage was left lower lobectomy with en bloc esophageal resection, cervical esophagostomy, and jejunostomy. After stabilizing from infection and general weakness, the second stage was cervical esophagogastrotomy.

Management

ERFs have high rates of morbidity and mortality, and the ideal treatment for patients with ERFs is not clearly defined. Due to repeated episodes of aspiration pneumonia and the fact that the remaining life expectancy of ERF patients is only weeks to months, the goal of ERF manage-

ment is to provide the best possible supportive care. Left untreated, ongoing spillage of gastric contents into the pulmonary tree will result in rapid deterioration from pulmonary infections and respiratory insufficiency [2].

Non-surgical treatment includes infection control and stent insertion. For infection control, oral intake should be withheld and alternative forms of nutrition, such as total parenteral nutrition or feeding jejunostomy, should be established. Broad-spectrum antibiotics should be administered to cover Gram-positive bacteria, anaerobes, and yeast. The most important point is that any contaminated fluid collections in the mediastinum, pleural space, and pericardium, as well as any lung abscesses, should be adequately drained by a percutaneous catheter or a surgical procedure. Stent insertion is the primary treatment option for esophageal fistulas. The insertion of self-expanding metal stents has the advantage of providing rapid and effective temporary palliation in tight, malignant esophageal strictures. The stent should be long enough to include any stricture, both to facilitate oral intake and minimize stent migration. A nitinol-covered Ultraflex expandable stent is preferred because it is less likely to migrate due to its design with expanded flanges and flared proximal and distal ends, and it often completely seals the esophageal fistula. However, it should be noted that the placement and expansion of a large-diameter expandable stent through a bulky, firm retrobronchial tumor can result in acute airway obstruction by compressing the airway wall. If there is a potential risk of external tracheal compression, then consideration should be given to placing a tracheal stent before placing an esophageal stent. In addition, an expanded stent may readily erode through and enlarge the fistula. Poten-

tial stent migration can be easily monitored with routine chest X-rays. Generally, 4 to 6 weeks are required for healing with a stent, as confirmed by endoscopy during removal of the stent. If the fistula is closed, confirmatory contrast esophagography should be obtained within 48 hours.

In cases of advanced esophageal cancer with ERFs, the role of surgical treatment is palliative because of its minimal survival advantage for esophageal cancer itself, although in highly selected patients with malignant ERFs, aggressive surgical treatment has been reported to improve survival. It is rare for patients to be candidates for radical surgery because most patients have advanced-stage cancer at presentation, with nutritional depletion and pulmonary sepsis. Therefore, palliative surgery includes exclusion (cervical esophagostomy) and bypass surgery to relieve dysphagia from obstruction and to maintain drainage of the esophageal segment. Currently, video-assisted thoracoscopic surgery can accomplish decortication of the contaminated pleural space, including unroofing of any mediastinal abscess and contaminated pericardial effusions. If a prolonged delay in resuming oral nutrition is expected, a surgically or fluoroscopically placed feeding tube to the jejunum should be considered.

Aortoesophageal fistulas

Because AEFs are highly lethal, it is very rare to treat patients with AEFs. Patients generally visit the emergency room or an outpatient clinic in the silent period before impending rupture, after which massive hematemesis develops and most patients die. Chiari [14] first described AEFs as a syndrome that consists of midthoracic pain, sentinel hemorrhage, and exsanguination after a symptom-free interval. The common causes are thoracic aortic aneurysm, malignant intrathoracic neoplasm, foreign body ingestion, or endovascular stent graft repair. Advanced esophageal cancer can cause AEFs by direct mediastinal tumor invasion, radiotherapy alone, CRT, or esophageal stent placement [9].

Management

Some reports have described the successful management of AEFs using thoracic endovascular aortic repair (TEVAR), and open surgery and TEVAR can prevent death by exsanguination; however, patients remain at a high risk of infectious complications if the esophageal defect is not repaired. Conservative medical management led to a 100% rate of in-hospital mortality; as such, nonoperative management, hemodynamic instability at admission, and sepsis

are closely related to in-hospital mortality. The combination of TEVAR or open aortic replacement with esophageal surgery should only be considered if the patient is otherwise in excellent condition.

Conclusion

A fistula to adjacent vital organs is a frequently fatal complication of esophageal cancer. Younger age, high CRP levels, stage T4 disease, longer segmental stenosis, a tumor in the middle part of the esophagus, a necrotizing pattern, and total circumferential lesions are risk factors. All treatments are palliative-only, with intent to improve the quality of life, to reduce the risk of ongoing pneumonia, and to enable swallowing for a limited time. Esophageal stenting is an effective form of management for ERFs. TEVAR can effectively serve as a bridge to definitive open surgery for AEFs.

Conflict of interest

No potential conflict of interest relevant to this article was reported.

ORCID

Sukki Cho: <https://orcid.org/0000-0002-9309-8865>

References

1. Hamai Y, Hihara J, Emi M, et al. *Treatment outcomes and prognostic factors for thoracic esophageal cancer with clinical evidence of adjacent organ invasion*. *Anticancer Res* 2013;33:3495-502.
2. Shamji FM, Inculet R. *Management of malignant tracheoesophageal fistula*. *Thorac Surg Clin* 2018;28:393-402.
3. Zhou C, Hu Y, Xiao Y, Yin W. *Current treatment of tracheoesophageal fistula*. *Ther Adv Respir Dis* 2017;11:173-80.
4. Yamazato T, Nakamura T, Abe N, et al. *Surgical strategy for the treatment of aortoesophageal fistula*. *J Thorac Cardiovasc Surg* 2018;155:32-40.
5. Kawakami T, Tsushima T, Omae K, et al. *Risk factors for esophageal fistula in thoracic esophageal squamous cell carcinoma invading adjacent organs treated with definitive chemoradiotherapy: a monocentric case-control study*. *BMC Cancer* 2018;18:573.
6. Balazs A, Galambos Z, Kupcsulik PK. *Characteristics of esophago-respiratory fistulas resulting from esophageal cancers: a single-center study on 243 cases in a 20-year period*. *World J Surg* 2009;33:994-1001.
7. Zhang Y, Li Z, Zhang W, Chen W, Song Y. *Risk factors for esophago-*

- geal fistula in patients with locally advanced esophageal carcinoma receiving chemoradiotherapy. *Onco Targets Ther* 2018;11:2311-7.
8. Miyata H, Yamasaki M, Kurokawa Y, et al. *Clinical relevance of induction triplet chemotherapy for esophageal cancer invading adjacent organs*. *J Surg Oncol* 2012;106:441-7.
 9. Um SJ, Park BH, Son C. *An aorto-esophageal fistula in patient with lung cancer after chemo-irradiation and subsequent esophageal stent implantation*. *J Thorac Oncol* 2009;4:263-5.
 10. Shin JH, Song HY, Ko GY, Lim JO, Yoon HK, Sung KB. *Esophago-respiratory fistula: long-term results of palliative treatment with covered expandable metallic stents in 61 patients*. *Radiology* 2004;232:252-9.
 11. Chen YH, Li SH, Chiu YC, et al. *Comparative study of esophageal stent and feeding gastrostomy/jejunostomy for tracheoesophageal fistula caused by esophageal squamous cell carcinoma*. *PLoS One* 2012;7:e42766.
 12. Balazs A, Kupcsulik PK, Galambos Z. *Esophago-respiratory fistulas of tumorous origin: non-operative management of 264 cases in a 20-year period*. *Eur J Cardiothorac Surg* 2008;34:1103-7.
 13. Kim KR, Shin JH, Song HY, et al. *Palliative treatment of malignant esophagopulmonary fistulas with covered expandable metallic stents*. *AJR Am J Roentgenol* 2009;193:W278-82.
 14. Chiari H. *Ueber Fremdkorperverletzung des Oesophagus mit Aorten-perforation [Foreign body injury to the esophagus with aortic perforation]*. *Ber Klin Wochenschr* 1914;51:7-9.