



# Ustekinumab-Associated Posterior Reversible Encephalopathy Syndrome in a Patient With Crohn's Disease

Ariel Jordan, MD<sup>1</sup>, and Jami Kinnucan, MD<sup>2</sup>

<sup>1</sup>Department of Internal Medicine, University of Michigan, Ann Arbor, MI

<sup>2</sup>Department of Gastroenterology, Mayo Clinic-Jacksonville, Jacksonville, FL

## ABSTRACT

Ustekinumab is a common biologic therapy for the treatment of inflammatory bowel disease. Posterior reversible encephalopathy syndrome (PRES) is an uncommon condition consisting of a constellation of neurologic findings and characteristic findings on imaging. The association between ustekinumab and PRES is not well defined. We present a case of PRES in a patient with Crohn's disease on ustekinumab and a brief review of the literature. Clinicians should be aware of this rare complication with high morbidity in patients with inflammatory bowel disease on ustekinumab and be able to recognize clinical symptoms.

## INTRODUCTION

Ustekinumab is a human monoclonal antibody inhibitor that binds to the p40 subunit shared by receptors interleukin (IL)-12 and IL-23 modulating lymphocyte function.<sup>1</sup> Ustekinumab has been approved for use in psoriasis and inflammatory bowel disease (IBD) and is becoming increasingly used in both conditions. Although ustekinumab has an overall favorable safety profile, there is a rare, reported association with posterior reversible encephalopathy syndrome (PRES). PRES is a clinical syndrome consisting of rapid-onset neurologic findings such as headache, seizures, altered consciousness, and visual disturbances with classic findings on magnetic resonance imaging (MRI).<sup>2</sup> While the cause is not fully understood, patients often recover with the withdrawal of the inciting agent, although lasting neurologic deficits have been reported.<sup>2</sup> There are only 4 known cases of PRES in patients taking ustekinumab and only 2 cases in patients with IBD.<sup>3-5</sup> We present a case of PRES in a patient with Crohn's disease (CD) treated with ustekinumab.

## CASE REPORT

A previously healthy 64-year-old woman with a 40-year history of Montreal class B3 ileocolonic, vulvar, and perianal CD presented to the emergency department (ED) after a 4-day history of headache, upper back pain, weakness, and numbness of bilateral hands. She had returned from Colorado the previous day and originally attributed the symptoms to a change in altitude. She was noted to have new-onset hypertension with a blood pressure of 175/89 mm Hg in the ED. Abdominopelvic computed tomography ruled out aortic dissection and acute intra-abdominal pathology. Her blood pressure improved spontaneously, and she was discharged home from the ED that same afternoon. Later that evening, she experienced new-onset urinary incontinence and difficulty walking prompting her return to the ED. Laboratory test results at this time included a mild leukocytosis of 10.3 K/uL, a normal hemoglobin of 14.3 g/dL, a normal creatinine of 0.86 mg/dL, an elevated creatine kinase of 402 U/L, and an erythrocyte sedimentation rate of 54 mm. She was hypertensive with a systolic blood pressure of approximately 200 mm Hg. Infectious workup was negative, including a normal procalcitonin of 0.03 ng/mL and negative blood and urine cultures. She was then admitted to the family medicine service. Regarding her IBD history, she had been on a maintenance dose of ustekinumab 90 mg every 8 weeks for 2.5 years with no adverse events and deep clinical and endoscopic remission of her CD based on her last colonoscopy 1 year before this presentation. Her last ustekinumab injection was approximately 2 months before presentation; thus, she was near due for the next dose. Previously, she had been on adalimumab for the past 25 years but lost response, prompting the transition to ustekinumab. Given her neurologic findings, MRI of the brain was completed shortly after admission showing multifocal T2/fluid-attenuated inversion

recovery hyperintensities noted in the bilateral hemispheres of the cerebellum, left greater than right, specifically in the supratentorial area and posterior fossa (Figure 1). MRI of the spine was negative for epidural abscess or a demyelinating process. Given her long-standing history of Crohn's disease with small bowel involvement, vitamin deficiencies were ruled out with a normal vitamin B12 level of 386 pg/mL and a copper level of 1.0 ug/mL. The imaging findings and clinical history were felt to be most consistent with PRES likely associated with ustekinumab use and less so with a cerebrovascular accident (CVA) or new demyelinating diseases, such as subacute combined degeneration of the spinal cord due to vitamin B12 deficiency or multiple sclerosis. The neurology team was consulted and recommended intravenous (IV) labetalol for her new hypertension and discontinuation of ustekinumab. She had a modest response to the IV labetalol over the next 3–4 days and was transitioned to an oral regimen of antihypertensives on the fourth day of admission. She also developed hyponatremia around day 2 of admission with nadir sodium of 129 on day 3, which responded appropriately to fluid and NaCl tablets and resolved by the time of discharge. Her hyponatremia was also believed to be a sequela of PRES. She was discharged after 10 days on amlodipine because of persistent hypertension at the time of discharge. At the outpatient gastrointestinal follow-up 1 month later, she was persistently hypertensive and had continued difficulty with ambulation, although her urinary incontinence had resolved. Repeat MRI at that time remained unchanged. She was ultimately transitioned to vedolizumab for continued CD medical management given concerns about the continuation of ustekinumab. She ultimately required over a month of care in a skilled nursing facility for rehabilitation services and continues to require home assistance. She has thus far tolerated the transition to vedolizumab without new symptoms.

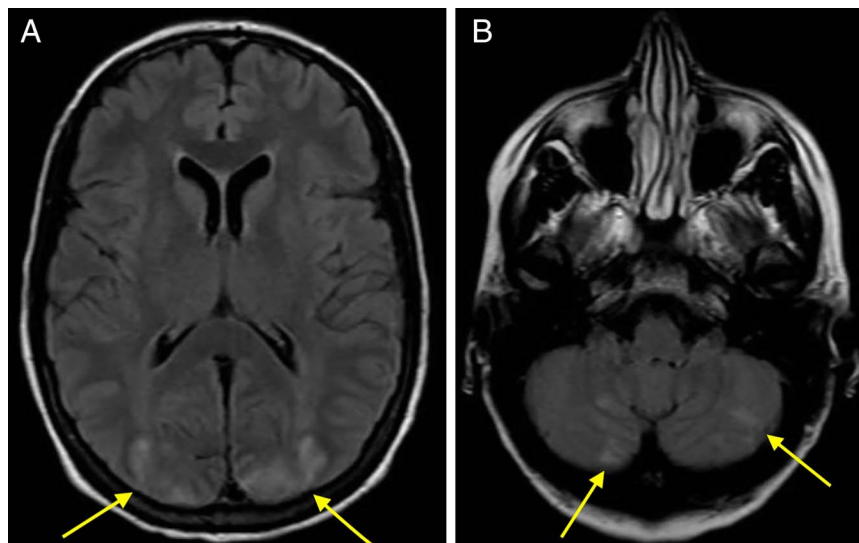
## DISCUSSION

PRES evolves rapidly, often over the course of several hours, with the most common symptoms being seizures, headaches, and altered

mental status.<sup>2</sup> Most patients are severely hypertensive, similar to the patient in our case. Although the pathophysiology of PRES is still not fully understood, there are multiple known associated clinical conditions, including autoimmune diseases. The leading explanation for this association is the neuropeptide hypothesis of the cytotoxic theory. This theory postulates that an initial inflammatory insult, common in autoimmune diseases, causes the recruitment and activation of cytokines and T lymphocytes. These proinflammatory markers lead to endothelial injury which alters the integrity of the blood-brain barrier, ultimately leading to the symptoms of PRES.<sup>6,7</sup> Although these theories have yet to be proven, PRES has been described in multiple other immune-mediated diseases, including systemic lupus erythematosus, mixed connective tissue disease, and rheumatoid arthritis.<sup>8,9</sup> Many of these patients developed symptoms after induction with immunosuppressive therapy but some patients developed PRES, not on any disease-modifying therapy. This calls into question whether immunosuppressive therapy or the autoimmune disease itself is the primary contributor to the development of PRES.

In addition, there are case reports that describe PRES in patients with IBD in the setting of treatment with various biologics, most notably infliximab.<sup>10</sup> In some of these cases, notably the infliximab cases, there was a class switch from the biologics to immunomodulators such as azathioprine.<sup>7,11,12</sup> Based on present evidence, it seems that having both immune-mediated disease and treatment with an immunosuppressive medication further predisposes patients to develop PRES.<sup>10</sup>

We report the fifth known case of ustekinumab-associated PRES and third case in a patient with IBD. This is the first case report to describe PRES in a patient with IBD on maintenance therapy with ustekinumab. Notably, the other known cases of PRES in patients with IBD were during induction with ustekinumab. Although in all cases ustekinumab was stopped immediately, most patients had full neurologic recovery within 2



**Figure 1.** (A) Enhancement of the supratentorial area. (B) Enhancement of the posterior fossa.

**Table 1. Summary of other published cases of biologic-associated PRES**

Case (by author)	Patient description	Initial presentation	MRI findings	Treatment	Outcome
Drummond et al <sup>14</sup>	33-yr-old woman with a 12-yr history of Crohn's disease recently induced on infliximab; postoperative from laparotomy for subacute obstruction	Generalized weakness; blurry vision; tonic-clonic seizures	Widespread foci of abnormal white matter signal, most prominent in the posterior regions	Antiepileptics	Complete neurologic recovery 11 d after initial presentation; improvement of imaging findings at 2 mo
Zamvar et al <sup>11</sup> case 1	14-year-old adolescent boy with newly diagnosed colonic Crohn's disease induced on infliximab	Photophobia; tonic-clonic seizures; notably hypertensive at presentation	T2 and fluid-attenuated inversion recovery signal hyperintensities in a broadly symmetrical distribution affecting the cerebellar hemispheres, occipital poles, medial parietal lobes, and peripheral frontal lobes	Antiepileptics, antibiotics; class switch to azathioprine	Complete neurologic recovery 2 wk after initial presentation; resolution of imaging findings at 1 mo
Zamvar et al <sup>15</sup> case 2	15-yr-old adolescent girl with newly diagnosed ulcerative pancolitis induced on infliximab	Tonic-clonic seizures requiring intubation; notably hypertensive at presentation	T2 and fluid-attenuated inversion recovery signal hyperintensities in a broadly symmetrical distribution affecting the cerebellar hemispheres, occipital poles, medial parietal lobes, and peripheral frontal lobes	Authors did not specify treatment	Complete neurologic recovery; resolution of imaging findings (time frame unspecified)
Gratton et al <sup>4</sup>	65-yr-old woman with a history of psoriasis in a phase 3 clinical study on a stable dose of ustekinumab for 2 yr	Several hours of headache, altered mentation, nausea, and vomiting, followed by seizure; notably hypertensive at presentation	T2 and fluid-attenuated inversion recovery hyperintensities in the white matter of both cerebellar hemispheres, left superior thalamus, and right posterior parietal periventricular white matter	None	Complete neurologic recovery 6 d after initial presentation; resolution of imaging findings at 1 mo
Haddock et al <sup>7</sup>	8-yr-old girl with newly diagnosed colonic Crohn's disease induced on infliximab	Photophobia, nausea, focal left-sided seizure requiring intubation; notably hypertensive at presentation	High signal in the subcortical region, in bilateral occipital lobes, and on the right side with extension to involve the right temporal region	Antiepileptics, antihypertensives; class switch to azathioprine	Development of femoral deep venous thrombosis requiring anticoagulation, 3 additional focal seizures requiring additional antiepileptics; resolution of imaging findings at 11 mo
Chow et al <sup>12</sup>	24-yr-old woman with newly diagnosed fistulizing, colonic Crohn's disease recently induced on infliximab	Tonic-clonic seizures; hypertension was noted	Scattered T2/FLAIR signal abnormalities in the subcortical white matter bilaterally, predominantly in the frontal and posterior parietal lobes	Antiepileptics; class switch to immunomodulator (not specified)	Complete neurologic recovery 1 wk after initial presentation; improvement of imaging findings at 1 wk
Mishra and Seril <sup>3</sup> case 1	18-yr-old woman with a 6-yr history of endoscopically active fistulizing, ileocolonic Crohn's disease recently induced on ustekinumab	Tonic-clonic seizures; hypertension not noted	Bilateral foci of high signal intensity on T2/FLAIR imaging within the frontal, parietal, and occipital lobes	Antiepileptics	Complete neurologic recovery 2 wk after initial presentation; persistence of imaging findings

**Table 1. (continued)**

Case (by author)	Patient description	Initial presentation	MRI findings	Treatment	Outcome
Mishra and Seril <sup>3</sup> case 2	54-yr-old man with a history of endoscopically active, perianal and small bowel, fistulizing Crohn's disease recently induced on ustekinumab	Sudden altered mental status, fever, leukocytosis, elevated lactate, and hypokalemia; hypertension not noted	Scattered foci of increased T2 and FLAIR signaling within the periventricular and subcortical white matter	None	Complete neurologic recovery with persistence of mild headaches 2 wk after initial presentation; persistence of imaging findings not noted
Dickson et al <sup>5</sup>	58-yr-old man with a history of psoriasis and psoriatic arthritis on ustekinumab for >6 yr	Altered mental status, seizures; notably hypertensive at presentation	Bilateral occipital parenchymal edema	Antihypertensives	Complete neurologic recovery; resolution of imaging findings (time frame not specified)
Bandeo et al <sup>16</sup>	26-yr-old woman with a history of endoscopically active ulcerative pancolitis on adalimumab for 7 mo	"Thunderclap" headache, photophobia, nausea/vomiting; notably hypertensive at presentation	Left frontal subarachnoid hemorrhage and hyperintense lesions on T2-weighted and FLAIR sequences located in both occipital lobes, left cerebellar hemisphere, and brainstem	None	Complete neurologic recovery; near resolution of imaging findings (timeframe not specified)
Jordan et al	64-yr-old woman with a history of endoscopically remissive, ileocolonic, vulvar, and perianal Crohn's disease on ustekinumab for 2.5 yr	Headache, back pain, weakness and numbness of bilateral hands; notably hypertensive at presentation	Multifocal T2/FLAIR hyperintensities in the bilateral left greater than right cerebellum, particularly the supratentorial area and posterior fossa	Antihypertensives; class switch to vedolizumab	Persistent hypertension and difficulty with ambulation; persistence of imaging findings

FLAIR, fluid-attenuated inversion recovery; MRI, magnetic resonance imaging.

weeks of initial presentation. Our patient is the only ustekinumab-associated PRES case and second biologic-associated PRES case that did not achieve full neurologic recovery. This is interesting given her symptoms could be considered mild compared with the cases of tonic-clonic seizures and the requirement of intubation. One hypothesis is that this is because of our patient being on maintenance therapy as compared with most cases that occurred during biologic induction. Given there are a few cases of full neurologic recovery during the maintenance phase with other biologics, the authors question whether PRES occurring specifically during the maintenance phase of ustekinumab is a predisposing factor to continued clinical neurologic sequelae. Our patient's hyponatremia was also the first seen in ustekinumab-associated PRES but has been previously seen in PRES.<sup>13</sup> A summary of the known cases of biologic-associated PRES, including ustekinumab-associated PRES, is presented in Table 1. Although clinical presentations and outcomes were varied, MRI findings were consistent among all cases. While there are no formal diagnostic guidelines for PRES, gastroenterologists need to recognize its presentation and its rare association with IBD and IBD therapies.

## DISCLOSURES

Author contributions: All authors contributed to the content. J. Kinnucan is the article guarantor.

Financial disclosures: None to report.

Potential competing interests: None to report.

Informed consent was obtained for this case report.

Received April 6, 2022; Accepted August 16, 2022

## REFERENCES

- Benson J, Peritt D, Scallon B. Discovery and mechanism of ustekinumab. *MAbs* 2011;3(6):535–45.
- Hobson E, Craven I, Blank S. Posterior reversible encephalopathy syndrome: A truly treatable neurologic illness. *Perit Dial Int* 2012;32(6):590–4.
- Mishra A, Seril D. Posterior reversible encephalopathy syndrome after ustekinumab induction [Abstract]. *Am J Gastroenterol* 2017;112(suppl 1):S1114–5; Abstract 2027.
- Gratton D, Szapary P, Goyal K, Fakharzadeh S, Germain VÉ, Saliel P. Reversible posterior leukoencephalopathy syndrome in a patient treated with ustekinumab: Case report and review of the literature. *Arch Dermatol* 2011;147(10):1197–202.
- Dickson D, Menter A. Reversible posterior leukoencephalopathy syndrome (RPLS) in a psoriasis patient treated with ustekinumab. *J Drugs Dermatol* 2017;16(2):177–9.
- Legriél S, Lerner A, Wintermark M, Rykken JB, Gao B. Editorial: Posterior reversible encephalopathy syndrome and associated diseases. *Front Neurol* 2020;11:667.
- Haddock R, Garrick V, Horrocks I, Russell R. A case of posterior reversible encephalopathy syndrome in a child with Crohn's disease treated with infliximab. *J Crohns Colitis* 2011;5(6):623–7.
- Khanjar I, Abdulmomen I, Yahia YM, Al-Allaf AW. Posterior reversible encephalopathy syndrome (PRES) in rheumatic autoimmune disease. *Eur J Case Rep Intern Med* 2018;5(6):000866.
- Machiraju PK, Alex NM, Safinaaz, et al. Posterior reversible encephalopathy syndrome as the first manifestation of mixed connective tissue disorder: A case report. *J Med Case Rep* 2021;15:40.
- Vernia F, Di Ruscio M, Massella A, Variola A, Montanari R, Bocus P. Posterior reversible encephalopathy syndrome after azathioprine administration in severe ulcerative colitis. *ACG Case Rep J* 2021;8(1):e00521.
- Zamvar V, Sugarman ID, Tawfik RF, et al. Posterior reversible encephalopathy syndrome following infliximab infusion. *J Pediatr Gastroenterol Nutr* 2009;48:102–5.
- Chow S, Patnana S, Gupta NK. Posterior reversible encephalopathy syndrome in a patient with Crohn's disease on infliximab. *J Clin Gastroenterol* 2016;50:687.
- Jeon JS, Park SP, Seo JG. Posterior reversible encephalopathy syndrome due to hyponatremia. *J Epilepsy Res* 2014;304(1):31–3.
- Drummond AD, Williamson RM, Silverdale MA, et al. Postoperative muscle weakness in a patient recently treated with infliximab. *Anaesthesia* 2008;63:548–50.
- Zamvar V, Puntis JW. Re: "Posterior reversible encephalopathy syndrome following infliximab infusion". *J Pediatr Gastroenterol Nutr* 2010;50:353.
- Bandeo L, Rausch A, Saucedo M, et al. Convexity subarachnoid hemorrhage secondary to adalimumab in a patient with ulcerative colitis. *J Vasc Interv Neurol* 2018;10:62–4.

**Copyright:** © 2022 The Author(s). Published by Wolters Kluwer Health, Inc. on behalf of The American College of Gastroenterology. This is an open-access article distributed under the terms of the Creative Commons Attribution-Non Commercial-No Derivatives License 4.0 (CCBY-NC-ND), where it is permissible to download and share the work provided it is properly cited. The work cannot be changed in any way or used commercially without permission from the journal.