

Modified Bilateral Neurovascular Cheek Flap: Functional Reconstruction of Extensive Lower Lip Defects

Bowornsilp Chowchuen, MD,
MBA

Background: Reconstruction of extensive lower lip defects is challenging, and functional outcomes are difficult to achieve.

Methods: A modified bilateral neurovascular cheek (MBNC) flap has been described. The data of patients with cancer of the lower lip treated with wide excision and reconstructed with the MBNC flap in the Plastic Surgery Unit, Srinagarind Hospital, Khon Kaen University, from 1966 to 2012 were reviewed.

Results: Of the total of 143 patients included, 90.91% were women, and their age ranged from 32 to 100 years. All defects involved 70% or greater of the lower lip, which included oral commissure, buccal mucosa, or cheek skin and upper lip. All 20 patients who were followed up demonstrated good outcomes of intercommissural distance, interlabial distance, sulcus depth, and 2-point discrimination compared with normal lip parameters according to age group and satisfaction with treatment.

Conclusions: Reconstruction of extensive lower lip defects with the MBNC flap provided good oral competence and functional outcomes. The flap provided adequate lip height and width, with proper position of oral commissure and vermilion reconstruction. The awareness about neurovascular anatomy of the lip and cheek and gentle dissection preserve the lip function. The flap overcomes the drawbacks of Karapandzic technique, which is microstomia, and of Bernard technique, which is a tight adynamic lower lip. It can be used in defects of more than two-thirds of the lip, extending to the cheek, commissural reconstruction, and secondary reconstruction. (*Plast Reconstr Surg Glob Open* 2016;4:e721; doi: 10.1097/GOX.0000000000000680; Published online 26 May 2016.)

A study of carcinoma of the lips in Srinagarind Hospital, Khon Kaen University, showed the female to male ratio to be 7.2:1; 14, 25, 21, and 15 cases in stage I, II, III, and IV, respectively;

From the Faculty of Medicine, Division of Plastic Surgery, Department of Surgery, Khon Kaen University, Khon Kaen, Thailand.

Received for publication April 3, 2015; accepted February 23, 2016.

Copyright © 2016 The Author. Published by Wolters Kluwer Health, Inc. on behalf of The American Society of Plastic Surgeons. All rights reserved. This is an open-access article distributed under the terms of the Creative Commons Attribution-Non Commercial-No Derivatives License 4.0 (CCBY-NC-ND), where it is permissible to download and share the work provided it is properly cited. The work cannot be changed in any way or used commercially.

DOI: 10.1097/GOX.0000000000000680

and the ratio of the lower lip to the upper lip to be 5.4:1.¹ Challenges in reconstructing large lower lip defects include restoring good sensation, preserving sphincter or muscle function, opposing vermilion to vermilion of the opposite lips, creating a water-tight seal, providing sufficient opening for food and dentures, and being aesthetically pleasing.^{2,3} The majority of described techniques cannot meet the requirements of functional lip, good oral competence, and prevention of microstomia.⁴

A neurovascular cheek flap has been described as a unilateral flap by McHugh⁵ and a bilateral flap by Vatanasapt et al.⁶ The author (B.C.) has described

Disclosure: *The author has no financial interest to declare in relation to the content of this article. The Article Processing Charge was paid for by the author.*

a modified bilateral neurovascular cheek (MBNC) flap for lower lip reconstruction^{7,8} and upper lip reconstruction,^{9,10} with flap details to preserve neurovascular structure and the addition of rectangular flaps to the base of the triangular flap.

This study aimed to present design and outcomes of the MBNC flap for reconstruction of various extensive lower lip defects.

PATIENTS AND METHODS

The clinical records of patients with cancer of the lower lip reconstructed with the MBNC flap in the Plastic Surgery Unit, Srinagarind Hospital, Khon Kaen University, from 1966 to 2012 were reviewed.

The outcomes included the intercommissural distance (ICD; the distance between the commissures measured while a patient is swallowing), the interlabial distance (ILD; the straight line between the wet-dry line in the center of the upper lip and the lower lip when the mouth is widely opened), the sulcus depth (SD; the distance between the bottom of the labiogingival sulcus and the wet-dry line of the

vermilion), the lip sensitivity [the 2-point discrimination test (2PD)],^{11,12} and patient's satisfaction.

The protocol was approved by the ethics committee of Khon Kaen University.

OPERATIVE TECHNIQUE

Details of the MBNC flap have been described,⁸ such as designing the lower line of resection parallel to the vermilion border, avoiding an incision below the mental crease, and designing the part of the mucosal flap slightly higher than the commissure for resurfacing the vermilion (Fig. 1A, B). Figure 1C and D shows the final closure of the skin and mucosal flaps. Figure 2 shows intraoperative techniques of the MBNC flap.

RESULTS

Of the 143 patients included in the study, 130 were women (90.91%) and 13 were men (9.09%), and their ages ranged from 32 to 100 years (average age, 69 years). The size of tumor ranged from 2.5 to 6 cm. All defects included 70% or more of a lower

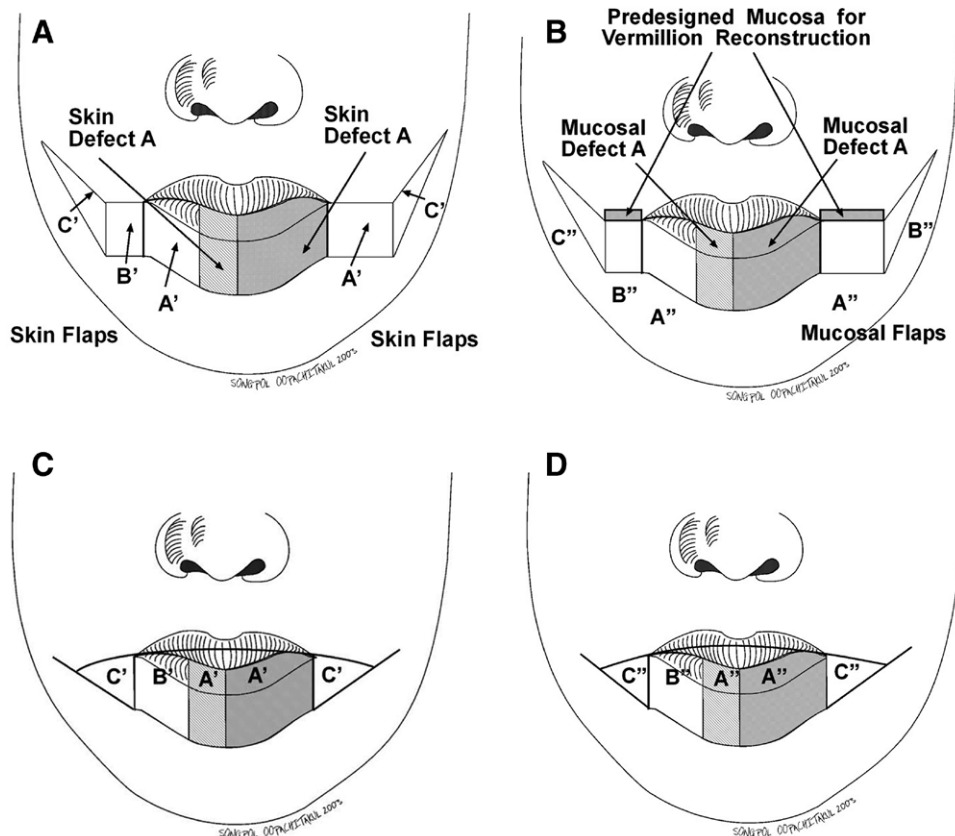


Fig. 1. The design of the skin and mucosal flaps and the final closure of the lip. A, Design of the skin flap. B, Design of the mucosal flap. C, Closure of the skin flap. D, Closure of the mucosal flap. © Journal of Medical Association of Thailand. Reprinted with permission from Chowchuen B. Modified bilateral neurovascular cheek flaps: a new technique for reconstruction of difficult and extensive lower lip defect. *J Med Assoc Thai.* 2012;95(suppl 11):S164–S167.

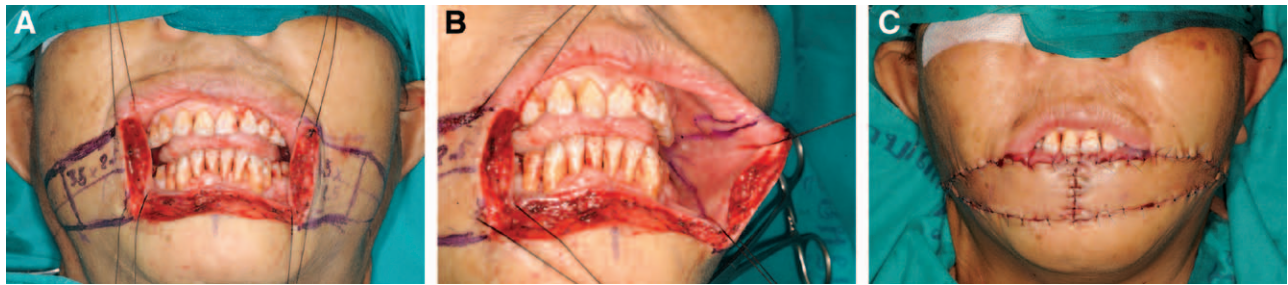

Fig. 2. Photographs show intraoperative techniques of the MBNC flap. A, Design of the skin flap. B, Design of the mucosal flap. C, Closure of the skin flap.

lip and oral commissure, buccal mucosa, cheek skin, and upper lip. There were 9 patients with a recurrent tumor, and 10 patients received preoperative radiation treatment (6.99%).

There were no immediate complications, ie, bleeding and infection, except 1 patient with wound dehiscence, which required resuturing. One patient presented with a 6-cm recurrent tumor of the lower lip after excision with the Estlander flap, and a total lower lip reconstruction was performed. There was a slight limitation of mouth opening, which was improved without additional surgery. Another patient presented with 4.5-cm lesions, and a total lower lip reconstruction was performed. There was a minimal narrow oral commissure, and a commissuroplasty was later performed 3 months after operation. No patient required scar revision. Nineteen patients had recurrent tumors and additional surgery, such as surgical excision and neck dissection. Twenty-five patients (17.48%) received postoperative radiation treatment.

Twenty patients were followed up for outcome measures with a range of 6 to 132 months [mean, 53.35 months (± 40.44)]. The defect size and comparable functional outcomes of ICD, SD, ILD, and 2PD to normal lip parameters according to different age groups are described in Table 1.

Reconstruction of Total Lower Lip Defects

A female patient, aged 74 years, presented with multiple ulcerative masses of lower lip cancer and underwent a wide excision and reconstruction with the MBNC flap and postoperative radiation therapy. At 31 months after operation, she was very satisfied with her appearance and has good functional lips (Fig. 3). The ICD, ILD, SD, and 2PD were 55, 52, 21, and 2 mm, respectively.

A female patient, aged 74 years, presented with a 4-cm lower lip lesion, and underwent a wide excision and a total lip reconstruction with the MBNC flap. At 14 months after operation, the ICD, ILD, SD, and 2PD were 62, 50, 28, and 2 mm, respectively. The patient had satisfactory appearance (Fig. 4).

Table 1. The Defect Size and Functional Outcomes of the MBNC Flap Compared with Normal Lip Parameters of Different Age Groups

Age Group (y)	No. Patients	% of Defect	ICD Mean of Patients (mm)	ICD Mean of Normal Lip Parameters* (mm)
46–60	2	85 (80–90)	53.5	66
61–75	15	86 (70–100; ± 11.49)	53.47 (± 6.51)	66
>75	3	93 (80–100)	56.33	63
Age Group (y)	No. Patients	% of Defect	ILD Mean of Patients (mm)	ILD Mean of Normal Lip Parameters* (mm)
46–60	2	85 (80–90)	35.5	47
61–75	15	86 (70–100; ± 11.49)	36.8 (± 6.73)	44
>75	3	93 (80–100)	40.67	44
Age Group (y)	No. Patients	% of Defect	SD Mean of Patients (mm)	SD Mean of Normal Lip Parameters* (mm)
46–60	2	85 (80–90)	24	26
61–75	15	86 (70–100; ± 11.49)	28.07 (± 6.40)	23
>75	3	93 (80–100)	30	25
Age Group (y)	No. Patients	% of Defect	2PD Mean of Patients (mm)	2PD Mean of Normal Lip Parameters* (mm)
46–60	2	85 (80–90)	4.13	3.4
61–75	15	86 (70–100; ± 11.49)	1.9 (± 1.08)	3.3
>75	3	93 (80–100)	3.42	3.2

*Fogel & Stranc, 1984¹¹.

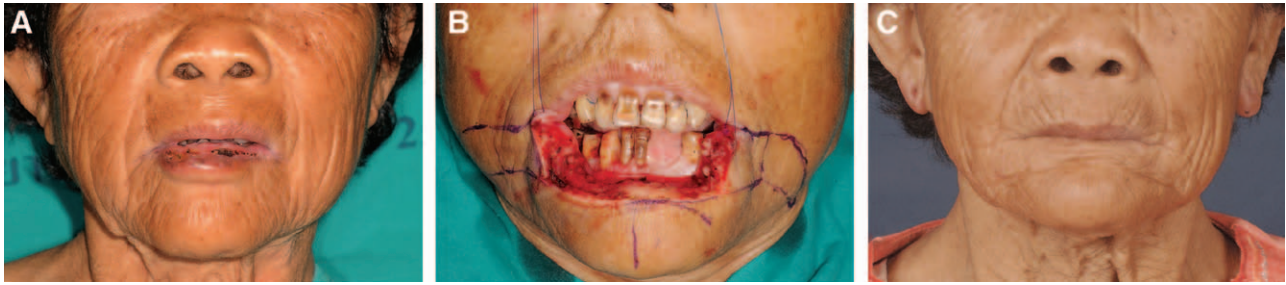

Fig. 3. Intraoperative (A) and postoperative (B) photographs of a female patient after a total lower lip reconstruction with the MBNC flap. C, At 2 years after operation, she had a satisfactory appearance and a good functional lip reconstruction.

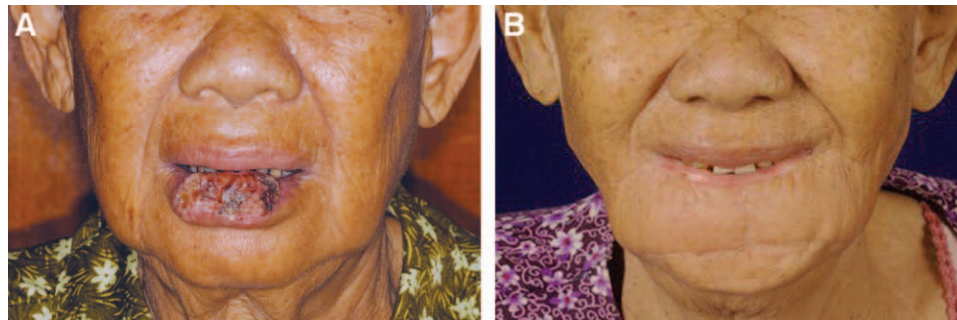


Fig. 4. Preoperative (A) and postoperative (B) photographs of a female patient after a complete lower lip reconstruction with the MBNC flap. At 2 years after operation, she had a satisfactory appearance.

Reconstruction of Defects Larger Than a Total Lip Defect

An 83-year-old female patient presented with a lower lip lesion sized 5 cm, involving oral commissure, and underwent a wide excision of lip, commissure, and right cheek and a reconstruction with the MBNC flap. At 39 months after operation, she was very satisfied with her lips (Fig. 5). The ICD, ILD, SD, and 2PD were 63, 42, 24, and 2 mm, respectively.

Reconstruction of Recurrent Cancer of a Lower Lip

A 66-year-old woman presented with recurrent carcinoma involving almost the entire lower lip after the Karapandzic fan flap reconstruction¹³ 5 years ago and underwent resection and total lip reconstruction with the MBNC flap. At 6 months after operation, the ICD, ILD, SD, and 2PD were 47, 35, 16, and 1 mm, respectively. The scar was acceptable with good oral competence (Fig. 6).

The measurement of lip function was also performed in 201 Thai volunteers (101 women and 100 men). The results of this study will be reported in another article.

DISCUSSION

A previous study reported that carcinoma of the lip in the Thai population predominantly occurred in women because of the habit of chewing betel nut and working outdoors.¹

The primary goal of lip reconstruction is a functional lip with good oral competence, which can be achieved if the sphincter is reconstructed and sensation preserved.¹⁴ The local tissue provides color and texture match, tissue with similar thickness, and skin and mucosal tissue characteristics.¹⁵ Various techniques have been proposed,^{16,17} but total or near-total defects of the lip pose challenges of a poor aesthetic outcome and compromised oral competence. The Karapandzic flap provides lip competence with a sensate, mobile lip, but its primary drawback is microstomia.^{14,18} Bernard's¹⁹ technique uses transposition of full-thickness flaps and requires the excision of 3 cutaneous triangles. Although microstomia can be avoided, there is no functional orbicularis with a tight adynamic lower lip because of denervation.¹⁸ Many reconstructive techniques do not provide mucosal replacement of lip vermilion. The free flap techniques produce less cosmetic and functional results.²⁰

The MBNC provides adequate lip height with muscular part by the rectangular flap added to the base of the triangular flap. The mental crease defines the inferior margin of the flap.¹⁵ Injury to the parotid duct ampulla is avoided by preserving it outside or inside the flap. The flap design incorporates the remaining lower lip, the orbicularis oris muscle, which forms a sphincteric ring around the mouth¹⁵ and cheek musculature. A full-thickness incision was

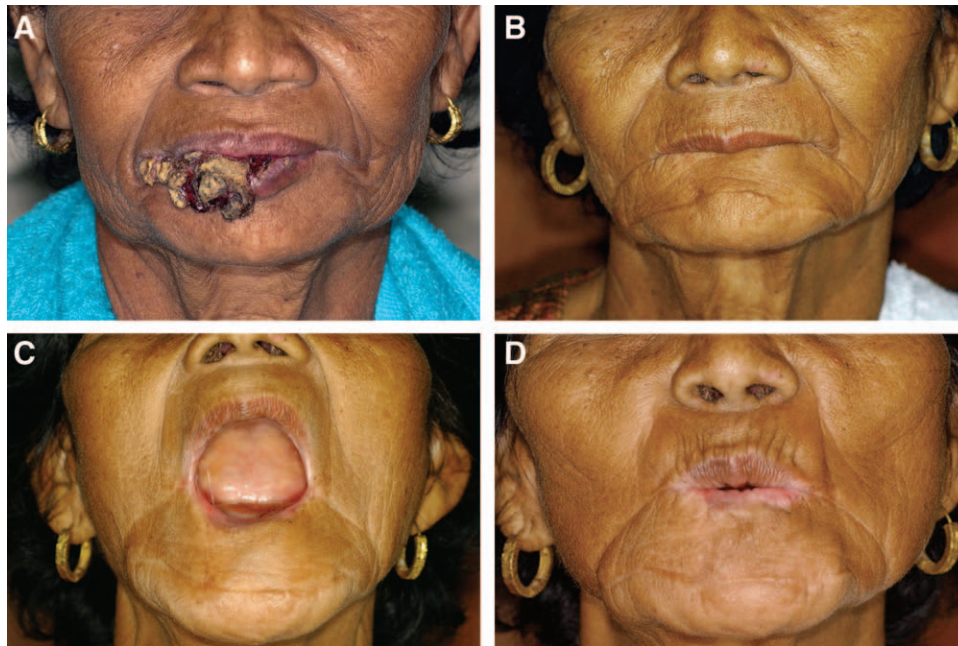

Fig. 5. Preoperative (A) and postoperative (B–D) photographs of a female patient after a total lower lip reconstruction with the MBNC flap. Fifteen months after operation, she had a satisfactory appearance and a good functional lip. Figures 5B–D © the Royal College of Surgeons of Thailand and are reprinted with permission from Chowchuen B. Reconstructive surgery following resection of head and neck tumor. In: Chowchuen B, Jenwitheesuk K, Chuangsuwanich A, eds. *The Book of Progress in Surgery*. Bangkok: Bangkok Medical Journal Publisher; 2011:266.

made at the medial edge of the skin and mucosal flap with preservation of branches of arterial supply to the lower lip and was not made lateral to the facial artery. The lateral incision was deep to subcutaneous and submucosal tissue with blunt dissection of subcutaneous and cheek muscular tissue to preserve neurovascular structure, the major depressor muscles of lip¹⁵ and the buccinators²¹ and to allow better advancement of lower lip flaps. For adequate lip width and preservation of original position of the oral commissure, the modiolus is reconstructed by suturing muscle of the flap to the muscle of the upper lip just lateral to the commissure. The buccal and mandibular branches of the facial nerves leave the parotid near the parotid-masseteric fascia in the same plane as the parotid duct²² to supply the orbicularis oris, buccinators, and lip depressors. Branches of the maxillary and mandibular divisions of the trigeminal nerve for sensation to the lower lip are preserved by careful blunt dissection. The lateral edge of the skin and mucosal flaps are approximated using a V-Y technique.¹⁰ The designed mucosa in the mucosal flap above the oral commissure is used to reconstruct the red vermilion.

The facial artery hooks around the lower border of the mandible at the anterior edge of the masse-

ter muscle and passes upward and forward to near the oral commissure.²³ The inferior labial artery and horizontal labiomental artery (HLA) are the main arteries of the MBNC flap.^{24,25} Their location, course, and dimensions of the lower lip are not constant.²⁶ Knowledge about their location is important to avoid complications.²⁷ The HLA branches from the facial artery in the middle of the lower lip and the inferior labial artery branches at the level of the oral commissure. In most cases, the HLA runs under the depressor anguli oris muscle and passes through the depressor labii inferioris and orbicularis oris muscles^{28,29} and can be preserved in the lower lip inferior to the oral commissure, and inclined gradually toward the lower lip. Careful dissection with precaution of variance in anatomical landmark will assure flap viability and avoid injury to these vessels. A number of facial artery perforators located predominantly at the level of the oral commissure are preserved in the flap and can be used as a pedicle flap.³⁰

The MBNC flap resolves the challenges of aesthetic outcomes and provision of good oral competence with a sensate and mobile lip. The functional outcome was comparable with normal lip parameters described in a study.¹¹ The

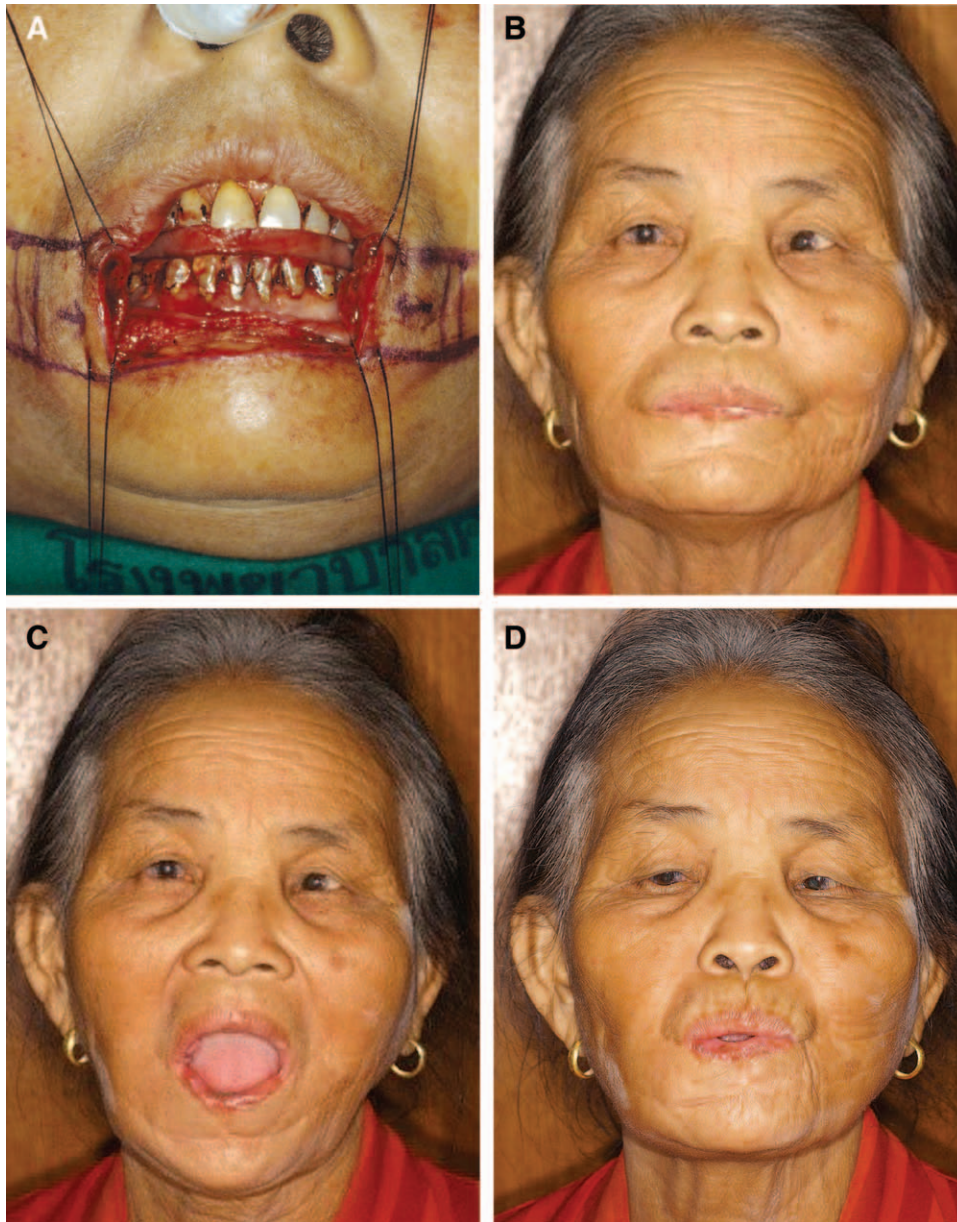


Fig. 6. Postoperative (A) and 6-month postoperative (B–D) photographs of a female patient presented with recurrent carcinoma of the entire lower lip after resection and reconstruction with the MBNC flap. Figure 6A © Journal of Medical Association of Thailand. Reprinted with permission from Chowchuen B. Modified bilateral neurovascular cheek flaps: a new technique for reconstruction of difficult and extensive lower lip defect. *J Med Assoc Thai.* 2012;95(suppl 11):S164–S167.

flap preserved neurovascular tissue similar to the Karapandzic flap,¹⁴ but it overcomes microstomia, the limitation of the Karapandzic flap caused by change of position of the oral commissure.^{14,15,18} The flap overcomes the limitations of Webster-Bernard's technique,¹⁹ which are chronic tension of closure and a tight adynamic lip.^{15,18} When the lip defect extends to a large portion of cheek or buccal mucosa, there may not be enough local tissues to use the MBNC flap.

The limitations of this retrospective study are as follows: patient records collected were for a long period of time (over decades), difficulty of the long-term follow-ups, economy, and death of a number of patients or recurrent tumors in many because of the advanced stage.

CONCLUSIONS

Good functional and aesthetic outcomes and patient satisfaction support clinical applications of

the MBNC flap. It can be used in extensive lower lip defects, such as defects of more than two-thirds of the lip, defects extending to the cheek, commissural reconstruction, both upper and lower lip reconstruction, and the secondary reconstruction of various difficult lip defects. With the recent modification, the cheek incision will be placed along the natural skin crease and provides a better scar.

Bowornsilp Chowchuen, MD, MBA
Faculty of Medicine
Division of Plastic Surgery
Department of Surgery
Khon Kaen University
Mitraparb Road
Khon Kaen 40002, Thailand
E-mail: bowcho@kku.ac.th

ACKNOWLEDGMENTS

The author thanks Dr. Radhakrishnan Muthukumar for assistance with English language presentation, Mr. Songpol Oopachitakul for illustration, Dr. Pattana Ongkasuwan for assistance of clinical data, and support from the Center of Cleft Lip-Palate and Craniofacial Deformities (Tawanchai Center), Khon Kaen University.

PATIENT CONSENT

The patient in figure 6 provided written consent for the use of her image.

REFERENCES

- Komthong R, Taksaphan P, Chowchuen B, et al. Carcinoma of the lip in Srinagarind Hospital. *Thai J Surg*. 1989;10:103–106.
- Panje WR. Lip reconstruction. *Otolaryngol Clin North Am*. 1982;15:169–178.
- Mazzola RF, Lupo G. Evolving concepts in lip reconstruction. *Clin Plast Surg*. 1984;11:583–617.
- Zide BM. Deformities of the lips and cheeks. In: McCarthy JG, ed. *Plastic Surgery*. Vol. 3. Philadelphia, PA: W.B. Saunders; 1990:2009–2056.
- McHugh M. Reconstruction of the lower lip using neurovascular island flap. *Br J Plast Surg*. 1977;30:316–318.
- Vatanasapt V, Chadbunchachai W, Taksaphan P, et al. Bilateral neurovascular cheek flaps for one stage lower lip reconstruction. *Br J Plast Surg*. 1987;40:173–175.
- Chowchuen B. Cancer of the lip: surgeons comment. *J Plast Reconstr Aesthetic Surg Thai*. 1996;2:53–59.
- Chowchuen B. Modified bilateral neurovascular cheek flaps: a new technique for reconstruction of difficult and extensive lower lip defect. *J Med Assoc Thai*. 2012;95(suppl 11):S164–S167.
- Chowchuen B. Modified bilateral neurovascular cheek flaps: functional reconstruction of major upper lip defects. *J Plast Reconstr Aesthetic Surg Thai*. 1997;3:33–47.
- Chowchuen B, Surakunprapha P. Modified bilateral neurovascular cheek flaps: a new technique for reconstruction of extensive upper lip defects. *Ann Plast Surg*. 2001;47:64–69.
- Fogel ML, Stranc MF. Lip function: a study of normal lip parameters. *Br J Plast Surg*. 1984;37:542–549.
- Stranc MF. Lip reconstruction. In: Stark RB, ed. *Plastic Surgery of the Head and Neck*. Vol. 2. New York, NY: Churchill Livingstone; 1987:1242–1257.
- Chowchuen B. Reconstructive surgery following resection of head and neck tumor. In: Chowchuen B, Jenwitheesuk K, Chuangsuwanich A, eds. *The Book of Progress in Surgery*. Bangkok: Bangkok Medical Journal Publisher; 2011:266.
- Karapandzic M. Reconstruction of lip defects by local arterial flaps. *Br J Plast Surg*. 1974;27:93–97.
- Langstein HN, Robb GL. Lip and perioral reconstruction. *Clin Plast Surg*. 2005;32:431–45, viii.
- Neligan PC. Strategies in lip reconstruction. *Clin Plast Surg*. 2009;36:477–485.
- Abbe R. A new plastic operation for the relief of deformity due to double harelip. *Plast Reconstr Surg*. 1986;42:481.
- Salgarelli AC, Sartorelli F, Cangiano A, et al. Treatment of lower lip cancer: an experience of 48 cases. *Int J Oral Maxillofac Surg*. 2005;34:27–32.
- Bernard, C. Cancer de la levre inférieure; restauration a l'aide de lambeaux quadrilateres-lateraux querison. *Scalpel, Liège*. 1851–1853;5:162–165.
- Neligan PC. Cheek and lip reconstruction. In: Neligan PC, ed. *Plastic Surgery*. Vol. 3. 3rd ed. London: Elsevier Saunders; 2013:254–277.
- Matros E, Pribaz JJ. Reconstruction of acquired lip deformities. In: Thorne CH, ed. *Grabb and Smith's Plastic Surgery*. 7th ed. Philadelphia, PA: Wolters Kluwer/Lippincott Williams & Wilkins; 2014:372–383.
- Wijayaweera CJ, Amaratunga NA, Angunawela P. Arrangement of the orbicularis oris muscle in different types of cleft lips. *J Craniofac Surg*. 2000;11:232–235.
- Zucker MZ, Gur Eyal, Hussian G, et al. In: Neligan PC, ed. *Plastic Surgery*. Vol. 3. 3rd ed. London: Elsevier Saunders; 2013:278–306.
- Pinar YA, Bilge O, Govsa F. Anatomic study of the blood supply of perioral region. *Clin Anat*. 2005;18:330–339.
- Standing S. *Gray's Anatomy: The Anatomical Basis of Clinical Practice*. 40th edition. Edinburgh: Churchill Livingstone; 2008:490.
- Whetzel TP, Mathes SJ. Arterial anatomy of the face: an analysis of vascular territories and perforating cutaneous vessels. *Plast Reconstr Surg*. 1992;89:591–603; discussion 604.
- Edizer M, Mağden O, Tayfur V, et al. Arterial anatomy of the lower lip: a cadaveric study. *Plast Reconstr Surg*. 2003;111:2176–2181.
- Ahmadi SK, Rahpeyma A, Rezvani HN. Vermilion lower lip cross flap—an anatomic study on 22 fresh cadavers. *Ann Maxillofac Surg*. 2012;2:107–110.
- Lee SH, Lee HJ, Kim YS, et al. What is the difference between the inferior labial artery and the horizontal labio-mental artery? *Surg Radiol Anat*. 2015;37:947–953.
- Demirseren ME, Afandiyev K, Ceran C. Reconstruction of the perioral and perinasal defects with facial artery perforator flaps. *J Plast Reconstr Aesthet Surg*. 2009;62:1616–1620.