

Segmental alopecia areata affecting the scalp, eyebrow, and lash line: A novel presentation



Claire Doyle, MB, BCh, BAO,^a Marta Costa Blasco, MB, BCh, BAO,^a Mark McCabe, MB, BCh, BAO,^b Anastasia Therianou, MD, PhD,^c and Richard Edward Watchorn, MB, BCh, BAO, MD^a

Key words: alopecia areata; segmental alopecia.

INTRODUCTION

Alopecia areata (AA) affects 1 to 2 percent of the population and is often associated with autoimmune conditions such as vitiligo, thyroid disease, rheumatoid arthritis, and type 1 diabetes mellitus.¹ Reported patterns of AA include a single patch of hair loss, multiple patches of hair loss, reticular, ophiasis, sisaipho, alopecia totalis, and alopecia universalis.² Alopecia presenting in a linear distribution is rare with 2 cases in the literature of linear AA of the scalp.³ Linear alopecia has more frequently been associated with lupus erythematosus profundus.⁵

CASE REPORT

A 24-year-old woman presented with a 3-year history of localized hair loss involving a linear streak on her right forehead, right medial eyebrow, and right medial lash line. The hair loss started on the scalp and progressed to involve the eyebrow and lash line over 6 months. She was healthy and took no regular medication. There was no associated pain or itch in the affected areas. She had no family history of AA or autoimmune disease. Examination revealed nonscarring alopecia of the right anterior scalp, right medial eyebrow, and right medial right lash line in a linear pattern (Fig 1). The skin in the affected areas appeared healthy, and no perifollicular erythema or scaling was observed. Hair pull test was negative. Dermoscopic examination revealed preserved follicular openings. Yellow dots were visible as were exclamation point hairs and broken hairs (Fig 1).

Abbreviation used:

AA: alopecia areata

There was no evidence of vellus hairs. She had undergone tattooing of her medial eyebrow to camouflage the affected area (Fig 1). There was no hair loss elsewhere, and her nails appeared healthy. Full blood count, renal profile, liver profile, iron studies, ferritin, vitamin B12, folate, vitamin D, and thyroid function tests were normal. Connective tissue disease screen was negative. Complement levels were normal. A punch biopsy from the affected area on her scalp revealed a reduction in the number of hair follicles with a distortion in the appearance of residual follicles. Follicular plugging was seen. There was mild perifollicular chronic inflammation without interface changes (Fig 2). Histology was reported to be in keeping with AA. One ml of triamcinolone (10 mg/ml) was injected across the affected areas of the scalp and eyebrow. At 3-month review, no response was observed. A further injection of 1-ml intralesional triamcinolone 10 mg/ml across the affected area of her scalp and eyebrow did not yield a response on review 2 months later.

DISCUSSION

Characteristic dermoscopic features of hair loss in AA include yellow dots, broken hairs, exclamation mark hairs, and black dots among others.⁴ In our

From the Department of Dermatology, Beaumont Hospital, Dublin, Ireland^a; Department of Histopathology, Beaumont Hospital, Dublin, Ireland^b; and Imperial College, NHS Healthcare Trust, London, United Kingdom.^c

Funding sources: None.

IRB approval status: Not applicable.

Consent: The patient consented to the publication of her case, including the clinical images. Patient consent forms are on file.

Correspondence to: Claire Doyle MB, BCh, BAO, Department of Dermatology, Beaumont Hospital, Beaumont Rd, Dublin 9, Ireland. E-mail: doylec32@tcd.ie.

JAAD Case Reports 2022;29:43-5.
2352-5126

© 2022 Published by Elsevier on behalf of the American Academy of Dermatology, Inc. This is an open access article under the CC BY-NC-ND license (<http://creativecommons.org/licenses/by-nc-nd/4.0/>).

<https://doi.org/10.1016/j.jidcr.2022.08.026>

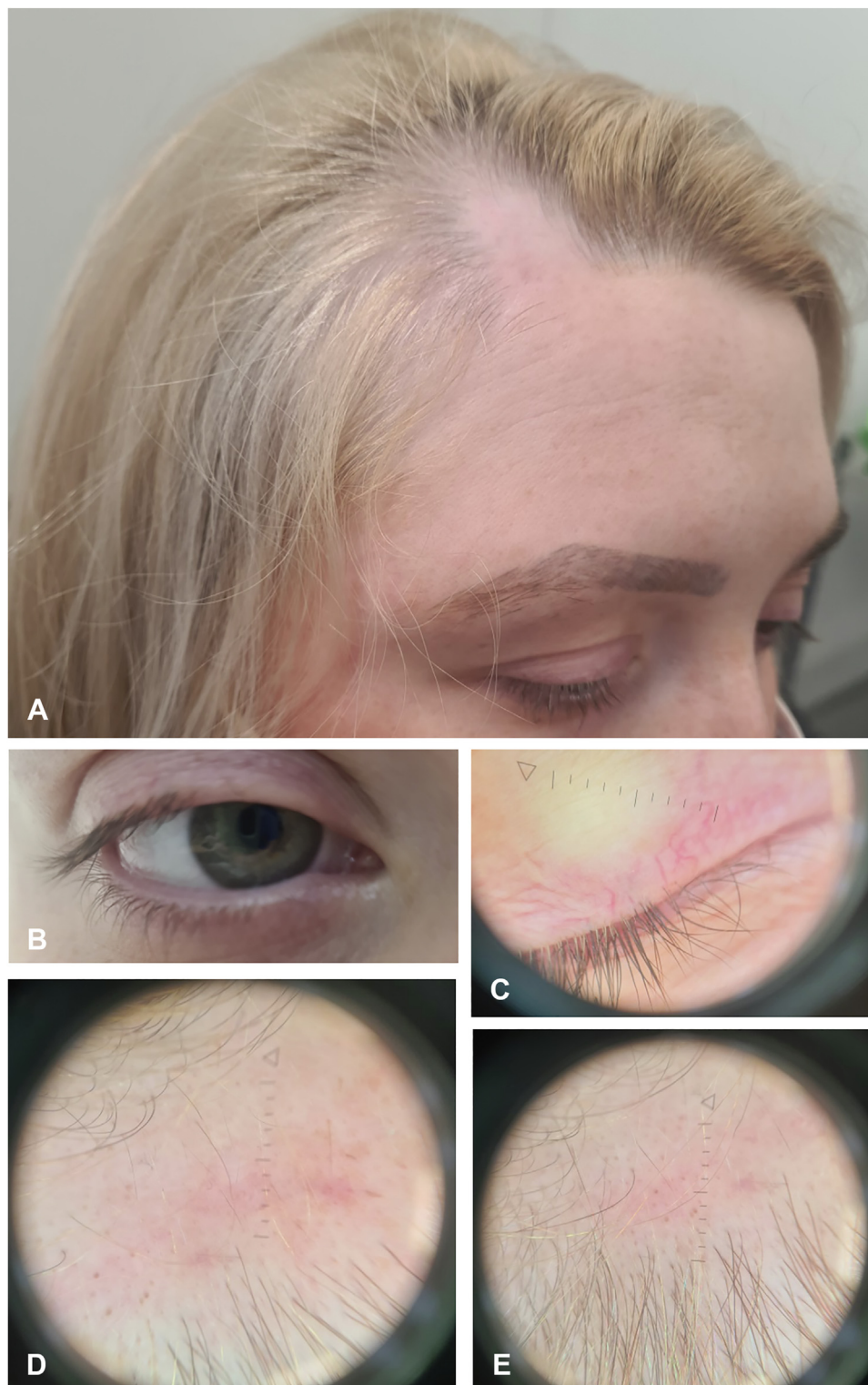

Fig 1. **A**, Linear streak of alopecia right forehead, right medial eyebrow, right medial lash line. **B**, Loss of medial lash line close-up image. **C**, Dermoscopic view showing loss of medial eyelashes. **D**, Dermoscopic image highlighting yellow dots and exclamation point hairs. **E**, Dermoscopic image of scalp

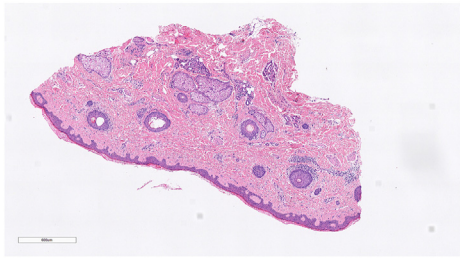


Fig 2. H&E stain 10x magnification showing a reduction in the number of hair follicles with distortion in the appearance of residual follicles. Mild perifollicular chronic inflammation is seen without evidence of interface changes.

case, dermoscopic examination of the scalp and eyebrows revealed both of these features. Segmental vitiligo is characterized by early onset, rapid stabilization, and unilateral distribution.⁵ The etiology of segmental vitiligo remains elusive. Possibilities proffered include neuronal mechanisms, somatic mosaicism, a specific migration pattern of cytotoxic T cells, or a combination of some or all of the proposed theories.⁵ A similar pathomechanism may account for the segmental nature of the alopecia observed in our case. Segmental vitiligo is less responsive to treatment with topical steroids, topical calcineurin inhibitors, and phototherapy. However, there is some evidence that treatment early in the course of disease is more effective.⁶ The fact that segmental vitiligo is less responsive to treatment may also

indicate a similar pathomechanism as in our case, treatment has not been successful to date.

To our knowledge, this case is the first case of AA affecting the scalp, eyebrow, and lash line in such a unilateral linear distribution. This may reflect the complex pathogenesis associated with AA. It is important to consider AA as a differential diagnosis for alopecia presenting in a linear distribution.

Conflicts of interest

None disclosed.

REFERENCES

1. Juárez-Rendón KJ, Rivera Sánchez G, Reyes-López MÁ, et al. Alopecia areata: current situation and perspectives. *Arch Argent Pediatr.* 2017;115:e404-e411.
2. Shetty S, Rao R, Kudva RR, Subramanian K. Linear alopecia areata. *Int J Trichology.* 2016;8(3):144-145. <https://doi.org/10.4103/0974-7753.189017>
3. Yu L, Lu Z. Linear alopecia areata. *JAAD Case Rep.* 2018;4(10):1072-1073. <https://doi.org/10.1016/j.jdc.2018.08.015>
4. Waśkiel A, Rakowska A, Kurzeja M, et al. The value of dermoscopy in diagnosing eyebrow loss in patients alopecia areata and frontal fibrosing alopecia. *J Eur Acad Dermatol Venereol.* 2018;33(1):213-219. <https://doi.org/10.1111/jdv.15279>
5. Van Geel N, Mollet I, Brochez L, et al. New insights in segmental vitiligo: case report and review of theories. *Br J Dermatol.* 2012;166:240-246. <https://doi.org/10.1111/j.1365-2133.2011.10650.x>
6. Park J-H, Park SW, Lee D-Y, Lee J-H, Yang J-M. The effectiveness of early treatment in segmental vitiligo: retrospective study according to disease duration. *Photodermatol Photoimmunol Photomed.* 2013;29:103-105. <https://doi.org/10.1111/phpp.12029>