



## Case Report

# Atypical herpes vasculitis in a leukemic patient: An unusual presentation



Jade Cury-Martins<sup>a,\*</sup>, Marcelo Bellesso<sup>b</sup>, Mirian Nacagami Sotto<sup>a</sup>,  
Jose Antonio Sanches<sup>a</sup>

<sup>a</sup> Hospital das Clínicas, Faculdade de Medicina da Universidade de São Paulo (HC FMUSP), São Paulo, SP, Brazil

<sup>b</sup> Instituto Hemomed, São Paulo, SP, Brazil

## ARTICLE INFO

## Article history:

Received 26 April 2018

Accepted 9 July 2018

Available online 7 August 2018

## Introduction

Acute lymphoid leukemia (ALL) is a heterogeneous hematological neoplasm characterized by a proliferation of immature lymphoid cells. It is the most common form of childhood leukemia, but, in contrast, represents approximately 20% of all leukemias among adults.<sup>1,2</sup>

In these patients, as well as in those with other lymphoproliferative malignancies, immunosuppression related to the disease itself or to its treatment leads to a higher frequency of infectious complications.<sup>3,4</sup> Varicella-zoster (VZV) and herpes-simplex virus (HSV) are among the most common infections in this scenario and are often associated to atypical clinical presentations, posing a diagnostic challenge and delaying adequate treatment.

We describe a case of an adult ALL patient with atypical, chronic, cutaneous lesions due to herpes vasculitis.

## Case report

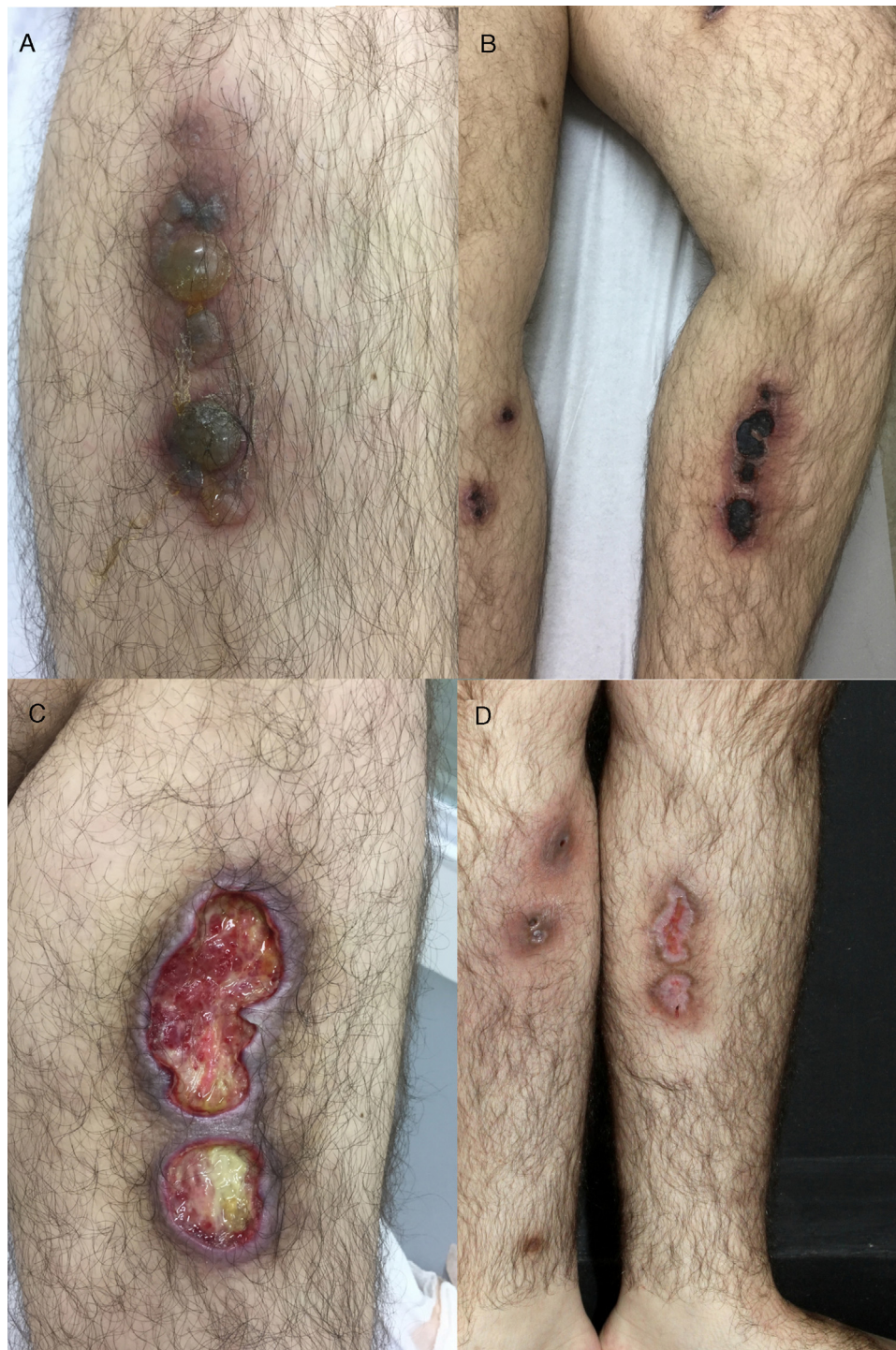A 26-year-old male with a Philadelphia-negative ALL was treated with eight cycles of hyper-CVAD (hyperfractionated cyclophosphamide, vincristine, doxorubicin and dexamethasone). He had minimal residual disease negativity and was on maintenance therapy with dose-adjusted POMP regimen due to a prior grade 4 neutropenia (prednisone 200 mg days 1–5, vincristine 2 mg IV day 1, methotrexate 40 mg IM weekly and 6-mercaptopurine 50 mg orally days 1–28). Prophylaxis for pneumocystis (sulfamethoxazol-trimetoprim), fungal infections (fluconazole) and herpes (acyclovir) was used during the induction phase and thereafter only while the patient was neutropenic during the first two cycles of maintenance phase. In the 24th cycle, he developed multiple tender, round, indurated deep nodules on both legs and thighs, with no history of ulceration and no systemic symptoms. He was

\* Corresponding author.

E-mail address: [jadecury@yahoo.com.br](mailto:jadecury@yahoo.com.br) (J. Cury-Martins).

<https://doi.org/10.1016/j.htct.2018.07.001>

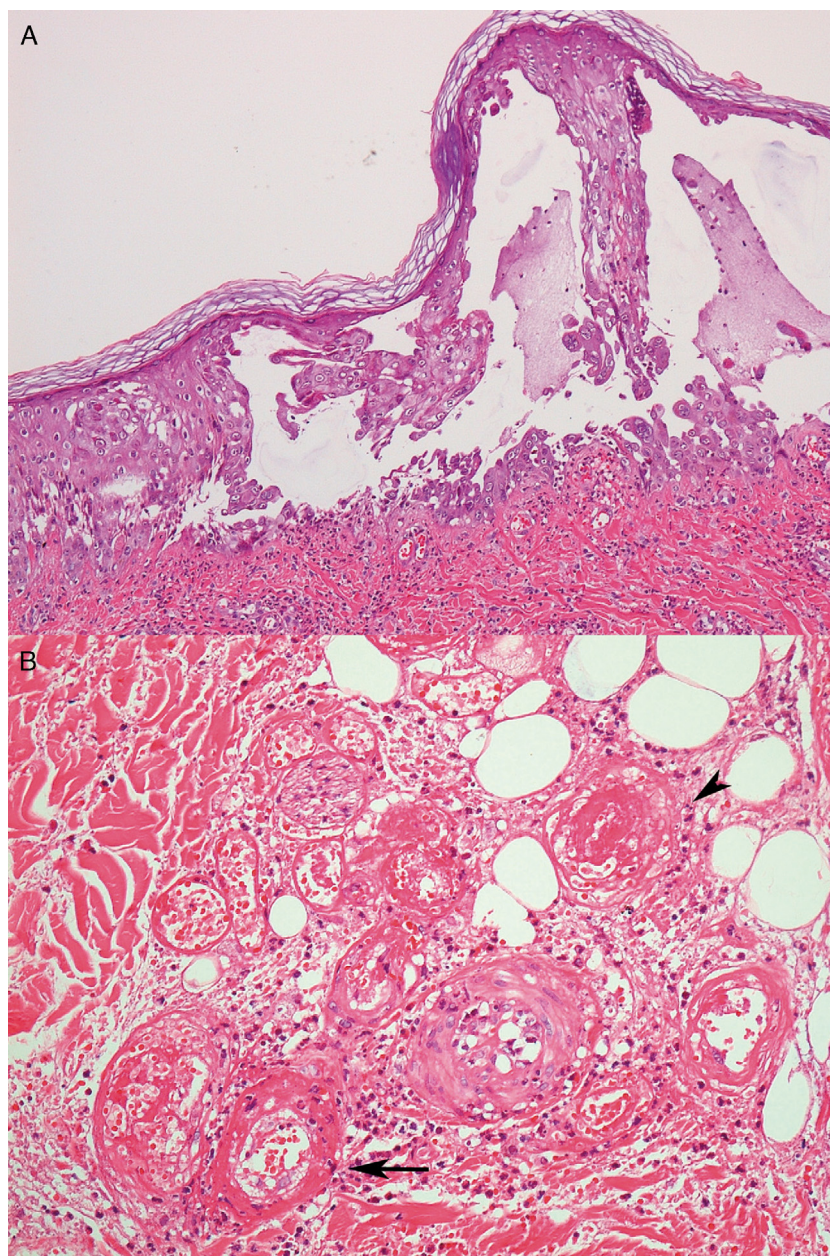
2531-1379/© 2018 Associação Brasileira de Hematologia, Hemoterapia e Terapia Celular. Published by Elsevier Editora Ltda. This is an open access article under the CC BY-NC-ND license (<http://creativecommons.org/licenses/by-nc-nd/4.0/>).



**Figure 1 – (A) Deep infiltrated lesions with tense blisters on the surface; (B) after starting therapy with acyclovir, lesions became necrotic and ulcerated covered with an adherent black eschar; (C) lesions evolved to extensive deep ulcerated areas; (D) three months after initiating therapy, almost complete healing with residual atrophic scars.**

treated with oral tetracyclines and topical antibiotics with the presumptive diagnosis of erythema nodosum; no improvement was seen. Two months later, the deep infiltrated lesions started to develop tense blisters on the surface (Fig. 1A). The patient had no signs of extracutaneous involvement. The complete blood count was normal (hemoglobin 13.7 g/dL,

leukocyte count  $2 \times 10^9 \text{ L}^{-1}$ , neutrophil count  $1.3 \times 10^9 \text{ L}^{-1}$  and platelet count  $153 \times 10^9 \text{ L}^{-1}$ ). No imaging was done at the time. Since he was in apparent remission, it was important to exclude leukemic cutaneous infiltration and to differentiate from other dermatologic conditions such as neutrophilic dermatosis (Sweet syndrome or pyoderma gangrenosum),



**Figure 2 – Intraepidermal blister displaying ballooning and acantholytic keratinocytes and multinucleated cells with nuclear molding. (A) Fibrinoid necrosis (arrow) and thrombosis (arrowhead) of vessels of the hypodermis. (B) Hematoxylin and eosin stain;  $\times 200$  original magnification.**

or atypical bacterial or fungal infection. Therefore, a punch biopsy was taken. Histology revealed an intraepidermal blister with viral cytopathic changes characteristic of herpes HSV/VZV infection (keratinocyte alterations with ballooning, acantholysis, marginalization of the nuclear chromatin and multinucleation; Fig. 2a). Leukocytoclastic vasculitis of the dermal vessels and vascular fibrinoid necrosis of the hypodermis could be seen; thrombosis and adipocyte necrosis were present (Fig. 2b). Viral culturing, staining with monoclonal antibodies and polymerase chain reaction (PCR) of skin and blood samples were not available to differentiate between HSV and VZV. Cytomegalovirus infection (CMV) was excluded due to the different cytopathic alterations related to this infection.

Cultures for bacterial, mycobacterial and fungal infections were negative. Plasma PCR for HSV, VZV and CMV was not performed.

With these findings, a diagnosis of herpes vasculitis (either HSV or VZV) with thrombosis was made, and the patient was started on IV acyclovir 10 mg/kg every 8 h for 7 days, with maintenance with oral acyclovir 400 mg three times daily thereafter. Some days after the initial therapy, lesions started to ulcerate, forming confluent necrotic plaques covered with an adherent black eschar which evolved to extensive deep ulcerated areas, as shown in Fig. 1B and C. Another biopsy was performed that showed extensive necrosis and thrombosis of larger vessels, with no signs of viral infection, so the patient

was kept on acyclovir prophylaxis (400 mg q12 h) with complete healing and residual atrophic scars after eight months (Fig. 1D).

## Discussion

Classically, cutaneous herpes virus lesions are described as painful, grouped vesicles on an erythematous base (in the case of herpes zoster, lesions follow a dermatome distribution).<sup>6</sup> Lesions usually resolve after 7–14 days, even without treatment. Immunocompromised patients, e.g. those with HIV infection or neoplasia, especially hematological malignancies,<sup>7</sup> tend to have a higher incidence of infections, with herpes being one of the most frequent. In these patients, lesions can become more invasive, might have a longer duration, with sometimes a chronic evolution and are an important cause of morbidity. They also have a greater potential for visceral dissemination and therefore, increased mortality.<sup>3–5</sup>

By histology, both herpes simplex and varicella zoster virus share similar aspects. Biopsy often reveals vesicles or ulcers with keratinocyte ballooning, acantholysis and necrosis with viral cytopathic changes such as multinucleated cells with nuclear molding.<sup>6</sup> In the scenario of immunosuppression, atypical findings, such as dermal or deeper involvement, not only epidermal involvement might occur. Different techniques might be used to differentiate between herpes simplex (HSV) and varicella zoster virus (VZV) such as viral culturing, staining with monoclonal antibodies and PCR of biopsy specimens. Unfortunately, none of these were available for the case illustrated here, so the differentiation between HSV and VZV could not be made.

Cutaneous manifestations of CMV infection are not frequent. The cytopathic alteration related to CMV is the characteristic owl's eye intranuclear inclusion generally observed in endothelial cells and the pericytes of dermal vessels, not of keratinocytes. Thus, this differential diagnosis was ruled out based on the histological findings.

Many infections, including herpes, can trigger a vasculitis, more often due to an indirect mechanism where the agent stimulates an immune response against blood vessels, usually manifested as a palpable purpura. However, deeper and sometimes even obliterative vasculitis of larger vessels directly induced by the virus, as illustrated in the current case, are rare, with only a few similar cases reported in the literature.<sup>4,8,9</sup>

It is a matter of debate whether these atypical clinical and histological findings are related only to a more severe course, or, if the impaired cell-mediated immunity of these individuals, important for the local immune response against the agent, would cause a different path of dissemination and pathogenesis.<sup>4</sup> Most of the times, after reactivation and spreading through the peripheral nerves, the virus primarily infects the epidermis with the main replication being within keratinocytes causing typical lesions and histological

findings.<sup>10</sup> The fact that, in our patient, lesions started as deep infiltrated nodules and only months later developed epidermal involvement goes in favor of this theory.

## Conclusion

The current case demonstrates an example of a hematological patient, for whom the atypical presentation led to a delay in the correct diagnosis and, therefore, delayed the appropriate treatment. As the main limitation, we could not differentiate between herpes simplex and varicella zoster infection.

In conclusion, we highlight the importance of keeping herpetic infections on the differential diagnosis on immunosuppressed individuals, even when cutaneous lesions are not typical. An early and correct diagnosis and prompt treatment can avoid fatal outcomes related to viral dissemination.

## Conflicts of interest

The authors declare no conflicts of interest.

## REFERENCES

- Jabbour EJ, Faderl S, Kantarjian HM. Adult acute lymphoblastic leukemia. *Mayo Clin Proc.* 2005;80(11):1517–27.
- Dores GM, Devesa SS, Curtis RE, Linet MS, Morton LM. Acute leukemia incidence and patient survival among children and adults in the United States, 2001–2007. *Blood.* 2012;119(1):34–43.
- Khera P, Haught JM, McSorley J, English JC 3rd. Atypical presentations of herpesvirus infections in patients with chronic lymphocytic leukemia. *J Am Acad Dermatol.* 2009;60(3):484–6.
- Erhard H, Runger TM, Kreienkamp M, Muller J, Muller-Hermelink HK, Brocker EB. Atypical varicella-zoster virus infection in an immunocompromised patient: result of a virus-induced vasculitis. *J Am Acad Dermatol.* 1995;32 5 (Pt 2):908–11.
- Piaserico S, Sandini E, Peserico A, Alaibac M. Cutaneous viral infections in organ transplant patients. *G Ital Dermatol Venereol.* 2014;149(4):409–15.
- Hoyt B, Bhawan J. Histological spectrum of cutaneous herpes infections. *Am J Dermatopathol.* 2014;36(8):609–19.
- Tran TN, Ray GT, Horberg MA, Yawn BP, Castillo AL, Saddier P, et al. Complications of herpes zoster in cancer patients. *Scand J Infect Dis.* 2014;46(7):528–32.
- Cohen C, Trapuckd S. Leukocytoclastic vasculitis associated with cutaneous infection by herpesvirus. *Am J Dermatopathol.* 1984;6(6):561–5.
- Gilson IH, Barnett JH, Conant MA, Laskin OL, Williams J, Jones PG. Disseminated ecthymatous herpes varicella-zoster virus infection in patients with acquired immunodeficiency syndrome. *J Am Acad Dermatol.* 1989;20(4):637–42.
- Orfanos CE, Runne U. Virus propagation, virus replication and virus elimination in the human skin in zoster. *Hautarzt.* 1975;26(4):181–90.