

Case Report

Renal Carcinoma and Kartagener Syndrome: An Unusual Association

Hamza Dergamoun , **Abdelilah El Alaoui, Imad Boualaoui, Hachem Sayegh, Lounis Benslimane, and Yassine Nouini**

Department of Urology A, Ibn Sina Hospital, Mohammed V University, Rabat, Morocco

Correspondence should be addressed to Hamza Dergamoun; hamza.dergamoun@gmail.com

Received 20 March 2020; Accepted 1 May 2020; Published 16 May 2020

Academic Editor: Giorgio Carmignani

Copyright © 2020 Hamza Dergamoun et al. This is an open access article distributed under the Creative Commons Attribution License, which permits unrestricted use, distribution, and reproduction in any medium, provided the original work is properly cited.

Background. The association of renal cell carcinoma and Kartagener's syndrome is unusual, and only eleven cases have been reported in the literature. The purpose of this work is to analyze this unusual association of Kartagener's syndrome and renal cell tumor and to study the main diagnostic and therapeutic aspects through our observation and review of the literature. *Case Presentation.* We report the case of a 50-year-old patient, with a history of recurrent respiratory infections, in whom a renal tumor was simultaneously diagnosed with Kartagener's syndrome, represented by situs inversus, bronchiectasia, and chronic sinusitis. The patient was treated by partial nephrectomy, and the histological examination showed a clear cell carcinoma. Through this observation and a review of the literature, we try to analyze this association as well as the main diagnostic and therapeutic aspects. *Conclusion.* The association of situs inversus and renal cell carcinoma is very rare—preoperative assessment and anatomy knowledge are crucial for a better adaptation of the surgical technique.

1. Background

Kartagener's syndrome is rare. Bronchiectasis, chronic sinusitis, and situs inversus are the classic three abnormalities. This syndrome is a part of primary ciliary dyskinesias (PCD), a rare genetic group of diseases that involve a constitutional abnormality of the cilia leading to respiratory damages [1, 2]. More rarely, PCD may be associated with cardiac, renal, or sensory defects, resulting in complex phenotypes. There is no known evidence that situs inversus increases the risk of malignancy [3]. The association of renal cell carcinoma and Kartagener's syndrome is unusual, and only 11 cases have been reported in the literature.

We report a case of renal cell carcinoma (RCC) discovered in a patient with Kartagener's syndrome. According to our knowledge, this case is the first reported in our country, and the 2nd case in the world treated with partial nephrectomy.

Through this observation and a review of the literature, we try to analyze this association as well as the main diagnostic and therapeutic aspects.

2. Case Presentation

We report the case of 50-year-old patient, married for 12 years, without children, a regular chronic smoker (30 pack years), who suffered from recurrent pulmonary infections. He consulted for right lumbago beginning 8 months earlier, nonrelieved by analgesic treatment. The patient's overall condition was preserved and no hematuria has been noticed.

An abdominal ultrasound showed cystic lesions of the right kidney containing multiple thick septa, without vegetation, measured 73 × 72 mm. The liver is found in the left hypochondriac region and the spleen on the right one, confirming the situs inversus. A chest X-ray revealed dextrocardia (Figure 1).

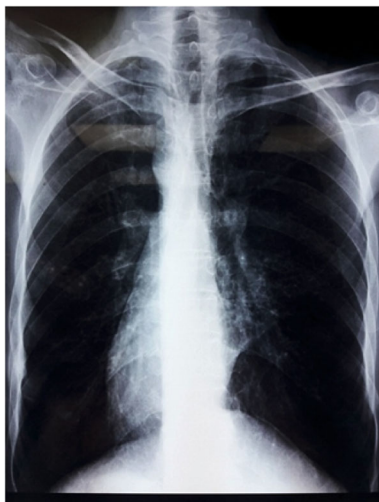

FIGURE 1: Chest X-ray showing dextrocardia.

Enhanced abdominal computed tomography (CT) has confirmed the situs inversus and showed a bulky mass in the right kidney, measuring 7 cm × 8 cm (anterolateral and craniocaudal) with cystic patches and multiple images of thickened septa (Figure 2). There were no tumor thrombus in the renal vein or the inferior vena cava.

Functional respiratory tests were also performed and revealed an irreversible obstructive airway disorder and pulmonary hyperinflation. Azoospermia was found in the sperm test, preoperative renal function was normal, and the rest of biological assessment showed no other abnormalities.

We diagnosed our patient as having a T2bN0M0 renal tumor. The favorable RENAL nephrometry score (6a) allow us to put forward a partial nephrectomy with open approach, by a flank incision along the eleventh intercostal space (Figure 3). The histologic examination of the surgical specimen revealed a renal cell carcinoma—the margins were not affected.

In immediate postoperative, the patient has presented with a hematuria but the renal function was still be normal. The patient was discharged at postoperative on day 5. *In the absence of standardized data*, we plan to carry out a follow-up according to the recommendations of the *French Association of Urology* of a renal tumor with low risk, either the realization of a scanner at 6 months followed by every year for 3 years, a final control at 5 years and a monitoring of the renal function by assaying plasma creatinine at the same time as the scanner [4].

One year later, the patient is still alive, without any metastases and with a normal renal function.

3. Discussion

A review of the literature unveils the rarity of this association. Only eleven cases have been published. Bertini and Boileau described firstly the same case in a 54-year-old woman [5]. Oake and Drachenberg studied the operative considerations for the treatment of renal carcinoma in a 65-year-old man with situs inversus [6]. The age of patients varies between

43 and 83 years with only one woman and ten men. Six patients had the tumor in the left side when five in the right one. Nine patients had a curative treatment by radical nephrectomy, while only one palliative treatment and another treated by partial nephrectomy. Five cases of clear cell carcinoma had been reported (Table 1).

Surgery in these patients with situs inversus is particular. The modifications in surgical anatomy for the reversed abdominal organs complicates the surgical attitudes. Surgical treatment presents many technical issues; moreover, several surgical techniques have been described including laparoscopic techniques. To reduce these surgical difficulties, Makiyama et al. described the first case of a laparoscopic nephroureterectomy in a patient with situs inversus; the team developed a laparoscopic simulator specially dedicated to the reversed anatomy to allow preoperative training [7].

Patient's preoperative evaluation with CT scan and magnetic resonance imaging can be helpful to explore anatomical variations and determine surgical approach. Literature reports increased the frequency of vascular anomalies associated to the situs inversus; in addition to the transposed position of the aorta and vena cava, Makiyama et al. [7] in their case report found 2 renal arteries to the right kidney and a right renal vein passing over the aorta and ramifying an adrenal vein, a lumbar vein, and a gonadal vein. Oake and Drachenberg [6] report a case of patient with two renal veins and a number of extrarenal arteries travelling both anterior and posterior to the inferior vena cava.

The second case of renal cell carcinoma reported in a patient with situs inversus in the world mentioned a lower than normal origin of the left renal vein [8].

The management of renal vessels should be carefully performed because of the transposed position of the aorta and the inferior vena cava and the elevated incidence of associated vascular abnormalities.

Radiological image, such as 3D-constructed CT, may specify the different variations and facilitate the management of the surgical procedure. The use of magnetic resonance scanning preoperatively allows detailed planning of the approach as required.

The surgical approach is not standardized, and an exhaustive preoperative assessment (CT, MRS) seems to be the best way to orient towards the safest technique.

We did not use the laparoscopic approach in our case because of the rarity of that and lack of facility due to anatomical variations. We suppose that partial nephrectomy will be very difficult in laparoscopic approach.

Preoperative evaluation and postoperative follow-up are very important in these patients that have cardiac, pulmonary, and renal anomalies [8].

4. Conclusion

The association of situs inversus and renal cell carcinoma is very rare. To our knowledge, this is the first reported case in Morocco. Preoperative assessment and knowledge

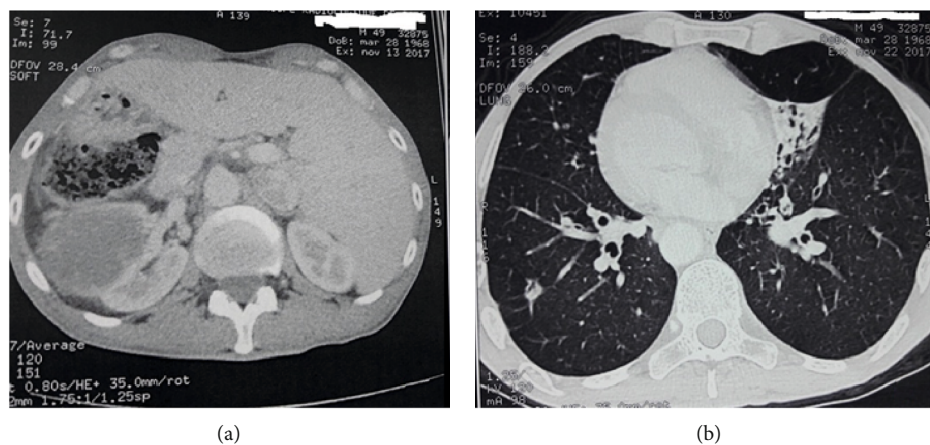


FIGURE 2: Computed tomography demonstrated a mass in the right kidney and mirror-image organs with left-to-right reversal (a) and bronchiectasia with situs inversus (b).

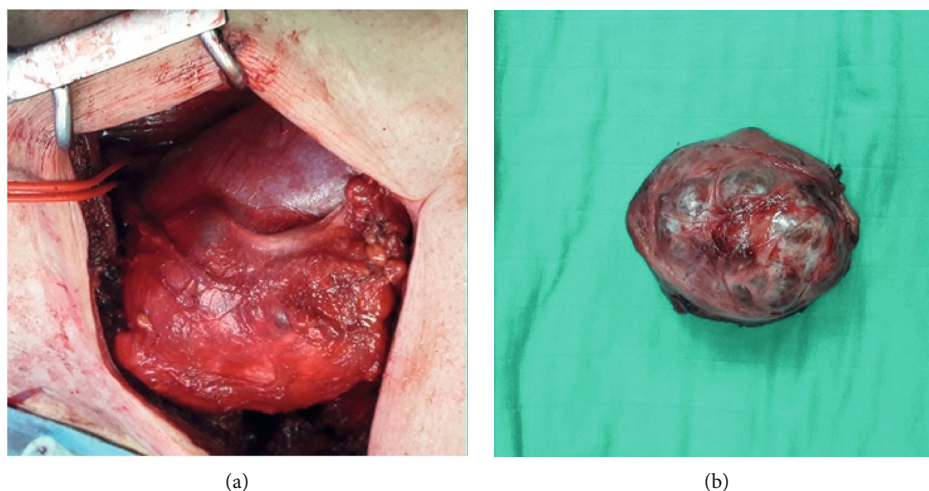


FIGURE 3: Intraoperative image showing the kidney and the tumor lesion (a) and specimen of partial nephrectomy (b).

TABLE 1: Literature review: clinical cases published of situs inversus and renal carcinoma.

No.	Case report	Age/sex	Location	Open/Lap nephrectomy	Radical/partial nephrectomy	Histology
1	Bertini and Boileau 1987 [5]	54/F	Right	Open	Radical	–
2	Treiger et al. 1993 [8]	82/M	Left	Open	Radical	–
3	Adler and Lerner 1998 [3]	58/M	Left	Open	Radical	–
4	Jimenez Verdejo et al. 2000 [9]	43/M	Right	Open	Radical	–
5	Jewell and Bowa 2001 [10]	43/M	Left	Open	Radical	Clear cell
6	Takagi et al. 2008 [11]	50/M	Left	Open	Radical	–
7	Makiyama et al. 2012 [7]	61/M	Right	Lap	Radical	–
8	Rangarajan et al. 2013 [12]	65/M	Right	Nonsurgical	–	Clear cell
9	Terakawa et al. 2014 [13]	81/M	Left	Lap	Radical	Clear cell
10	Sağlam et al. 2015 [14]	52/M	Right	Open	Partial	Clear cell
11	Oake and Drachenberg 2017 [6]	65/M	Left	Open	Radical	Clear cell
12	Our study	50/M	Right	Open	Partial	Clear cell

F: female; Lap: laparoscopic; M: male.

of anatomy are crucial and allow for better adaptation of the surgical technique.

Abbreviations

PCD: Primary ciliary dyskinesias
 VHL: von Hippel-Lindau disease
 CT: Computed tomography
 RCC: Renal cell carcinoma
 MRS: Magnetic resonance scanning.

Conflicts of Interest

The authors declares that they have no conflicts of interest.

References

- [1] B. A. Afzelius, "A human syndrome caused by immotile cilia," *Science*, vol. 193, no. 4250, pp. 317–319, 1976.
- [2] M. Kartagener, "Zur pathogenese der Bronchiektasien," *Beiträge zur Klinik der Tuberkulose und spezifischen Tuberkulose-Forschung*, vol. 83, no. 4, pp. 489–501, 1933.
- [3] H. L. Adler and S. P. Lerner, "Renal cell carcinoma and situs inversus viscerum," *The Journal of Urology*, vol. 160, 6 Part 1, pp. 2141–2142, 1998.
- [4] K. Bensalah, L. Albiges, J. C. Bernhard et al., "RETRACTED: Recommendations françaises du Comité de Cancérologie de l'AFU – Actualisation 2018–2020 : prise en charge du cancer du rein French ccAFU guidelines – Update 2018–2020: Management of kidney cancer: management of kidney cancer," *Progrès en Urologie*, vol. 28, no. 12S, pp. S3–S31, 2018.
- [5] J. E. Bertini Jr. and M. A. Boileau, "Renal cell carcinoma in a patient with situs inversus totalis," *Journal of Surgical Oncology*, vol. 34, no. 1, pp. 29–31, 1987.
- [6] J. Oake and D. Drachenberg, "A case of renal cell carcinoma in a patient with situs inversus: operative considerations and a review of the literature," *Canadian Urological Association Journal*, vol. 11, no. 5, pp. 233–236, 2017.
- [7] K. Makiyama, R. Sakata, H. Yamanaka, T. Tatenuma, F. Sano, and Y. Kubota, "Laparoscopic nephroureterectomy in renal pelvic urothelial carcinoma with situs inversus totalis: preoperative training using a patient-specific simulator," *Urology*, vol. 80, no. 6, pp. 1375–1378, 2012.
- [8] B. F. Treiger, R. Khazan, S. M. Goldman, and F. F. Marshall, "Renal cell carcinoma with situs inversus totalis," *Urology*, vol. 41, no. 5, pp. 455–457, 1993.
- [9] A. Jimenez Verdejo, J. L. Martinez Torres, F. Palao Yago et al., "Carcinoma de células renales en paciente con situs inversus y síndrome de kartagener," *Actas Urológicas Españolas*, vol. 24, no. 2, pp. 169–172, 2000.
- [10] J. Jewell and K. Bowa, "Situs inversus with renal neoplasm: a case report," *East and Central African Journal of Surgery*, vol. 6, pp. 95–97, 2001.
- [11] Y. Takagi, M. Narushima, and T. Shimoji, "A case of renal cell carcinoma with situs inversus totalis," *Japanese Journal of Clinical Urology*, vol. 62, pp. 315–317, 2008.
- [12] S. Rangarajan, B. Sunil, and A. S. Shet, "Situs inversus and metastatic renal cell carcinoma: a case report," *International Journal of Case Reports and Images*, vol. 3, pp. 1–5, 2013.
- [13] T. Terakawa, H. Miyake, H. Tanaka, T. Inoue, and M. Fujisawa, "Feasibility of a retroperitoneal approach as a surgical strategy for patients with situs inversus totalis: presentation of a patient undergoing laparoscopic radical nephrectomy for renal cell carcinoma," *International Cancer Conference Journal*, vol. 3, no. 1, pp. 8–10, 2014.
- [14] E. Sağlam, A. Türk, A. Selimoğlu, M. K. Demirkol, N. P. Sağlam, and A. Özgül, "Renal cell carcinoma in a patient with Kartagener syndrome: first case report in English language," *Journal of Urological Surgery*, vol. 1, no. 1, pp. 33–35, 2015.