



Hypertrophic osteopathy in a cat with a concurrent injection-site sarcoma

Raquel Salgüero¹, Jackie Demetriou²,
Fernando Constantino-Casas¹ and Michael Herrtage¹

Journal of Feline Medicine and Surgery

Open Reports

1–5

© The Author(s) 2015

Reprints and permissions:

sagepub.co.uk/journalsPermissions.nav

DOI: 10.1177/2055116915593968

jfmsopenreports.com



Abstract

Case summary An 11-year old neutered female domestic shorthair cat presented for investigation of a large, partially ulcerated skin mass in the area of the left scapula. The cat had been vaccinated 6 weeks previously in the same area. Haematology showed a marked neutrophilia and monocytosis. Tru-cut biopsies were taken and histopathology was consistent with a high-grade soft tissue sarcoma. Thoracic radiographs and abdominal ultrasound revealed no abnormalities. Moderate mixed (palisading, brush border and smooth) periosteal reaction was seen on the diaphysis of long bones at the time of the radiographic examination. Magnetic resonance imaging of the mass showed infiltration within deeper tissues and the owners elected euthanasia. Post-mortem examination confirmed the presence of hypertrophic osteopathy with a concurrent injection-site sarcoma. No evidence of intra-thoracic or intra-abdominal disease was found.

Relevance and novel information To our knowledge, this is the first report where hypertrophic osteopathy has been described in a cat with a soft tissue sarcoma, most likely an injection-site sarcoma.

Accepted: 12 April 2015

Introduction

Hypertrophic osteopathy (HO), also called Marie's disease, is a polyostotic disease characterised by palisading or brush border periosteal proliferation on the diaphysis of long bones. In dogs, HO is usually secondary to neoplastic (primary or metastatic lung neoplasia) or infectious masses in the thoracic cavity, or, less commonly, in the abdominal cavity.^{1–3} In cats, neoplastic or inflammatory thoracic or abdominal diseases are also the most common causes of HO.^{4–12} However, a cat with megaoesophagus and HO has also been described in the literature.¹³ Two reports have described the presence of HO in cats with no underlying disease and were therefore termed idiopathic.^{14,15} Primary hypertrophic osteoarthropathy or pachydermoperiostosis has been described in humans, usually manifesting in young males and accounting for approximately 3–5% of cases with hypertrophic arthropathy.^{16–18}

Currently, there have been no reported feline cases of HO caused by a lesion with no thoracic or abdominal involvement. In this report we describe a case of a cat with HO and a concurrent soft tissue sarcoma (STS), most likely an injection-site sarcoma.

Case description

An 11-year old neutered female domestic shorthair cat was admitted to the Queen's Veterinary School Hospital at the University of Cambridge for investigation of a rapidly growing mass over the left scapular region. The cat had received its annual vaccination (Purevax RCP FeLV; Merial) 6 weeks previously and had been missing for 4 weeks before presentation. On initial presentation to the referring veterinarian, a 4 × 5 cm mass was present over the left scapular region and the cat was pyrexia (39.5°C). Oral treatment with meloxicam 0.1 mg q24h (Metacam; Boehringer Ingelheim) and antibiotics 50 mg q12h (clavulanic acid and amoxicillin; Pfizer Animal Health)

¹Queen's Veterinary School Hospital, University of Cambridge, Cambridge, UK

²Dick White Referrals, Six Mile Bottom, UK

Corresponding author:

Raquel Salgüero DVM, MA, MRCVS, Queen's Veterinary School Hospital, University of Cambridge, Madingley Road, Cambridge CB3 0ES, UK

Email: raquel.salgüero.vet@gmail.com



was given for 4 days with no response. On presentation at referral 4 days after the cat was presented to the referring veterinarian, the cat was quiet but alert. Mild tachypnoea with an increased inspiratory effort and pyrexia (39.5°C) were noted. The mass over the left scapular region had increased in size since initial presentation (7 × 5 × 4 cm) and was superficially ulcerated.

Haematology revealed mild anaemia (haematocrit 19%, reference interval [RI] 26–45%) and marked leukocytosis ($140.0 \times 10^9/l$, RI 5.5–19.5), with absolute neutrophilia ($133.0 \times 10^9/l$, RI 2.5–12.5) and monocytosis ($4.2 \times 10^9/l$, RI 0–1.5). Serum biochemistry was unremarkable. FeLV/FIV IDEXX SNAP test was negative.

Fine-needle aspiration of the mass revealed neutrophilic inflammation and mesenchymal cell proliferation. Tru-cut needle biopsies were taken under general anaesthesia and were consistent with a high-grade STS. Fungal and mycobacterial cultures were negative.

Abdominal ultrasound was unremarkable. Thoracic radiographs revealed no intrathoracic pathology. A 7 × 5 cm soft tissue opacity at the level of the left scapula was noticed (Figure 1). Incidentally, a mixture of brush border, palisading and smooth periosteal reaction was seen along the diaphysis of the humerus, radius and ulna in both forelimbs, and as well on the distal tibia, calcaneus, and tarsal and metatarsal bones (Figure 2). These bone abnormalities were radiographically consistent with HO.

A magnetic resonance imaging (MRI) examination of the mass was performed to assess the extension and aid possible surgical planning. The mass was associated

with the left proximal humerus, being lateral to the left scapula and in very close relation to the transverse spinous process of the caudal cervical vertebrae. The mass (5.5 × 4.5 × 3 cm) was mostly hyperintense to muscle on T1-weighted (T1W) and T2-weighted (T2W) images, with internal T1W hypointensities and T2W hyperintensities consistent with necrosis (Figure 3). The

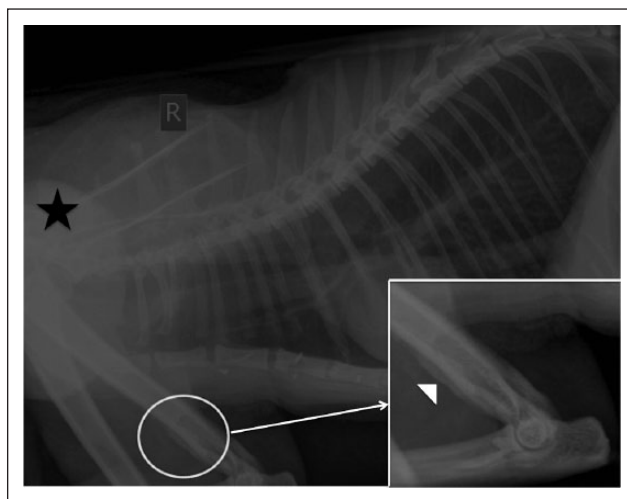


Figure 1 Right lateral view of the thorax, showing no pulmonary abnormalities. A mass over one of the shoulders is seen (black star), and there is a brush border periosteal reaction on the humerus, seen better on the caudal aspect (white circle). The periosteal reaction is magnified and marked with a white arrowhead. Cranial is to the left of the image

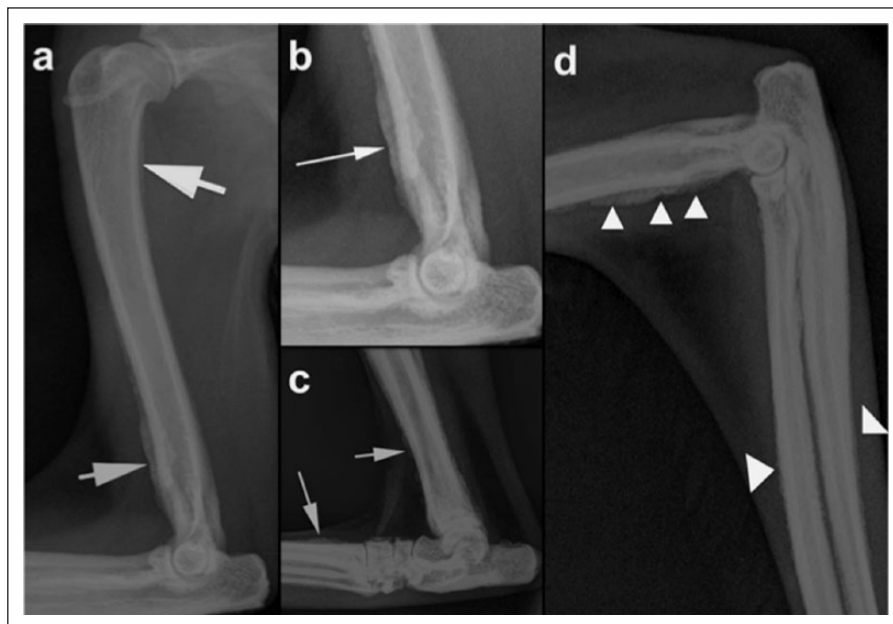


Figure 2 Mediolateral radiographs of the (a,b) left forelimb, (c) right hindlimb and (d) right forelimb, showing a moderate amount of a mixed periosteal reaction (palisading, smooth and brush border) on the cranial and caudal cortex of the humerus, distal tibia and dorsal aspect of the metatarsi (white arrows), and radius and ulna (white arrowheads). (b) Magnified view of the periosteal reaction in the left distal humerus

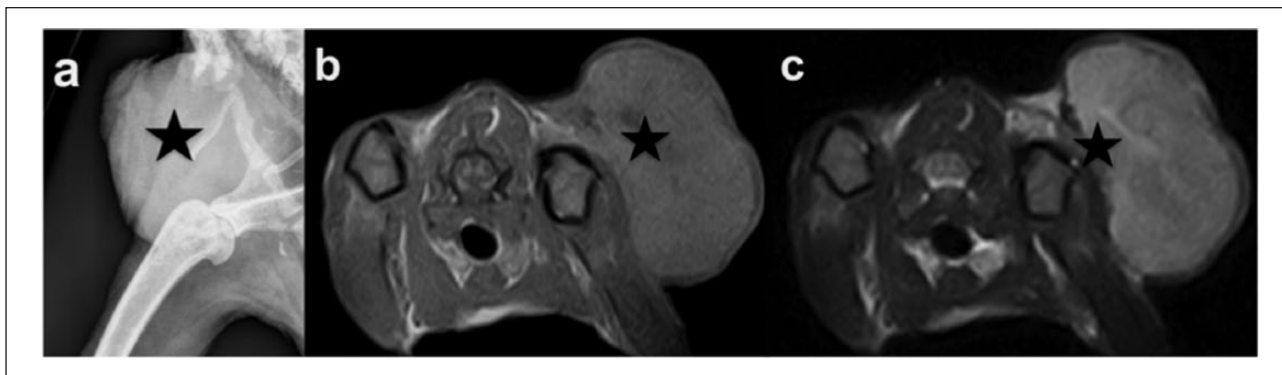


Figure 3 (a) Mediolateral oblique radiograph of the left elbow, with a large soft tissue mass over the scapula–humeral joint (black star). (b) T1-weighted transverse image at the level of the proximal humeral metaphysis, showing a mostly hyperintense mass lateral to the left shoulder joint (black star), with a focal area of necrosis. (c) T2-weighted image, showing the same changes as in (b) but in this case the area of necrosis is hyperintense. Left is to the right of the image

mass had ill-defined and irregular margins, and there was strong suspicion of muscle invasion. The owners elected euthanasia on humane grounds, as they did not wish to pursue radical resection of the mass. Post-mortem examination showed marked rough increased periosteal new bone in the diaphysis of long limb bones and scapulae (Figure 4a), which had a double cortex-like appearance on transverse sections. Microscopically, the mass revealed invasion of the skin, dermis, subcutaneous tissue and skeletal muscle with spindle-shaped neoplastic cells was noted. Fibrin deposition and necrosis, and a mitotic rate of 0–3/high power field were noted (Figure 4b). There was marked periosteal reaction with new woven bone tissue in the diaphysis of the long bones. The new bone formed was cancellous to compact with large number of osteoblasts and osteocytes. There was clear distinction from the new bone with the normal compact bone (Figure 4c). These changes were characteristic for HO. Other post-mortem findings include mild pulmonary congestion and oedema, mild hepatitis and splenic lymphoid depletion. A cystic thyroid adenoma on the right thyroid lobe was found.

The gross post-mortem findings, microscopic examination, and clinical and radiological findings confirmed the presence of a high-grade STS, most likely an injection-site sarcoma, in the left scapular region, and HO.

Discussion

The exact pathogenesis of HO is still unknown and several theories have been suggested, including irritation of the periosteum by circulating toxins from the primary lesions, changes in the peripheral blood flow to the distal extremities, neurogenic mechanisms, afferent impulses that travel in the vagus and intercostal nerves from the lesion to the central nervous system and develop the HO, and distal vascular release of platelet-derived growth factor and vascular endothelial growth factor.^{1–3} The mechanism for the development of HO in

this case was not determined; however, it is possible that any or all of the proposed mechanisms could have contributed.

HO is commonly seen in middle-aged male cats, Persian and Persian crosses.³ The most common presenting sign is moderate-to-severe lameness with the underlying cause typically identified as an incidental finding.^{1–15} Interestingly, this cat did not have any clinical signs of lameness and no pain or swelling of the long bones was found in the general examination. It is possible the STS progression was more rapid than the development of clinical signs associated with HO in this case, as the periosteal reaction was only moderate.

Only one other case of HO associated with a sarcoma in a cat has been described in the literature; however, this was a pulmonary sarcoma in keeping with the intrathoracic pathology history seen with HO in cats.⁶ Furthermore, no other reports of STS with HO have been previously described in cats or humans. Owing to the vaccination history, localisation of the mass, MRI characteristics and histopathology, the most likely final diagnosis was an injection-site sarcoma.

Feline injection-site STSs are thought to be caused by an anomalous response to a chronic local inflammation after vaccine administration, long-acting antibiotics, methylprednisolone or non-absorbable suture material. They have a very rapid growth, are locally invasive and have a low distant metastatic rate.^{19–22} Generally, STS occurs at 6–7 years or 10–11 years, as in our case.²²

MRI characteristics of injection-site STSs have been recently described showing a wide variability, but all tumours were hyperintense relative to surrounding muscles on T1W and T2W images, similar to this case.²³

Although it is impossible to define causation of the HO with STS, given the lack of other causative features (thoracic or abdominal abnormalities), the presence of the STS causing HO is highly likely. The thyroid adenoma

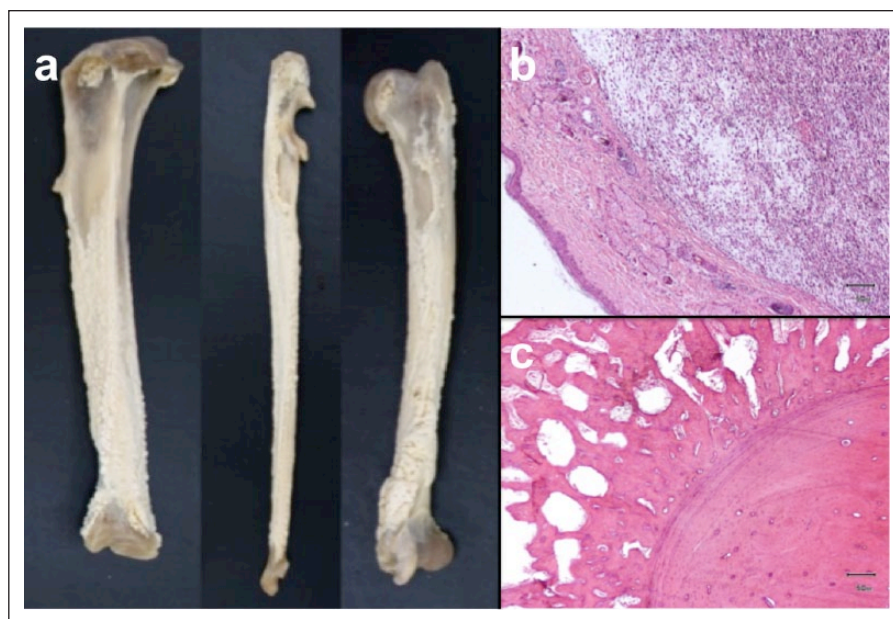


Figure 4 (a) Macroscopic appearance of the tibia, ulna and humerus, showing a moderate diffuse palisading periosteal reaction involving mainly the diaphysis. (b) Histological sample of the skin mass, showing a densely cellular, non-encapsulated neoplastic tissue (haematoxylin and eosin; bar = 50 μ m). (c) Histological sample of a transverse section of the diaphysis of the ulna showing periosteal growth of cancellous bone with a clear distinction with the compact bone (haematoxylin and eosin; bar = 50 μ m)

is unlikely to be the cause of HO in this case, as no other reports of HO associated with thyroid adenoma have been published in the literature. Only one human report with thyroid cancer and secondary HO has been reported; however, in that case, HO only developed once pulmonary metastases were present.²⁴

In human medicine HO has been associated with cyanotic congenital heart disease.²⁵ Mild pulmonary congestion was identified in the post-mortem examination of this case, most likely related to the euthanasia as no cardiovascular abnormalities were found in this cat on post-mortem examination.

An idiopathic HO in this case is also unlikely. Only eight cats with suspected idiopathic HO have previously been reported.^{14,15} Although we cannot completely exclude the possibility of an idiopathic HO and a STS occurring independently from each other in this case, it is far more likely that the origin of HO in this case is related to the STS as, by definition, HO usually develops secondary to another disease process, for example neoplasia or inflammation, and additionally all human and veterinary cases of primary HO have clinical signs due to the periosteal reaction, which this cat lacked.¹⁶⁻¹⁸

Resolution of the HO after surgical removal of the primary lesion has been reported.⁹ In the present case, confirmation of the association of HO and STS would have included the resolution of the periosteal reaction after surgical resection of the mass, which was not performed at the owners' request.

Conclusions

This report describes the first case of a cat with an STS (likely an injection-site STS) with secondary HO. HO can also occur in cats where no lameness or swollen limbs and pain are present. We recommend radiographing the distal limbs and including HO as a differential in cases when STS and lameness are present. Further research is needed to identify the exact connection between injection-site STS and HO in cats.

Funding The authors received no specific grant from any funding agency in the public, commercial or not-for profit sectors for preparation of this case report.

Conflict of interest The authors do not have any potentials conflicts of interest to declare.

References

- 1 Cetinkaya MA, Yardimci B and Yardimci C. **Hypertrophic osteopathy in a dog associated with intra-thoracic lesions: a case report and a review.** *Vet Med* 2011; 56: 595–601.
- 2 Lenehan TM and Fetter AW. **Hypertrophic osteopathy.** In Newton CD and Nunamaker DM (eds). *Textbook of small animal orthopaedics*. 1st ed. Philadelphia, PA: Lippincott Williams & Wilkins, 1985, p 603.
- 3 Langley-Hobbs S. **Musculoskeletal oddities in the cat. An overview of some curious causes of lameness.** *J Feline Med Surg* 2012; 14: 31–42.
- 4 Richards CD. **Hypertrophic osteopathy in a cat.** *Feline Pract* 1977; 7: 41–43.

- 5 Roberg J. **Hypertrophic pulmonary osteoarthropathy.** *Feline Pract* 1977; 7: 18–22.
- 6 Grierson JM, Burton CA and Brearley MJ. **Hypertrophic osteopathy secondary to a pulmonary sarcoma in a cat.** *Vet Comp Oncol* 2003; 1: 227–231.
- 7 Gram WD, Wheaton LG, Snyder PW, et al. **Feline hypertrophic osteopathy associated with pulmonary carcinoma.** *J Am Anim Hosp Assoc* 1990; 26: 425–428.
- 8 Carr SH. **Secondary hypertrophic pulmonary osteoarthropathy in a cat.** *Feline Pract* 1971; 1: 25–26.
- 9 Becker TJ, Perry RL and Watson GL. **Regression of hypertrophic osteopathy in a cat after surgical excision of an adrenocortical carcinoma.** *J Am Anim Hosp Assoc* 1999; 35: 499–505.
- 10 Nafe LA, Herron AJ and Burk RL. **Hypertrophic osteopathy in a cat associated with renal papillary adenoma.** *J Am Anim Hosp Assoc* 1981; 17: 659–662.
- 11 Johnson RL and Lenz SD. **Hypertrophic osteopathy associated with a renal adenoma in a cat.** *J Vet Diagn Invest* 2011; 23: 171–175.
- 12 Houdemer. **Sur quelques cas de tuberculose observés chez les animaux domestiques ou sauvages du Tonkin.** *Bull Adad Vet Fr* 1982; 81: 40–42.
- 13 Mills J. **Hypertrophic osteopathy and megaesophagus in a cat.** *Vet Comp Orthop Traumatol* 2010; 23: 218–222.
- 14 Huang CH, Jeng CR, Lin CT, et al. **Feline hypertrophic osteopathy: a collection of seven cases in Taiwan.** *J Am Anim Hosp Assoc* 2010; 46: 346–352.
- 15 De Melo Ocarino N, Fukushima FB, de Matos Gomes A, et al. **Idiopathic hypertrophic osteopathy in a cat.** *J Feline Med Surg* 2006; 8: 345–348.
- 16 Cooper RG, Freemont AJ, Riley M, et al. **Bone abnormalities and severe arthritis in pachydermoperiostosis.** *Ann Rheum Dis* 1992; 51: 416–419.
- 17 Rastogi R, Suma GN, Prakash R, et al. **Pachydermoperiostosis or primary hypertrophic osteoarthropathy: a rare clinicoradiologic case.** *J Radiol Imaging* 2009; 19: 123–126.
- 18 Zhang Z, Zhang C and Zhang Z. **Primary hypertrophic osteoarthropathy: an update.** *Front Med* 2013; 7: 60–64.
- 19 Ladlow J. **Injection site-associated sarcoma in the cat. Treatment, recommendations and results to date.** *J Feline Med Surg* 2013; 15: 409–418.
- 20 Dean RS, Pferiffer DU and Adams V. **The incidence of feline injection site sarcomas in the United Kingdom.** *Vet Res* 2013; 9: 17.
- 21 Woodward KN. **Origins of injection-site sarcomas in cats: the possible role of chronic inflammation – a review.** *ISRN Vet Sci* 2011: 210982.
- 22 Martano M, Morello E and Buracco P. **Feline injection-site sarcoma: past, present and future perspectives.** *Vet J* 2011; 188: 136–141.
- 23 Rousset N, Holmes MA, Caine A, et al. **Clinical and low-field MRI characteristics of injection site sarcoma in 19 cats.** *Vet Radiol Ultrasound* 2013; 54: 623–629.
- 24 Vico P, Delcorde A, Rahier I, et al. **Hypertrophic osteoarthropathy and thyroid cancer.** *J Rheumatol* 1992; 19: 1153–1156.
- 25 Martinez-Lavin M, Bobadilla M, Casanova J, et al. **Hypertrophic osteoarthropathy in cyanotic congenital heart disease.** *Arthritis Rheum* 1982; 25: 1186–1193.