

## CASE REPORT

# Coronary subclavian steal syndrome—is there a need for routine assessment for subclavian artery stenosis following coronary bypass surgery?

M.A. Waduud<sup>1,\*</sup>, M. Giannoudi<sup>1</sup>, M. Drozd<sup>2</sup>, C.J. Malkin<sup>3</sup>, J.V. Patel<sup>1</sup>  
and D.J.A. Scott<sup>1</sup>

<sup>1</sup>Leeds Vascular Institute, Leeds General Infirmary, Leeds LS1 3EX, UK, <sup>2</sup>Leeds Institute for Cardiovascular and Metabolic Medicine, University of Leeds, Leeds LS1 9JT, UK, and <sup>3</sup>Department of Cardiology, Leeds General Infirmary, Leeds LS1 3EX, UK

\*Correspondence address. Leeds Vascular Institute, Leeds General Infirmary, Leeds LS1 3EX, UK. Tel: +44-740-082-2828; E-mail: m.a.waduud@leeds.ac.uk

## Abstract

Subclavian artery stenosis (SAS) resulting in coronary subclavian steal syndrome (CSSS) is a common but under recognized pathology following coronary artery bypass surgery (CABG). Patients with SAS may be asymptomatic due to the sub-clinical diversion of blood flow from the myocardium and retrograde blood flow during catheter angiography in the left internal mammary artery (LIMA) may be the first suggestion of CSSS. The management of SAS, causing CSSS, may rarely require acute assessment and intervention. However, full anatomical assessment of the stenosis morphology may be limited on fluoroscopy. Correction of SAS may be essential to achieve effective reperfusion therapy.

## INTRODUCTION

Coronary subclavian steal syndrome (CSSS) is an uncommon complication following cardiac bypass surgery involving the left internal mammary artery (LIMA) [1]. Subclavian artery stenosis (SAS) proximal to the LIMA graft can result in retrograde blood flow and diminished myocardial perfusion. It is therefore important to suspect CSSS as a rare but important potential cause of chest pain and myocardial ischaemia in patients following coronary artery bypass graft (CABG) surgery.

SAS affects ~2% of the general population with an increased prevalence in patients with concomitant cardiovascular disease [2, 3]. Despite SAS being relatively common in patients with previous cardiac surgery, patients are rarely investigated for CSSS on re-presentation with cardiac chest pain. We report an unusual case of a patient who was asymptomatic following

CABG until presentation with acute coronary syndrome. Emergency reperfusion by recanalization of an acutely occluded aorto-coronary graft was compounded by acute subclavian steal that negatively impacted on myocardial perfusion until correction of SAS.

## CASE REPORT

A 68-year-old male presented with abrupt central chest pain on waking with diaphoresis in the early hours of the morning. The pain did not radiate and was not relieved by glyceryl trinitrate spray. He denied any other symptoms. There were no upper or lower limb extremity symptoms (i.e. peripheral claudication, muscle fatigue, weakness, numbness) or cerebrovascular symptoms (i.e. syncope, headache, visual disturbances). At the time of

Received: May 21, 2018. Revised: September 5, 2018. Accepted: September 24, 2018

© The Author(s) 2018. Published by Oxford University Press.

This is an Open Access article distributed under the terms of the Creative Commons Attribution Non-Commercial License (<http://creativecommons.org/licenses/by-nc/4.0/>), which permits non-commercial re-use, distribution, and reproduction in any medium, provided the original work is properly cited. For commercial re-use, please contact [journals.permissions@oup.com](mailto:journals.permissions@oup.com)

presentation, the patient had a past medical history of CABG surgery performed in 2002 for unstable angina. The LIMA was anastomosed to the diagonal artery, and three autologous long saphenous vein grafts to the: left anterior descending (LAD), right coronary artery (RCA) and obtuse marginal artery (OMA). Percutaneous coronary stenting of the vein graft to the proximal obtuse marginal was later performed successfully in 2011 for an acute coronary syndrome. Post-intervention, there was no stenosis evident in the LIMA graft or vein grafts to the RCA and OMA. However, 75% stenosis was evident in the vein graft to the LAD. Despite this, he had been free of cardiac symptoms until this acute presentation. Previous medical history included hypertension and hypercholesterolaemia. There was no history of carotid or peripheral vascular disease, and there was no evidence to suggest diabetes mellitus. Regular medications included aspirin, ramipril, bisoprolol and simvastatin. There was also no family history of cardiovascular disease. The patient was a smoker who consumed four cigarettes per day (0.2 pack-year).

At the time of clinical examination the patient was pain free with a National Early Warning Score of 0 and clinically euvolemic [4]. Chest examination was unremarkable. Heart sounds were normal with no audible murmurs. He had a regular pulse (91 bpm) with no radial-radial delay. Blood pressure was measured at 117/85 mmHg, however, individual arm measurements were not recorded. There was no evidence of increase jugular venous pressure or peripheral oedema. Blood tests highlighted an elevated troponin I measured at 50 000 ng/L (normal laboratory limit <50 ng/L). An electrocardiogram performed demonstrated hyperacute ST-segment elevation in the anterior leads.

In light of these findings, the patient was moved immediately to the cardiac catheterization laboratory for emergency percutaneous coronary intervention (PCI). Angiography of the coronary arteries identified a co-dominant circulation. There was complete acute occlusion of the vein graft to the LAD with visible thrombus. In addition, a severe stenosis of the proximal section of the vein graft to the RCA, the stent within the vein graft to the OMA appeared patent. Retrograde blood flow was observed within the LIMA graft following revascularization of the LAD (Fig. 1). Angiographic imaging of the aortic arch was subsequently undertaken and stenosis of the proximal subclavian artery was identified (Fig. 2a). CSSS physiology was clearly evident.

Successful PCI with thrombectomy and implantation of three drug eluting stents was performed to the occluded vein graft to the LAD. This resulted in satisfactory blood flow down the graft but ongoing diminished flow into the native LAD with

blood flow away from the heart via the patent LIMA. Ongoing chest pain and continued ST-elevation was present suggestive of unsatisfactory myocardial reperfusion despite patent conduits, an acute CSSS was therefore suspected. Urgent review was sought with the on-call vascular interventional radiologist to determine optimal treatment for the SAS. A 8 mm × 20 mm Cobalt Assurant stent was deployed at the origin of the left subclavian artery (Fig. 2b). This resulted in relief of the acute CSSS with immediate antegrade blood flow down both grafts and into the native vessels beyond the surgical anastomoses (Fig. 2c). Relief of chest pain and improvement in ECG changes was subsequently noted. No immediate intervention was performed on the vein graft to the RCA.

Two days later the patient was discharged pain free. He was prescribed a year long course of dual antiplatelet therapy and secondary prevention medications were optimized with the conversion of simvastatin to high dose atorvastatin.

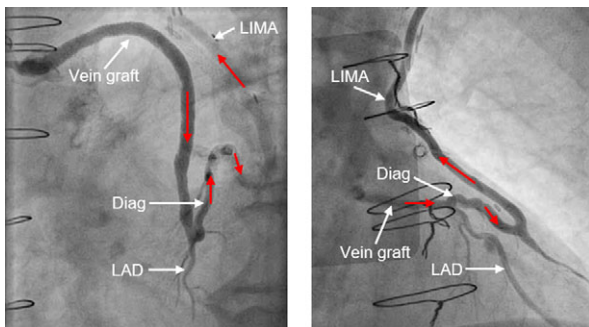
## DISCUSSION

LIMA bypass graft during CABG surgery is a surgical standard [5, 6]. It was originally thought that CSSS is a relatively uncommon phenomenon following CABG, with a reported incidence of between 0.2 and 6.8%, it is now thought that this is an under-estimate of the true clinical magnitude of the problem [2, 7]. On angiography, we demonstrate the typical transit of blood through the coronary circulation observed with CSSS [8, 9]. In our case, the presence of an apparently asymptomatic SAS resulted in complicated and delayed myocardial reperfusion, due to poor flow down the LIMA graft, despite successful graft PCI until treatment of the SAS.

SAS is a common pathology with a prevalence of between 3 and 4% in the general population. It is often secondary to extrinsic compression, arteritis, inflammation due to radiation and rarely fibromuscular dysplasia [3]. Furthermore, SAS is associated with concomitant coronary artery disease (CAD), peripheral vascular disease and carotid artery disease. It can cause significant morbidity due to ischaemia of the upper extremities and in certain situations the myocardium as demonstrated in our case. Patients may typically report upper extremity symptoms such as arm claudication or muscle fatigue, and rarely rest pain and finger necrosis [3]. Furthermore, patients may report neurological symptoms consistent with vertebrobasilar hypoperfusion, due to the competitive diversion of blood flow to the subclavian artery through a patent circle of Willis [3]. However, these features may not be always present as demonstrated by our case.

Despite up to 50% of patients with CAD having SAS, it is not routinely investigated in patients representing with cardiac ischaemia following CABG. Patients with SAS are typically investigated by vascular surgeons, following clinical examination and measurement of the blood pressure between arms, with either duplex ultra-sonography, computer tomography angiography (CTA) or magnetic resonance angiography (MRA) [10]. This allows for patient to be adequately counselled after timely discussion regarding risk and benefits of potential intervention.

In the emergency setting, such as PCI for acute ST-elevation MI, where SAS with CSSS is incidentally identified, it may not be always possible to evaluate the optimal method of intervention on fluoroscopy. However, recognition of these typical angiographic features should drive immediate decision on treatment, since uncorrected CSSS will attenuate the beneficial effect of emergency revascularisation. Angiogram features that raise suspicion of SAS include the inability to catheterize the left subclavian artery and retrograde flow in the LIMA graft.



**Figure 1:** Angiograms (LAO 30°, cranial 0°) illustrating (in white): vein graft, left anterior descending artery (LAD), diagonal artery (Diag) and left internal mammary artery (LIMA). Red arrows demonstrate antegrade flow down vein graft and retrograde flow up the LIMA.

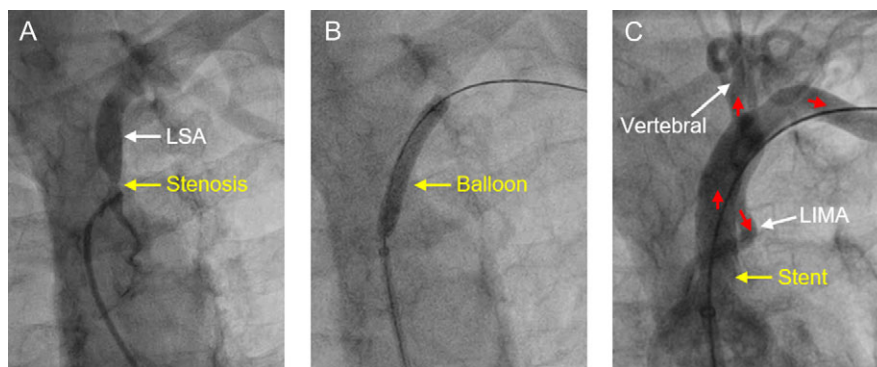


Figure 2: Angiograms (RAO 30°, cranial 0°) illustrating (A) proximal subclavian artery stenosis, (B) ballooning and stenting of the proximal subclavian artery stenosis and (C) antegrade flow down the left internal mammary artery (LIMA) and left vertebral artery. Red arrows represent the direction of blood flow.

Although endovascular intervention is associated with a 93% technical and clinical success, there is a 1% risk of stroke and stent patency is 89% at 5 years [3]. It is important to note that not all cases of SAS may be suitable for endovascular stenting due to anatomy suitability or plaque morphology. There is an inherent risk that a heavily calcified stenotic lesion, which cannot be adequately assessed on fluoroscopy, may result in complications when acutely treated [11]. In our case we judged the risk of ongoing myocardial ischaemia/infarction due to CSSS physiology as high and therefore this mandated immediate treatment of the SAS.

Several case studies have reported the identification of CSSS whilst performing acute coronary intervention [8, 12]. The measurement the blood pressure from both arms is a simple assessment tool in diagnosing SAS that is often overlooked. There is a growing body of evidence suggesting the a difference in the systolic blood pressure of >10 mmHg between arms is predictive of SAS [13, 14]. However, at present, there is no consensus which imaging modality is best to assess for SAS in an elective setting. Non-invasive imaging that may be useful include doppler ultrasound, MRA or CTA. Doppler ultrasound has the advantage of being relatively cheap with minimal radiation exposure. It may demonstrate: low flow or a damped waveform in the left subclavian artery, retrograde flow in the left vertebral artery or if the proximal end of LIMA is visualized retrograde flow. MRA or CTA of the arch/left subclavian may confirm and outline anatomy of the lesion and may be valuable in planning intervention. These modalities could be used to evaluate the location and degree of stenosis of the subclavian artery and help determine the likelihood of the SAS being the culprit lesion for any myocardial ischaemia [15]. Furthermore, high-risk patients such as patients exposed to prior radiation therapy to the chest or, a past medical history of vasculitis, peripheral vascular disease or carotid artery disease may potentially have the greatest benefit.

## CONCLUSIONS

Our case highlights that in an emergency setting the correction of SAS causing CSSS may be essential to achieve effective reperfusion therapy. Key angiographic features may aid diagnosis but in an elective setting there is currently no consensus on the best pre-intervention management strategy. The treatment in many cases is relatively straightforward with the aid of an interventional radiologist. We demonstrate that on occasions it may be vital for the interventional cardiologist to look away from the heart.

## SUPPLEMENTARY MATERIAL

Supplementary material is available at *Oxford Medical Case Reports* online.

## ACKNOWLEDGEMENTS

MAW and MD hold British Heart Foundation Clinical Research Training Fellowships.

## CONFLICT OF INTEREST STATEMENT

The authors have no conflicts of interests to declare.

## FUNDING

No funding was required for this case report.

## ETHICAL APPROVAL AND CONSENT

All data has been anonymised so that the patient cannot be identified from any one or the combination data described. We have confirmed to the ethical principles within our institution.

## GUARANTOR

All authors guarantee the content of this case report to be accurate. The authorship consists of the medical team whom performed all interventions and were responsible for the pre- and post-intervention care for the patient.

## REFERENCES

- Iglesias JF, Degrauwe S, Monney P, Glauser F, Qanadli SD, Eeckhout E, et al. Coronary subclavian steal syndrome and acute anterior myocardial infarction: a new treatment dilemma in the era of primary percutaneous coronary intervention. *Circulation* 2015;132:70–1.
- Cua B, Mamdani N, Halpin D, Jhamnani S, Jayasuriya S, Mena-Hurtado C. Review of coronary subclavian steal syndrome. *J Cardiol* 2017;70:432–7.
- Ochoa VM, Yeghiazarians Y. Subclavian artery stenosis: a review for the vascular medicine practitioner. *Vasc Med* 2011;16:29–34.
- McGinley A, Pearse RM. *A National Early Warning Score for Acutely Ill Patients*. 2012, British Medical Journal Publishing Group.

5. Ramadan R, Boden WE, Kinlay S. Management of left main coronary artery disease. *J Am Heart Assoc* 2018;**7**:e008151.
6. Goldman S, Zadina K, Moritz T, Ovitt T, Sethi G, Copeland JG, et al. Long-term patency of saphenous vein and left internal mammary artery grafts after coronary artery bypass surgery: results from a Department of Veterans Affairs Cooperative Study. *J Am Coll Cardiol* 2004;**44**:2149–56.
7. Sintek M, Coverstone E, Singh J. Coronary subclavian steal syndrome. *Curr Opin Cardiol* 2014;**29**:506–13.
8. Bicknell C, Subramanian A, Wolfe J. Coronary subclavian steal syndrome. *Eur J Vasc Endovasc Surg* 2004;**27**:220–1.
9. Samoil D, Schwartz JL. Coronary subclavian steal syndrome. *Am Heart J* 1993;**126**:1463–6.
10. Shadman R, Criqui MH, Bundens WP, Fronck A, Denenberg JO, Gamst AC, et al. Subclavian artery stenosis: prevalence, risk factors, and association with cardiovascular diseases. *J Am Coll Cardiol* 2004;**44**:618–23.
11. Forbes TJ, Garekar S, Amin Z, Zahn EM, Nykanen D, Moore P, et al. Procedural results and acute complications in stenting native and recurrent coarctation of the aorta in patients over 4 years of age: a multi-institutional study. *Catheter Cardiovasc Interv* 2007;**70**:276–85.
12. Arboine L, Palacios JM, Jauregui O, Cruz R, Galvan E, Lopez U, et al. Coronary-subclavian steal syndrome: an infrequent cause of ischemia post coronary artery bypass graft surgery. *J Med Case* 2017;**8**:256–8.
13. English JA, Carell ES, Guidera SA, Tripp HF. Angiographic prevalence and clinical predictors of left subclavian stenosis in patients undergoing diagnostic cardiac catheterization. *Catheter Cardiovasc Interv* 2001;**54**:8–11.
14. Osborn LA, Vernon SM, Reynolds B, Timm TC, Allen K. Screening for subclavian artery stenosis in patients who are candidates for coronary bypass surgery. *Catheter Cardiovasc Interv* 2002;**56**:162–5.
15. Chai P, Dubowitz M, Mohiaddin R. Coronary-subclavian steal syndrome demonstrated by cardiovascular magnetic resonance. *Circulation* 2006;**113**:e930–1.