



***Dioctophyme renale* in *Vulpes vulpes* from the Caspian Sea littoral of Iran**

***Elham HAJIALILO, Iraj MOBEDI, Jafar MASOUD, Hamid HASANPOUR,
*Gholamreza MOWLAVI***

Dept. of Medical Parasitology and Mycology, School of Public Health, Tehran University of Medical Sciences, Tehran, Iran

***Corresponding Author:** Email: molavig@yahoo.com

(Received 16 Dec 2014; accepted 24 Mar 2015)

Abstract

During a long term of road survey for detection of the zoonotic helminthes in carnivores, a male *Vulpes vulpes* was naturally found infected by *Dioctophyme renale* in Caspian Sea littoral in Iran. Since the parasite transmission usually occurs through consumption of fish and other accidental food items, investigation of the worm amongst fish-eating animals in the areas with potential circulation of the helminth life cycle, has been regarded as a public health importance so far. Concerning the rout of parasite transmission to humans, different epidemiological aspects should be studied in the country. Present paper describes a destructive lesion of the kidney in the fox due to *D. renale* after almost a decade of monitoring for the parasite reservoirs in the region.

Keywords: *Dioctophyma renale*, Fox, Zoonosis, Iran

Introduction

D. renale circulates in the nature, employing aquatic oligochaete annelids and fish eating animals as intermediate and final hosts respectively. Species of fishes and amphibians are served as paratenic hosts in the life cycle of this renal harboring helminthes (1). This nematode parasitizes different mammalian species and is acquired by humans through consumption of infected fish and/or direct ingestion of oligochaete caring larvae, occasionally (2).

Identification of the giant kidney worm in different carnivores has been reported worldwide. In Brazil and Turkey for instance, natural infection of *D. renale* in dogs and cats have been described well by previous researchers (3-5). Review of the literature shows the occurrence is much higher in the Southeast Asia, comparing with rest of the

world. Reminding the cases including a farmer who expelled the worm in the urine and exhibition of dermal granuloma accompanying by creeping eruption in a female patient in China, showing the variety of clinical manifestation of the infection (6-7).

In Iran Jackals in the wildlife and stray dogs have been found infected by *D. renale* in some occasions (8). The only human infection in Iran has been observed by Hanjani and his colleagues in a young female from Mianeh, Northwestern the country in 1968 (9).

The present paper describes the infection of *D. renale* in *V. vulpes* in Caspian Sea littoral which can attract the mind of health authorities towards the possible chance of parasite transmission to humans after decades ago in the region.

Case

The carcass of the fox, *V. vulpes* was found killed on the road, Roodbar 36° 48' 35" N / 49° 23' 17" E, 67 km southern Rasht the capital of Gilan province in the summer 2005. Initial observation revealed the sample, parasitized by *D. renale* and collected materials were subsequently transferred to the laboratory of Helminthology at Tehran University of Medical Sciences. Identification of the worm was based on characteristic morphologic and morphometric parameters introduced by

pioneer parasitologists (2). The infected left kidney (Fig.1a) was found seriously damaged, as the tissues had been already destroyed by the worm during the course of infection. Right kidney was not existed presumably due to laceration of the carcass on the road. Two segments of a male worm, 12 and 4cm in length, beside another female worm 24cm long (Fig. 1 c) which was observed free within the abdominal cavity were collected. The width in the middle parts of the samples (female and two segmented male), was measured about 5.8, 3.7 and 4mm respectively (Fig. 1b).

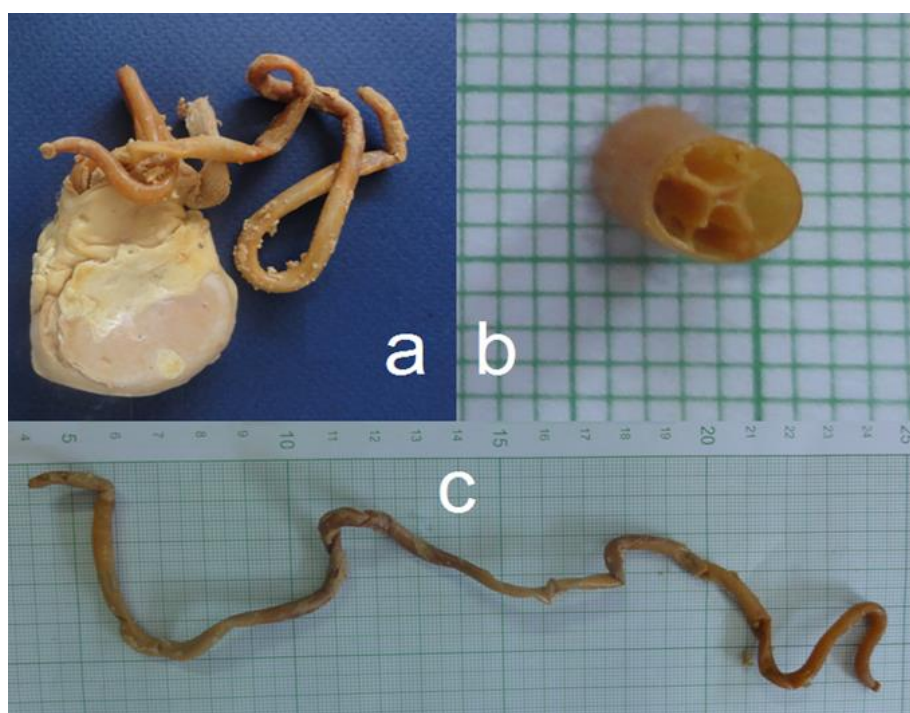


Fig.1: Infected kidney and the measurements of the width and length of the worm (The original identified worm)

Discussion

To search zoonotic helminths in carnivores of wild life, regular road inspection for carcasses has been regarded valuable. *Diectophyme renale* a food borne helminthic infection can be acquired by humans with consumption of aquatic parasitized edible items occasionally worldwide.

The existence of giant kidney worm amongst carnivores in the Caspian Sea littoral has been previ-

ously observed during the surveys carried out in the country. Prevalence of infection in stray dogs and jackals in the north of Iran was reported 13% and 35% respectively (8). In the same region, *Rutilus frisii kutum* a type of fish has been also found infected with the parasite

(10). Referring to the only human infection of *D. renale* in Iran which was occurred in a 28 years old female in 1968, concerns that the issue will be emphasized in the country. The clinical signs and

symptoms, described for the patient at the time of admission, was a long term of fever, hepatomegaly and eosinophilia (9). The above-recorded clinical manifestations are partially alike to that of fascioliasis and visceral larval migrants; two well-regarded helminthic infection in northern Iran (11-13). Since the Caspian Sea littoral is an attractive tourist destination in the country, careful observation should be considered in order to avoid travelers from acquiring the rare possible infections, endemic in the areas where they enjoy living temporarily. The present report is released after nearly ten years of intensive inspection for the parasite with negative results in carnivores and laboratory double checks of suspected human urine samples. To avoid of neglected human occurrence with *D. renale*, doctors and the clinicians in the region should be continually kept noticed about existed potential of infection transmission in the country.

Ethical considerations

Ethical issues (including plagiarism, informed consent, misconduct, data fabrication and/or falsification, double publication and/or submission, redundancy) have been completely observed by the authors.

Acknowledgments

The authors would like to acknowledge Mr.Ali Rahimi for his kind participation in sample collection during a long period of field activities. Our special thanks is also due to Ms. Neda Mirsepahi for her worth mentioning efforts in the laboratory of helminthology. The authors declare that there is no conflict of interests.

References

1. Anderson RC (2000). Nematode parasites of vertebrates: their development and transmission. 2nded. CABI publishing. UK, New york. pp.:650.
2. Cheng, TC (2012). *General parasitology*. 2nded. Elsevier Science. PP.:827.

3. Ferreira VL, Medeiros FP, July JR, Raso TF (2010). *Diectophyma renale* in a dog: Clinical diagnosis and surgical treatment. *Vet Parasitol*, 168(1): 151-5.
4. Gargili A, Firat I, Toparlak M, ÇetÜnkaya H (2002). First case report of *Diectophyme renale* (Goeze, 1782) in a dog in Istanbul, Turkey. *Turk J Vet Anim Sci*, 26(5):1189-1191.
5. Verocai, GG, Measures LN, Azervedo FD, et al. (2009) *Diectophyme renale* (Goeze, 1782) in the abdominal cavity of a domestic cat from Brazil. *Vet Parasitol*, 161(3): 342-344.
6. Gu Y, Li G, Zhang J, Zhang y (2012). *Diectophyma renale* infection masquerading as a malignancy. *Kidney Int*, 82(12): 1342-1342.
7. Urano Z, Haseqawa H, Katsumata T, Toriyama K, et al. (2001). *Diectophymatid* nematode larva found from human skin with creeping eruption. *J Parasitol*, 87(2): 462-5.
8. Sadighian A, Amini F (1967). *Diectophyma renale* (Goeze, 1782) Stiles, 1901 in stray dogs and jackals in Shasavar area, Caspian region, Iran. *J Parasitol*, 53(5): 961.
9. Hanjani A, Sadighian A, Nikakhtar B, Arfaa F (1968). The first report of human infection with *diectophyma renale* in Iran. *Trans R Soc Trop Med Hyg*, 62(5): 647-8.
10. Mohammad R, Mobedi I, Aghazadeh Meshgi M, Jalali B, et al. (2011). Occurrence and intensity rate of internal Metazoan parasites in *Rutilus frisii kutum* and the first report of *octophyma renale* (Nematoda: Diectophymidae) in Iran. *World J Zoology*, (1): 91-97.
11. Ashrafi K, Massoud J, Holakonei K, Mahmoodi M, et al. (2004). Evidence suggesting that *Fasciola gigantica* might be the most prevalent causal agent of fascioliasis in northern Iran. *Iran J Public Health*, 2004. 33(4): 31-7.
12. Moghaddam A, Massud J, Mahmood M, Mahvi AH, et al. (2004). Human and animal fascioliasis in Mazandaran province, northern Iran. *Parasitol Res*, 94(1): 61-9.
13. Sharif M, Daryani G, Barzegar G, Nasrolahei M, et al. (2010). Seroprevalence of toxocarasis in schoolchildren in Northern Iran. *Pak J Biol Sci*, 13(4): 180-4.