

Case report

Open Access

A rare case of concomitant huge exophytic gastrointestinal stromal tumor of the stomach and Kasabach-Merritt phenomenon

Taiji Watanabe*, Kohei Segami, Takahiro Sasaki, Hatsuya Kawashima, Takeharu Enomoto, Yuji Jinnouchi, Satoshi Koizumi, Naotaka Tobe, Joh Sakurai, Tsukasa Shimamura, Tadashi Suda, Takeshi Asakura, Hiroshi Nakano, Tanaka Ichiroh and Takehito Otsubo

Address: Department of Gastroenterological and General Surgery, St. Marianna University School of Medicine 2-16-1, Sugao Miyamae, Kawasaki, Kanagawa, Japan

Email: Taiji Watanabe* - taiji_watanabe@marianna-u.ac.jp; Kohei Segami - k2segami@marianna-u.ac.jp; Takahiro Sasaki - sasa09302005@marianna-u.ac.jp; Hatsuya Kawashima - hatuya@marianna-u.ac.jp; Takeharu Enomoto - takeharu@marianna-u.ac.jp; Yuji Jinnouchi - y2jinno@marianna-u.ac.jp; Satoshi Koizumi - satoshi.koizumi@excite.co.jp; Naotaka Tobe - t3tobe@marianna-u.ac.jp; Joh Sakurai - j2sakurai@marianna-u.ac.jp; Tsukasa Shimamura - t2shimamura@marianna-u.ac.jp; Tadashi Suda - t-suda.med3asa@marianna-u.ac.jp; Takeshi Asakura - t3asa@marianna-u.ac.jp; Hiroshi Nakano - nakahiro@marianna-u.ac.jp; Tanaka Ichiroh - ichiro28@marianna-u.ac.jp; Takehito Otsubo - otsubo@marianna-u.ac.jp

* Corresponding author

Published: 1 June 2007

Received: 28 February 2007

World Journal of Surgical Oncology 2007, 5:59 doi:10.1186/1477-7819-5-59

Accepted: 1 June 2007

This article is available from: <http://www.wjso.com/content/5/1/59>

© 2007 Watanabe et al; licensee BioMed Central Ltd.

This is an Open Access article distributed under the terms of the Creative Commons Attribution License (<http://creativecommons.org/licenses/by/2.0>), which permits unrestricted use, distribution, and reproduction in any medium, provided the original work is properly cited.

Abstract

Background: We report an extremely rare case of concomitant huge exophytic GIST of the stomach and Kasabach-Merritt phenomenon (KMP).

Case presentation: The patient was a 67-year-old man experiencing abdominal distension since September 2006. A physical examination revealed a 25 × 30 cm hard mass that was palpable in the middle and lower left abdomen minimal intrinsic mobility and massive ascites. Since the admitted patient was diagnosed with DIC, surgery could not be performed. The patient received a platelet transfusion and the DIC was treated. Due to this treatment, the platelet count recovered to 7.0×10^4 ; tumor resection was performed at 16 days after admission. Laparotomy revealed a huge extraluminal tumor arising from the greater curvature of the stomach that measured 25 × 30 cm and had not ruptured into the peritoneal cavity or infiltrated other organs. Partial gastric resection was performed. The resected mass measured 25 × 25 × 20 cm. In cross section, the tumor appeared hard and homogenous with a small polycystic area. Histopathology of the resected specimen showed large spindle cell GIST with >5/50 HPF (high-power field) mitotic activity. The postoperative course was uneventful, and the coagulopathy improved rapidly.

Conclusion: Since the characteristic of tumor in this case was hypervascularity with bleeding and necrotic lesions, coagulopathy was thought to be caused by the trapping of platelets within a large vasculized tumor mass.

Background

Gastrointestinal stromal tumors (GISTs) are mesenchymal tumors of the digestive tract with various clinical and biological characteristics. The expression of c-kit distinguishes GISTs from true leiomyomas, leiomyosarcomas, and other mesenchymal tumors of the GI tract [1-3]. The stomach (60%–70%) and small intestine (20%–30%) are the most common sites for GISTs [1,2].

An association between a vascular lesion and life-threatening coagulopathy is termed as the Kasabach-Merritt phenomenon (KMP). It includes thrombocytopenia, microangiopathic hemolytic anemia, and disseminated intravascular coagulopathy (DIC). Generally, KMP is the most characteristic symptom of giant hemangiomas [4-7]. To our knowledge, no case of concomitant GIST and KMP has been reported thus far. Here, we report an extremely rare case of concomitant huge exophytic GIST of the stomach and KMP.

Case presentation

The patient was a 67-year-old man experiencing abdominal distension since September 2006. In October 2006, the abdominal fullness became progressive, and he had hard general fatigue. There was no history of vomiting, fever, or gastrointestinal bleeding. Renal failure occurred due to diabetes mellitus (DM). On admission in November 2006, a physical examination revealed a 25 × 30 cm hard mass that was palpable in the middle and lower left abdomen minimal intrinsic mobility and massive ascites.

An upper gastrointestinal barium study and gastric endoscopic examination indicated no anomalies. Tumor findings of Doppler ultrasonography showed a hypoechoic lesion with a hypervascular area (Figure 1). An abdominal

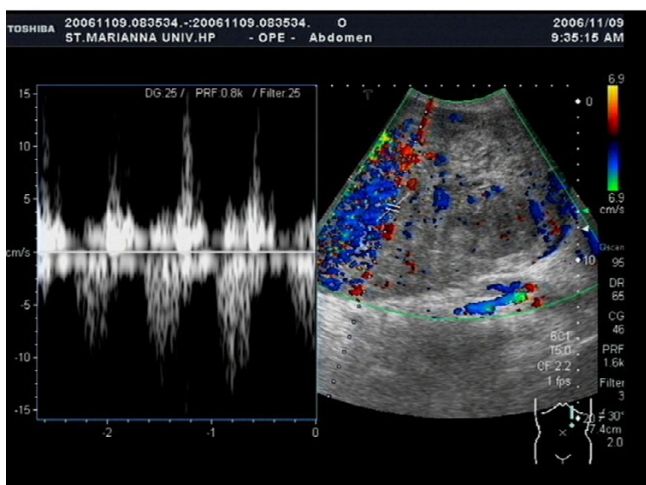


Figure 1
Doppler ultrasonography shows hypervascular area in the tumor.

computed tomography (CT) scan showed a huge heterogeneous mass sized 20 × 25 cm extending from the greater curvature of the middle body of the stomach (Figure 2). Abdominal magnetic resonance imaging (MRI) was performed, and almost the entire abdominal cavity was visualized in the coronal view. The irregular wall of the lesion exhibited a low intensity signal on the T1-weighted image and a high-intensity signal on the T2-weighted image (Figure 3).

Routine biochemical investigation revealed hypoalbuminemia, renal dysfunction, and hyperglycemia. Since the admitted patient was diagnosed with DIC (platelet count: 2000 mm³, FDP: 135.4 μg/ml, PT: 1.20, SIRS score: over 3 heads) surgery could not be performed. The patient received a platelet transfusion of 20 units each day 6 times, and the DIC was treated with nafamostat mesilate and fresh-frozen plasma. Due to this treatment, the platelet count recovered to 7.0 × 10⁴; tumor resection was performed at 16 days after admission. Laparotomy revealed a huge extraluminal tumor arising from the greater curvature of the stomach that measured 25 × 30 cm and had not ruptured into the peritoneal cavity or infiltrated other organs (Figure 4A). An attaching pedicle approximately 3 cm in breadth was observed in the greater curvature of middle body of the stomach. Partial gastric resection was performed (Figure 4A).

The resected mass measured 25 × 25 × 20 cm. In cross section, the tumor appeared hard and homogenous with a small polycystic area (Figure 4B). Histopathology of the resected specimen showed large spindle cell GIST with >5/50 HPF (high-power field) mitotic activity (Figure 5A). No evidence of infiltration was observed in the resected margins of the stomach wall. Immunohistochemical staining was strongly positive for CD34 and CD117 (Figure 5B and 5C), and negative for α-SMA, S-100 and Desmin.

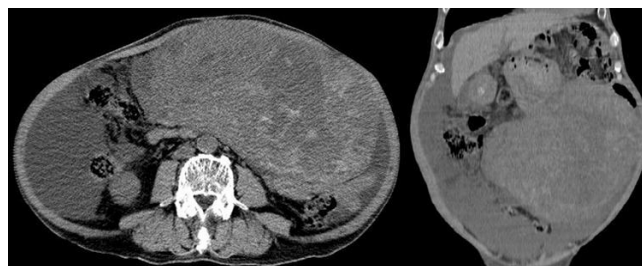


Figure 2
Abdominal computed-tomography shows a huge heterogeneous mass with a thick and irregular wall sized 20 × 25 cm extending from the greater curvature of the middle of the stomach.

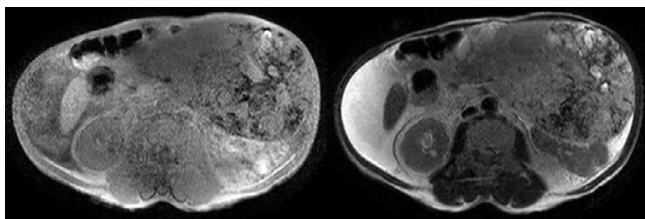


Figure 3
Abdominal MRI shows huge inhomogeneous mass lesion can be identified in the right side of the intra-abdomen.

The postoperative course was uneventful, and the coagulopathy improved rapidly. The patient was carefully followed up regularly. Imatinib mesylate (Gleevec™/Novartis Pharma AG, Basel, Switzerland) was administered orally 300 mg per day because the patient displayed renal dysfunction (serum creatinine: 3.98, blood urea nitrogen (BUN): 41.5)

Discussion

The definition of a GIST has been changing with immuno-histochemical and molecular technical advances [8]. It is widely accepted that a GIST is a mesenchymal tumor that expresses the c-kit oncoprotein or has a mutation in either the c-kit or the platelet-derived growth factor receptor-alfa (PDGFRA) gene [9]. Several studies have revealed various

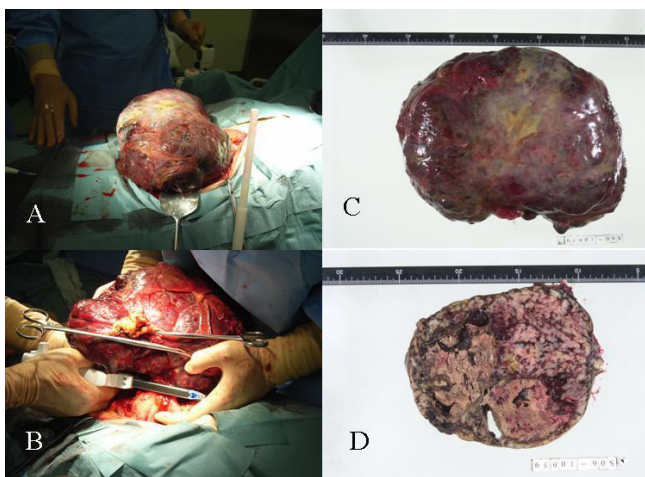


Figure 4
A and B) huge solid tumor arising from the greater curvature of the stomach that measured 25 × 25 cm and had not ruptured into the peritoneal cavity or infiltrated other organs. An attaching pedicle approximately 3 cm in breadth was observed in the greater curvature of middle body of the stomach. Partial gastric resection was performed. C and D) The resected mass measured 25 × 25 × 20 cm. In cross section, the tumor appeared hard and homogenous with a small polycystic area and calcification.

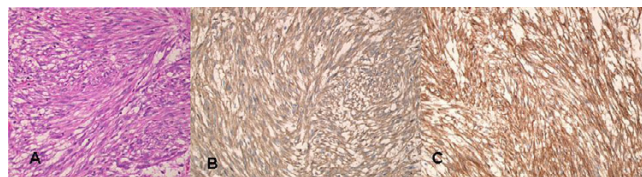


Figure 5
Photomicrograph showing A). Microscopically, the tumor was characterized by fascicular and interlacing proliferation of the spindle-shaped cells.(Hematoxylin and Eosin × 200) B). Histopathology slide after Immunostaining for CD34: Tumor cell show positivity after CD34 staining. C) Histopathology slide after Immunostaining for CD117: Tumor cell show positivity after CD117 staining.

types of c-kit mutations, including mutations in the juxtamembrane (exon 11), extracellular (exon 9), and tyrosine kinase (exon 13 and 17) domains [9].

Fletcher *et al.*, reported a classification for malignancies that is based on tumor size and the number of mitotic divisions [10]. They classified gastric GISTs into the following four groups: very low risk (<2 cm in size and <mitoses/50 HPF), low risk (2~5 cm and < mitoses 5/50 HPF), intermediate risk (<5 cm and < mitoses/50 HPFs or 5–10 cm and <5/50 HPF), high risk (>5 cm and >5/50 HPF or >10 cm and any mitotic rate or any size and >10/50 HPF). According to this classification, our case was classified as high risk. Moreover, Carrillo *et al.*, reported that a high MIB-1 index (>22%, in the most active area) was the most powerful predictor of poor survival [11]. The highest MIB-1 index value for the present patient was 28%, suggesting the malignant nature of the tumor.

The designation of KMP has been applied to cases in which vascular lesions occur in association with profound thrombocytopenia and hypofibrinogenemia with fibrin degradation products. It is important to rule out visceral lesions in the liver, spleen, and retroperitoneum, and hematologic malignancies such as leukemia and other malignancies that can cause a similar cutaneous presentation such as neuroblastoma [12]. The disseminated intravascular coagulation is caused by an activation of the clotting cascade and the formation of intravascular fibrin, and can results in microangiopathic hemolysis and occasionally red cell fragmentation seen on the peripheral blood smear [13]. Since the characteristic of tumor in this case was hypervascularity with bleeding and necrotic lesions, coagulopathy was thought to be caused by the trapping of platelets within a large vasculized tumor mass. Only a few reports described the coincidence of consumption coagulopathy and angiomatous tumor associated with KMP in the adulthood [7,15]. Moreover, although KMP is believed to be caused by clotting and fibrinolysis

within giant hemangiomas and despite several cases of giant GIST of the stomach being reported, no case of concomitant gastric GIST and KMP has been reported thus far [8]. Because the predisposition to bleeding (observed in KMP) is the primary cause of death, aggressive treatment is required.

Imatinib mesylate, which is a competitive inhibitor of certain tyrosine kinases including intracellular kinases ABL and the BCR-ABL fusion proteins present in some leukemias, and PDGFRA, is the first effective drug for GIST [[16,17], 18]. The use of Gleevec as an adjuvant is currently being explored with on going randomized phase III trials.

Conclusion

Since the characteristic of tumor in this case was hypervascularity with bleeding and necrotic lesions, coagulopathy was thought to be caused by the trapping of platelets within a large vasculized tumor mass.

Competing interests

The author(s) declare that they have no competing interests.

Authors' contributions

TW designed the study and participated in the writing process. KS, TS, HK and TE designed the study, carried out the data and picture acquisition as well as bibliographic research, drafted and revised the manuscript. YJ, SK, NT, JS and TS participated in manuscript revision process. TS, TA, HN and TO they participated in the editing process. All authors read and approved the final manuscript.

Acknowledgements

Written informed consent was obtained from the patient for publication of this case report.

References

- Miettinen M, Lasota J: **Gastrointestinal stromal tumors (GISTs): definition, occurrence, pathology, differential diagnosis and molecular genetics.** *Pol J Pathol* 2003, **54**:3-24.
- Mehta Rajiv M, Sudheer Vayoth O, John Anil K, Nandakumar Raghavan R, Dhar Puneet S, Surendran Sudhindran, Vallath Balakrishnan: **Spontaneous rupture of giant gastric stromal into gastric lumen.** *World J Surg Oncol* 2005, **3**:11.
- Behranwala KA, Spalding D, Wotherspoon A, Fischer C, Thompson JA: **Small bowel gastrointestinal stromal tumors and amullary cancer in type I neurofibromatosis.** *Word J Surg Oncol* 2004, **2**:1.
- Brouwers MA, Peeters PM, de Jong KP, Haagsma EB, Klompmaker JJ, Bijleveld CM, Zwaveling JH, Slooff MJ: **Surgical treatment of giant hemangioma of the liver.** *Br J Surg* 1997, **84**:314-316.
- Mereno Egea A, Del Pozo Rodriguez M, Vincent Cantero M, Abellan Atenza J: **Indication for surgery in the treatment of hepatic hemangioma.** *Hepatogastroenterology* 1996, **43**:422-426.
- Gedaly R, Pomposlli JJ, Pomfret EA, Lewis WD, Jenkins RL: **Cavernous hemangioma of the liver.** *Arch Surg* 1999, **134**:407-411.
- Kumashiro Y, Kasahara M, Nomoto K, Kawai M, Sasaki K, Kiuchi T, Tanaka K: **Living donor liver transplantation for giant hepatic hemangioma with Kasabach-Merritt syndrome with a posterior segment graft.** *Liver transplantation* 2002, **8**:721-724.
- Hashiba T, Oda K, Koda K, Takiguchi N, Seike K, Miyazaki M: **A gastrointestinal stromal tumor in the stomach: usefulness of computed tomographic volumetry.** *Gastric Cancer* 2004, **7**:260-265.
- Hirota S, Isozaki K, Moriyama Y, Hashimoto K, Nishida T, Ishiguro S, et al.: **Gain-of-function mutations of c-kit in human gastrointestinal stromal tumors.** *Science* 1998, **279**:577-580.
- Fletcher CD, Berman JJ, Corless C, Gorstein F, Lasota J, Longley BJ, Miettinen M, O'Leary TJ, Remotti H, Rubin BP, Shmookler B, Sobin LH, Weiss SW: **Diagnosis of gastrointestinal stromal tumors: a consensus approach.** *Hum Pathol* 2002, **33**:459-465.
- Carrillo R, Candia A, Rodriguez-Peralto JL, Caz V: **Prognostic significance of DNA ploidy and proinfiltrating index (MIB-1 index) in gastrointestinal stromal tumors.** *Hum Pathol* 1997, **28**:160-165.
- Muzaffar AR, Friedrich JB, Lu KK, Hanel DP: **Infantile fibrosarcoma of the hand associated with coagulopathy.** *Plast Reconstr Surg* 2006, **117**:81e-86e.
- Pousti TJ, Upton J, Loh M, Grier H: **Congenital fibrosarcoma of the upper extremity.** *Plast Reconstr Surg* 1998, **102**:1158-1162.
- Bernathova M, Jaschke W, Pechlahner C, Zelger B, Bonder G: **Primary angiosarcoma of the breast associated Kasabach-Meritt syndrome during pregnancy.** *The Breast* 2006, **15**:255-258.
- DeMatteo RP, Lewis JJ, Leung D, Mudan SS, Woodruff JM, Brennan MF: **Two hundred gastrointestinal stromal tumors: Recurrence patterns and prognostic factors of survival.** *Ann Surg* 2000, **231**:51-58.
- Savage DG, Antman KH: **Imatinib mesylate – A new oral targeted therapy.** *N Engl J Med* 2002, **346**:683-693.
- Guanghi D, Jiahe Y, Shuqun C, Liu K, Li N, Shuhi Z, Wenming, Mengchao W: **A rare case of rapid growth of exophytic gastrointestinal stromal tumor of the stomach.** *Dig Dis Sci* 2005, **50**:820-823.

Publish with **BioMed Central** and every scientist can read your work free of charge

"BioMed Central will be the most significant development for disseminating the results of biomedical research in our lifetime."

Sir Paul Nurse, Cancer Research UK

Your research papers will be:

- available free of charge to the entire biomedical community
- peer reviewed and published immediately upon acceptance
- cited in PubMed and archived on PubMed Central
- yours — you keep the copyright

Submit your manuscript here:
http://www.biomedcentral.com/info/publishing_adv.asp

