



Restorative management using hybrid ceramic of a patient with severe tooth erosion from swimming: a clinical report

Chaimongkon Peampring*

Department of Prosthetic Dentistry, Faculty of Dentistry, Prince of Songkla University, Hat Yai, Thailand

This clinical report presents the clinical appearance and treatment approach in a case of excessive anterior teeth erosion resulted from swimming in a poorly-chlorinated swimming pool. Clinical findings revealed tooth sensitivity, severe enamel erosion resembling veneer preparations, and the presence of anterior open bite. A novel hybrid ceramic (Vita Enamic) was chosen for fabricating full-coverage crowns for this patient. After 6-months follow-up, the tooth sensitivity disappeared and the patient was satisfied with esthetic outcome. The hybrid ceramic restorations can be recommended with no complications. [*J Adv Prosthodont 2014;6:423-6*]

KEY WORDS: Dental erosion; Swimming; Hybrid ceramic; Vita enamic

INTRODUCTION

Dental erosion is defined as the loss of tooth structure resulted from chemical dissolution, which was produced by non-bacterial produced acid.¹ The etiology of dental erosion is multi-factorial in origin. It can be produced by intrinsic or extrinsic acid exposure based upon the patient history. The intrinsic factor of dental erosion is the attacking of gastric acid on the teeth in the case of vomiting and gastro-esophageal reflex.² The extrinsic origin is caused by consumption of acidic beverages, medication, or the occupational environment.³ It has been reported that the exposure of the tooth surface to acidic beverages with pH below 5.5 can cause enamel dissolution. Its progression can

be accelerated by the combination of frequent acidic diet consumption and exposure to potentially high erosive environments.⁴

Previous clinical reports showed that poorly chlorinated swimming pools have been a contributing factor to dental erosion among competitive swimmers. An insufficient buffering system of the swimming pool resulted in low pH values of the pool water that could cause erosion of teeth. The maxillary and mandibular anterior teeth are commonly affected by dental erosion caused by swimming. The characteristics of the typical lesion are severe loss of enamel creating diastema, definite margins of the lesion resembling anterior veneer preparation, wear of the incisal edges resulting in the reduction of clinical crown height, and tooth hypersensitivity.^{1,5,6} Definitive treatment for this type of lesion aims to eliminate hypersensitivity, replace lost tooth structure, and establish proper esthetics. Several treatment modalities can be performed depending on the severity of the tooth surface loss such as direct composite resin restorations, laminate veneers, and complete coverage crowns.⁶ To gain desirable esthetic outcomes, metal-free restorative materials are usually recommended to restore the extensively damaged anterior teeth.⁷ The objective of this case report is to describe the clinical appearance and treatment approach in a case of severe dental erosion caused by swimming in a poorly maintained swimming pool with low pH pool water.

Corresponding author:
Chaimongkon Peampring
Department of Prosthetic Dentistry, Faculty of Dentistry, Prince of Songkla University, 15 Kanchanawanit Road, Hat Yai, Thailand
Tel. 6674-429-874; e-mail, mongkon.5c@gmail.com
Received 24 February, 2014 / Last Revision 18 June, 2014 / Accepted 5 August, 2014

© 2014 The Korean Academy of Prosthodontics
This is an Open Access article distributed under the terms of the Creative Commons Attribution Non-Commercial License (<http://creativecommons.org/licenses/by-nc/3.0>) which permits unrestricted non-commercial use, distribution, and reproduction in any medium, provided the original work is properly cited.

The Dental Hospital at the Faculty of Dentistry, Prince of Songkla University, Thailand provided all supports for this clinical report.

CASE REPORT

A 48-year-old man presented with a chief complaint of hypersensitivity and unacceptable esthetic appearance of his anterior teeth. The patient went to see a dentist at a private clinic to receive dental treatment for his anterior teeth erosion. The dentist performed history taking and found no obvious intrinsic or extrinsic causes of the erosive lesion. Thus, the patient was referred to the Prosthodontic Clinic at the Faculty of Dentistry, Prince of Songkla University, Thailand for consultation and joint management. Medical and dental history taking were performed to verify whether the patient was exposed to any cause of dental erosion or not. The patient mentioned that he rarely consumed acidic foods or beverages and had no sign of acid regurgitation presented. Apparently, it was found that the patient had been routinely swimming for 3 months. Since then, he noticed that his anterior teeth had been eroded. He stopped swimming 2 weeks ago because of the extreme sensitivity of the anterior teeth. The patient was asked to collect a sample of pool water from the swimming pool that he routinely went to swim in. The sample of pool water was eval-

uated for a pH value using a pH meter (Precisa, pH900, Precisa Gravimetrics AG, Dietikon, Switzerland). The pH value for the pool water was 4.5, which was lower than the critical value for enamel dissolution.⁸ Moreover, the patient reported that he spent more than an hour swimming each time, which meant that he had been exposed to low pH pool water for more than an hour every day over 3 months.

Intra-oral examination revealed loss of enamel on the labial and incisal surface of the maxillary anterior teeth. Four mandibular incisor teeth presented with loss of enamel on the facial surface and there was excessive reduction of the incisal edges. Diastemas appeared between most of the teeth, and the incisal plane was uneven (Fig. 1). The patient's esthetic appearance was affected by the irregular incisal edge position of the remaining tooth structure. Thus, he had no confidence to smile. The erosive lesion appeared with well-defined finish lines along the free gingival margins resembling veneer preparation (Fig. 2). There was no dental caries which existed and his periodontal health was fine. The pulp vitality test showed no signs of pulpal pathology. The occlusal function and vertical dimension of occlusion appeared to be normal since the patient had adequate and stable posterior stops. A significant finding in this case was the maxillary-mandibular relationship, which appeared to have anterior open bite due to the loss of tooth structure. However, the patient had no difficulty in pronouncing an "S" and "F" sound during function. During the comprehensive oral examination, the patient complained that his teeth were extremely sensitive to air blow. The diagnosis in this case was severe anterior tooth surface loss, resulting from long-term exposure to low pH in swimming pool water.

The treatment goals in this case were to restore the damaged tooth structure and reestablish the esthetics of the smile. Definitive treatment modalities for excessive tooth erosion include direct composite resin restorations, porcelain laminated veneers, and complete coverage crowns.

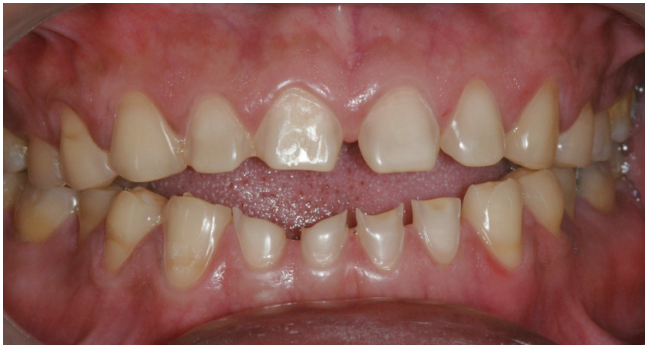

Fig. 1. Preoperative frontal view at maximum intercuspal position.

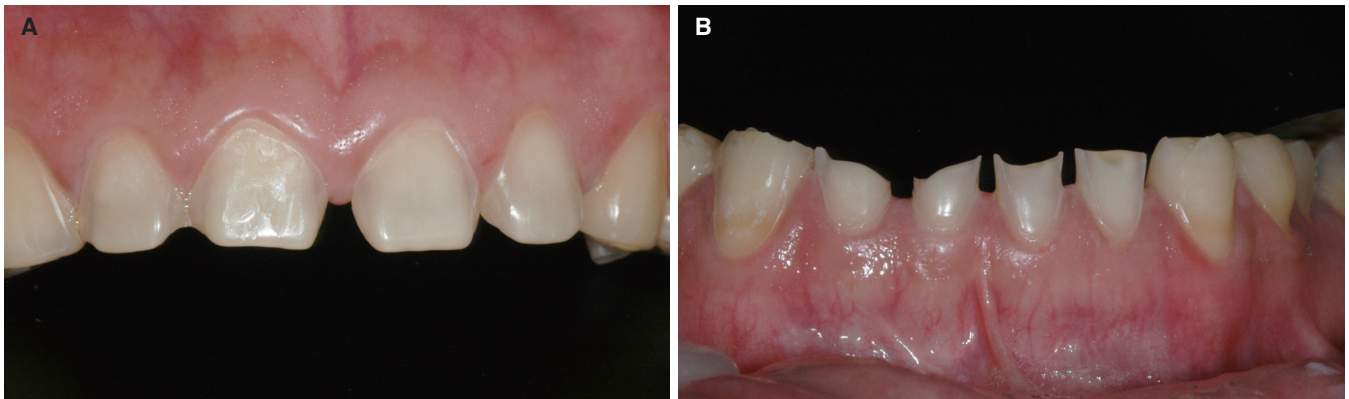


Fig. 2. (A) Dental erosion patterns in maxillary anterior teeth, (B) dental erosion patterns in mandibular anterior teeth.

Since the remaining tooth structures were insufficient to support composite resin restorations and porcelain-laminated veneers and the optimal clinical crown height needed to be restored, complete coverage metal-free crown restorations were the treatment of choice in this case for long-term durability and esthetic satisfaction.

Irreversible hydrocolloid impressions were performed for fabricating diagnostic casts. A face-bow transfer was made and the casts were mounted in maximum intercuspation on a semi-adjustable articulator (Denar Mark II, Whip Mix, Louisville, KY, USA). Diagnostic wax-up was made on the casts with the optimal tooth proportion and with 1 mm horizontal and vertical overlap. The wax-up was transferred to the patient's mouth using the direct intra-oral mock-up procedure with bis-acryl provisional material (Protemp 4, 3M ESPE, Seefeld, Germany). The mock-up (Fig. 3) was adjusted to obtain desirable esthetics, phonetics and function, and it was subsequently duplicated for using as a guideline for fabricating provisional restorations. The splinted provisional restorations were made with heat-polymerized polymethyl methacrylate (Namilon, American Tooth Industries, Oxnard, CA, USA) prior to the tooth preparation.

It was decided to use a novel hybrid ceramic (Vita Enamic, Vita, Zahnfabrik, Germany) for constructing metal-free restorations in this case. Vita Enamic is an interpenetrating phase composite material that combines the properties of ceramic and polymer. This material consists of a fine microstructure of feldspathic ceramic matrix and an acrylate-based polymer network. As a result, wear characteristics, flexural properties, and elasticity of this material are similar to dentin.^{9,10} The minimum thickness required to ensure clinical success of restorations made from VITA ENAMIC is at least 0.8 mm circumferentially. Therefore, the amount of tooth reduction required is less than tooth preparation designs for other all-ceramic materials.¹⁰ Maxillary incisor and canine teeth were prepared with a 1

mm wide chamfer finish line and mandibular incisor teeth with a 0.8 mm wide chamfer finish line. No additional incisal reduction was required since the incisal edges were eroded. Internal line angles were rounded in all prepared teeth. A double cord gingival retraction was performed and final impressions were taken using a polyether impression material (Impregum Soft, 3M ESPE, Seefeld, Germany).

Shade selection was made using the Vita 3D Master System. Splinted provisional restorations were relined and temporarily cemented (Temp-Bond NE, Kerr, Orange, CA, USA). The impressions were poured in Type IV stone (Silky Rock, Whip Mix, Louisville, KY, USA) and pindexed. The pindexed casts were mounted on an articulator in maximum intercuspation. Laboratory prescription for Vita Enamic crowns were completed and sent to an outside laboratory (T Dental Lab, Bangkok, Thailand). Final restorations were received from the laboratory (Fig. 4).

Clinical try-in and adjustment were performed prior to permanent cementation. Comprehensive esthetics, phonetics, and function were evaluated. The occlusion was assessed to eliminate occlusal interferences, especially on the maxillary and mandibular canines. The edge-to-edge occlusal relationship was established in this case to avoid excessive coronal crown height in both maxillary and mandibular anterior teeth. The intaglio surfaces of the restorations were treated with 5% hydrofluoric acid (VITA CERAMICS ETCH, Vita, Zahnfabrik, Germany) for 60 seconds according to the manufacturer's instruction. The etching gel was completely removed using water spray and the restorations were dried for 20 seconds. Silane was applied to the intaglio surfaces of the crowns and dried completely. Self-adhesive resin cement (Rely X Unicem, 3M ESPE, Seefeld, Germany) was used to cement restoration following the manufacturer's recommendations. Excess cement was removed completely and the special care instructions for ceramic restorations were given to the patient (Fig. 5). After completion, the patient's discomfort and tooth sensitivity disappeared.

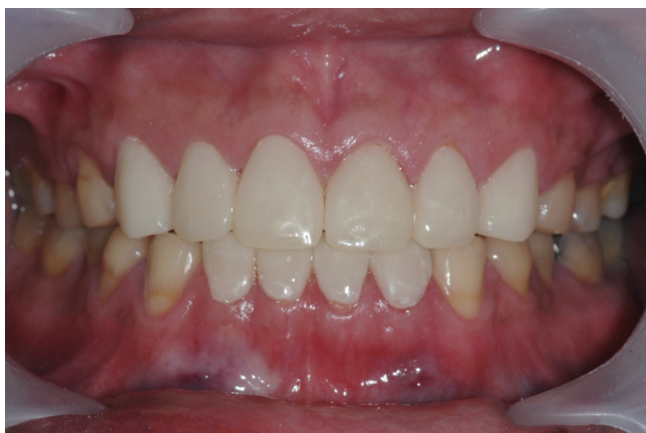

Fig. 3. Direct intra-oral mock-up made from bis-acryl provisional material.

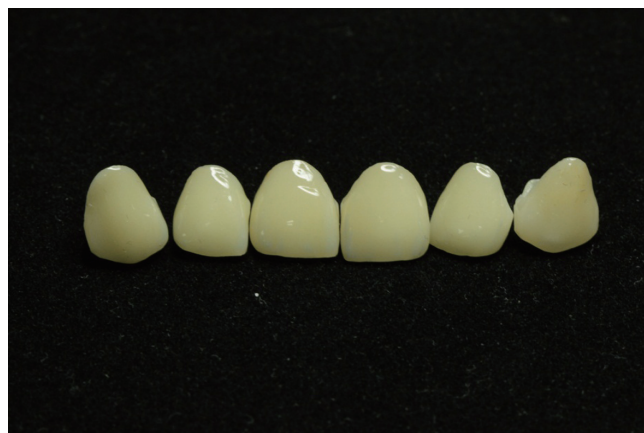

Fig. 4. Final restorations for the maxillary anterior teeth before cementation.

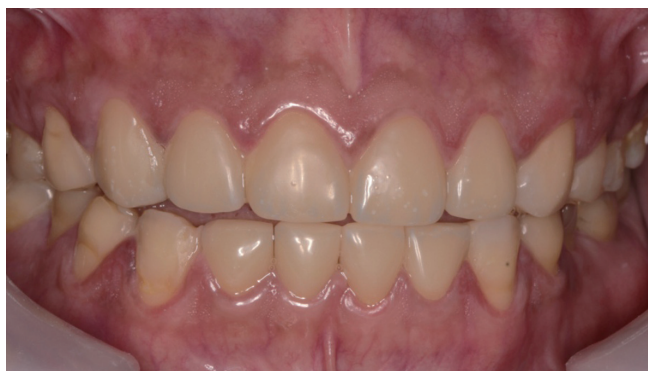

Fig. 5. Postoperative frontal view at maximum intercuspation position.

The patient has been back to swim in a swimming pool with proper chlorination. Esthetics, phonetics, and function were satisfactorily restored. After 6-months follow-up, the restorations were in place with no complications. The periodontal health appeared to be normal. The patient has been maintaining good oral hygiene care of his teeth. Post-treatment monitoring will be followed in every 6 months. Since there have been insufficient clinical report regarding using hybrid ceramic in this type of case, long-term follow-up will be performed for at least 3 years. Further long-term clinical performance will be provided.

DISCUSSION

Previous clinical case reports and *in vitro* studies demonstrated that low pH swimming pool water was a contributing factor of enamel erosion on the anterior teeth.^{5,6} This patient had a significant habit of frequent swimming in an improperly chlorinated swimming pool. The clinical findings in this case fitted with the clinical characteristics of dental erosion caused by exposure to poor-chlorinated pool water. Full coverage restorations were selected to achieve desirable esthetics, function, and long-term durability of the restorations. A novel hybrid ceramic (Vita Enamic) was used as a material of choice to restore this patient. It was chosen because the material requires less tooth preparation and it is more conservative than tooth preparation for other all-ceramic materials. Also, this material consists of a complex interconnected polymer-ceramic microstructure that helps in resistance to chipping.^{9,10} The restorations were cemented with adhesive resin cement since the hybrid ceramic, which contains glassy matrix, can adhesively bonded to the resin cement by using silane solution. Previous study showed that adhesively cemented glass-containing restorations exhibited higher fracture loads compared to the restorations, which were cemented with conventional cements.¹¹ The esthetic outcome of hybrid ceramic restorations appeared to be satisfying for the patient. Finally, oral hygiene instruction was given to the patient. Also, the

patient was instructed to understand the significant influence of swimming in a poorly-maintained swimming pool which could cause severe tooth surface loss, and therefore would further damage his teeth. This case will be followed-up for observing long-term clinical performance.

CONCLUSION

The diagnosis and treatment procedure of a patient with severe anterior teeth erosion from swimming have been described. Hybrid ceramic restorations were fabricated to overcome extreme sensitivity and obtain desirable esthetics, phonetics, and function. The restorations have been in service for 6 months with no complications.

REFERENCES

1. Wiegand A, Attin T. Occupational dental erosion from exposure to acids: a review. *Occup Med (Lond)* 2007;57:169-76.
2. Bartlett DW, Evans DF, Smith BG. The relationship between gastro-oesophageal reflux disease and dental erosion. *J Oral Rehabil* 1996;23:289-97.
3. Scheutzel P. Etiology of dental erosion--intrinsic factors. *Eur J Oral Sci* 1996;104:178-90.
4. Chuajedong P, Kedjarune-Leggat U, Kertpon V, Chongsuvivatwong V, Benjakul P. Associated factors of tooth wear in southern Thailand. *J Oral Rehabil* 2002;29:997-1002.
5. Dawes C, Boroditsky CL. Rapid and severe tooth erosion from swimming in an improperly chlorinated pool: case report. *J Can Dent Assoc* 2008;74:359-61.
6. Jahangiri L, Pigliacelli S, Kerr AR. Severe and rapid erosion of dental enamel from swimming: a clinical report. *J Prosthet Dent* 2011;106:219-23.
7. Hayashi M, Shimizu K, Takeshige F, Ebisu S. Restoration of erosion associated with gastroesophageal reflux caused by anorexia nervosa using ceramic laminate veneers: a case report. *Oper Dent* 2007;32:306-10.
8. Chuenarrom C, Daosodsai P, Benjakul P. Erosive potential of low pH swimming pool water on dental enamel. *J Health Res* 2010;24:91-4.
9. Coldea A, Swain MV, Thiel N. Mechanical properties of polymer-infiltrated-ceramic-network materials. *Dent Mater* 2013;29:419-26.
10. Dirxen C, Blunck U, Preissner S. Clinical performance of a new biomimetic double network material. *Open Dent J* 2013; 7:118-22.
11. Bindl A, Lüthy H, Mörmann WH. Strength and fracture pattern of monolithic CAD/CAM-generated posterior crowns. *Dent Mater* 2006;22:29-36.