

Resolution of severe secondary mitral valve regurgitation following aortic valve replacement in infective endocarditis

SAGE Open Medical Case Reports
Volume 9: 1–5
© The Author(s) 2021
Article reuse guidelines:
sagepub.com/journals-permissions
DOI: 10.1177/2050313X211034377
journals.sagepub.com/home/sco



Jan Oliver Friess¹ , Thomas Bruelisauer², Samuel Hurni³,
Miralem Pasic⁴, Gabor Erdoes¹ and Balthasar Eberle¹

Abstract

We present the case of a patient with infective endocarditis anesthetized for replacement of severely regurgitant aortic valve. Intraoperative transesophageal echocardiography revealed a new diagnosis of severe secondary mitral regurgitation. After aortic valve replacement and tricuspid valve repair, severe mitral regurgitation resolved rapidly without any intervention. In multivalvular disease, instant spontaneous resolution of secondary mitral regurgitation is possible after surgical correction of an aortic regurgitation causing left ventricular volume overload.

Keywords

Multivalvular disease, aortic regurgitation, mitral regurgitation, surgical repair, aortic valve replacement, transesophageal echocardiography

Date received: 11 January 2021; accepted: 5 July 2021

Introduction

Intraoperative transesophageal echocardiography (TEE) during general anesthesia for cardiac surgery is nowadays considered routine in cardiac centers and recommended by guidelines.¹ It allows surgical teams to tailor therapeutic interventions and to control the success of surgical interventions. In a relevant number of cases, unexpected valvular lesions or dysfunctions are identified by intraoperative TEE (up to 15%–30%) and often lead to a change in surgical strategy.^{2,3} When looking for evidence on how to manage “new” intraoperative TEE findings, recommendations for the management of several “single” valvular lesions offer guidance, whereas for numerous constellations involving more than one valve, the perioperative specialist team still cannot revert to robust guidelines.⁴ In these cases, clinical judgment must be used when tailoring management to multiple lesions, comorbidities, frailty, and overall prognosis of an individual patient.^{5–7}

This case of a patient with three combined regurgitant valvular lesions, one of them not described as severe before, elucidates intraoperative time-critical decision-making concerning the surgical strategy.

Case report

A 61-year-old female with a history of intravenous drug abuse (IVDA) presented in a septic state with dyspnea. Her

history included recurrent systemic infective episodes from IV puncture sites and chronic dermal ulcers, which led to right-sided infective endocarditis (IE) 27 years ago with remaining severe tricuspid regurgitation (TR). Anemia (hemoglobin 7.9 g/dL) and chronic kidney disease (creatinine 1.88 mg/dL and eGFR 31 mL/min) were also present. A presumptive diagnosis of recurrent IE was made.

On admission, transthoracic echocardiography (TTE) and a subsequent TEE revealed severe aortic regurgitation (AR) from a flail non-coronary cusp (Classification of regurgitation according to American Society of Echocardiography), with vegetations on all three cusps (Figure 1; Clips 1 and 2 in Supplemental Material).⁴ Whereas tricuspid and mitral valve

¹Department of Anesthesiology and Pain Medicine, Inselspital, Bern University Hospital, University of Bern, Bern, Switzerland

²Department of Anaesthesiology, German Heart Center Berlin, Humboldt University, Berlin, Germany

³Department of Cardiovascular Surgery, Inselspital, Bern University Hospital, University of Bern, Bern, Switzerland

⁴Department of Cardiovascular Surgery, German Heart Center, Humboldt University, Berlin, Germany

Corresponding Author:

Jan-Oliver Friess, Department of Anesthesiology and Pain Medicine, Inselspital, Bern University Hospital, University of Bern, Freiburgstrasse, 3010 Bern, Switzerland.

Email: jan-oliver.friess@insel.ch



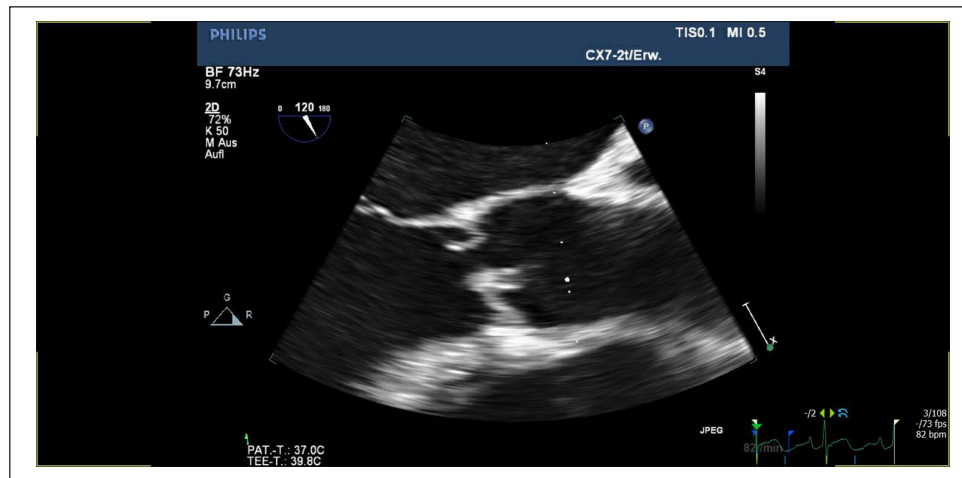


Figure 1. Transesophageal echocardiography (TEE) midesophageal aortic valve long-axis view showing aortic valve endocarditis with perforated cusp and severe aortic regurgitation.

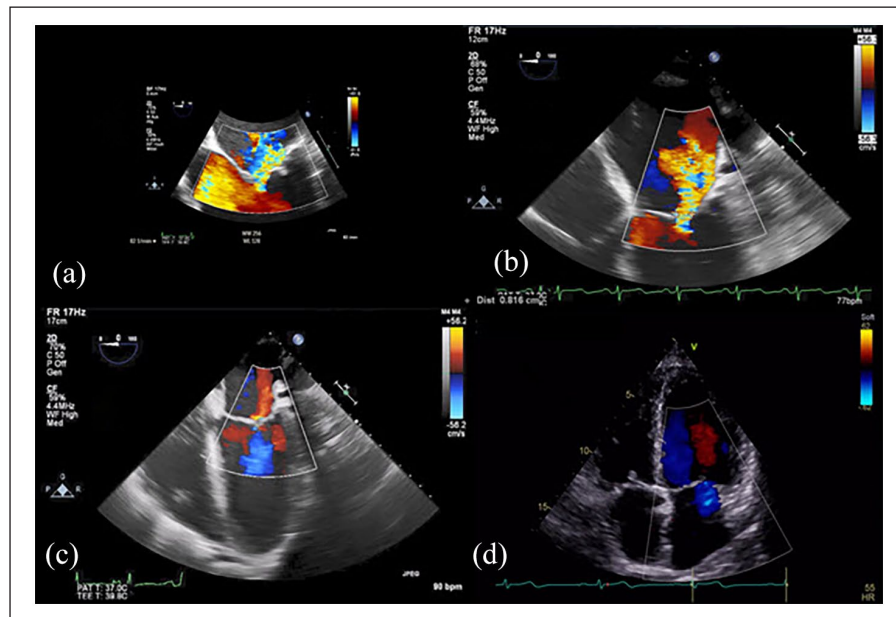


Figure 2. (a) Initial transesophageal echocardiography (TEE) zoomed midesophageal 4-chamber (ME-4CH) view showing moderate mitral regurgitation (MR) (zoomed recording resized to match scale of Panel b). (b) Initial intraoperative TEE vena contracta (VC) measurement of severe MR in ME-4CH view before surgery. (c) Intraoperative TEE after aortic valve replacement (AVR) and cardiopulmonary bypass (CPB). (d) Postoperative transthoracic echocardiography (TTE) apical 4-chamber view with mild MR (4 months after AVR).

LA: left atrium; LV: left ventricle; RA: right atrium; RV: right ventricle.

(MV) were both without apparent vegetations. Pre-existing severe TR was confirmed, and severe mitral regurgitation (MR) was noted in TEE (Figure 2(a); Clip 3 in Supplemental Material). Biventricular function was preserved; however, the left ventricle (LV) was dilated (left ventricular end-diastolic inner diameter (LVEDD) of 65 mm). A coronary computed tomography angiogram described no stenotic lesions. Blood cultures returned positive for *Serratia marcescens*. Despite a given indication for early surgery, valve surgery was deferred

until her poor overall medical state had improved to the point where high-risk cardiac surgery could be discussed with her.⁸ After a total of 3 weeks of appropriate antibiotic therapy, a TTE exam confirmed the findings of the initial echocardiography studies except for a now mild MR (Clip 4 in Supplemental Material) with a dilated LV (LVEDD 58 mm; blood pressure 123 mmHg systolic, 56 mmHg diastolic, and 78 mmHg mean arterial pressure; heart rate 99/min). The patient was scheduled for combined aortic valve (AV)

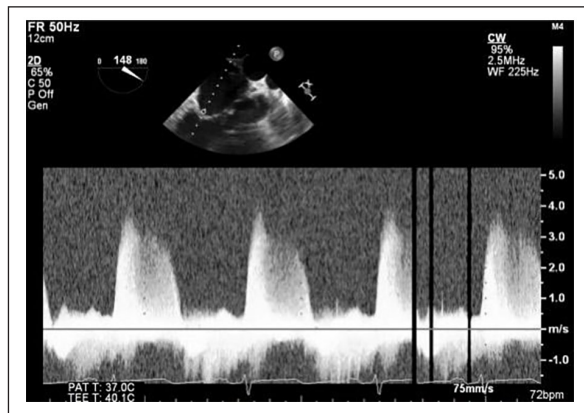


Figure 3. Intraoperative transesophageal echocardiography (TEE) with pre-surgical continuous wave (CW) Doppler profile of the mitral regurgitation jet.

replacement (biological prosthesis) and tricuspid valve (TV) repair.

After an uneventful induction of anesthesia, the intraoperative initial TEE exam confirmed vegetations on all three AV cusps, the presence of severe AR, and also its mechanism as described in the preoperative exam. In contrast to the latest preoperative TTE exam, the initially performed intraoperative TEE revealed severe-grade MR (vena contracta (VC), 8 mm; PISA method quantification: effective regurgitant orifice area (EROA), 0.55 cm²; regurgitant volume, 63 mL, all measured in midesophageal long axis view), with a dense and notching regurgitant jet (Figures 2(b) and 3; Clip 5 in Supplemental Material).⁴ Left cavities were dilated (LVEDD, 62 mm; MV diameter, 38 mm ME commissural view, 27 mm ME LAX view) but left ventricular function was preserved (Clip 6 in Supplemental Material). The mechanism of MR appeared mixed, as there was malcoaptation (Carpentier's Classification IIIb) but also some thickening of both leaflets. No vegetations, perforations, leaflet prolapsed, or flail were seen on the MV apparatus. At the time of this exam, the blood pressure was normal (125 mmHg systolic, 50 mmHg diastolic, and 75 mmHg mean arterial pressure, heart rate 73 per minute).

Interdisciplinary discussion of the new finding arrived at the decision to continue with the planned double-valve procedure, that is, aortic valve replacement (AVR) and TV repair, in line with class I guideline recommendations.^{6,9} Given the patient's poor general condition and numerous comorbidities, one important aspect was to limit time on cardiopulmonary bypass (CPB) to the necessary minimum. Although severe AR appeared as primary cause for volume overload of the LV, with the latter mechanism aggravating severe MR, it remained uncertain at that point whether correction of AR would also significantly reduce severity of MR.

The decision was to test MV function during reperfusion after AVR and TV repair, before considering a triple valve

procedure. Indeed, TEE on partial CPB during reperfusion as well as after complete weaning from CPB showed sustained improvement of the formerly severe- to mild-grade MR (Figure 2; Clip 7 in Supplemental Material), this classification also held true when the MV was carefully challenged with elevated afterload by norepinephrine (100 mmHg systolic, 56 mmHg diastolic, and 70 mmHg mean arterial pressure, heart rate 89 per minute). Two postoperative follow-up echocardiograms confirmed the presence of a merely mild MR (one 6 days and the other exam 4 months after surgery, Figure 2, each with normal blood pressures and heart rates).

Postoperative recovery was complicated by an episode of atrial flutter but otherwise uneventful. Kidney function improved after surgery (creatinine 108 μmol/L and eGFR 51 mL/min on the day before discharge) without any need for dialysis. The patient was discharged home 3 weeks after cardiac surgery.

Discussion

In patients with severe AR, concomitant moderate-to-severe MR is not uncommon. Its prevalence amounted to 25% in a large retrospective database analysis, and appeared independently associated with reduced survival.^{5,10} In a small subset of patients with AR (n=65), MV repair (but not replacement) in combination with AVR was associated with improved survival.¹⁰ However, literature on the natural history of MR in the setting of surgical or transfemoral AVR is focused on aortic stenosis as the leading lesion. But even there, the development of MR after AVR is not always toward an "intuitive" improvement of MR and the fate of MR remains uncertain.^{11,12}

Guideline recommendations for surgical treatment of valvular heart disease mostly refer to single valve lesions.^{6,13} Multiple-valve disease (mVD) is covered by recommendations merely in the context of chronic secondary MR or TR at the time of other cardiac surgery, and mostly with C level evidence.^{6,9} However, multiple-valvular lesions, especially when affecting the same (left) chamber, are hemodynamically interdependent and presumably interact in remodeling and reverse remodeling of the LV.

This case of left-sided IE with severe AR in a patient with IVDA showed a rather rapid deterioration from mild- to severe-grade MR. The patient's clinical course, however, did not give any hints for an acute deterioration but had improved slowly until the time of surgery. Also, no obvious morphological aspects of an acute etiology (e.g. perforated or flail mitral leaflet) were observed during the preoperative and intraoperative echocardiography exams. Therefore, despite some leaflet thickening, a secondary etiology of MR appeared likely, supported by the lack of coaptation and the dilated LV. Severe primary AR certainly increased LV volume load, and hence, LV preload. Echocardiographic grading of MR in this patient was thus based on guidelines for chronic secondary MR.⁴ A classification into "acute or

“chronic” MR, as given in recent recommendations, was difficult due to progression of severity over days, particularly since there appear to be no exact time frame definitions for “acute” or “chronic.”^{4,9,13}

General anesthesia is well known to reduce severity of MR mainly by reducing LV afterload, which may lead intraoperatively to a relative underestimation of lesion grade. In contrast, in this case, MR was judged even more severe under anesthesia conditions. However, there is a difference in heart rate from the severe-grade initial intraoperative TEE evaluation (heart rate 73/min) to the other echocardiographic evaluations of MR (HR 93–99/min) that may contribute to altered loading conditions, that is, to a larger regurgitant volume and hence a higher grade MR. The mVD will render echocardiographic grading of valvular lesion severity rather more complex owing to the hemodynamic interaction of the lesions’ effects. For the combination of AR with MR, the recent literature recommends the PISA method for grading of MR with calculation of EROA.^{6,7} Measurement of VC is also relatively independent from loading conditions.⁷ In secondary MR, two-dimensional VC and PISA measurements are prone to underestimating MR severity due to non-circularity of the regurgitant orifice (with its larger diameter along the coaptation line). Nevertheless, in this case, PISA and VC measurements were clearly indicative of severe MR and were measured orthogonal to the coaptation line.⁴

Volume overload together with systolic hypertension will frequently induce eccentric hypertrophy of the LV. Subsequent dilatation of the LV may have worsened mild-to-moderate MR by progressive symmetrical tethering of the systolic leaflet motion (Carpentier Class IIb).

Given the Class I indication for surgical AVR in this case of IE, surgical treatment of the incidentally diagnosed severe-grade secondary chronic MR would be considered reasonable by current guidelines,^{9,13} is supported by small retrospective series^{10,14} and a recent review,⁵ but has obviously been proven unnecessary in this patient. Echocardiographic re-evaluation of the MR during reperfusion on partial CPB support was predictive of immediate, substantial, and sustained improvement of MR after weaning. The chosen strategy of correcting the leading left-sided lesion first and only add TV repair as a brief beating-heart procedure, with reevaluation of the MV thereafter, turned out well and spared this multi-morbid patient a prolongation of the open-chamber procedure and her CPB time.

Conclusion

When deciding to extend surgery to another structurally intact valve, careful and multi-disciplinary consideration of individual pathophysiology is of utmost importance. This is even more important after intraoperative detection of additional lesions. Specifically determining the etiology of the separate lesions and their interaction is essential (independent, common, or dependent etiology). It also

underlines the importance of a comprehensive and current preoperative and intraoperative echocardiographic work-up particularly in patients with rapidly changing cardiac loading conditions and a fluctuating entity like functional MR.

Acknowledgements

This manuscript adheres to the applicable EQUATOR guideline.

Author contributions

J.O.F.: This author helped to analyze patient history, write, and edit the manuscript. T.B.: This author helped editing the manuscript. S.H.: This author helped editing the manuscript. M.P.: This author helped editing the manuscript. G.E.: This author helped editing the manuscript. B.E.: This author helped to analyze patient history and editing the manuscript.

Declaration of conflicting interests

The author(s) declared no potential conflicts of interest with respect to the research, authorship, and/or publication of this article.

Funding

The author(s) received no financial support for the research, authorship, and/or publication of this article.

Ethical approval

Our institution does not require ethical approval for reporting individual cases.

Informed consent

Written informed consent was obtained from the patient(s) for their anonymized information to be published in this article.

ORCID iD

Jan Oliver Friess  <https://orcid.org/0000-0002-5483-5498>

Supplemental material

Supplemental material for this article is available online.

References

1. American Society of Anesthesiologists and Society of Cardiovascular Anesthesiologists Task Force on Transesophageal Echocardiography. An updated report by the American Society of anesthesiologists and the Society of Cardiovascular Anesthesiologists Task Force on Transesophageal Echocardiography. *Anesthesiology* 2010; 112(5): 1084–1096.
2. Buck T, Kortmann K, Plicht B, et al. Critical importance of unsuspected findings detected by intraoperative transesophageal echocardiography for decision making during cardiac surgery. *Clin Res Cardiol* 2013; 102(5): 351–359.
3. Click RL, Abel MD and Schaff HV. Intraoperative transesophageal echocardiography: 5-year prospective review of impact on surgical management. *Mayo Clin Proc* 2000; 75(3): 241–247.

4. Zoghbi WA, Adams D, Bonow RO, et al. Recommendations for noninvasive evaluation of native valvular regurgitation: a report from the American Society of Echocardiography developed in collaboration with the Society for Cardiovascular Magnetic Resonance. *J Am Soc Echocardiogr* 2017; 30(4): 303–371.
5. Unger P, Lancellotti P, Amzulescu M, et al. Pathophysiology and management of combined aortic and mitral regurgitation. *Arch Cardiovasc Dis* 2019; 112(6–7): 430–440.
6. Unger P, Pibarot P, Tribouilloy C, et al. Multiple and mixed valvular heart diseases. *Circ Cardiovasc Imaging* 2018; 11(8): e007862.
7. Venneri L, Khattar RS and Senior R. Assessment of complex multi-valve disease and prosthetic valves. *Heart Lung Circ* 2019; 28(9): 1436–1446.
8. Baddour LM, Wilson WR, Bayer AS, et al. Infective endocarditis in adults: diagnosis, antimicrobial therapy, and management of complications: a scientific statement for healthcare professionals from the American Heart Association. *Circulation* 2015; 132: 1435–1486.
9. Nishimura RA, Otto CM, Bonow RO, et al. 2014 AHA/ACC guideline for the management of patients with valvular heart disease: executive summary: a report of the American College of Cardiology/American Heart Association Task Force on Practice Guidelines. *J Am Coll Cardiol* 2014; 63: 2438–2488.
10. Pai RG and Varadarajan P. Prognostic implications of mitral regurgitation in patients with severe aortic regurgitation. *Circulation* 2010; 122: S43–7.
11. Jeong DS, Park PW, Sung K, et al. Long-term clinical impact of functional mitral regurgitation after aortic valve replacement. *Ann Thorac Surg* 2011; 92(4): 1339–1345; discussion 1345.
12. Abdelghani M, Abdel-Wahab M, Hemetsberger R, et al. Fate and long-term prognostic implications of mitral regurgitation in patients undergoing transcatheter aortic valve replacement. *Int J Cardiol* 2019; 288: 39–43.
13. Nishimura RA, Otto CM, Bonow RO, et al. 2017 AHA/ACC focused update of the 2014 AHA/ACC guideline for the management of patients with valvular heart disease: a report of the American College of Cardiology/American Heart Association Task Force on Clinical Practice Guidelines. *J Am Coll Cardiol* 2017; 70: 252–289.
14. Moazami N, Diodato MD, Moon MR, et al. Does functional mitral regurgitation improve with isolated aortic valve replacement. *J Card Surg* 2004; 19(5): 444–448.