

Case Report

Endovascular management of distal anterior inferior cerebellar artery aneurysms: Report of two cases and review of the literature

Alejandro Santillan¹, Y. Pierre Gobin¹, Athos Patsalides¹, Howard A. Riina^{1,2}, Axel Rosengart³, Philip E. Stieg²¹Division of Interventional Neuroradiology, Department of Neurological Surgery, and ²Department of Neurological Surgery, and ³Department of Neurology, New York Presbyterian Hospital, Weill Cornell Medical Center, New York, NY, USA

E-mail: *Alejandro Santillan - als2052@med.cornell.edu; Y. Pierre Gobin - yvg2001@med.cornell.edu; Athos Patsalides - atp9002@med.cornell.edu; Howard A. Riina - har9005@med.cornell.edu; Axel Rosengart - axr9001@med.cornell.edu; Philip E. Stieg - pes2008@med.cornell.edu

*Corresponding author

Received: 31 March 11

Accepted: 20 April 11

Published: 30 June 11

This article may be cited as:Santillan A, Gobin YP, Patsalides A, Riina HA, Rosengart A, Stieg PE. Endovascular management of distal anterior inferior cerebellar artery aneurysms: Report of two cases and review of the literature. *Surg Neurol Int* 2011;2:95.Available FREE in open access from: <http://www.surgicalneurologyint.com/text.asp?2011/2/1/95/82577>

Copyright: © 2011 Santillan A. This is an open-access article distributed under the terms of the Creative Commons Attribution License, which permits unrestricted use, distribution, and reproduction in any medium, provided the original author and source are credited.

Abstract**Background:** Aneurysms of the anterior inferior cerebellar artery (AICA), especially those located in the distal portion of the AICA, are rare. There are few reported cases treated with surgery or endovascular embolization.**Case Description:** We report two cases of fusiform distal AICA aneurysms presenting with subarachnoid hemorrhage. Parent artery occlusion with coils and n-butyl cyanoacrylate (n-BCA) resulted in complete aneurysm occlusion and prevented rebleeding. Both patients presented postprocedure neurological deficits, but have made a good recovery at 4 and 10 months, respectively.**Conclusion:** Occlusion of the parent artery for the treatment of ruptured fusiform distal AICA aneurysms is effective but has significant neurological risks.**Key Words:** Anterior inferior cerebellar artery aneurysm, coil, endovascular therapy, meatal, parent artery occlusion, postmeatal**Access this article online****Website:**www.surgicalneurologyint.com**DOI:**

10.4103/2152-7806.82577

Quick Response Code:**INTRODUCTION**

Aneurysms of the distal AICA are very rare, accounting for only 0.1% of all cerebral aneurysms.^[25] Almost all of them are treated surgically by clipping, wrapping or trapping,^[3,20] with few reported cases treated with endovascular embolization.^[4-6,8,11-13,15,17,21,23,26,27]

The most likely mechanism for the developing of distal fusiform aneurysms is arterial dissection caused either by local trauma or nonspecific inflammation.^[19] Distal AICA aneurysms are often wide-neck or fusiform, making this type of lesions difficult to preserve the parent artery, either by clipping or coiling.^[11,14] They can be divided according to their location into 1) meatal and 2) postmeatal aneurysms. As they are located near the auditory canal, aneurysms of the distal AICA have a

significant risk of postoperative seventh and eighth cranial nerve function deficit after clipping or coiling.^[18,24,27]

Endovascular treatment with parent artery occlusion (PAO) using coils or glue for aneurysms located in the distal portion of cerebellar arteries has been reported in very few cases.^[7,16,26] This deconstructive approach may lead to infarction in the territory of the occluded cerebellar artery if collateral circulation is insufficient.^[21] If ischemic complications occur after PAO of distal cerebral arteries, they are usually tolerable and ultimately of limited clinical significance.^[2,7] In the present article we report two cases of distal anterior inferior cerebellar artery (AICA) aneurysms treated with endovascular PAO. We also conducted a review of the literature to evaluate the clinical impact of this treatment modality for this type of lesions [Table 1].

Table 1: Reported cases of meatal and postmeatal anterior inferior cerebellar artery (AICA) aneurysms treated with endovascular embolization

Author, Year	Age (years)/sex	Prev treated	Ruptured/Unruptured	Side (L/R)	Meatal loop/Postmeatal	Timing after SAH (days)	H&H/Fisher grade	Emb material	Angiographic occlusion	Immediate mRS	F/U (months)	Last mRS
Suzuki <i>et al.</i> , 1999	81/F	No	Ruptured	L	Postmeatal	SAH x 18 days	V/ Fisher 4	Coil	PAO ^c	2	Several months	0
Cloft <i>et al.</i> , 1999	49/F	Clipping	Ruptured	R	Meatal	NP	II/ NP	Coil	PAO ^a	2**	NP	NP
Ishikawa <i>et al.</i> , 2000	81/M	No	Ruptured	L	Postmeatal	NP	V/ Fisher 4	Coil	PAO ^a	1	3 mo	1
	69/F	No	Ruptured	L	Meatal	NP	III/ Fisher 4	Coil	PAO ^a	2 (cerebellar infarction)	3 mo	1
Saito <i>et al.</i> , 2001	68/F	No	Ruptured	L	Meatal	SAH x 19 days	II/ Fisher 4	Coil	PAO ^c	2 (left hearing disturbance)	NP	NP
Zager <i>et al.</i> , 2002	53/M	No	Unruptured	R	Postmeatal	NA	NA	Coil	PAO ^c	2***	NP	NP
Maekawa <i>et al.</i> , 2003	56/M	No	Ruptured	R	Postmeatal	NP	II/ Fisher 4	Coil	PAO ^d	2 (cerebellar infarction)	At discharge	0
Kusaka <i>et al.</i> , 2006	85/F	No	Ruptured	R	Meatal	NP	II/ Fisher 4	Coil	PAP	0	NP	NP
Choi <i>et al.</i> , 2006	20/M	Coiling [†]	Ruptured	R	Meatal	SAH x 1 day	IV/ Fisher 4	Coil	PAO ^b	4 (VI, VII, VIII palsy)	24 mo	0
Peluso <i>et al.</i> , 2007	45/M	No	Ruptured	NP	Meatal	SAH x 4 days/ VII & VIII CNP	II/ Fisher 4	Coil	PAO ^b	3	30 mo	3 [†]
Fukushima <i>et al.</i> , 2009	69/F	No	Ruptured	R	Meatal	SAH x 1 day	IV/ Fisher 4	Coil	PAO ^b	1	2 mo	6 ^{††}
Cui <i>et al.</i> , 2009	15/F	Bypass ^{**}	Unruptured	R	Meatal	NP*/ VIII CNP	NA	Coil	PAO ^b	0	12 mo	0
Ishii <i>et al.</i> , 2010	34/F	No	Ruptured	R	Postmeatal	NP	NP	Coil	PAO ^b	0	2 mo	0
	73/F	No	Ruptured	L	Postmeatal	NP	IV/ Fisher 2	Coil	PAO ^c	3****	NP	NP
Jimbo <i>et al.</i> , 2010	42/F	No	Ruptured	R	Meatal	SAH x 9 days	II/ Fisher 1	Coil	PAP	1	20 mo	0
Present report, 2011	73/M	No	Ruptured	R	Meatal	SAH x 14 days	II/ Fisher 4	Coil	PAO ^a	2****	10 mo	0
	59/F	No	Ruptured	L	Postmeatal	SAH x 4 days	I/ Fisher 4	n-BCA	PAO ^a	3 (brachium pontis infarction)	4 mo	2

MRI=magnetic resonance imaging, NP=Not provided, PAO=Parent artery occlusion, PAP= Parent artery preservation of the AICA, ^aOcclusion of the main trunk of the AICA, ^bOcclusion of the rostral trunk of the AICA, ^cOcclusion of the distal branch of the Ro. Tr. of the AICA (postmeatal segment), ^dOcclusion of the choroidal branch of the AICA; ^eRe-ruptured aneurysm previously treated with coils 1 month before the procedure; ^{††}The patient was treated with right occipital artery-AICA anastomoses 1 month before embolization; ^{*}No SAH but an extra-axial hemorrhagic lesion for 5 days; ^{**}The patient presented with sensorineural hearing loss as a result of previous surgery (clipping) performed 10 months ago, no ischemic complications from the endovascular treatment; ^{***}Patient returned to his previous neurological status of mild truncal ataxia; ^{****}High-grade sensorineural hearing loss; ^{*****}Moderate-grade sensorineural hearing loss; [†]Persistent facial palsy and hearing loss; ^{††}Sudden death, no AICA infarction

CASE REPORTS

Case 1

A 73-year-old male with a history of hypertension, diabetes and hyperlipidemia presented to the emergency room with severe headaches and nuchal rigidity starting approximately 14 days ago. Magnetic resonance imaging (MRI) revealed a subarachnoid hemorrhage (SAH), primary involving the bilateral sylvian fissures, the vertex and the bilateral ventricle occipital horns. Magnetic resonance angiography (MRA) did not show an aneurysm or any vascular abnormality. However, a digital subtraction angiogram showed a small right distal AICA aneurysm.

Intervention

The patient was placed under general anesthesia and anticoagulated with heparin. A diagnostic cerebral angiogram with three-dimensional (3D) reconstruction confirmed a small fusiform distal right AICA aneurysm [Figure 1a]. The maximal diameter of the aneurysm was 3.7 mm. A 5-F guide catheter was placed into the left vertebral artery, and then an Excelsior SL 10 microcatheter (Target Therapeutics/Boston Scientific, Fremont, CA) was advanced over a Synchro 2 standard microwire into the AICA, until the tip was within the aneurysm [Figure 1b]. Two coils, GDC 10 ultrasoft 2.5 mm x 3 cm and GDC ultrasoft 2 mm x 1 cm (Target Therapeutics/Boston Scientific) were deployed. The aneurysm and the distal AICA were completely obliterated. There was a significant collateral retrograde flow into the distal right AICA via the right superior cerebellar artery (SCA) and the right posterior inferior cerebellar artery (PICA) [Figure 1c]. Postprocedural angiography demonstrated a normal parenchymal blush in the right cerebellum during the capillary phase of the angiogram with no wedge defects.

Postoperative course

After embolization, the patient developed decreased hearing in the right side, ataxic gait, and was unable to tandem walk on his toes. One month after the procedure, the audiogram showed moderate-grade sensorineural hearing loss on the right side. At 10-months follow-up evaluation, the patient demonstrated full neurological recovery (mRS=0).

Case 2

A 59-year-old female presented to the emergency room with recent headaches. A computed tomography (CT) revealed an acute SAH with intraventricular hemorrhage and mild hydrocephalus. The CT angiogram demonstrated a 2.5-mm aneurysm of the distal left AICA, projecting within the left auditory canal [Figure 2a].

Intervention

The patient was placed under general anesthesia and anticoagulated with heparin. A diagnostic cerebral

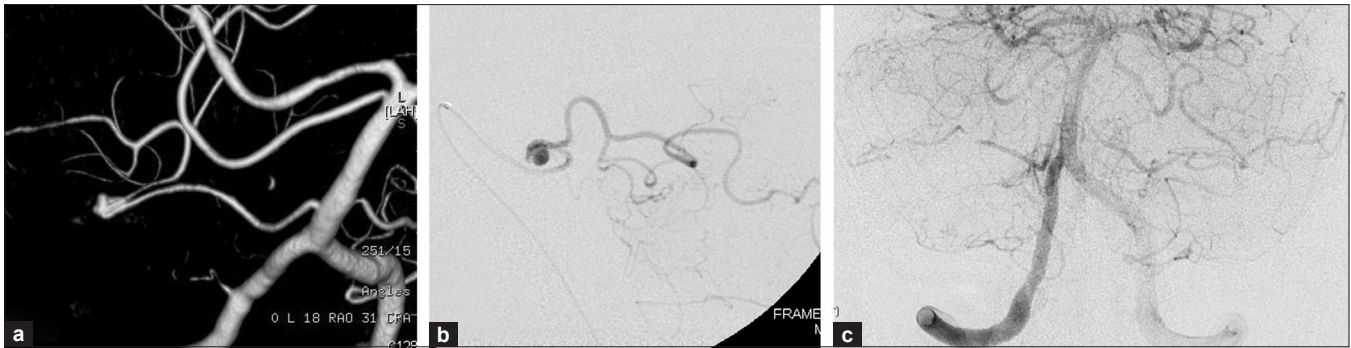


Figure 1: a) A 3D angiogram depicts a fusiform aneurysm in the distal segment of the right AICA. b) Superselective angiogram showing an aneurysm on the meatal loop of the right AICA. c) Selective vertebral artery angiogram (frontal view) shows complete occlusion of the aneurysm and the distal AICA. There is significant collateral retrograde flow into the AICA via the right superior cerebellar artery and the right posterior inferior cerebellar artery.

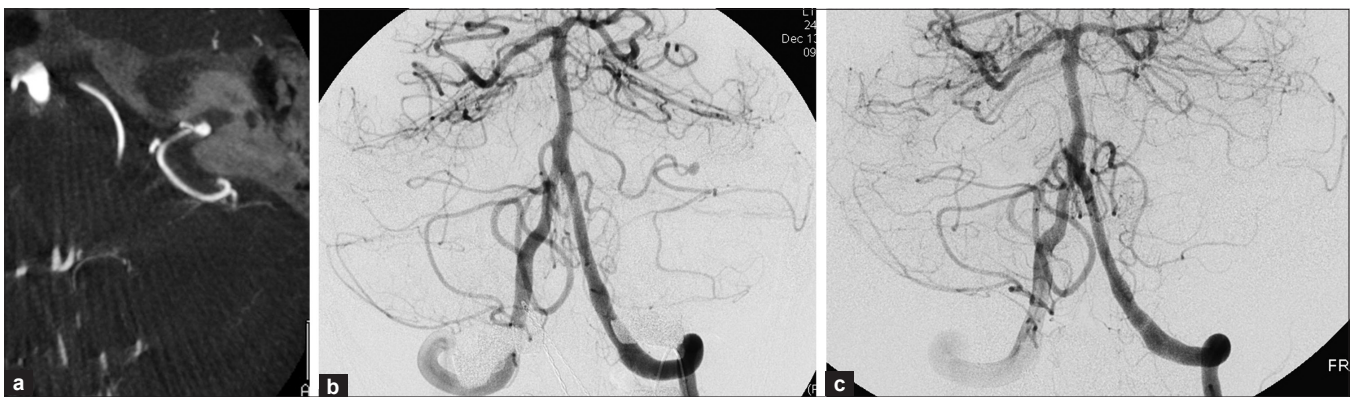


Figure 2: a) A CT angiogram (axial view) depicts a distal left AICA aneurysm projecting into the left auditory canal. b) Selective vertebral angiogram (frontal view) showing a 2.5-mm aneurysm arising distal to the meatal loop of the left AICA. c) Postoperative angiogram demonstrating complete obliteration of the aneurysm with absent filling of the AICA. There is also an area of hypoperfusion in the inferior left cerebellar hemisphere

angiogram with three-dimensional (3D) reconstruction confirmed a 2.5 mm aneurysm arising from the distal left AICA. The left PICA was hypoplastic and the left AICA was filling the distal PICA territory [Figure 2b]. The smaller branch of the AICA was oriented inferiorly to supply the medial aspect of the left PICA territory, while the larger, more superior branch supplied the AICA territory and the inferolateral PICA territory. Using roadmap technique, a Magic 1.5 F microcatheter was advanced over a 0.008" Mirage microwire into the left AICA until reaching the aneurysm, then n-BCA was injected through the microcatheter into the aneurysm, occluding the aneurysm and also the parent artery. Postprocedure angiography demonstrated an area of hypoperfusion in the inferior left cerebellar hemisphere, in the expected territory of the left PICA [Figure 2c].

Postoperative course

The patient developed moderate to severe truncal ataxia without any hearing disturbance after the procedure. Follow-up CT, performed at 1 week, revealed an evolving hypodensity at the left brachium pontis likely related to

infarction at this level. Follow-up evaluation 4 months later, the patient showed a mild truncal ataxia (mRS=2).

DISCUSSION

The anatomy of the AICA is highly variable. Typically, the artery arises from the junction between the middle and lower thirds of the basilar artery, courses along the pons and the middle cerebellar peduncle, to which it gives few but important perforating branches.^[18] The branches of the AICA that supply the inferior upper part of the olive arise 3-18 mm distal to the origin of the AICA, whose occlusion could lead to a lateral inferior pontine syndrome.^[1] Near the facial-vestibulocochlear complex, the AICA bifurcates into two major branches, called the rostralateral branch and the caudomedial branch. The rostralateral branch courses toward the internal auditory canal close to the seventh and eighth cranial nerve complex and gives off the labyrinthine artery also called internal auditory artery (IAA). The caudomedial branch courses medially close to the pons, to which it sends a few perforators, and terminates in cerebellar branches.^[21,24]

Also, the AICA sends few branches to the choroid plexus protruding from the foramen of Luschka.^[21] The hemispheric branches from the AICA frequently have anastomoses with the SCA and PICA.^[21,26]

Patients with aneurysms at the distal portion of the AICA may present acutely with SAH or with symptoms of a mass lesion in the cerebellopontine angle, including hearing loss, vertigo, tinnitus, facial weakness, diplopia, ataxia, or altered facial sensation.^[27] On the other hand, occlusion of the AICA may result in vertigo often associated with nausea and vomiting, followed by facial paralysis, ipsilateral deafness, sensory loss, and cerebellar disorders. It can also present with nystagmus, Horner syndrome, cerebellar ataxia, and contralateral hemisensory loss of pain and temperature sensation.^[21] The syndromes caused by AICA occlusion are very variable because of its anatomical variability.^[22]

At the meatal loop, distal AICA aneurysms may be located near the IAA.^[8] Aneurysms located within the IAA may be treated surgically, but have a high risk of postoperative facial or acoustic nerve palsy.^[26] For AICA aneurysms located at the postmeatal portion of the AICA (remote from the IAA) the endovascular treatment appears simpler than surgical treatment.^[26]

Embolization of AICA aneurysms with parent artery preservation

Endovascular embolization of distal AICA aneurysms can be achieved with parent artery preservation in case of berry aneurysm with small necks.^[13,15] However, distal AICA aneurysms are often fusiform. Therefore, embolization with parent artery preservation is difficult, and if the mechanism of formation of the aneurysm was arterial dissection, it may be dangerous because of the risk of regrowth and rerupture.^[4] Choi *et al.*, reported a case of a distal AICA aneurysm at the meatal loop treated with parent artery preservation. The dome of the aneurysm was occluded successfully. However, the patient experienced a recurrent hemorrhage from the recanalized aneurysm one month after embolization. Then, the parent artery at the proximal portion of the aneurysm was occluded with excellent results.^[4]

Embolization of distal AICA aneurysms with parent artery occlusion

In fusiform aneurysms or dissecting aneurysms with wide neck, PAO may be proposed as a therapeutic alternative.^[9,10,16]

Parent vessel occlusion is generally safe provided there is good collateral flow. The best way to test the safety of parent vessel occlusion is to perform a temporary balloon test occlusion, but this is impossible to perform in the distal AICA because the artery is too small. Therefore the risk of parent vessel occlusion in this location is difficult to predict. If the PICA is unusually small and the AICA is large, the collateral circulation is likely to be poor, creating

an unfavorable and dangerous situation in the event of an AICA occlusion.^[22] Matsuyama *et al.*,^[18] reported good results of a ruptured dissecting AICA aneurysm treated with endovascular embolization. They stated that no ischemic complications occurred after the sacrifice of the distal AICA because of sufficient collateral circulation from the ipsilateral SCA or PICA. Occlusion of the proximal AICA with insufficient collaterals may increase the risk of ischemic damage since distal flow would be dependent only from leptomeningeal anastomoses.^[8]

According to Zager *et al.*,^[27] if the aneurysm is located on the segment of the AICA that is distal to any branches coursing to the brainstem, distal occlusion may be performed with no neurological sequelae. However, it may carry the risk of retrograde thrombosis which could result in a devastating brainstem infarct. To avoid this complication, the patient may benefit from antithrombotic therapy immediately after the procedure.^[11] Embolization of the distal AICA should be performed remote from the origin of the IAA whenever feasible. Ishii *et al.*,^[11] reported a case of embolization of a postmeatal AICA aneurysm. After the procedure the patient presented with high grade sensorineural hearing loss, probably related to the sacrifice of the IAA after the procedure.

Occipital artery-AICA bypass

Occipital artery-AICA (OA-AICA) bypass may be performed to prevent ischemic complications before the sacrifice of the AICA. This strategy represents an alternative if there is insufficient collateral circulation into the AICA. Fukushima *et al.*,^[8] reported a case of a right distal AICA dissecting aneurysm with hypoplasia of the right PICA. The endovascular approach was selected for a PAO. Since the patient had the risk of diffuse cerebellar infarction due to the hypoplastic right PICA and the possibility of worsening deafness, an OA-AICA bypass was performed one month previous to the endovascular procedure. The patient showed excellent results after the procedure. If bypass surgery cannot be performed due to the age or clinical status of the patient, or if there is not effective patency after the anastomoses, PAO by endovascular embolization or surgery could still be considered.

CONCLUSIONS

Our two patients presented neurological deficits immediately after embolization, and made a good but not total recovery. Our results are similar to the literature that describes a high rate of complications with parent vessel occlusion in this location. Endovascular embolization by PAO is a potentially risky therapeutic option for ruptured distal AICA aneurysms, which should be considered when no other option is available.

REFERENCES

- Akar ZC, Dujovny M, Gomez-Tortosa E, Slavin KV, Ausman JI. Microvascular anatomy of the anterior surface of the medulla oblongata and olive. *J Neurosurg* 1995;82:97-105.
- Andreou A, Ioannidis I, Mitsos A. Endovascular treatment of peripheral intracranial aneurysms. *AJNR Am J Neuroradiol* 2007;28:355-61.
- Bambakidis NC, Manjila S, Dashti S, Tarr R, Megerian CA. Management of anterior inferior cerebellar artery aneurysms: An illustrative case and review of literature. *Neurosurg Focus* 2009;26:E6.
- Choi CH, Cho WH, Choi BK, Lee SW. Rerupture following endovascular treatment for dissecting aneurysm of distal anterior inferior cerebellar artery with parent artery preservation: Retreatment by parent artery occlusion with Guglielmi detachable coils. *Acta Neurochir (Wien)* 2006;148:363-6.
- Cloft HJ, Kallmes DF, Jensen ME, Lanzino G, Dion JE. Endovascular treatment of ruptured, peripheral cerebral aneurysms: Parent artery occlusion with short Guglielmi detachable coils. *AJNR Am J Neuroradiol* 1999;20:308-10.
- Cui L, Peng Q, Ha W, Zhou D, Xu Y. Parent artery occlusion for intracranial aneurysms. *Interv Neuroradiol* 2009;15:309-15.
- Eckard DA, O'Boynick PL, McPherson CM, Eckard VR, Han P, Arnold P, et al. Coil occlusion of the parent artery for treatment of symptomatic peripheral intracranial aneurysms. *AJNR Am J Neuroradiol* 2000;21:137-42.
- Fukushima S, Hirohata M, Okamoto Y, Yamashita S, Ishida S, Shigemori M. Anterior inferior cerebellar artery dissecting aneurysm in a juvenile: Case report. *Neurol Med Chir (Tokyo)* 2009;49:81-4.
- Gobin YP, Vinuela F, Gurian JH, Guglielmi G, Duckwiler GR, Massoud TF, et al. Treatment of large and giant fusiform intracranial aneurysms with Guglielmi detachable coils. *J Neurosurg* 1996;84:55-62.
- Hodes JE, Aymard A, Gobin YP, Rufenacht D, Bien S, Reizine D, et al. Endovascular occlusion of intracranial vessels for curative treatment of unclippable aneurysms: Report of 16 cases. *J Neurosurg* 1991;75:694-701.
- Ishii D, Takechi A, Shinagawa K, Sogabe T. Endovascular treatment for ruptured distal anterior inferior cerebellar artery aneurysm - Case report. *Neurol Med Chir (Tokyo)* 2010;50:396-9.
- Ishikawa E, Yanaka K, Meguro K, Narushima K, Suzuki K, Wada M, et al. Treatment of peripheral aneurysms of the posterior circulation. *No Shinkei Geka* 2000;28:337-43.
- Jinbo Y, Zheng Z, Jiaquan H, Hui Y, Jun L. Embolization of a ruptured aneurysm of the distal anterior inferior cerebellar artery with parent artery preservation. *Neurol India* 2010;58:786-8.
- Johnson JH Jr, Kline DG. Anterior inferior cerebellar artery aneurysms. Case report. *J Neurosurg* 1978;48:455-60.
- Kusaka N, Maruo T, Nishiguchi M, Takayama K, Maeda Y, Ogihara K, et al. Embolization for aneurismal dilatation associated with ruptured dissecting anterior inferior cerebellar artery aneurysm with preservation of the parent artery: Case report. *No Shinkei Geka* 2006;34:729-34.
- Lubicz B, Leclerc X, Gauvrit JY, Lejeune JP, Pruvo JP. Endovascular treatment of peripheral cerebellar artery aneurysms. *AJNR Am J Neuroradiol* 2003;24:1208-13.
- Maekawa M, Awaya S, Fukuda S, Teramoto A. A ruptured choroidal artery aneurysm of the anterior inferior cerebellar artery obliterated via the endovascular approach: Case report. *No Shinkei Geka* 2003;31:523-7.
- Matsuyama T, Okuchi K, Norimoto K, Ueyama T. Ruptured dissecting anterior inferior cerebellar artery aneurysm - Case report. *Neurol Med Chir (Tokyo)* 2002;42:214-6.
- Mitsos AP, Corkill RA, Lalloo S, Kuker W, Byrne JV. Idiopathic aneurysms of distal cerebellar arteries: Endovascular treatment after rupture. *Neuroradiology* 2008;50:161-70.
- Okumura Y, Sakaki T, Hirabayashi H, Shimomura T. Intrameatal aneurysm successfully treated by meatal loop trapping - Case report. *Neurol Med Chir (Tokyo)* 1999;39:161-4.
- Peluso JP, van Rooij WJ, Sluzewski M, Beute GN. Distal aneurysms of cerebellar arteries: Incidence, clinical presentation, and outcome of endovascular parent vessel occlusion. *AJNR Am J Neuroradiol* 2007;28:1573-8.
- Rhoton AL Jr. The cerebellar arteries. *Neurosurgery* 2000;47 Suppl 3:S29-68.
- Saito R, Tominaga T, Ezura M, Shimizu H, Yoshimoto T. Distal anterior inferior cerebellar artery aneurysms: Report of three cases and literature review. *No Shinkei Geka* 2001;29:709-14.
- Sarkar A, Link MJ. Distal anterior inferior cerebellar artery aneurysm masquerading as a cerebellopontine angle tumor: Case report and review of literature. *Skull Base* 2004;14:101-6.
- Suzuki J, Hori S, Sakurai Y. Intracranial aneurysms in the neurosurgical clinics in Japan. *J Neurosurg* 1971;35:34-9.
- Suzuki K, Meguro K, Wada M, Fujita K, Nose T. Embolization of a ruptured aneurysm of the distal anterior inferior cerebellar artery: Case report and review of the literature. *Surg Neurol* 1999;51:509-12.
- Zager EL, Shaver EG, Hurst RW, Flamm ES. Distal anterior inferior cerebellar artery aneurysms. Report of four cases. *J Neurosurg* 2002;97:692-6.

Commentary

This is a nice case report of two cases of distal anterior inferior cerebellar artery aneurysms. The authors clearly discuss the pertinent anatomy and include a comprehensive review of the relevant medical literature. It has been my personal preference to attempt microsurgical repair of aneurysms whenever possible, with the exception of intracavernous aneurysms. In the case of distal dissecting aneurysms involving the intracranial circulation, the tolerance of the brain tissue for temporary arterial occlusion is typically quite good, even within the posterior circulation. Distal aneurysms can often be

excised and revascularization performed with a variety of reconstruction techniques. The authors correctly observe in this manuscript that the risk of infarction with parent vessel occlusion is not insignificant, even when occluding the vessels distal in the circulation. Parent vessel occlusion should only be a treatment of last resort when vascular reconstruction is not technically feasible.

Thomas A. Kopitnik

Central Wyoming Neurosurgery, 6600 East Second Street, Casper, WY 82609, USA

E-mail: tom@cwneurosurgery.com