


Anatomical Study of Innervation of the Supinator Muscle to Reinnervate the Posterior Interosseous Nerve*

Estudo anatômico da inervação do músculo supinador para reinervar o nervo interósseo posterior

Edie Benedito Caetano¹ Luiz Angelo Vieira¹ João José Sabongi Neto² Maurício Ferreira Caetano²
Rodrigo Guerra Sabongi³ Bruno Azi Pacileo Cruz¹

¹ Faculty of Medical Sciences and Health, Pontifícia Universidade Católica de São Paulo, Sorocaba, SP, Brazil

² Hand Surgery Service, Conjunto Hospitalar de Sorocaba (CHS), Sorocaba, SP, Brazil

³ Medical Residence in Orthopedics, Universidade Federal do Estado de São Paulo (UNIFESP), São Paulo, SP, Brazil

Address for correspondence Edie Benedito Caetano, PhD, Rua Joubert Wey, 290, CEP: 18030-070, Sorocaba, SP, Brazil (e-mail: ediecaetano@uol.com.br).

Rev Bras Ortop 2019;54:253–260.

Abstract

Objective The purpose of this anatomical study was to analyze the possibility of transferring radial nerve branches to the supinator muscle to reinnervate the posterior interosseous nerve (PIN) originating from the C7–T1 roots.

Methods Thirty members of 15 cadavers, all male, prepared with an intra-arterial glycerol and formaldehyde solution injection, were dissected.


Results All dissected limbs presented at least one branch intended for the superficial and the deep heads of the supinator muscle. These branches originated from the PIN. A branch to the supinator muscle, proximal to the arcade of Frohse, was identified in six members. In addition, 2 and 3 branches to the supinator muscle were found in 11 and 4 members, respectively. In two limbs, only one branch detached from the PIN, but it duplicated itself proximal to the arcade of Frohse. Seven limbs had no branches to the supinator muscle at the region proximal to the arcade of Frohse. The branches destined for the supinator muscle were sectioned at the neuromuscular junction for connection with no tension to the PIN. The combined diameter of the branches for the supinator muscle corresponded, on average, to 53.5% of the PIN diameter.

Conclusion The radial nerve branches intended for the supinator muscle can be transferred, with no tension, directly to the PIN to restore thumb and finger extension in patients with C7–T1 brachial plexus lesions.

Keywords

- ▶ brachial plexus
- ▶ skeletal muscle
- ▶ peripheral nerves
- ▶ fingers
- ▶ nerve transfer

* Work performed at Pontifícia Universidade Católica de São Paulo, Faculdade de Ciências Médicas e da Saúde, Sorocaba, SP, Brazil.

 Edie Benedito Caetano's ORCID is <https://orcid.org/0000-0003-4572-3854>.



Resumo

Objetivo O objetivo deste estudo anatômico foi analisar a possibilidade de transferir os ramos do nervo radial destinados ao músculo supinador para reinervar o nervo interósseo posterior (NIP) que se origina das raízes de C7–T1.

Métodos Foram dissecados 30 membros 15 cadáveres, todos do sexo masculino, preparados por injeção intra-arterial de uma solução de glicerina e formol a 10%.

Resultados Em todos os membros dissecados encontramos pelo menos um ramo destinado a cada uma das cabeças superficial e profunda do músculo supinador. Esses tiveram origem no NIP. Identificamos, proximal à arcada de Frohse um ramo para o supinador em seis membros. Dois ramos para o supinador em 11 membros e 3 ramos em 4 membros. Em dois membros, apenas um ramo desprendia-se do NIP, mas se duplicava proximalmente à arcada de Frohse. Em sete membros, não identificamos ramos para o supinador proximal à arcada de Frohse. Os ramos destinados ao músculo supinador foram seccionados na junção neuromuscular, podendo ser conectados sem tensão ao NIP. O diâmetro somado dos ramos destinados ao músculo supinador correspondeu, em média, a 53,5% do diâmetro do NIP.

Conclusão Este estudo anatômico mostra que ramos do nervo radial destinados ao músculo supinador podem ser transferidos diretamente para o NIP, sem tensão, para restaurar a extensão do polegar e dos dedos da mão em pacientes com lesões de plexo braquial C7–T1.

Palavras-chave

- ▶ plexo braquial
- ▶ músculo esquelético
- ▶ nervos periféricos
- ▶ dedos da mão
- ▶ transferência de nervo

Introduction

The repair of a nerve injury is based on primary nerve repairs, nerve grafts, tendon transfers and free muscle transfer. However, some nerve lesions are not amenable to a primary repair; in addition, grafts do not always provide satisfactory results, and tendon transfers may be limited by the availability of donor muscles. These lesions include very proximal nerve injuries; extensive lesions, resulting in a long space between nerve stumps, and idiopathic nerve paralysis or neuritis, in which there is no healthy proximal nerve segment.^{1–3}

In brachial plexus injuries, with very large gaps between nerve ends, there may not be enough time for axonal regeneration in order to reach the motor endplates of target muscles before they become permanently resistant to reinnervation. This prolonged denervation period leaves target muscles susceptible to irreversible degeneration and terminal motor plates fibrosis. Nerve transfers are a possible surgical option in this scenario.^{1,4,5} Radicular C7, C8 and T1 lesions result in dysfunction of the hand intrinsic muscles, wrist flexor muscles and thumb flexor and extensor muscles. The functional recovery of the paralyzed hand is a great challenge for all facing this type of injury.

The radial nerve innervates all muscles from the arm and forearm posterior compartment. It travels from the posterior to the anterior compartment, bypassing the humeral groove of the radial nerve. It runs through the intermuscular septum between the brachialis muscles (BMs) medially and the brachioradial (BR) muscles laterally, continuing inferiorly at the anterior compartment of the arm. More distally, it emerges between the BR muscles and the exten-

sor carpi radialis longus muscle (ECRL). It is divided into the superficial branch of the radial nerve (SBRN) and the posterior interosseous nerve (PIN), also called deep radial nerve branch (DRNB). The radial tunnel is a muscle-aponeurotic structure that extends from the lateral epicondyle of the humerus to the distal edge of the supinator muscle.^{6,7} The supinator muscle has two heads, a superficial and a deep one, and the PIN is positioned between them. The proximal edge of the superficial head of the supinator muscle may form a fibrous arcade of variable length and thickness, also known as arcade of Frohse (AF). Described in 1908 by Frohse and Frankel,⁸ the AF is reported as the most common site of PIN compression.^{7,9,10} Electrophysiological studies have shown that the innervation to the supinator muscle originates in the C5–C6 roots and that the PIN innervation originates at the C7–T1 roots.^{11–13} The branches to the supinator muscle are close to the posterior interosseous nerve and a direct transfer can be easily performed, facilitating and accelerating the reinnervation. Forearm supination is performed by two main muscles, the biceps brachii and supinator muscles, and both are preserved in C7–T1 palsy.¹⁴ Therefore, the sacrifice of the motor branches for the supinator muscle does not compromise supination due to biceps compensation. The advantages of using distal donor nerve sites include proximity to terminal motor plates, operation in an area where anatomical structures are not compromised by fibrous tissue, and the certainty of using a source of viable motor axons originated from the donor nerve.¹⁵

The purpose of this study was to anatomically study, in 30 cadaveric limbs, the radial nerve branches directed to the supinator muscle and the PIN with its ramifications and to evaluate some details of this nerve transfer.

Material and Methods

This study was based on the dissection of 30 upper limbs from 15 cadavers, all from male subjects. They were prepared by intra-arterial injection of a 10% glycerol and formalin solution. Each forearm was dissected with the elbow extended, the wrist in neutral position, and the forearm pronated. None of the cadavers presented evidence of deformities, previous surgical procedures or traumatic lesions in the studied area. We removed the skin and fascia from the flexor and extensor surface of the distal third of the arm, forearm and wrist. The radial nerve was identified in the arm between the brachialis and brachioradial muscles and dissected from proximal to distal. The brachioradialis (BR), ECRL and extensor carpi radialis brevis (ECRB) muscle tendons were sectioned at their distal third and separated from the fibrous connections that united them to facilitate the nerve branches identification.

The branches for the PIN and BR, ECRL, ECRB and supinator muscles were dissected. Vascular structures were not spared, which facilitated nerve dissection. In certain phases of the dissection, a 2.5x magnifying glass was used. The innervation order of each muscle and the number of branches were recorded. The PIN was identified on the proximal and distal margins of the supinator muscle and dissected along its path between the superficial and deep heads of the supinator muscle, thus exposing all its branches. The number of branches proximal to the AF and within the supinator muscle mass were recorded. The PIN was distally followed until its entrance at the forearm muscles. A digital caliper was used to measure the nerve diameter. The PIN diameter was measured at the area distal to the ramification for the supinator muscle. The diameter of the branches to the supinator muscle was measured 0.5 cm distal to their origin at the PIN (►Figs. 1A and 1B). The branches for the supinator muscle were sectioned near the neuromuscular junction and easily connected to the PIN, thus simulating the surgical procedure at the cadaveric limb.

Results

The letters A and B are always on the proximal side of the figures to facilitate their understanding. All dissected limbs presented at least one branch intended for the superficial and the deep heads of the supinator muscle. These branches originated from the PIN. A branch to the supinator muscle, proximal to the AF, was identified in six members (►Figs. 2A and 2B). In addition, two branches to the supinator muscle were found in 11 limbs (►Fig. 3A), whereas three were found in four limbs (►Fig. 3B). In two limbs, only one branch detached from the PIN, but it duplicated itself proximal to AF (►Fig. 4A). Seven limbs had no branches to the supinator muscle at the region proximal to the AF (►Fig. 4B). The superficial and deep heads of the supinator muscle were identified in all limbs (►Figs. 5A and 5B). The superficial head received only one branch in 19 limbs (►Fig. 5A), and it had 2 branches in 11 limbs (►Fig. 5B). The deep head received one branch in 18 limbs (►Fig. 5A), 2 branches in

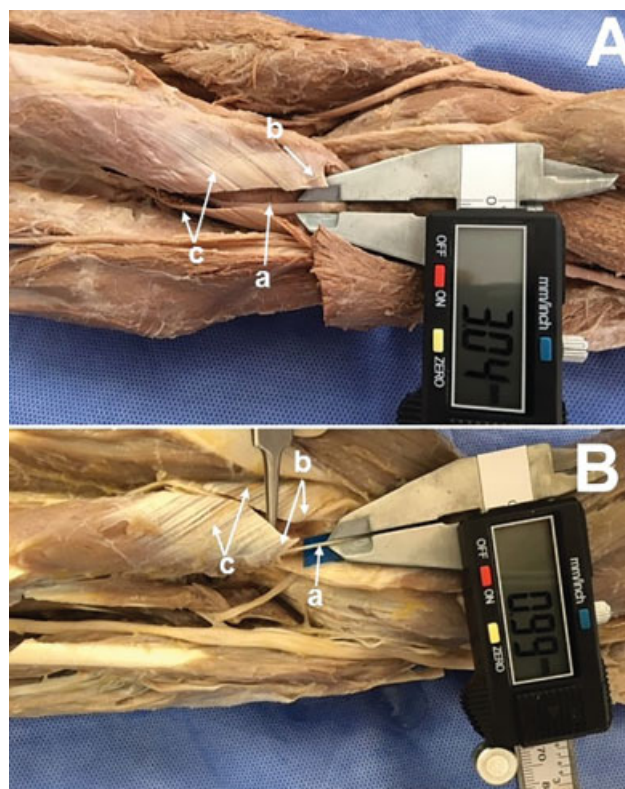


Fig. 1A Measurement of the posterior interosseous nerve (PIN) diameter, distal to the branching for the supinator muscle. PIN (a); Arcade of Frohse (AF) (b); Supinator muscle (c). **1B** - Measurement of the diameter of a branch to the supinator muscle, 0.5 cm distal to its origin at the posterior interosseous nerve (PIN). PIN (a); Arcade of Frohse (b); Supinator muscle (c).

10 (►Fig. 6A), and 3 branches in 2 limbs (►Fig. 6B). The PIN emerged at the distal supinator margin in 26 limbs (►Fig. 7A). In four limbs, it emerged piercing the supinator muscle body (►Fig. 7B). The terminal branches of the PIN run distally to innervate the forearm muscles. In 25 limbs, its branching, distal to the superficial and deep branches of the PIN, occurred at or below the distal margin of the supinator muscle (►Fig. 8A), whereas, in five limbs, the division occurred in the supinator muscle substance (►Fig. 8B). The mean PIN diameter in the area comprised distally to branching and proximally to its distal branch was 3.0 ± 0.5 mm, and the sum of the mean diameter of the branches to the supinator muscle was 1.4 ± 0.8 mm (►Figs. 9A and 9B). By dividing the branches to the superficial and deep heads of the supinator muscle at their penetration point into the muscle, we observed that the extremities of these nerves could be connected to the PIN without tension (insert, ►Figs. 5B, 9A and 9B).

Discussion

This study identified that the radial nerve divides into PIN and SBRN proximally to the intercondylar humeral line (IHL) in all limbs. The branches of the radial nerve for BR and ECRB detached from the radial nerve proximally to its division. The branches to the supinator muscle originated from the PIN.

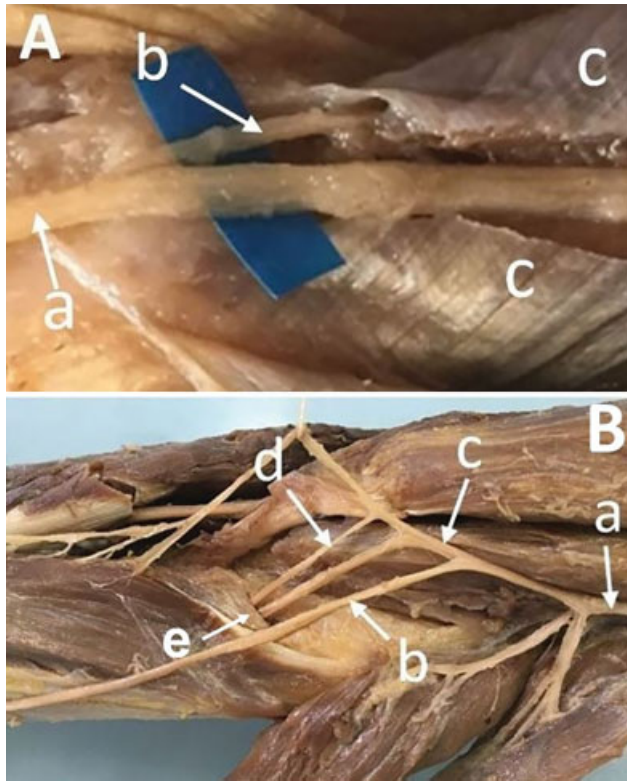


Fig. 2A Posterior interosseous nerve (PIN) (a); A branch to the supinator muscle (b); Sectioned supinator muscle (c); Arcade of Frohse (AF) (d). **2B** - Radial nerve (a); Superficial branch of the radial nerve (b); PIN (c); Branch to supinator muscle (d); AF (e).

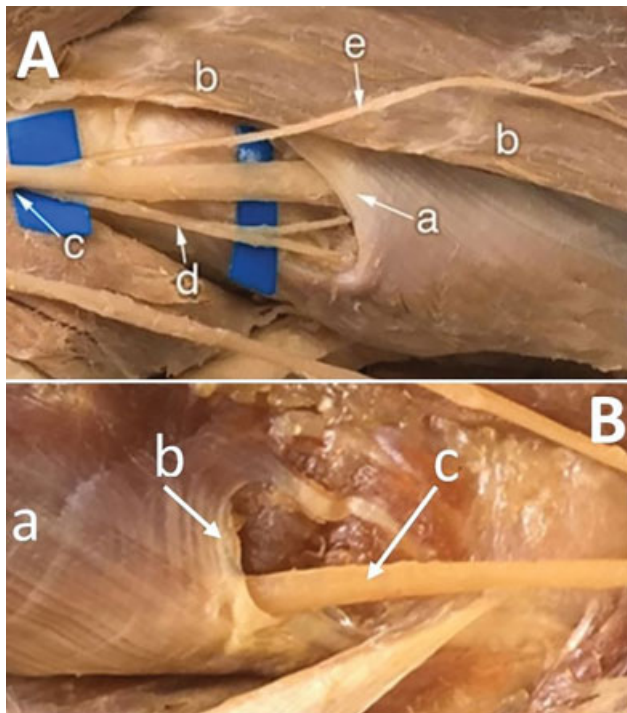


Fig. 4A Arcade of Frohse (AF) (a); Extensor carpi radialis brevis (ECRB) muscle (b); Posterior interosseous nerve (PIN) (c); Branch for the supinator muscle (d); Branch for the ECRB muscle (e) Superficial head of the supinator muscle. **4B** - Supinator muscle (a); AF (b); PIN (c).

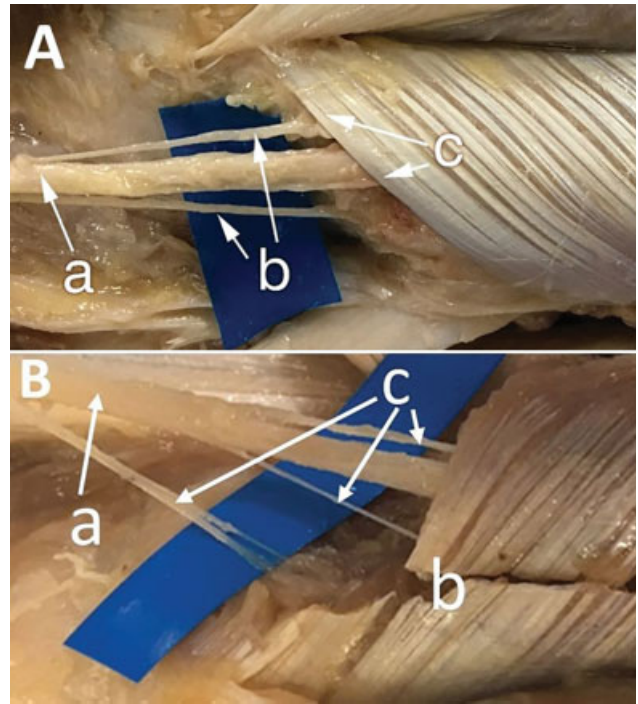


Fig. 3A Posterior interosseous nerve (PIN) (a); Two branches to the supinator muscle (b); Arcade of Frohse (AF) (c). **3B** - PIN (a); AF (b); Three branches to the supinator muscle (c).

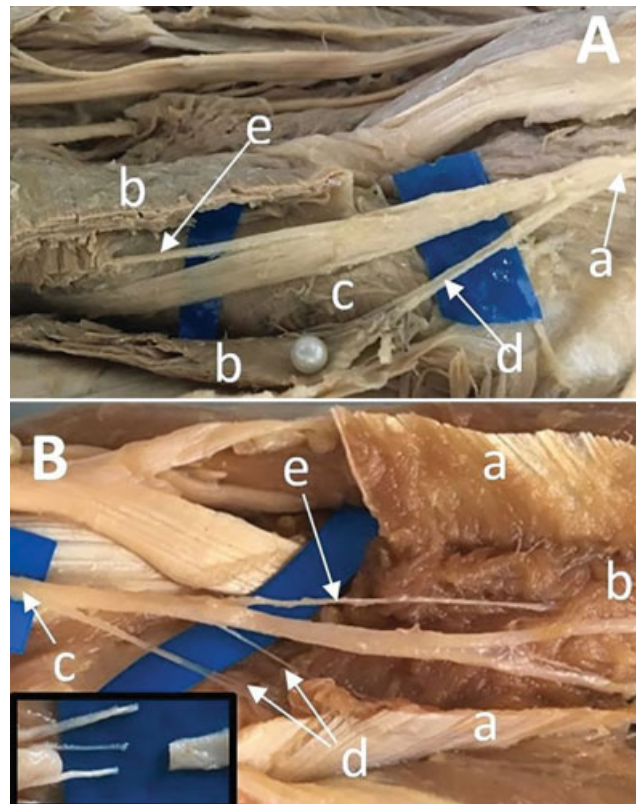


Fig. 5A Posterior interosseous nerve (PIN) (a); Superficial head (b); Deep head (c); Branches to the superficial head (d); Branch to the deep head (e); **5B** - Superficial head (a); Deep head (b); PIN (c); Branches to the superficial head (d); Branches to the deep head (e).

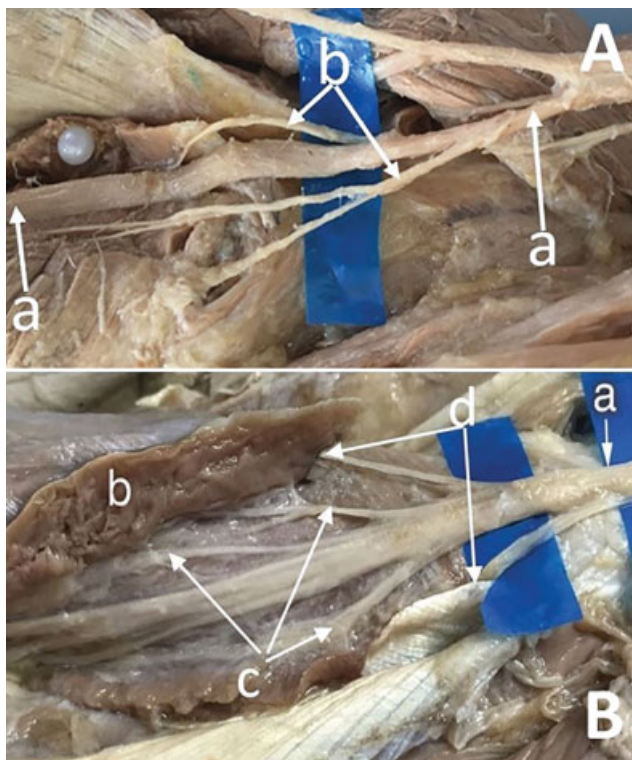


Fig. 6A Posterior interosseous nerve (PIN) (a); Two branches for the deep head (b); **6B** - PIN (a); Supinator muscle (b); Three branches to the deep head (c); Two branches for the superficial head (d).

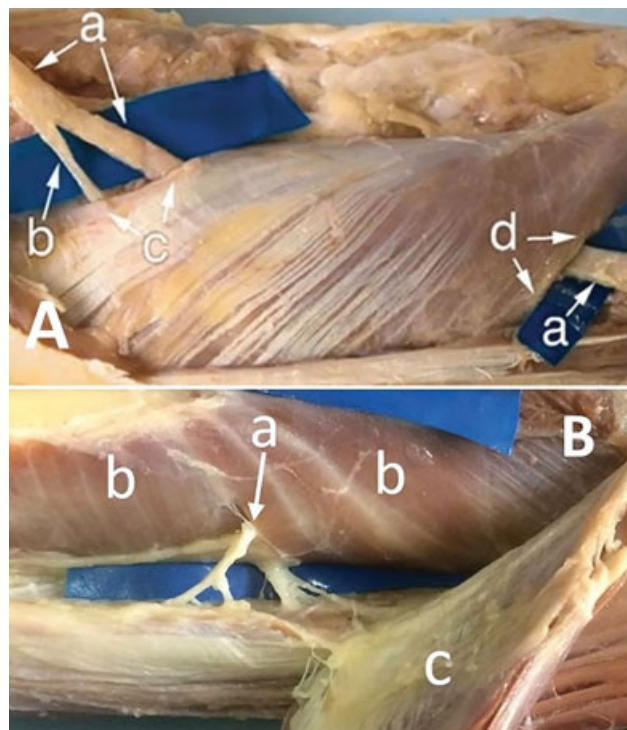


Fig. 7A Posterior interosseous nerve (PIN) (a); Branch to the supinator muscle (b); Arcade of Frohse (AF) (c); Distal margin of the supinator muscle (d). **7B** - PIN (a); Supinator muscle (b); Extensor carpi radialis brevis (ECRB) muscle (c).



Fig. 8A Distal margins of the supinator muscle (a); Posterior interosseous nerve (PIN) (b) Distal branching to the distal margin of the supinator muscle. **8B** - Distal margin of the supinator muscle (a); PIN (b); Superficial branch of the PIN (c) Deep branch of the PIN (d).

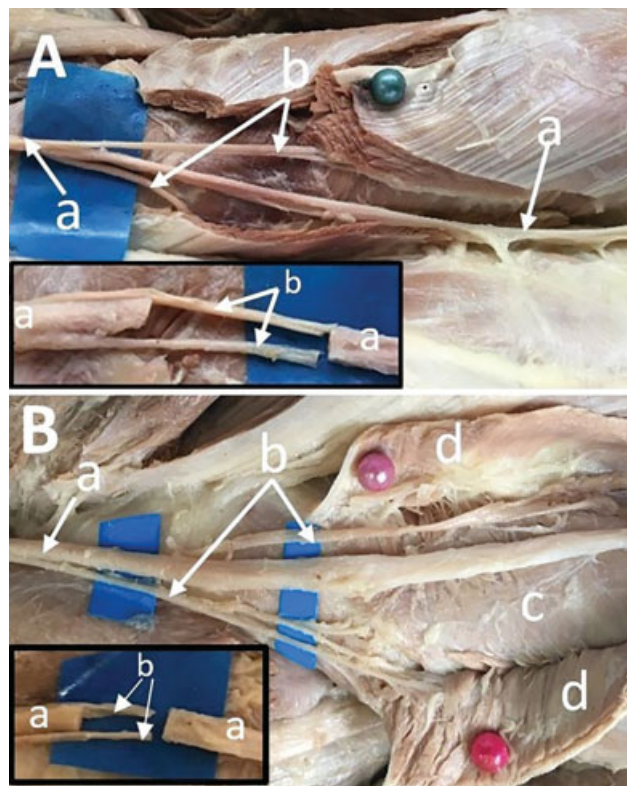


Fig. 9A Posterior interosseous nerve (PIN) (a); Branches to the supinator muscle (b); Insert: neurotization simulation. **9B** - PIN (a); Branches to the supinator muscle (b); Deep head (c); Superficial head (d); Insert: neurotization simulation.

Proximal to the AF, a branch to the supinator muscle was observed in six limbs (► **Figs. 2A** and **2B**). There were 2 branches to the supinator muscle in 11 limbs (► **Fig. 3A**), and 3 branches to this muscle in 4 limbs (► **Fig. 3B**). Seven limbs did not present branches to the supinator muscle proximal to the AF (► **Fig. 4A**). Other authors^{1,5} also identified at least two branches for the supinator muscle, one for the superficial head and the other for the deep head. The literature reports the great variability of AF anatomical constitution. Spinner⁷ studied 25 limbs from adult cadavers and 10 limbs from full-term fetuses. He reports the absence of fibrous AF in fetuses, in contrast to the 30% incidence of fibrous AF in adult cadavers, suggesting that this fibrous component forms in the proximal part of the supinator muscle in response to repetitive pronation and supination movements of the forearm. Papadopoulos et al¹⁶ analyzed a series of 120 cadaveric limbs, observing that the AF was fibrous in 61 specimens (51%). Prasarthitha et al¹⁷ dissected 60 limbs from 30 cadavers, identifying membranous AF in 26 (43%) and fibrotendinous AF in 34 specimens (57%). Riffaud et al¹⁸ dissected 25 cadaveric limbs, demonstrating AFs of fibrous constitution in 23 specimens (95%). Ozturk et al¹⁰ identified tendinous AF in 48 (87%) of the adult cadaveric limbs studied. Clavert et al⁹ reported that the AF had a semicircular shape and tendinous consistency in 26 limbs (87%) and membranous consistency in the remaining 4 specimens. Our study found fibrous AF in 22 limbs (73%) and muscular AF in 8 limbs (27%). This discrepancy of numbers can only be explained by the different ways of interpreting the constitution of the AF.

The supination of the forearm is performed by two muscles, the biceps brachii and the supinator muscle, both functional muscles in C7–T1 palsies.¹⁴ Therefore, the sacrifice of branches to the supinator muscle does not compromise supination due to biceps compensation. In addition, in some cases, only one branch was used for transfer because the other motor branch was very thin.⁵ In such cases, the supinator muscle was not completely denervated, explaining the preserved supination even with the elbow fully extended or flexed, thus abolishing the biceps action.¹⁴

The transfer of radial nerve branches from the supinator muscle to the PIN was described in patients with brachial plexus lower radicular lesions in order to recover the extension of the wrist and fingers.^{5,6} Bertelli et al¹¹ dissected 20 limbs from cadavers prepared at the laboratory; according to these authors, the mean diameter of the PIN distal to the point of branch detachment to the supinator muscle was 3.2 ± 0.6 mm, and the mean diameter of the branches to the supinator muscle was 2.6 ± 0.95 mm. Comparing the recorded PIN diameter to the combined diameter of the branches to the supinator muscle, these authors noted an 80% ratio (2.6 mm versus 3.2 mm). Likewise, the number of myelinated fibers in the supinator muscle branches was approximately 70% of the PIN distal to the AF. We recorded slightly different results; the mean diameter of the supinator branches and the PIN was, respectively, 1.6 ± 0.5 mm and PIN 3.0 ± 0.7 mm so the combined diameter of the branches to the supinator muscle roughly corresponds to 53.5% of the

PIN. In 12 limbs, this ratio was less than 50%, and, in 3, less than 40%. This significant difference between such studies can only be explained by the different measurement and interpretation forms.

Dong et al⁵ reported that there are usually two main branches for the supinator muscle, and the diameter of the major branch is approximately half of the diameter of the PIN; in some cases, these authors used only one branch, so some innervation to the supinator muscle was spared. Our findings agree that there are 2 or more branches to the supinator muscle, but our measurements did not identify any branch with a diameter corresponding to 50% of the PIN diameter. It does not mean, in our view, that this difference in diameter between these works may interfere with the efficacy of such nerve transfer.

Several papers show that nerve transfers between branches with considerable diameter differences and nerve fibers provide good results. For example, the transfer of a radial nerve branch for the head of the long triceps brachii to the axillary nerve is successful even if its diameter is less than 50% of the axillary nerve diameter.¹⁹ De Medinaceli et al²⁰ that a reinnervation of 20 to 30% of muscle fibers is compatible with normal muscle function. Jiang et al²¹ report that the axons in the proximal stump can multiply, with a three to four-fold increase in their numbers. Other factors also warrant this nerve transfer, even if the mean diameter of the supinator branches is less than 50% of the mean diameter of the PIN; for example, although the muscular strength required for thumb and fingers extension is minimal, since little force is required to open the hand, the muscular force required for apprehension is greater than that for release.¹¹ Wrist flexion is preserved in C7–T1 lesions and, through the tenodesis effect, wrist flexion favors fingers extension.² In addition, the supinator muscle is expendable, not only because its function can be replaced by the biceps muscle, but also because the supinator is a nontransferable muscle due to its anatomical location, providing a potential functional gain without sacrificing a valuable donor muscle for tendon transfer.¹¹

We suggest that the surgical approach to PIN and AF can be done with the forearm in pronation. An incision approximately 10 cm long starts at the lateral epicondyle, accompanying the radial axis. The forearm fascia is incised, and the space between the ECRB and the extensor digitorum communis (EDC) muscles is identified. The dissection is deepened into this space, with AF identification. The PIN, proximally to the AF, can be identified by palpation against the radial shaft. The superficial head of the supinator muscle should be sectioned, following the PIN path, to expose the intramuscular portion of the nerve and the branches destined to the supinator muscle. Next, the branches for the supinator muscle and the PIN must be sectioned, allowing a connection with no tension.

Some authors have reported their clinical results with this nerve transfer.^{5,11,22–24} Dong et al⁵ transferred the motor branch from the radial nerve to the supinator muscle to the PIN in four patients. These patients were followed-up and evaluated every three to four months postoperatively. Finger

extension was recovered between five and nine months in the first three cases, and its improvement over time was promising. These authors also report a recent case, still being followed-up, and concluded that the transfer from the supinator motor branch to the PIN provides a reliable recovery of the finger and thumb extension and, therefore, it is a viable option for C7–T1 brachial plexus palsies. In some cases, only one branch to the supinator muscle was used because the other one was too thin. Bertelli e Ghizoni¹¹ report the clinical results of radial nerve branches to the supinator muscle transferred to the PIN in 4 patients with C7–T1 radicular lesions who underwent surgery 5 to 7 months after the injury. The patients were assessed 12 months after the surgery. Thumb and fingers extension was restored in all patients. Xu et al²⁵ reported that there was no reliable method for finger and thumb extension restoration in C7–T1 brachial plexus palsy cases until the transfer of supinator motor branches to the PIN was proposed. These authors performed such transfer in 10 patients, from which 9 recovered at least M3 muscle strength (full range of motion overcoming gravity and small resistance). Zhang et al²² transferred one supinator branch to the PIN in two patients. They reported that this procedure proved to be reliable, effective, and quick in restoring finger and thumb extension. It was efficient even in a late case, where the time interval from trauma to surgery exceeded 15 months due to the short regeneration distance between the donor and recipient nerve. These patients not only recovered the fingers and thumb extension, but also M3 of the extensor carpi ulnaris muscle. Van Zyl et al²³ presented the case of a 21-year-old man with C6 level tetraplegia. They performed a triple nerve transfer. A nervous branch intended for the teres minor muscle was transferred to the branch of the long head of the triceps brachii muscle, a branch of the musculocutaneous nerve for the brachialis muscle was transferred to the anterior interosseous nerve, and a branch of the supinator was transferred to the PIN. These procedures were successful in rebuilding elbow extension, digital pinch and the ability to grasp and release objects. Bertelli et al¹ performed surgeries to restore elbow and finger flexion in 13 upper limbs from 7 patients with tetraplegia (average age, 26 years-old). The patients were operated on average 7 months after spinal cord injury. Elbow extension was restored by transferring axillary nerve branches for the long head of the triceps brachii, while fingers and thumb extension was restored by transferring branches from the supinator muscle to the PIN. Twelve patients recovered fingers and thumb extension, overcoming gravity and some resistance, which indicates an excellent result. Li et al²⁴ reported that 3 operated patients recovered M4 extension (full range of motion overcoming gravity and moderate resistance) of the thumb and fingers extension after a nerve transfer from supinator branches to the PIN.

Conclusions

This anatomical study shows that radial nerve branches destined to the supinator muscle can be transferred directly and with no tension to the PIN in order to restore thumb and

fingers extension in patients with C7–C8 and T1 brachial plexus injuries. The combined diameter of the branches to the supinator muscle corresponded, on average, to 53.5% of the PIN diameter.

Conflicts of Interest

The authors declare that there are no conflicts of interest.

References

- Bertelli JA, Ghizoni MF. Nerve transfers for elbow and finger extension reconstruction in midcervical spinal cord injuries. *J Neurosurg* 2015;122(01):121–127
- Mackinnon SE, Yee A, Ray WZ. Nerve transfers for the restoration of hand function after spinal cord injury. *J Neurosurg* 2012;117(01):176–185
- García-López A, Fernández E, Martínez F. Transfer of brachioradialis motor branch to the anterior interosseous nerve in C8-T1 brachial plexus palsy. An anatomic study. *Microsurgery* 2013;33(04):297–300
- Garg R, Merrell GA, Hillstrom HJ, Wolfe SW. Comparison of nerve transfers and nerve grafting for traumatic upper plexus palsy: a systematic review and analysis. *J Bone Joint Surg Am* 2011;93(09):819–829
- Dong Z, Gu YD, Zhang CG, Zhang L. Clinical use of supinator motor branch transfer to the posterior interosseous nerve in C7-T1 brachial plexus palsies. *J Neurosurg* 2010;113(01):113–117
- Vergara-Amador E, Ramírez A. Anatomic study of the extensor carpi radialis brevis in its relation with the motor branch of the radial nerve. *Orthop Traumatol Surg Res* 2015;101(08):909–912
- Spinner M. The arcade of Frohse and its relationship to posterior interosseous nerve paralysis. *J Bone Joint Surg Br* 1968;50(04):809–812
- Frohse F, Fränkel M. Die muskeln des menschlichen armes. In: Bardeleben K, ed. *Handbuch der anatomie des menschen*. Jena: von Gustav Fischer; 1908
- Clavert P, Lutz JC, Adam P, Wolfram-Gabel R, Liverneaux P, Kahn JL. Frohse's arcade is not the exclusive compression site of the radial nerve in its tunnel. *Orthop Traumatol Surg Res* 2009;95(02):114–118
- Ozturk A, Kutlu C, Taskara N, Kale AC, Bayraktar B, Cecen A. Anatomic and morphometric study of the arcade of Frohse in cadavers. *Surg Radiol Anat* 2005;27(03):171–175
- Bertelli JA, Ghizoni MF. Transfer of supinator motor branches to the posterior interosseous nerve in C7-T1 brachial plexus palsy. *J Neurosurg* 2010;113(01):129–132
- Roberts MM, Oliveros P. Electrodiagnostic examination of the supinator—a more dorsal approach: a brief report. *Am J Phys Med Rehabil* 1999;78(03):281–282
- Russel SM. Examination of the peripheral nerve injuries: an anatomical approach. New York: Thieme; 2006:91–92
- Tubiana R, Thomine JM, Mackin E. Examination of the hand and wrist. London: Martin Dunitz; 1996:286–327
- Ray WZ, Yarbrough CK, Yee A, Mackinnon SE. Clinical outcomes following brachialis to anterior interosseous nerve transfers. *J Neurosurg* 2012;117(03):604–609
- Papadopoulos N, Paraschos A, Pelekis P. Anatomical observations on the arcade of Frohse and other structures related to the deep radial nerve. Anatomical interpretation of deep radial nerve entrapment neuropathy. *Folia Morphol (Praha)* 1989;37(03):319–327
- Prasartritha T, Liupolvanish P, Rojanakit A. A study of the posterior interosseous nerve (PIN) and the radial tunnel in 30 Thai cadavers. *J Hand Surg Am* 1993;18(01):107–112
- Riffaud L, Morandi X, Godey B, Brassier G, Guegan Y, Darnault P, et al. Anatomic bases for the compression and neurolysis of the

- deep branch of the radial nerve in the radial tunnel. *Surg Radiol Anat* 1999;21(04):229–233
- 19 Witoonchart K, Leechavengvongs S, Uerpairojkit C, Thuvasethakul P, Wongnopsuwan V. Nerve transfer to deltoid muscle using the nerve to the long head of the triceps, part I: an anatomic feasibility study. *J Hand Surg Am* 2003;28(04):628–632
 - 20 de Medinaceli L, Rawlings RR. Is it possible to predict the outcome of peripheral nerve injuries? A probability model based on prospects for regenerating neurites. *Biosystems* 1987;20(03):243–258
 - 21 Jiang BG, Yin XF, Zhang DY, Fu ZG, Zhang HB. Maximum number of collaterals developed by one axon during peripheral nerve regeneration and the influence of that number on reinnervation effects. *Eur Neurol* 2007;58(01):12–20
 - 22 Zhang CG, Dong Z, Gu YD. Restoration of hand function in C7-T1 brachial plexus palsies using a staged approach with nerve and tendon transfer. *J Neurosurg* 2014;121(05):1264–1270
 - 23 van Zyl N, Hahn JB, Cooper CA, Weymouth MD, Flood SJ, Galea MP. Upper limb reinnervation in C6 tetraplegia using a triple nerve transfer: case report. *J Hand Surg Am* 2014;39(09):1779–1783
 - 24 Li Z, Reynolds M, Satteson E, Nazir O, Petit J, Smith BP. Double distal intraneural fascicular nerve transfers for lower brachial plexus injuries. *J Hand Surg Am* 2016;41(04):e15–e19
 - 25 Xu B, Dong Z, Zhang CG, Gu YD. Clinical outcome following transfer of the supinator motor branch to the posterior interosseous nerve in patients with C7-T1 brachial plexus palsy. *J Reconstr Microsurg* 2015;31(02):102–106