

Achalasia in a Patient Undergoing Hematologic Stem Cell Transplant After Exposure to Tacrolimus

Sencer Goklemez; Lauren M. Curtis, MD; Alao Hawwa, MD; Alexander Ling, MD; Daniele Avila, CRNP; Theo Heller, MD; and Steven Z. Pavletic, MD

Abstract

Calcineurin inhibitors (CNIs) are effective agents used for prevention of graft-vs-host disease after allogeneic hematopoietic stem cell transplant or for organ rejection in solid-organ transplant. However, CNIs have a wide range of adverse effects that may necessitate changing to another CNI or immunosuppressive agent. We report a case of acute myeloid leukemia in which achalasia developed after exposure to tacrolimus, as revealed by esophagram results. The patient's symptoms and signs were ameliorated after a change to cyclosporine. This case is the first in the literature to reveal achalasia associated with tacrolimus. Achalasia should be part of a differential diagnosis of upper gastrointestinal symptoms in patients undergoing transplant, and changing to another CNI may be a useful therapeutic intervention.

© 2017 Mayo Foundation for Medical Education and Research. Published by Elsevier Inc. This is an open access article under the CC BY-NC-ND license (<http://creativecommons.org/licenses/by-nc-nd/4.0/>) ■ *Mayo Clin Proc Inn Qual Out* 2017;1(2):198-201

From the Experimental Transplantation and Immunology Branch, National Cancer Institute (S.G., L.M.C., D.A., S.Z.P.); Translational Hepatology Unit, Liver Diseases Branch, National Institute of Diabetes and Digestive and Kidney Diseases (A.H., T.H.); and Radiology and Imaging Sciences (A.L.), National Institutes of Health, Bethesda, MD.

Calcineurin inhibitors (CNIs) are commonly used for prophylaxis of graft-vs-host disease (GVHD) in patients undergoing allogeneic hematopoietic stem cell transplant (HSCT) and for rejection in solid-organ transplant.¹ They are known to be associated with many adverse effects, including nephrotoxicity, hypertension, vulnerability to infection, and neurotoxicity.^{2,3} The gastrointestinal adverse effects of CNIs are mostly limited to nausea, vomiting, decreased oral intake, and elevation of liver enzyme levels. We present a compelling case of symptomatic achalasia likely induced by tacrolimus after allogeneic HSCT.

REPORT OF CASE

A 57-year-old male patient from Pakistan, with a history of acute promyelocytic leukemia and subsequent treatment-related acute myelocytic leukemia, received a reduced-intensity, 10 out of 10 human leukocyte antigen–matched, unrelated donor transplant. Conditioning pretransplant included administration of fludarabine and cyclophosphamide. For GVHD prophylaxis, tacrolimus and sirolimus were both started on day –3,

with goal levels of 5 to 10 ng/mL for tacrolimus and 3–12 ng/mL for sirolimus; 5 mg/m² intravenous (IV) methotrexate was given on days +1, +3, +6, and +11 posttransplant. In addition, the patient was taking ursodiol, acyclovir, fluconazole, ceftriaxone, tamsulosin, and metoprolol. On day –1 from transplant, the patient reported odynophagia, which at the time was attributed to mucositis. Given that the patient's amylase and lipase levels were elevated (amylase peak value, 185 U/L; lipase, 223 U/L) and a computed tomography scan of the abdomen revealed mild stranding around the pancreas suspicious for pancreatitis, bowel rest, IV hydration, and pain medications were initiated. By day +15, he had resumed oral intake but started experiencing worsening dysphagia with pills and solid food. Results of an oropharyngeal barium swallow test on day +19 were normal, except for mildly reduced motility of the proximal esophagus. By day +22, he was discharged home, although most of his medications were changed to liquid formulations, owing to persistent dysphagia.

On day +33, the patient was readmitted to the hospital for IV antibiotic treatment of an

abscess on his right arm that was related to a peripherally inserted central catheter line. While the patient was in the hospital, he complained of dysphagia and retrosternal discomfort. A barium swallow test, this time assessing the entire esophagus, was obtained on day +35 (Figure, A). Results revealed persistent, marked, smooth narrowing of the lower esophageal sphincter, with substantially delayed emptying of liquid barium, in a manner consistent with achalasia. After administration of twice-daily pantoprazole, the patient's chest

and abdominal pain improved. He began to tolerate pills and small quantities of food and was discharged from the hospital.

His improvement in oral intake was short-lived, and by day +50, his dysphagia once again worsened. To evaluate for GVHD vs pseudoachalasia, the patient underwent endoscopy on day +77. Results revealed mild duodenitis, but pathology test results were negative for GVHD and cytomegalovirus (CMV). Esophageal manometry results on day +78 were consistent with achalasia, with

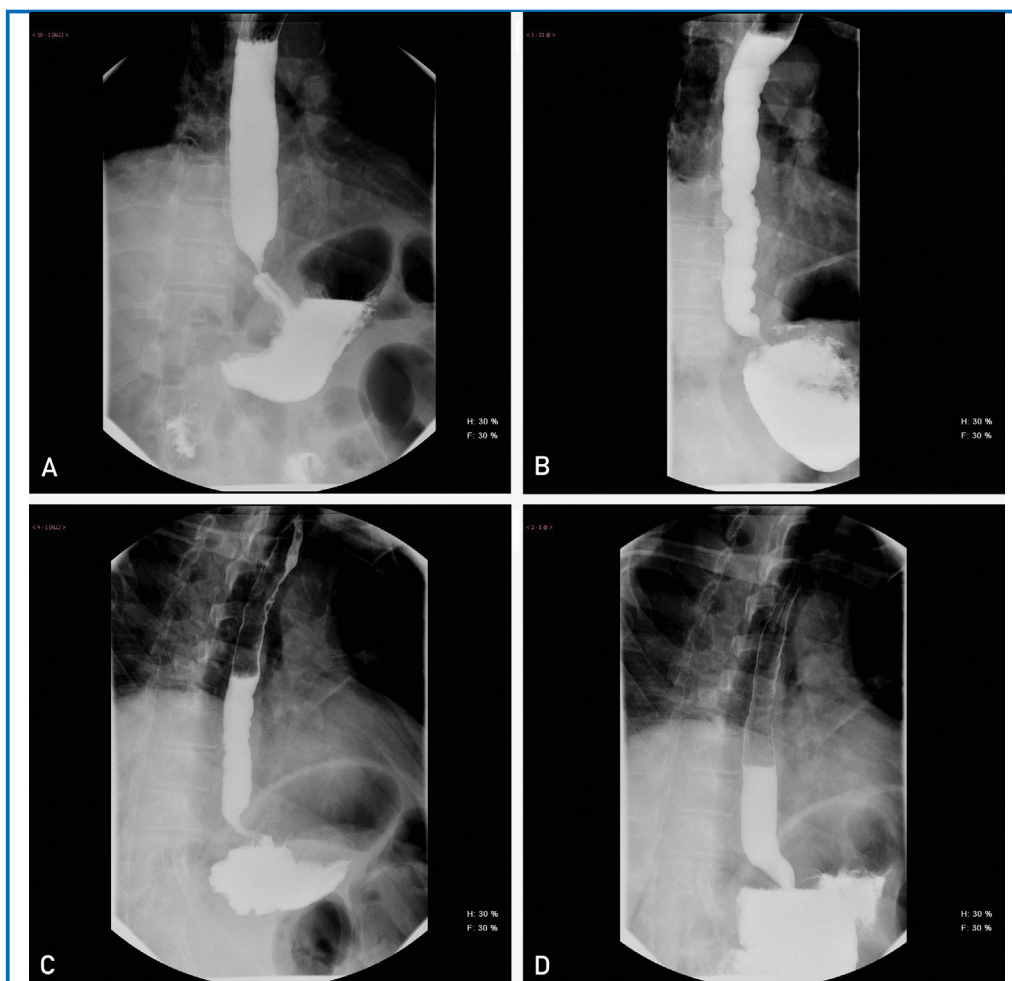


FIGURE. A, Results of esophagram at day +35 after transplant, with decreased peristalsis and spasm of the lower esophageal sphincter, consistent with the diagnosis of achalasia. B, Esophagram results at day +96 after transplant, with improved tertiary peristalsis soon after changing tacrolimus to cyclosporine for graft-vs-host disease prophylaxis. C, Esophagram results at day +140 after transplant, with improved esophageal motility pattern and minimally delayed emptying of contrast medium. D, Esophagram results at day +180 after transplant, with resolution of achalasia as seen from near-normal peristalsis as well as widely patent lower esophageal sphincter.

a lower esophageal sphincter pressure of 22 mm Hg (normal range, 8-12 mm Hg), and his esophagus was aperistaltic.

The patient also began to experience severe generalized bone and muscle pain, which was suspected of being secondary to tacrolimus. In an effort to relieve his pain, on day +84, tacrolimus was changed to cyclosporine. On day +96, the patient underwent another outpatient esophagram, results of which were consistent with those of the previous one, except that they revealed more tertiary peristalsis (Figure, B). At a follow-up visit on day +140, the esophagram was repeated, and this time results revealed a much better esophageal motility pattern, with only minimally delayed emptying, and rapid progression of contrast into the esophagus (Figure, C). However, the patient continued to complain of dysphagia, reflux, and upper abdominal pain. His appetite was poor because of these difficulties, and his weight was 64.5 kg (a 19% decrease from his pretransplant weight). Options for treatment of the achalasia were considered, including Heller myotomy, onabotulinum toxin A injection, and endoscopic balloon dilation. Given that less than 6 months had passed since the HSCT, invasive surgery was undesirable because of infection and wound-healing risks. A repeated endoscopy with onabotulinum toxin A injection was planned, owing to his ongoing weight loss and gastrointestinal symptoms.

At the patient's 6-month visit, he presented for his pre-onabotulinum toxin A assessment and, surprisingly, reported marked improvement in his symptoms, with increased ability to eat solids and liquids. A repeated esophagram was obtained (Figure, D). Results revealed a complete absence of lower esophageal sphincter narrowing, with peristaltically coordinated, normal prompt passage of contrast materials from the distal esophagus into the stomach and only minor dysmotility, as evidenced by only minimal and transient tertiary peristalsis. The patient reported corresponding improvement in his symptoms, and onabotulinum toxin A therapy was cancelled. A review of his history revealed that the only recent intervention or medication

change was switching from tacrolimus to cyclosporine 3 months before the dramatic improvement in his esophageal motility.

DISCUSSION

To our knowledge, this case report is the first to discuss a new diagnosis of achalasia after allogeneic HSCT. Given the temporal relationship of development of an exacerbation of achalasia soon after starting tacrolimus and complete resolution after stopping, we suspect that starting tacrolimus was the most likely inciting cause. Koch et al⁴ reported on a liver transplant recipient who experienced achalasia 3 months after transplant and for whom cyclosporine was started for organ rejection prophylaxis. When cyclosporine was changed to tacrolimus, the patient's esophageal mobility returned to normal. The authors speculated that this result may have occurred via inhibition of nitric oxide synthase (NOS) by CNIs.

Nitric oxide (NO) is present at the neurons along the entire esophageal lining, including the lower esophageal sphincter, and is not only responsible for appropriate relaxation of the sphincter to allow passage of food and liquid but also contributes to peristaltic movements of the body. Nitric oxide is synthesized by NOS. The inhibitory nonadrenergic noncholinergic neurons at the esophagus secrete NO (using their NOS) as a neurotransmitter,⁵ causing hyperpolarization of the innervated muscle, inhibiting its contraction. If this mechanism is somehow disrupted, the unopposed activity of the activator neurons secreting acetylcholine may prevent proper relaxation, causing a stiff lower esophageal sphincter and a body with unsynchronized peristalsis. Several reports suggest that CNIs may decrease NO levels in other diseases, including hypertension,⁶ inflammatory bowel disease,⁷ and renal diseases.⁸ Observations in the current case very likely result from decreased NO levels in the postganglionic neurons of the esophageal tract, leading to unopposed contractile activity. Changing from one drug to another was associated with resolution of achalasia within 3 months, in both our patient and the case reported by Koch et al.⁴ Owing to the difference in chemical structure between tacrolimus and cyclosporine, various drugs within the same class may have widely varying effects in different patients.⁹

This useful therapeutic substitution of one CNI for another is reported in thrombotic microangiopathy, or posterior reversible encephalopathy syndrome; several reports reveal that changing the CNI can lead to resolution or improvement of symptoms.¹⁰⁻¹² If achalasia symptoms do not improve, however, CNI cessation should be considered in certain cases.

CONCLUSION

Upper gastrointestinal symptoms after allogeneic HSCT can have multiple causes, including chemotherapy-related mucositis, gastrointestinal GVHD, CMV reactivation, and reflux-related gastritis.¹³ Achalasia could have been an underdiagnosed, drug-induced cause of gastrointestinal symptoms and should be considered in patients who have abdominal pain, reflux, dysphagia, and/or anorexia. If endoscopy with biopsy results are negative for GVHD and CMV and the work-up is otherwise unrevealing, an esophagram should be obtained. In this patient, a temporal association was found between the presence of achalasia and the starting and stopping of tacrolimus. Achalasia may be a rare adverse effect of CNIs, which may disrupt esophageal motility via decreasing NO levels in the postganglionic neurons of the esophageal tract. Once achalasia is diagnosed, changing from one CNI to another may be an effective management strategy.

ACKNOWLEDGMENTS

The opinions expressed in this article are those of the authors and do not represent the official position of the National Institutes of Health, National Cancer Institute, or the United States Government.

Abbreviations and Acronyms: CMV = cytomegalovirus; CNI = calcineurin inhibitor; GVHD = graft-vs-host disease; HSCT = hematopoietic stem cell transplant; IV = intravenous; NO = nitric oxide; NOS = nitric oxide synthase

Grant Support: This work was supported by the National Institutes of Health, National Cancer Institute, Intramural Program Center for Cancer Research.

Potential Competing Interests: The authors report no competing interests.

Correspondence: Address to Steven Z. Pavletic, MD, 10 Center Dr, Bethesda, MD 20892 (pavletis@mail.nih.gov).

REFERENCES

1. Ferrara JL, Levine JE, Reddy P, Holler E. Graft-versus-host disease. *Lancet*. 2009;373(9647):1550-1561.
2. Kahan BD. Cyclosporine. *N Engl J Med*. 1989;321(25):1725-1738.
3. Scott LJ, McKeage K, Keam SJ, Plosker GL. Tacrolimus: a further update of its use in the management of organ transplantation. *Drugs*. 2003;63(12):1247-1297.
4. Koch R, Zoller H, Graziadei I, Propst A, Vogel W. Cyclosporine A-induced achalasia-like esophageal motility disorder in a liver transplant recipient: successful conversion to tacrolimus. *Transplantation*. 2003;76(4):744-745.
5. Mashimo H, Goyal RK. Physiology of esophageal motility. <https://www.nature.com/gimo/contents/pt1/full/gimo3.html>. Accessed July 26, 2017.
6. Cook LG, Chiasson VL, Long C, Wu G-Y, Mitchell BM. Tacrolimus reduces nitric oxide synthase function by binding to FKBP rather than by its calcineurin effect. *Kidney Int*. 2009;75(7):719-726.
7. Hämäläinen M, Lahti A, Moilanen E. Calcineurin inhibitors, cyclosporin A and tacrolimus inhibit expression of inducible nitric oxide synthase in colon epithelial and macrophage cell lines. *Eur J Pharmacol*. 2002;448(2-3):239-244.
8. Baran DA, Galin ID, Gass AL. Calcineurin inhibitor-associated early renal insufficiency in cardiac transplant recipients: risk factors and strategies for prevention and treatment. *Am J Cardiovasc Drugs*. 2004;4(1):21-29.
9. Schreiber SL. Chemistry and biology of the immunophilins and their immunosuppressive ligands. *Science*. 1991;251(4991):283-287.
10. Kaufman DB, Kaplan B, Kanwar YS, Abecassis M, Stuart FP. The successful use of tacrolimus (FK506) in a pancreas/kidney transplant recipient with recurrent cyclosporine-associated hemolytic uremic syndrome. *Transplantation*. 1995;59(12):1737-1739.
11. Abdalla AH, Al-Sulaiman MH, Al-Khader AA. FK 506 as an alternative in cyclosporin-induced hemolytic uremic syndrome in a kidney transplant recipient. *Transpl Int*. 1994;7(5):382-384.
12. Apuri S, Carlin K, Bass E, Nguyen PT, Greene JN. Tacrolimus associated posterior reversible encephalopathy syndrome—a case series and review. *Mediterr J Hematol Infect Dis*. 2014;6(1):e2014014.
13. McDonald GB. How I treat acute graft-versus-host disease of the gastrointestinal tract and the liver. *Blood*. 2016;127(12):1544-1550.