

Case Report**Intra-abdominal heterotopic ossification of the peritoneum following traumatic splenic rupture**

*Orestis Ioannidis,¹ Argiro Sekouli,² George Paraskevas,³
Anastasios Kotronis,¹ Stavros Chatzopoulos,¹ Nikolaos Papadimitriou,¹
Athina Konstantara,¹ Apostolos Makrantonakis,¹ Emmanouil Kakoutis¹*

Abstract

Intra-abdominal heterotopic ossification is extremely rare with only approximately 30 cases having been reported. While most reported cases have involved the mesentery, ossification of the peritoneum is even rarer. The pathogenesis remains undetermined but is generally considered a reactive process in response to various stimuli. Histologically, it is composed of a peripheral area with bone formation and a central area of reactive hypercellular fibrous tissue. We report a rare case of intra-abdominal heterotopic ossification of the parietal peritoneum following traumatic splenic rupture.

KEYWORDS: Peritoneum, Bone, Myositis Ossificans.

J Res Med Sci 2012; 17(1): 92-95

The term heterotopic ossification refers to bone formation in a normally non-ossifying tissue. It represents a benign, localized, self-limiting, well-circumscribed lesion.^{1,2,3} The phenomenon is rather unusual in the immediate vicinity of skeletal bones while it is very rare in soft tissues.² Many other terms such as myositis ossificans, pseudomalignant osseous tumor, fibrositis ossificans, fibrodysplasia ossificans and neurogenic osteoma have been used to refer to soft tissue heterotopic ossification.¹⁻³

Intra-abdominal heterotopic ossification (IHO) is also known as intra-abdominal myositis ossificans, mesenteritis ossificans, heterotopic mesenteric ossification and heterotopic ossification of the intestinal mesentery. It is extremely rare and only approximately 30 cases have been reported in the literature since the first description in 1983.¹⁻⁵ With the most reported cases involving the mesentery, ossi-

fication of the peritoneum seems even rarer.^{2,3,6} We report a very rare case of IHO of the parietal peritoneum following traumatic splenic rupture.

Case Report

A 25 year-old male was transferred to the emergency department of our hospital following a car accident (1st Surgical Department, General Regional Hospital "George Papanikolaou", Thessaloniki, Greece, 2006). The patient, who was intubated, suffered from major trauma including an open fracture of the left tibia, an open fracture of the right radius and ulna, a right temporo-occipital subdural hematoma, fractures of the lower left ribs and splenic rupture. Splenectomy and surgical management of the fractures and the subdural hematoma were performed. The patient was then transferred to the intensive care unit (ICU). Six days later, acalculous cholecystitis was observed and

1- First Surgical Department, George Papanikolaou General Regional Hospital, Thessaloniki, Greece.

2- Department of Pathology, George Papanikolaou General Regional Hospital, Thessaloniki, Greece.

3- Department of Anatomy, School of Medicine, Aristotle University of Thessaloniki, Thessaloniki, Greece.

Corresponding author: Orestis Ioannidis

E-mail: telonakos@hotmail.com

open cholecystostomy was therefore conducted. On the 12th postoperative day, a tracheostomy was performed. A persistent fever and leukocytosis of unknown primary origin, at the 20th postoperative day, led to an abdominal CT scan which was normal except for the IHO of the parietal peritoneum. As the finding was incidental and was asymptomatic, the patient was managed conservatively. Fifty three days after the accident, the patient developed an esophagotracheal fistula and was therefore subjected to a gastrostomy. Because of the IHO of the parietal peritoneum, the gastrostomy was performed surgically. During the laparotomy, the IHO of the parietal peritoneum of the midline was observed and excised. Histopathological examination demonstrated mature osseous tissue (both solid and cancellous) and hyaloids cartilage and confirmed the diagnosis (Figure 1). Two months after the gastrostomy, the patient, still having the gastrostomy, underwent another abdominal CT scan because of vague abdominal pain. The CT scan demonstrated recurrence of the ossification of the parietal peritoneum (Figure 2). The patient was treated conservatively. Six years after the accident, the patient

is alive and well while the IHO of the peritoneum is stable in size and does not cause any symptoms.

Discussion

IHO is a rare presentation of heterotopic ossification (or myositis ossificans) usually affecting the mesentery and seldom the omentum, peritoneum or other intra-abdominal organs.^{2,3,5,6} Heterotopic mesenteric ossification usually develops within 1 to 3 weeks following the stimuli.^{7,8} While peritoneal ossification has been reported in very few cases and is mostly related to peritoneal dialysis,^{2,3,6} the present case of posttraumatic peritoneal ossification following splenic rupture was unique. Peritoneal ossification has been observed a few months to a period of years after the initiation of peritoneal dialysis. However, in the present case, ossification rapidly developed in only one and a half month.^{2,6} Clinically, IHO shows a male predominance (male to female ratio 3:2) and presents a wide age distribution most commonly affecting patients in mid and late adulthood.^{3,5} The most usual clinical presentation is intestinal obstruction, mainly in cases affecting the mesentery, with the symptoms

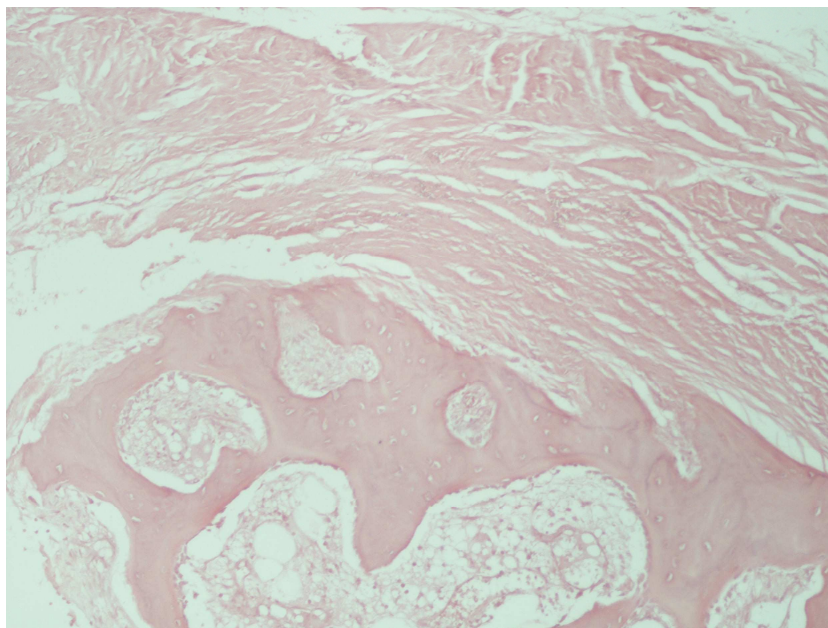


Figure 1. Hematoxylin and eosin stain of the intra-abdominal heterotopic ossification of the parietal peritoneum demonstrating osseous tissue and bone marrow formation without hematopoietic cells in the lower half and the peritoneum in the upper half (X100)

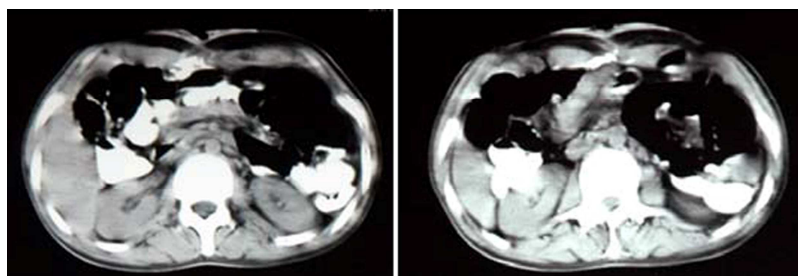


Figure 2. Abdominal CT scan demonstrating the intra-abdominal heterotopic ossification of the parietal peritoneum

including abdominal pain, nausea, vomiting, obstipation and distension, intestinal perforation and peritonitis, and enterocutaneous fistula in cases mainly of omental involvement. It can also be an incidental finding in asymptomatic patients as in the current case.^{3-5,8,9} Laboratory examination demonstrates an increased alkaline phosphatase due to osteoblastic activity and is considered a sensitive indicator.¹ Radiographs may be unremarkable or may reveal a trabecular architecture which is considered highly suggestive of IHO. On the other hand, CT scan can confirm the diagnosis by revealing multiple linear branching opacities with trabecular ossifications.^{1,3,7,10}

Although the pathogenesis of IHO still remains uncertain and undetermined, a reactive process in response to various stimuli has mostly been considered as responsible.^{1,8} While abdominal trauma and/or abdominal surgery have been present in almost all cases, neoplasia, infection, ischemia, prolonged immobilization and venous stasis, burns, inflammation and edema have also been associated with IHO.^{1,3,8,11} The mechanism of ossification can be explained by two theories: 1) bone formation is developed from implementation of small particles containing osteogenic cells from perichondrium or periosteum of pubic symphysis or sternum, or rarely other bones, that are incubated during laparotomy or trauma or 2) stem cells differentiated to mesoblast and also erroneously to osteoblasts or chondroblasts due to local injury or infectious inflammatory stimuli.^{2,4,11} In the current case, the most possible explanation of IHO of the peritoneum was the implementation of bone particles following the fractures in ribs.

IHO is composed of a peripheral area with bone formation and a central area of hypercellular reactive fibrous tissue.³ Microscopic examination of IHO revealed an admixture of zones reminiscent of sclerosing mesenteritis with fat necrosis and inflammation, as well as zones identical to myositis ossificans with peripheral endochondral ossification, ordered chondroid differentiation and myofibroblastic proliferation.⁵ The most important diagnostic criterion is the zone phenomena, a term referring to the progressive maturation of the immature central portion towards the periphery from atypia, mitosis and hypercellularity, to first primitive osteoid, then well-organized osteoid with prominent osteoblastic rimming and finally mature lamellar bone.¹²

Differential radiological diagnosis should be made based on postoperative complications including retained foreign bodies and wound infection, metastatic and primary neoplasms, especially osseous ones, oral contrast leakage and dystrophic calcification.^{3,7,13} Histopathological differential diagnosis must be based on malignances, mainly extraskeletal osteosarcoma, dedifferentiated liposarcoma,^{3,5} and the number of mitosis, level of cellularity and the grade of nuclear polymorphism.⁴

IHO has a good prognosis, without any malignant potential, but shows the tendency for recurrence and can also contribute to morbidity due to bowel obstruction.^{3,5} Surgical intervention is deemed necessary only in symptomatic cases or for the treatment of complications and should be generally avoided whenever possible because IHO is related to repetitive surgery.³ In cases of surgery, anti-inflammatory drugs, diphospho-

nates and radiotherapy may prove useful in prevention of recurrence,³ while anti-inflammatory drugs also reduce the incidence of the disease.

Conflict of Interests

Authors have no conflict of interests.

Authors' Contributions

OI wrote the manuscript, performed the final proof reading. AS significantly contributed to the literature review and writing the manuscript. GP significantly contributed to the writing and linguistic formatting of the manuscript. AK significantly contributed to conception and design and to the writing. SC significantly contributed to the literature review and linguistic formatting of the manuscript. NP was involved in the research and interpretation and linguistic formatting of the manuscript. AK was involved in reviewing the literature and acquisition, analysis and interpretation of data and also in writing. AM significantly contributed to the correction and linguistic formatting of the manuscript. EK significantly contributed to the correction of the manuscript and was responsible for final proof reading of the article.

References

1. Bovo G, Romano F, Perego E, Franciosi C, Buffa R, Uggeri F. Heterotopic mesenteric ossification ("intraabdominal myositis ossificans"): a case report. *Int J Surg Pathol* 2004; 12(4): 407-9.
2. Di PN, Sacchi G, Lorenzoni P, Sansoni E, Gaggiotti E. Ossification of the peritoneal membrane. *Perit Dial Int* 2004; 24(5): 471-7.
3. Zamolyi RQ, Souza P, Nascimento AG, Unni KK. Intraabdominal myositis ossificans: a report of 9 new cases. *Int J Surg Pathol* 2006; 14(1): 37-41.
4. Patel RM, Weiss SW, Folpe AL. Heterotopic mesenteric ossification: a distinctive pseudosarcoma commonly associated with intestinal obstruction. *Am J Surg Pathol* 2006; 30(1): 119-22.
5. Vlachos K, Archontovasilis F, Karameris A, Tsiambas E, Lagoudiannakis E, Manouras A. Heterotopic mesenteric ossification after gastrectomy for watermelon stomach. *J Gastrointest Liver Dis* 2009; 18(2): 229-31.
6. Kuo PH, Shin MS. Images in clinical medicine. Pulmonary and peritoneal ossification. *N Engl J Med* 2007; 356(17): e16.
7. Hashash JG, Zakhary L, Aoun EG, Refaat M. Heterotopic mesenteric ossification. *Colorectal Dis* 2012; 14(1): e29-e30.
8. Shi X, Zhang W, Nabieu PF, Zhao W, Fu C. Early postoperative heterotopic omental ossification: report of a case. *Surg Today* 2011; 41(1): 137-40.
9. Yushuva A, Nagda P, Suzuki K, Llaguna OH, Avgerinos D, Goodman E. Heterotopic mesenteric ossification following gastric bypass surgery: case series and review of literature. *Obes Surg* 2010; 20(9): 1312-5.
10. Hakim M, McCarthy EF. Heterotopic mesenteric ossification. *AJR Am J Roentgenol* 2001; 176(1): 260-1.
11. Gouello JP, Auvray L, Bouix A, Vazelle F, Guinard N, Hermes D. Early post-traumatic heterotopic mesenteric ossification: report of a case. *Intensive Care Med* 2006; 32(6): 950-1.
12. Wilson JD, Montague CJ, Salcuni P, Bordi C, Rosai J. Heterotopic mesenteric ossification ('intraabdominal myositis ossificans'): report of five cases. *Am J Surg Pathol* 1999; 23(12): 1464-70.
13. Lai HJ, Jao SW, Lee TY, Ou JJ, Kang JC. Heterotopic mesenteric ossification after total colectomy for bleeding diverticulosis of the colon--a rare case report. *J Formos Med Assoc* 2007; 106(2 Suppl): S32-S36.