

# A study on orthomorphic correction of mandibular dysmorphology

Access this article online

Website:  
www.amsjournal.com

DOI:  
10.4103/2231-0746.92774

Quick Response Code:



Saikrishna Degala, Sujeeth Shetty, Gen Morgan

Department of OMFS, JSS Dental College and Hospital, Mysore, Karnataka, India

Address for correspondence:

Dr. Saikrishna Degala, Department of OMFS,  
JSS Dental College and Hospital, Mysore, Karnataka, India.  
E-mail: degalasaikrishna@gmail.com

## ABSTRACT

**Purpose:** To evaluate the usefulness of orthomorphic surgery in correcting mandibular dysmorphology. **Materials and Methods:** This is a prospective study in which five patients having mandibular dysmorphology were treated using orthomorphic surgery. The patients were evaluated for outcome in terms of duration of surgery, assessment of mandibular split, mental nerve paresthesia/ neurosensory changes after surgery, assessment of mouth opening before and after surgery, postoperative assessment of mandibular symmetry, and postoperative complications. **Statistical Analysis Used:** Descriptive statistics, frequencies, contingency coefficient test (cross tabs). **Results:** Our study has revealed results in support of the technique mentioned, showing good success rate in terms of mandibular dysmorphology correction when used in mild to moderate dysmorphology cases. **Conclusion:** Orthomorphic surgery will play an increasingly important role in the repertoire of the maxillofacial surgeon in correcting mandibular dysmorphology.

**Keywords:** Functional occlusion, oral surgery, mandibular asymmetry

## INTRODUCTION

All normal human faces have some degree of asymmetry. The ancient Greeks were probably the first to notice these variations between the two sides of the face, as discovered much later by analysis of their statuary, which included mild to moderate facial asymmetries. Normal asymmetries such as these often go unnoticed by the general public. Esthetically pleasing and apparently symmetrical faces do indeed exhibit skeletal asymmetries and one side of the face can be rather different from the other and still be considered completely normal. The level at which asymmetry becomes unacceptable to a patient is variable and depends on many factors, most of which are psychological.<sup>[1]</sup>

Facial asymmetry, when obvious, has enormous sociopsychological impact on the affected individuals. It can occur as a consequence of developmental anomalies or disease or after trauma or surgery. Surgical reconstruction is usually indicated in most instances involving a noticeable facial asymmetry. This is usually accomplished by reconstructing the deformed portion with its

normal counterpart working as a reference.<sup>[2]</sup> Patients who present with significant facial asymmetry are not only concerned with restoring functional occlusion but also with improving esthetics and beauty. This has often been a source of social scorn for many of these patients. Beauty and symmetry have often been thought of synonymously; hence, the belief that unattractiveness is the result of asymmetry.<sup>[3]</sup>

Unilateral temporomandibular joint ankylosis occurring during the active growth period if left without treatment, or when improperly treated, is often complicated by the development of secondary changes in the structure, shape, and size of the mandible together with the surrounding tissues.<sup>[4]</sup> Mandibular asymmetry may be caused by infection and trauma during the growing period. Primary trauma may lead to asymmetry and in some cases ankylosis. Asymmetry may also follow a surgical procedure or a malunited fracture.<sup>[5]</sup>

Orthognathic surgery for the correction of facial deformity arising from discrepancy in spatial relationship or dimensional differences

is well established. However, when the cause of the deformity includes an alteration of the shape of the jaws, orthognathic surgery is unable to correct the resulting contour deformity.<sup>[6]</sup> For this reason in the management of facial asymmetry, orthomorphic principles of management are an adjunct to orthognathic surgery or osseodistraction.<sup>[7]</sup>

The surgical correction consisting of an osteotomy aimed at restoring the morphology is denoted the term “orthomorphic” to distinguish it from conventional orthognathic surgery. The orthomorphic correction aims to correct deformities related to shape and contour of the jaws without affecting the status of occlusion.<sup>[6]</sup>

## MATERIALS AND METHODS

In this clinical study, five patients having mandibular dysmorphism were randomly selected and evaluated.

### Inclusion Criteria

1. Patients after cessation of skeletal growth.
2. Patients operated for TMJ ankylosis (both unilateral and bilateral).
3. Hemimandibular hyperplasia.
4. Mandibular asymmetry secondary to craniofacial anomalies.

### Exclusion Criteria

1. Patients having hemifacial microsomia.
2. Patients who are medically compromised (uncontrolled diabetes, psychiatric condition, and alcohol or drug abuse).
3. Patients with systemic bone diseases.

### Surgical technique

All cases were treated under general anesthesia with nasotracheal intubation. Face was painted with povidone-iodine followed by spirit. The oral cavity was prepared with diluted povidone-iodine. Towels and drapes were applied to expose the surgical area. Local infiltration at the incision site was done using 2% lignocaine with 1:80,000 adrenaline for vasoconstriction. Access to the ramus and mental region was made with two separate lower vestibular incisions and a mucoperiosteal flap raised to visualize the lower border of the mandible. Care was taken to prevent mental nerve injury. In cases of unilateral ankylosis, the osteotomy was performed on the nonankylosed side of mandible. The osteotomy was designed as an eccentric genioplasty extended along the corpus to an osteotomy of the lateral cortex of the ramus. A full-thickness osteotomy of the lower border of the mandible was done closer to the area where the corpus is joined in an eccentric position. The osteotomy was extended to involve the lateral aspect of the ramus following the external oblique ridge similar to the Dal Pont modification of Obwegeser sagittal split osteotomy with the difference being the medial cut being placed on the lateral aspect of ramus. Care was taken to ensure that the inferior alveolar neurovascular bundle is not compromised at the junction between the corpus and the ramus as the osteotomy cut is changed from full thickness to an outer cortical osteotomy. The anterior segment was positioned to correct midline and restore vertical and anteroposterior relationship as planned [Figure 1]. The determination of the final position was subjective. Fixation was performed with mini bone plates, and autogenous corticocancellous bone grafts harvested from iliac crest were

sandwiched and used to bridge overlapping edges. The incision was sutured using 3-0 vicryl sutures after hemostasis was achieved ensuring a watertight seal. An extraoral pressure dressing was also applied. Patient was advised to take liquid diet for 2 days followed by soft diet for 2 weeks.

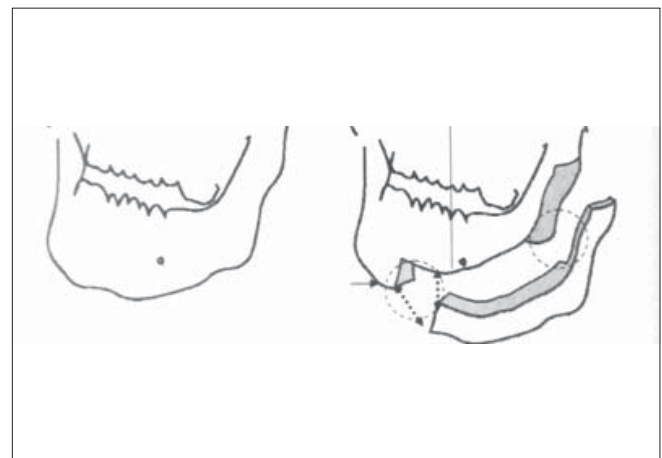
All the subjects received Chlorhexidine mouth wash and intravenous antibiotics (Amoxicillin 500 mg and Metronidazole 500 mg 8<sup>th</sup> hourly) from the day of surgery to 5 days postoperatively, followed by a 5-day course of oral antibiotics.

Patients were evaluated on first and third postoperative day, 2 weeks and 6 weeks postoperatively by,

- **Duration of surgery**
- **Assessment of mandibular split.**  
Assessed clinically and graded into:  
*Favorable:* When there is no fracture of buccal or lingual fragments.  
*Unfavorable:* When there is fracture of buccal or lingual fragments.
- **Mental nerve paresthesia/neurosensory changes after surgery.**  
Assessed using Light Touch Sensation test and Brush directional strokes test.
- **Assessment of mouth opening before and after surgery.**  
Inter incisal clearance was measured using a Willis gauge.
- **Postoperative assessment of mandibular symmetry.**  
Assessed by surgeon, subjectively after 2 weeks postoperatively and 6 weeks postoperatively.
- **Soft tissue infection.**  
Assessed by occurrence of any swelling, pain, tenderness, wound dehiscence, or pus discharge from the operated site.
- **Infection requiring debridement.**
- **Nonunion/delayed union.**  
Assessed by excessive mobility at the operated site 4 weeks postoperatively.

## RESULTS

There were three males and two female patients. Minimum



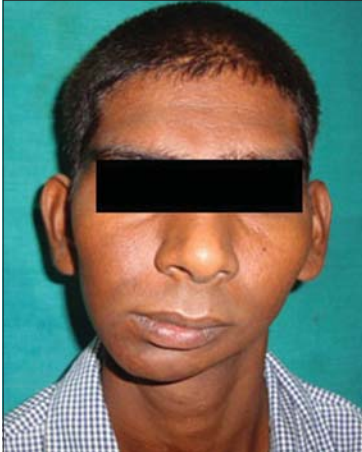**Figure 1:** Line diagram showing the planned osteotomy. Dotted circles show the area where the osteotomized fragment can be positioned three dimensionally to correct deformity

duration of surgery was 120 min and the maximum duration was 130 min with a mean of 125 min. Standard deviation was five.

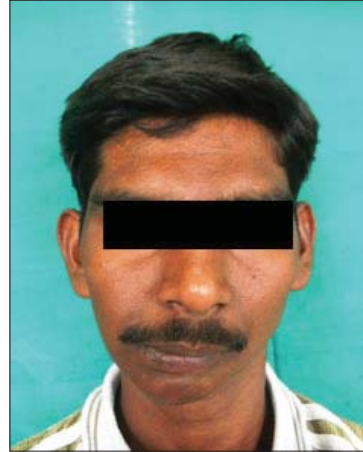Two patients had postoperative mental nerve paresthesia on third postoperative day, 2 weeks, and 6 weeks postoperatively. Contingency coefficient was found to be 0.354 at a *P* value

of 0.414 which is not significant. Representative clinical and radiological images are given in Figures 2–15.

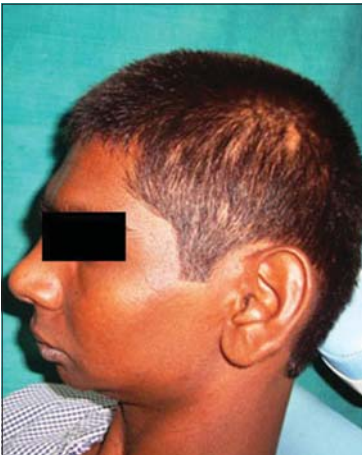The mean preoperative mouth opening was 32.2000 and the second postoperative week was 29.6000. The mean mouth opening on sixth postoperative week was 32.2000.



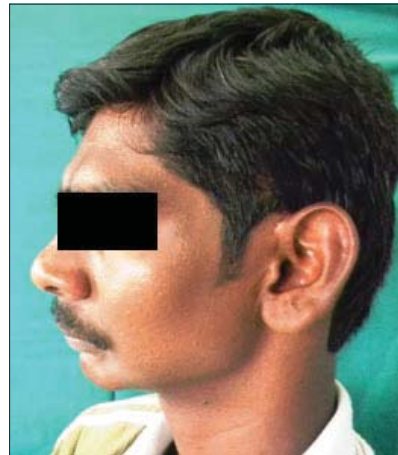**Figure 2:** Preoperative photograph of case 1 (frontal view)



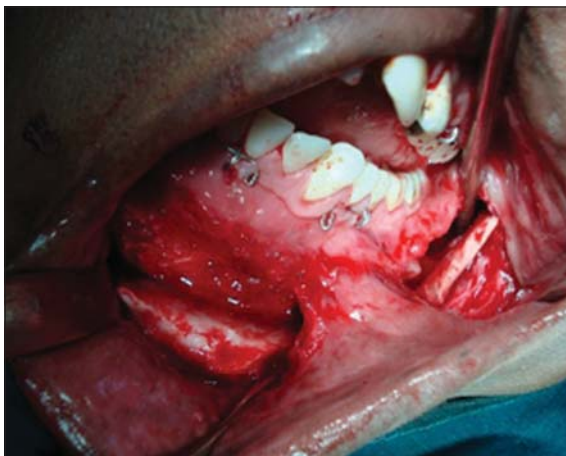
**Figure 3:** Postoperative photograph of case 1 (frontal view)



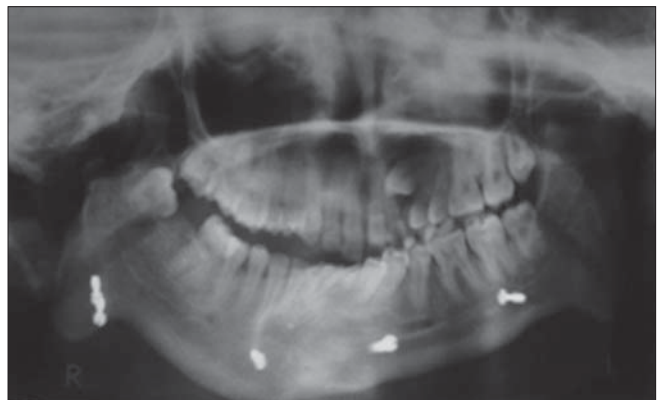
**Figure 4:** Preoperative photograph of case 1 (lateral view)



**Figure 5:** Postoperative photograph of case 1 (lateral view)



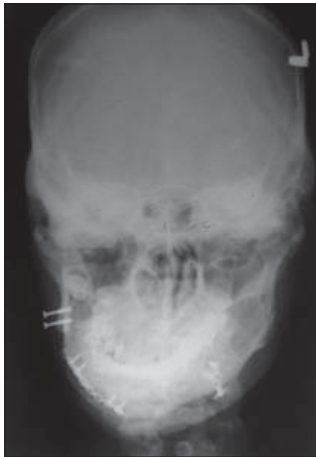**Figure 6:** Intraoperative photograph of case 1



**Figure 7:** Preoperative panoramic radiograph of case 1



Three patients had good postoperative mandibular symmetry, while other two had moderate postoperative mandibular symmetry. Contingency coefficient was found to be 0.000 at a *P* value of 1.000 which is not significant.



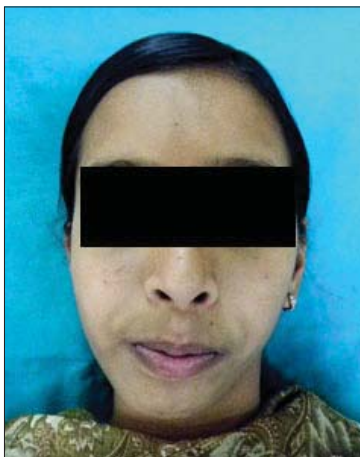**Figure 8:** Postoperative posteroanterior radiograph of case 1

## DISCUSSION

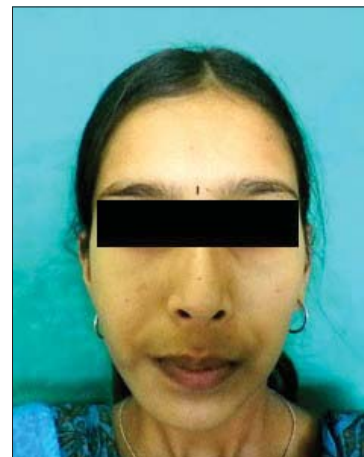In all the cases of our study, ankylosis of the temporomandibular joint following childhood trauma was the cause of the facial deformity. The mean age of male patients was 25 years and female patients were 18 years. This shows that female patients were keener for early facial dysmorphism correction.

The duration of surgery was increased in cases where the deformity was severe with reduced mandibular body height. In second case, lag screws on the mandibular body region which was placed along with the onlay graft for asymmetry correction one and a half years ago were removed, which increased duration of surgery.

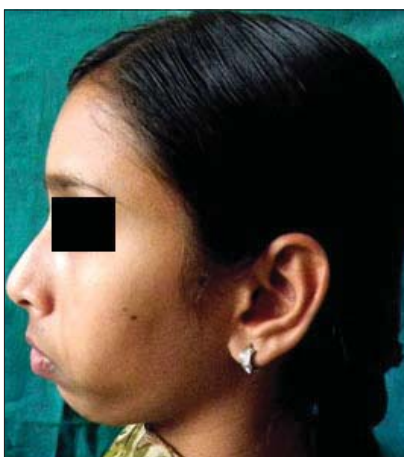Mandibular split was favorable in all the cases. Particular care was taken to ensure through and through osteotomy in the junction between the body and ramus of the mandible as the cut is changed from full thickness to an outer cortical osteotomy. The existence of cancellous bone between the two cortical plates allows a plane for mandibular split. This was based on the study conducted by Muto *et al.*,<sup>[8]</sup> who investigated the distribution of cancellous bone relative to the performance of medial osteotomy of a sagittal split



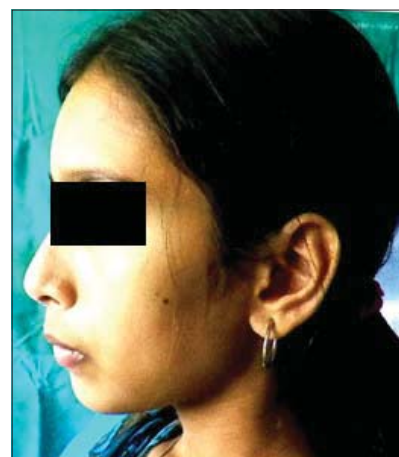**Figure 9:** Preoperative photograph of case 2 (frontal view)



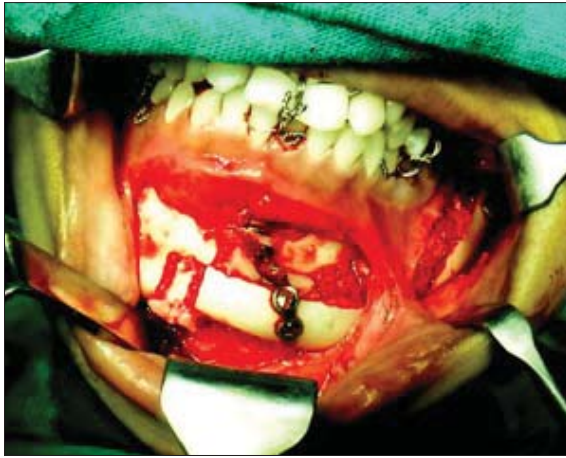**Figure 10:** Postoperative photograph of case 2 (frontal view)



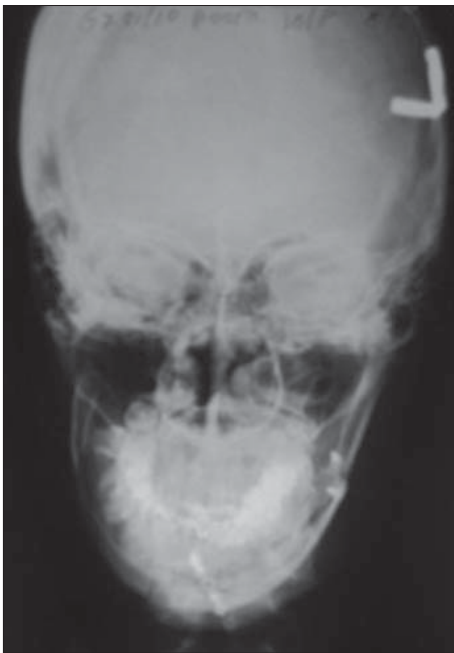
**Figure 11:** Preoperative photograph of case 2 (lateral view)



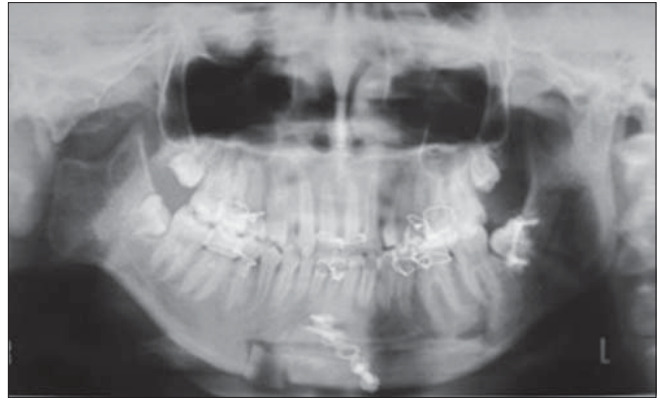**Figure 12:** Postoperative photograph of case 2 (lateral view)



**Figure 13:** Intraoperative photograph of case 2



**Figure 15:** Postoperative posteroanterior radiograph of case 2



**Figure 14:** Postoperative panoramic radiograph of case 2

ramus osteotomy using computed tomography.

Mental nerve paresthesia was noted in two patients (40%) in our study. The height of the body of mandible was short in those cases making the osteotomy difficult with increased risk of mental nerve damage. Injury to mental nerve was prevented by leaving a fringe of tissue in the premolar region, while making the incision. In second case the onlay graft placed during the previous surgery had resorbed resulting in extensive fibrosis. This created problem during our surgery in identifying and isolating the mental nerve, resulting in injury to the nerve and subsequent paresthesia. In the subsequent follow-up, mental nerve paresthesia reduced from the initial level.

Lindquist et al.<sup>[9]</sup> reported 28.5% of patients had altered sensation of lower lip and chin after combined genioplasty and bilateral sagittal split osteotomy. 10% of patients had mental nerve

paresthesia after genioplasty alone. Al-Bishri et al.<sup>[10]</sup> reported, 37% of operated sides, having sensory disturbance after undergoing sagittal osteotomy.

The reduction in mouth opening was due to postoperative pain which later improved.

Good asymmetry correction was noted in 60% of cases and the remaining 40% had moderate asymmetry correction. During the initial assessment, consideration was given to postoperative edema. Final assessment was, however, done on the sixth postoperative week.

We found some amount of deficiency in the mandibular body region, while the results were good at the symphysis and angle region. This was because the osteotomized segment can be mobilized only in the anterior and posterior region and does not correct the straightened contour of mandibular body. Salins et al.<sup>[6]</sup> also reported the same.

None of the cases developed postoperative complications.

Resorption of graft was noted in a case after a long period compromising the results. Follow-up period was less for accurate assessment.

Major limitation of this technique was not able to establish perfect symmetry. This was because it relocates the deformed mandibular segment but does not correct the straightened contour of the body of mandible. This will be evident as a flattening of the mandibular contour, which will require some additional augmentation. Another limitation is deficient mandibular body as in cases of hemifacial microsomia, where full-thickness osteotomy of the mandibular lower border would be impossible.

Modifications of this technique can be used in a number of ways including as a technique for bridging small osseous defects of the mandibular body.<sup>[6,11]</sup>

## CONCLUSION

The surgical correction of facial asymmetry is extremely challenging because the asymmetry may be centered at the hard

and/or soft tissue; any of a combination of dimensions; and it may involve the maxilla, mandible, and symphysis or any combination of the three. It is the effective treatment of the hard tissues that brings about the most dramatic change, as soft tissue defects are usually corrected after skeletal correction.<sup>[12]</sup>

We found orthomorphic surgery useful in correcting mild to moderate cases of mandibular deformity without any serious complications.

As the sample size is less in our study, further research is needed to evaluate the ultimate outcome of orthomorphic surgery in correcting facial deformities.

## REFERENCES

1. Severt TR, Proffit WR. The prevalence of facial asymmetry in the dentofacial deformities population at the University of North Carolina. *Int J Adult Orthod Orthognath Surg* 1997;12:171-6.
2. Wong TY, Fang JJ, Chung CH, Huang JS, Lee JW. Comparison of 2 methods of making surgical models for correction of facial asymmetry. *J Oral Maxillofac Surg* 2005;63:200-8.
3. Stringer D, Brown B. Correction of mandibular asymmetry using angled titanium mesh. *J Oral Maxillofac Surg* 2009;67:1619-27.
4. El-Sheikh MM, Medra AM. Management of unilateral temporomandibular ankylosis associated with facial asymmetry. *J Craniomaxillofac Surg* 1997;25:109-15.
5. Cohen MM. Perspectives on craniofacial asymmetry. III. Common and/or well-known causes of asymmetry. *Int J Oral Maxillofac Surg* 1995;24:127-33.
6. Salins PC, Venkatraman B, Kavarody M. Morphometric basis for orthomorphic correction of mandibular asymmetry. *J Oral Maxillofac Surg* 2008;66:1523-31.
7. Kent JN, Craig MA. Secondary autogenous and alloplastic reshaping procedures for facial asymmetry. *Atlas Oral Maxillofac Surg Clin North Am* 1996;4:83-105.
8. Muto T, Shigeo K, Yamamoto K, Kawakami J. Computed tomography morphology of the mandibular ramus in prognathism: Effect on the medial osteotomy of the sagittal split ramus osteotomy. *J Oral Maxillofac Surg* 2003;61:89-93.
9. Lindquist CC, Obeid G. Complications of genioplasty done alone or in combination with sagittal split-ramus osteotomy. *Oral Surg Oral Med Oral Pathol* 1988;66:13-6.
10. Al-Bishri A, Dahlberg G, Barghash Z, Rosenquist J, Sunzel B. Incidence of neurosensory disturbance after sagittal split osteotomy alone or combined with genioplasty. *Br J Oral Maxillofac Surg* 2004;42:105-11.
11. Salins PC, Rao CB. Immediate reconstruction of the mandible after resection by sliding osteotomy: A new technique. *Br J Oral Maxillofac Surg* 1997;35:116-8.
12. Reyneke JP, Tsakiris P, Kienle F. A simple classification for surgical treatment planning of maxillomandibular asymmetry. *Br J Oral Maxillofac Surg* 1997;35:349-51.

**Cite this article as:** Degala S, Shetty S, Morgan G. A study on orthomorphic correction of mandibular dysmorphology. *Ann Maxillofac Surg* 2011;1:120-5.

**Source of Support:** Nil, **Conflict of Interest:** None declared.

## New features on the journal's website

### Optimized content for mobile and hand-held devices

HTML pages have been optimized of mobile and other hand-held devices (such as iPad, Kindle, iPod) for faster browsing speed.

Click on **[Mobile Full text]** from Table of Contents page.

This is simple HTML version for faster download on mobiles (if viewed on desktop, it will be automatically redirected to full HTML version)

### E-Pub for hand-held devices

EPUB is an open e-book standard recommended by The International Digital Publishing Forum which is designed for reflowable content i.e. the text display can be optimized for a particular display device.


Click on **[EPub]** from Table of Contents page.

There are various e-Pub readers such as for Windows: Digital Editions, OS X: Calibre/Bookworm, iPhone/iPod Touch/iPad: Stanza, and Linux: Calibre/Bookworm.

### E-Book for desktop

One can also see the entire issue as printed here in a 'flip book' version on desktops.

Links are available from Current Issue as well as Archives pages.

Click on  View as eBook