





Left Ventricular Assist Device Implantation with Concomitant Replacement of the Ascending Aorta

Sebastian Johannes Bauer¹  Yukiharu Sugimura¹ Moritz Benjamin Immohr¹  Arash Mehdiani¹
Artur Lichtenberg¹ Payam Akhyari¹

¹ Department of Cardiac Surgery, Heinrich Heine University Düsseldorf, Düsseldorf, Nordrhein-Westfalen, Germany

Thorac Cardiovasc Surg Rep 2024;13:e37–e39.

Address for correspondence Sebastian Johannes Bauer, Department of Cardiac Surgery, Heinrich Heine University Düsseldorf, 40225 Düsseldorf, Nordrhein-Westfalen, Germany (e-mail: sebastian.Bauer@med.uni-duesseldorf.de; sebauer@uk-essen.de).

Abstract

Dilated cardiomyopathy (DCM) is one of the main causes for end-stage heart failure. Until the transplantation, left ventricular assist devices (LVAD) have become an established treatment. We report a case of a 66-year-old patient with ischemic and DCM and suspected aortic ulcer formation. LVAD was implanted in the same session with a supracoronary aortic replacement. Bilateral cannulation of the subclavian arteries omitted the need of circulatory arrest and proximal aortic cross-clamping. Pneumonia-associated decarboxylation failure prolonged the postoperative intensive care period. The patient was finally discharged home on the 115th postoperative day.

Keywords

- ▶ aortic disease
- ▶ aorta/aortic
- ▶ cardiopulmonary bypass
- ▶ left ventricular assist device

Introduction

Left ventricular assist devices (LVAD) therapy has become a major cornerstone in the treatment of end-stage heart failure.¹ Simultaneous aortic valve surgery has been described. However, ascending aortic interventions have rarely been described, which may be related to the elevated risk of bleeding and neurological complications.² Considering the overall operative risk on one hand and the expected survival for destination therapy patients on the other, individual planning for operative strategy represents a challenge in the respective setting.

Case

A 66-year-old male patient with acutely decompensated chronic heart failure due to ischemic and dilated cardiomyopathy was referred to our hospital with an Inter-

agency Registry for Mechanically Assisted Circulatory Support profile of 3, a left ventricular ejection fraction of 24%, a cardiac index of 1.8 L/m²/min under intermittent levosimendan therapy and congestive pneumonia. The medical history further included severe atheromatous degeneration of the aorta with suspected aortic ulcer formation at the level of the ascending aorta (▶**Fig. 1**), a single vessel coronary artery disease, a thalassemia minor and protein S deficiency, and chronic hepatitis C infection. Interdisciplinary evaluation recommended LVAD implantation concomitant with supracoronary replacement of the ascending aorta. Considering the atheromatous lesions reaching from the ascending aorta up to the proximal aortic arch, and further considering the compromised overall status of the patient, a strategy for replacement of the ascending aorta without clamping the proximal arch as well as omitting circulatory arrest was attempted (▶**Supplementary Video 1**). Cardiopulmonary bypass (CPB) was installed via percutaneous venous femoral

received
October 12, 2023
accepted after revision
September 24, 2024
accepted manuscript online
November 5, 2024

DOI <https://doi.org/10.1055/a-2461-3284>.
ISSN 2194-7635.

© 2024. The Author(s).

This is an open access article published by Thieme under the terms of the Creative Commons Attribution-NonDerivative-NonCommercial-License, permitting copying and reproduction so long as the original work is given appropriate credit. Contents may not be used for commercial purposes, or adapted, remixed, transformed or built upon. (<https://creativecommons.org/licenses/by-nc-nd/4.0/>)

Georg Thieme Verlag KG, Rüdigerstraße 14, 70469 Stuttgart, Germany

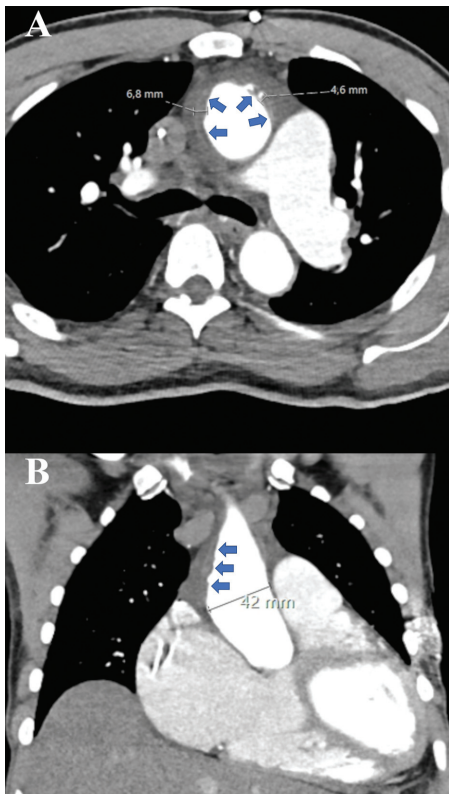


Fig. 1 Preoperative computed tomography imaging: Transverse (A) and frontal (B) plane demonstrate the sizes of penetrating aortic ulcers (A: 6.8 mm, 4.6 mm) and soft plaques (B: arrows).

cannulation and bilateral cannulation of the subclavian arteries. A femoral arterial access was avoided due to the presence of vulnerable plaques in the descending and abdominal aorta. LVAD implantation via sternotomy was performed with pericardial enlargement in Furoshiki technique.³ Next, under reduced perfusion the common offspring of the innominate artery and the left carotid artery was clamped just above the aortic arch. A second clamp was applied to the aortic arch proximal to the junction of the left subclavian artery (►Fig. 2A). CPB perfusion via right subclavian artery was performed at 8 to 10 mL/kg bodyweight and under pressure monitoring derived from a side branch of the perfusion cannula targeting 60 to 70 mmHg. Cerebral oxygenation was monitored continuously. Perfusion of the left subclavian artery was adjusted to achieve a systemic artery pressure of 70 mmHg, measured via both femoral arteries. This way, resection of the ascending aorta with open anastomosis in the region of the proximal aortic arch was feasible without circulatory arrest. However, surgery was done under mild hypothermia at 31.5°C. Aortic inspection revealed soft plaques and ulceration of the lesser and greater aortic curvature (►Fig. 2B). Calafiore cardioplegia was given twice in the following course. Distal anastomotic line was performed using the French cuff technique (►Fig. 2C). Aortic clamp was relocated to the level of ascending aorta under reduced CPB perfusion and after a meticulous de-airing maneuver. Surgery was continued in standard fashion by performing the proximal anastomosis line at the level of the

sinotubular junction with consecutive LVAD implantation (Abbott HeartMate 3). The final anastomosis of the LVAD outflow graft to the aortic prosthesis was performed under partial clamping (►Fig. 2D). Total operative time was 550 minutes, including 56 minutes of reperfusion. CPB time was 151 minutes and cross-clamping time was 49 minutes. Despite extensive intraoperative efforts of coagulation, rethoracotomy became necessary on the same day, revealing a diffuse bleeding tendency. The further postoperative course was prolonged due to pneumonia-associated decarboxylation failure, necessitating venovenous extracorporeal membrane oxygenation from 6th to 45th postoperative day. However, kidney function was not affected. The patient remained without hemodialysis throughout the entire stay. He recovered continuously and was transferred to the intermediate care unit and the normal ward on 66th and 93rd postoperative day, respectively. He was finally discharged home on 115th postoperative day. At 18 months postoperatively, the patient is back to daily life and returns to regular on-site follow-ups without neurological sequelae, not even a wheeled walker is necessary.

Supplementary Video 1

The video sequences illustrate the performed surgical techniques in a step-by-step manner with additional subtitles. Online content including video sequences viewable at: <https://www.thieme-connect.com/products/ejournals/html/10.1055/a-2461-3284>.

Conclusion

LVAD implantation with concomitant replacement of the proximal aortic arch without clamping of the proximal arch is a feasible surgical approach when elevated risk of cerebral embolization or coagulopathy is expected. As patients with LVAD are already at high risk of bleeding events,⁴ the need for circulatory arrest with hypothermia can also be omitted with the shown surgical strategy. Further risk reduction can be achieved with appropriate preparation and precautions. Preoperative computed tomography (CT) analysis (i.e., 1-mm multislice CT scan)⁵ and intraoperative epi-aortic point-of-care ultrasound have been shown as effective in reducing embolic stroke. Bilateral subclavian cannulation and application of two arterial clamps (one on the common offspring of the innominate artery and the left common carotid artery and second on the distal aortic arch proximal to the left subclavian artery) are essential factors contributing to the safety of this method. If the patient has had no common offspring of the innominate and left common carotid artery, another clamp would have been placed proximal to the left common carotid artery, enabling the same approach.

This strategy may be a valid option in complex scenarios including heart failure and advanced aortic pathology.

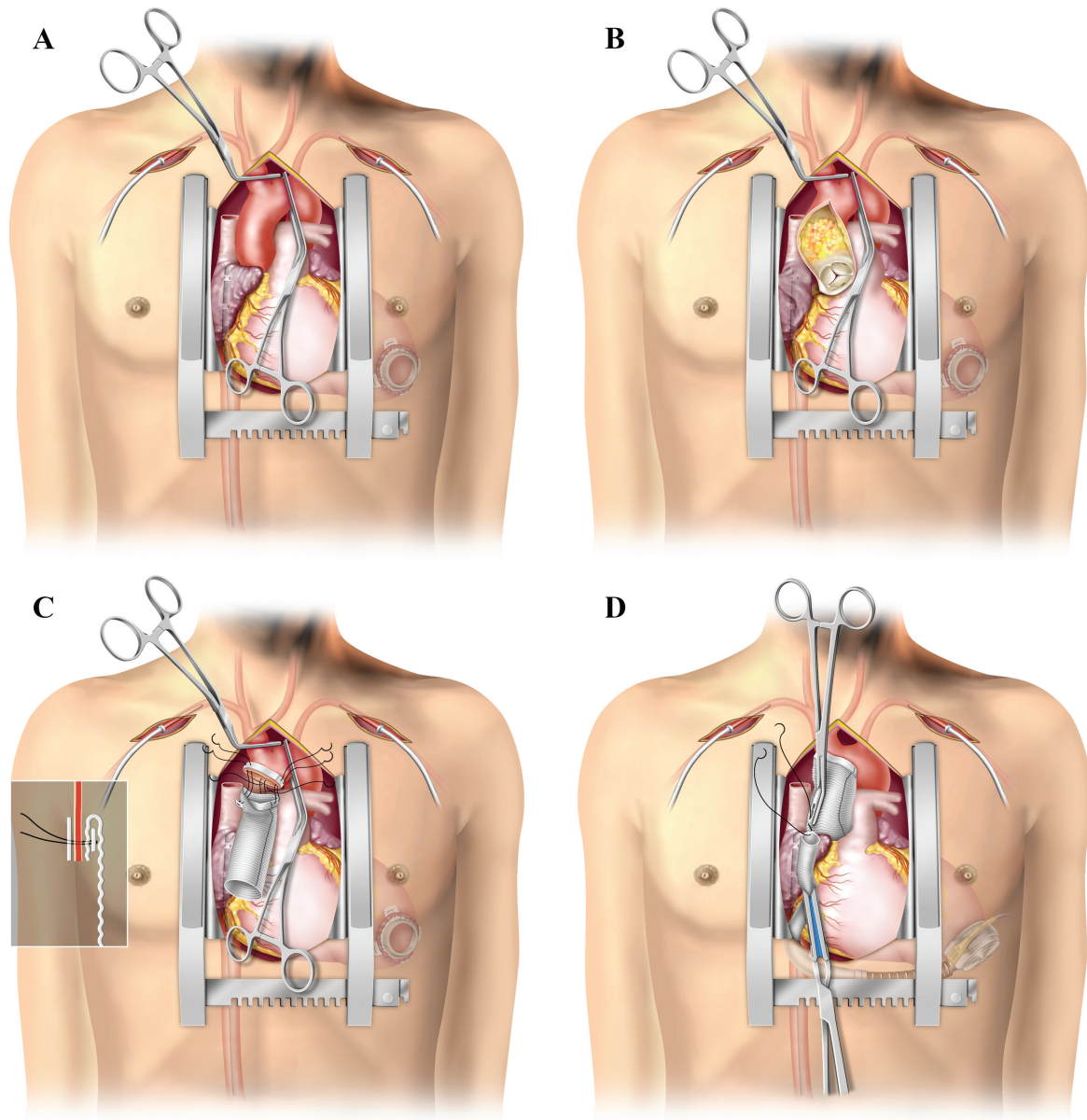


Fig. 2 Surgical technique: (A) Setup for extracorporeal circulation with percutaneous venous femoral cannulation, bilateral subclavian arterial cannulation, and clamping of the brachiocephalic trunk and aortic arch in zone 1. (B) Situs after longitudinal incision of the ascending aorta. Soft and hard plaque formation can be seen. (C) Distal anastomosis using the French cuff technique. (D) Implantation of left ventricular assist device (LVAD). Anastomosis of outflow-graft under partial prosthesis clamping.

Patients' Consent

The patient behind the described case has given written consent on publication of the contents of this report.

Conflict of Interest

None declared.

References

- 1 Kormos RL, Cowger J, Pagani FD, et al. The Society of Thoracic Surgeons INTERMACS database annual report: evolving indications, outcomes, and scientific partnerships. *J Heart Lung Transplant* 2019;38(02):114–126
- 2 Gode S, Erkanlı K, Başgoze S, Turen S, Kahraman MZ. Left ventricular assist device implantation combined with Bentall procedure. *Braz J Cardiovasc Surg* 2019;34(02):233–236
- 3 Sugimura Y, Katahira S, Aubin H, Boeken U, Lichtenberg A, Akhyari P. Less invasive left ventricular assist device implantation with the Furoshiki technique. *Ann Thorac Surg* 2021;111(06):e451–e453
- 4 Varshney AS, DeFilippis EM, Cowger JA, Netuka I, Pinney SP, Givertz MM. Trends and outcomes of left ventricular assist device therapy: JACC Focus Seminar. *J Am Coll Cardiol* 2022;79(11):1092–1107
- 5 den Harder AM, de Heer LM, Meijer RC, et al. Effect of computed tomography before cardiac surgery on surgical strategy, mortality and stroke. *Eur J Radiol* 2016;85(04):744–750