

Surgical management of spontaneous in-the-bag intraocular lens and capsular tension ring complex dislocation

Uzeyir Gunenc, Nilufer Kocak, A. Taylan Ozturk¹, Gul Arikan

We describe a technique to manage late spontaneous intraocular lens (IOL) and capsular tension ring (CTR) dislocation within the intact capsular bag. The subluxated IOL and CTR complex can be positioned in a closed chamber and fixed to the pars plana at both 3 and 9 o'clock quadrants with the presented ab externo direct scleral suturation technique which provides an easy, safe and effective surgical option for such cases.

Key words: Ab externo surgical technique, capsular tension ring displacement, intact capsular bag, intraocular lens luxation

Access this article online

Website:

www.ijo.in

DOI:

10.4103/0301-4738.116451

Quick Response Code:



In-the-bag intraocular lens (IOL) subluxation is a rare but serious complication even after an uneventful cataract surgery. Bag dislocation may occur as a result of progressive zonular dehiscence many years after the surgery.^[1-3] Capsular tension ring (CTR) implantation provides a reasonable preventive measure from the complication of in-the-bag IOL dislocation by supporting the zonules after cataract surgery, however, late spontaneous IOL and CTR dislocation within the intact capsular bag in patients with pseudoexfoliation is reported in the literature.^[1-5] We describe a simplified and safe surgical technique that uses transscleral suture fixation in a closed chamber for the patients with late spontaneous IOL and CTR dislocation within the intact capsular bag.

Surgical Technique

We had two patients whose subluxated IOLs and were managed with trans-scleral fixation. Six years after an uneventful phacoemulsification combined with viscocanalostomy surgery, first patient presented to us because of the blurred vision of her left eye. Inferiorly subluxation of the IOL along with its capsule like a setting sun was detected on slit-lamp biomicroscopic examination.

Under topical anesthesia, two conjunctival peritomies were created from 2-4 o'clock and 8-10 o'clock at both temporal and nasal limbus. A clear corneal incision was performed at 12 o'clock. In order to protect the corneal endothelium as well as expand the posterior chamber, the anterior chamber

and the retropupillary space were filled with an ophthalmic viscosurgical device (OVD). Four additional clear corneal side port incisions were performed for the placement of iris hooks to dilate the pupil. A double-armed 10-0 polypropylene suture on straight needles (Prolene®, Ethicon Inc) was cut in half. One straight needle was inserted into the globe from pars plana at 9 o'clock quadrant and passed through the ciliary sulcus and the intact capsular bag around the edge of CTR posterior-anteriorly [Fig. 1]. Needle was slightly directed towards the main corneal incision after advanced beneath the iris and visualized behind the pupil. Afterwards, same needle was reentered into the anterior chamber and advanced beneath the iris after passing inside the pupil. Needle was directed towards the ciliary sulcus as well as pars plana at 9 o'clock quadrant after passing the intact capsular bag towards the edge of CTR anterior-posteriorly [Fig. 2]. Subluxated IOL and CTR complex was retracted and the polypropylene suture was tied on the sclera after needle was withdrawn through the pars plana. The other arm of the 10-0 polypropylene suture that was inserted into the globe at 3 o'clock quadrant, was used for the scleral fixation of the opposite edge of the IOL and CTR complex within the intact capsular bag [Fig. 3]. After the polypropylene sutures tied off, we buried the knots into the sclera. The iris hooks were removed and OVD was aspirated through corneal paracentesis site using an irrigation-aspiration unit. Vitrectomy was not performed as there was no sign of either vitreal traction in the anterior chamber, or vitreous disturbance inside the vitreal cavity. The conjunctiva was then closed with 8-0 polyglactin 910 (Vicryl®, Ethicon Inc) sutures [Fig. 4]. At the third year of follow-up, best corrected visual acuity (BCVA) was found as 20/20, and the position of IOL and CTR complex has still been centralized in the affected eye [Fig. 5].

The second patient had a left eye with pseudophacodonesis and a pressure of 37 mmHg despite using three anti-glaucomatous medications. The IOL and its capsule were subluxated inferiorly. We first performed a trabeculectomy

Department of Ophthalmology, Dokuz Eylul University School of Medicine, ¹Department of Ophthalmology, Dr. Behçet Uz Children's Hospital, Izmir, Turkey

Correspondence to: Dr. A. Taylan Ozturk, Department of Ophthalmology, Dr. Behçet Uz Children's Hospital, Pamukkale-2, 2040 Sokak, No: 52/48, Mavisehir, Karsiyaka, Izmir, Turkey. E-mail: ataylan6@yahoo.com

Manuscript received: 07.05.12; Revision accepted: 26.07.13

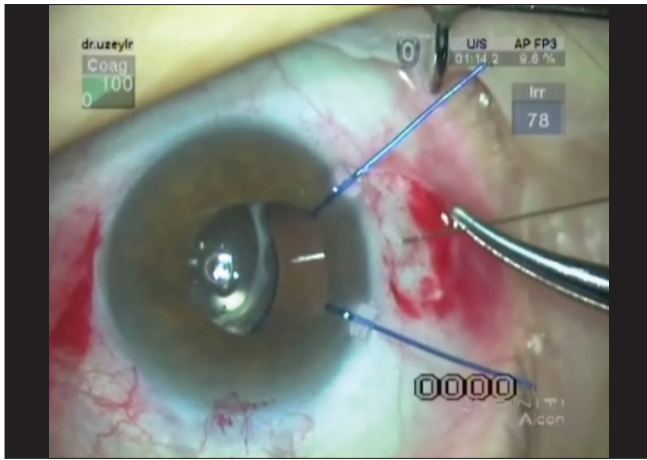


Figure 1: The straight needle of a double-armed 10-0 polypropylene suture was inserted from pars plana at 9 o'clock quadrant; passed through the ciliary sulcus and the intact capsular bag around the edge of capsular tension ring posterior-anteriorly after the placement of iris hooks

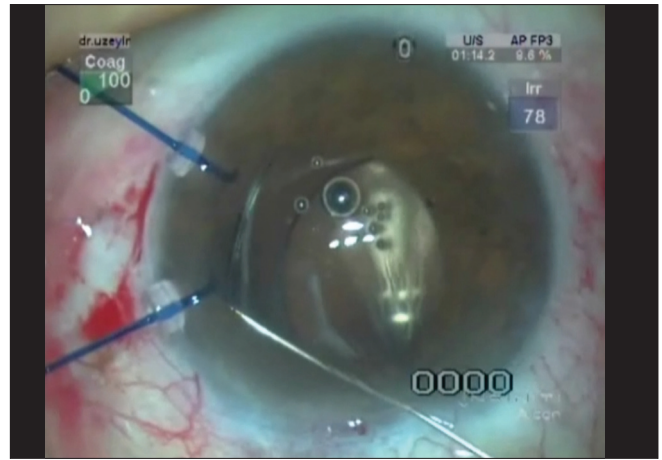


Figure 2: Same needle was directed towards the ciliary sulcus as well as pars plana at 9 o'clock quadrant after passing the intact capsular bag towards the edge of CTR anterior-posteriorly

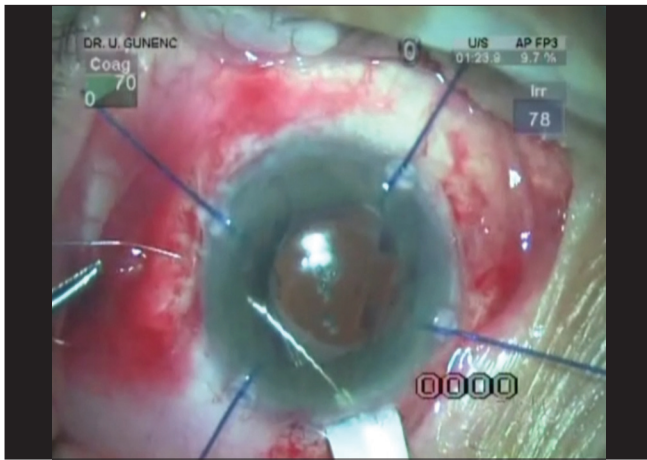


Figure 3: The other arm of the 10-0 polypropylene suture that was inserted into the globe at 3 o'clock quadrant, was used for the scleral fixation of the opposite edge of the intraocular lens and CTR complex within the intact capsular bag

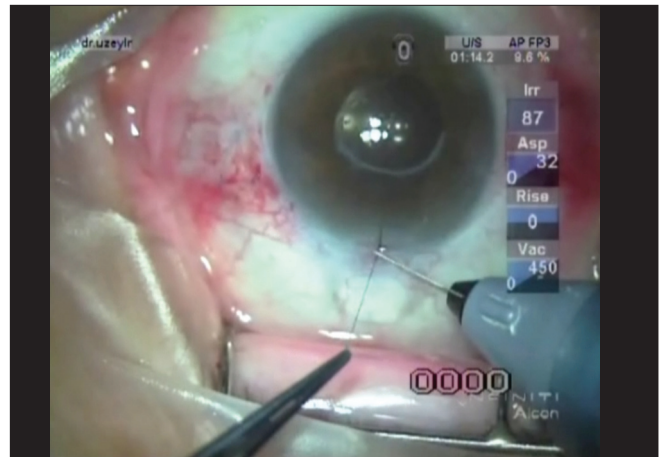


Figure 4: Surgical sites were sutured after the aspiration of viscosurgical device

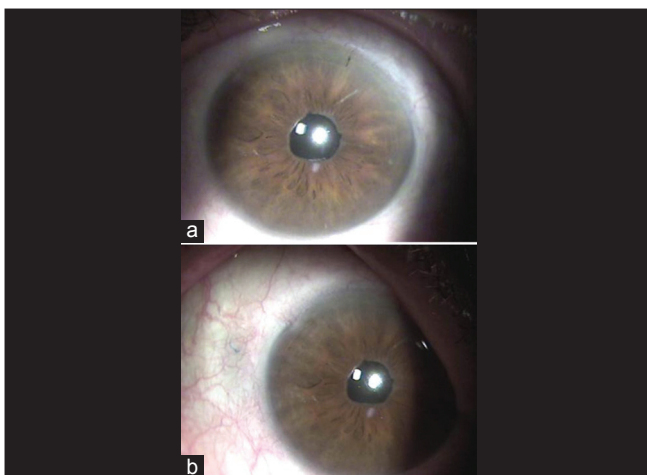


Figure 5: (a) Central position of IOL on slit-lamp biomicroscopy. (b) 10-0 polypropylene suture hardly seen under the nasal bulbar conjunctiva at the third year of follow-up

and trans-scleral fixation of IOL and CTR complex in the same operation as mentioned above. Postoperative BCVA was improved from 20/1600 to 20/30, and slit-lamp biomicroscopy remained no signs of IOL dislocation at the 32nd month of follow-up.

Discussion

Insufficient capsule and zonule support is one of the most common etiologic factor for dislocation of an IOL.^[1-3] Trauma and congenital disease such as Marfan syndrome, Ehlers-Danlos syndrome, homocystinuria, hyperlysinemia, and Weill-Marchesani syndrome are some of the systemic causes of this phenomenon while, it can be related with ocular problems as pseudoexfoliation, high myopia, chronic uveitis and history of vitrectomy.^[2-4] Therefore, CTR implantation during cataract surgery has been recommended in such cases.^[1-5] However, herein we describe 2 glaucoma cases with spontaneous dislocation of IOL and CTR within the intact capsular bag.

Various surgical interventions in the management of subluxated in-the-bag IOLs have been introduced such as repositioning the dislocated IOL and fixating it to the sclera, or

externalizing and exchanging the IOL.^[1-8] Direct scleral fixation of the subluxated IOL and CTR complex in a closed chamber by placing the sutures through the intact capsular bag around the edge of CTR was performed with the presented surgical technique in our cases.

The main advantages of this surgical technique over other recently published procedures are being a simple, effective, and safe management option which involves minimal handling and reduces the intraocular complication risk without disturbing the anterior chamber stability, despite providing early visual rehabilitation. Furthermore, performing small corneal incision and lack of the need for scleral flaps lower the risk of endophthalmitis. Postsurgical astigmatism and corneal endothelial injury are also reduced due to the small clear corneal incision.^[9,10] In the present procedure, scleral knots are buried into the sclera and tight closure of the conjunctiva is performed to avoid knot exposure and suture erosion. Scleral sutures are also square knotted more than three times for the prevention of suture loosening.

In cases of a dislocated IOL and CTR within the intact capsular bag, the surgeon must see both the haptic ends and the capsule well enough to place the scleral retraction sutures which is almost impossible with a miotic pupil. Implanting the iris hooks at the quadrants of planned scleral fixation helps to visualize the edge of CTR.

In conclusion, our surgical technique provides a simple, effective and safe approach for repositioning and scleral fixating of a dislocated IOL and CTR complex within the intact capsular bag. Reduced surgical time with minimal handling requirement, as well as reduction of the intraocular complication risk owing to the lack of disruption in the anterior chamber stability are the major advantages of this procedure.

References

1. Gross JG, Kokame GT, Weinberg DV. Dislocated in-the-bag intraocular lens study group. In-the-bag intraocular lens dislocation. *Am J Ophthalmol* 2004;137:630-5.
2. Gimbel HV, Condon GP, Kohnen T, Olson RJ, Halkiadakis I. Late in-the-bag intraocular lens dislocation: Incidence, prevention, and management. *J Cataract Refract Surg* 2005;31:2193-204.
3. Monteiro TP, Estrela Silva SE, Domingues M, Fernandes AV, Falcao-Reis F. Complete spontaneous posterior luxation of capsular bag-intraocular lens-capsular tension ring complex. *J Cataract Refract Surg* 2009;35:2154-6.
4. Por YM, Lavin MJ. Techniques of intraocular lens suspension in the absence of capsular/zonular support. *Surv Ophthalmol* 2005;50:429-62.
5. Blecher MH, Kirk MR. Surgical strategies for the management of zonular compromise. *Curr Opin Ophthalmol* 2008;19:31-5.
6. Kim SS, Smiddy WE, Feuer W, Shi W. Management of dislocated intraocular lenses. *Ophthalmology* 2008;115:1699-704.
7. Ma KT, Kang SY, Shin JY, Kim NR, Seong GJ, Kim CY. Modified Siepser sliding knot technique for scleral fixation of subluxated posterior chamber intraocular lens. *J Cataract Refract Surg* 2010;36:6-8.
8. Rahim MF, Malyugin B. Two-string technique to manage dislocated posterior chamber plate-haptic intraocular lens. *J Cataract Refract Surg* 2006;32:722-6.
9. Oh HS, Chu YK, Kwon OW. Surgical technique for suture fixation of a single-piece hydrophilic acrylic intraocular lens in the absence of capsule support. *J Cataract Refract Surg* 2007;33:962-5.
10. Chung EJ, Kim CY, Koh HJ. Ab externo direct suture technique for dislocated intraocular lens. *J Cataract Refract Surg* 2007;33:955-8.

Cite this article as: Gunenc U, Kocak N, Ozturk AT, Arkan G. Surgical management of spontaneous in-the-bag intraocular lens and capsular tension ring complex dislocation. *Indian J Ophthalmol* 2014;62:876-8.

Source of Support: Nil. **Conflict of Interest:** None declared.