

## Is thoracic esophagostomy an option in esophageal perforation in pediatric patients?

*Pediatric hastalarda özofagus perforasyonunda torasik özofagostomi bir seçenek midir?*

Atilla Eroğlu<sup>1</sup>, Ali Bilal Ulaş<sup>2</sup>, Yener Aydın<sup>3</sup>

Department of Thoracic Surgery, Atatürk University Faculty of Medicine, Erzurum, Türkiye

### ABSTRACT

Esophagostomy and subsequent esophagectomy are extremely rare operations in the management of benign esophageal perforations in children. In this report, we present a 20-month-old female in whom we performed thoracic esophagostomy and subsequent intrathoracic esophagogastric anastomosis due to esophageal perforation caused by a chronic foreign body. The patient was discharged on the 10<sup>th</sup> postoperative day, and no complications were observed in the patient, who was followed for four years. The thoracic esophagostomy procedure helps preserve the esophageal length and easy execution of the esophagogastric anastomosis in the thorax. We believe it can be a safe and useful technique in carefully selected cases.

**Keywords:** Esophageal perforation, foreign body, thoracic esophagostomy.

Esophageal foreign body ingestion (EFBI) is a common health problem in the pediatric population.<sup>[1]</sup> Although early diagnosis and treatment are performed in most cases, some may be overlooked, and consequently, severe complications can occur. The fatal complications are esophageal perforation and subsequent mediastinitis. Esophagoscopy is generally the intervention of choice to remove the foreign body, though surgery may be necessary in some cases.<sup>[1-4]</sup> Herein, we describe a pediatric patient in whom a thoracic esophagostomy was performed due to a longstanding foreign body in the esophagus.

### ÖZ

Özofagostomi ve sonrasında özofajektomi, çocuklarda iyi huylu özofagus perforasyonlarının tedavisindeki son derece nadir ameliyatlardır. Bu makalede kronik yabancı cisme bağlı özofagus perforasyonu nedeniyle torasik özofagostomi ve ardından intratorasik özofagogastrik anastomoz yapılan 20 aylık bir kız hasta sunuldu. Hasta ameliyat sonrası 10. günde taburcu edildi ve dört yıldır takibi sürdürülen hastada komplikasyon izlenmedi. Torasik özofagostomi işlemi, özofagus uzunluğunun korunmasına ve özofagogastrik anastomozun toraks içinde kolaylıkla yapılmasına yardımcı olur. Dikkatli seçilmiş olgularda bunun güvenli ve faydalı bir teknik olabileceğine inanıyoruz.

**Anahtar sözcükler:** Özofagus perforasyonu, yabancı cisim, torasik özofagostomi.

### CASE REPORT

A 20-month-old female was admitted to the pediatric ward due to difficulty in feeding and vomiting immediately after each feeding. Detailed neurological and gastroenterological investigations were done other than esophagoscopy, and no exact cause was identified. Meanwhile, the child's grandmother revealed that the patient had ingested a piece of boneless meat a month before admission. Subsequently, a thoracic computed tomography (CT) was performed after consultation in our clinic. The CT scan revealed left pleural effusion, left lower lobe

Received: July 29, 2020 Accepted: September 15, 2020 Published online: April 27, 2022

**Correspondence:** Ali Bilal Ulaş, MD, Atatürk Üniversitesi Tıp Fakültesi Göğüs Cerrahisi Anabilim Dalı, 25240 Erzurum, Türkiye.

Tel: +90 542 - 225 87 39 e-mail: dralibilalulas@gmail.com

#### Cite this article as:

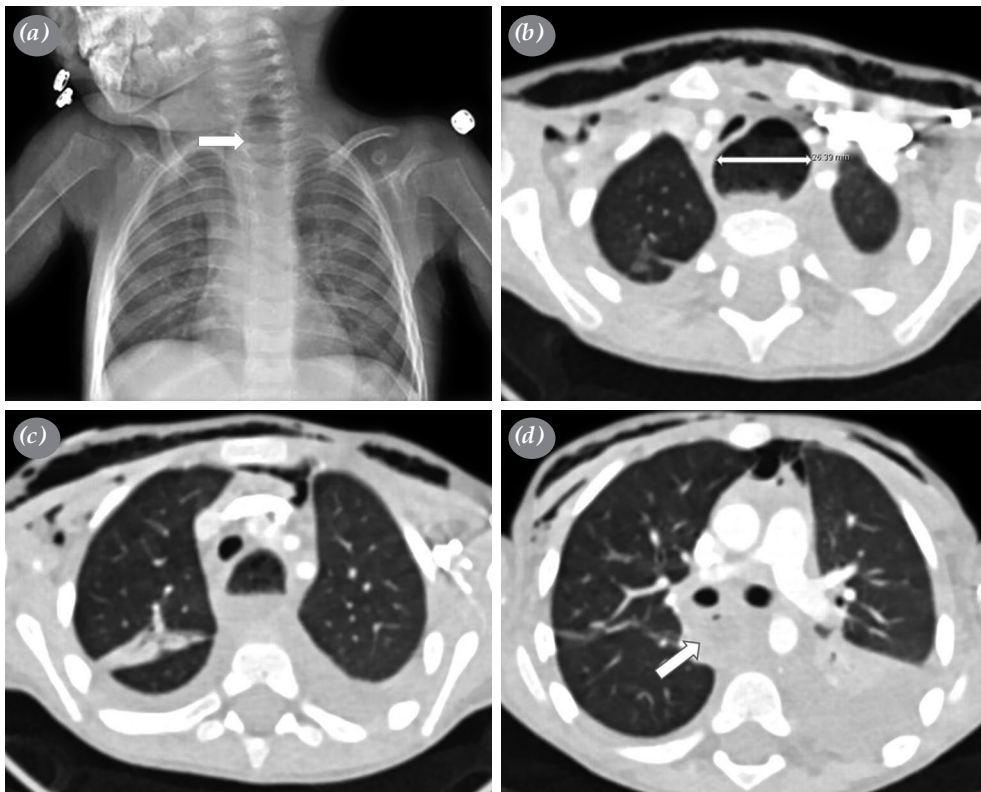
Eroğlu A, Ulaş AB, Aydın Y. Is thoracic esophagostomy an option in esophageal perforation in pediatric patients?. Turk Gogus Kalp Dama 2022;30(2):294-298

©2022 All right reserved by the Turkish Society of Cardiovascular Surgery.

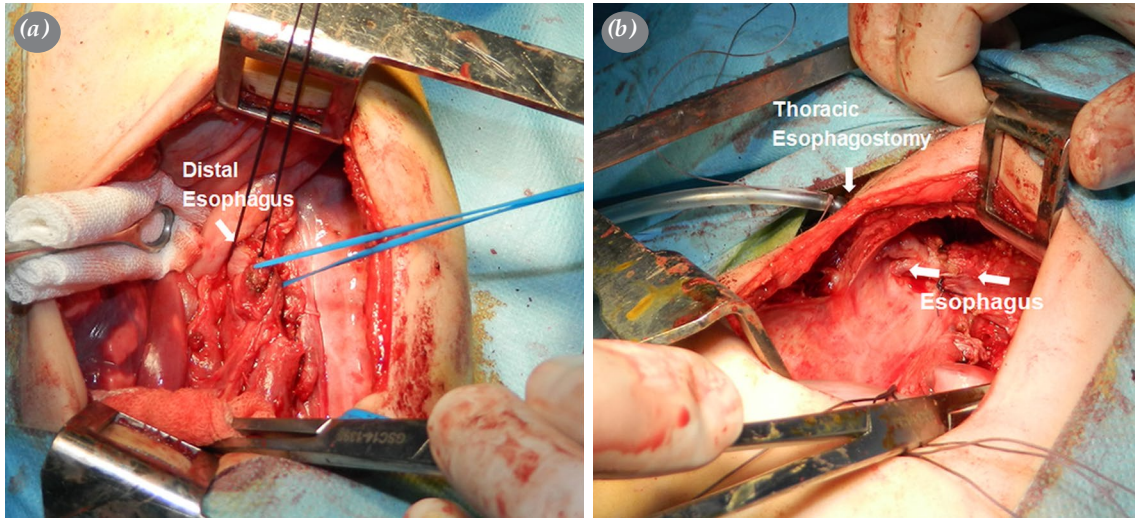
This is an open access article under the terms of the Creative Commons Attribution-NonCommercial License, which permits use, distribution and reproduction in any medium, provided the original work is properly cited and is not used for commercial purposes (<http://creativecommons.org/licenses/by-nc/4.0/>).

atelectasis, pneumomediastinum, and subcutaneous emphysema, in addition to significant dilation of the esophagus (Figure 1). Rigid esophagoscopy was performed to remove the foreign body (the piece of boneless meat); however, a nasogastric tube could not be placed into the stomach following the procedure. Therefore, a left thoracotomy was performed. When the mediastinal pleura was opened, the esophageal wall could not be seen as the distal part of the esophagus was overwhelmingly necrotic and the tip of the nasogastric tube was in the mediastinum. The mediastinal loculations were drained, and the mediastinum was irrigated with diluted povidone-iodine on the left side; however, the right upper mediastinal loculations could not be reached. Afterward, a right thoracotomy was performed after two chest tubes were placed into the left hemithorax and the existing thoracotomy was closed. The mediastinal pleura was opened to the superior thoracic aperture, and purulent collections were aspirated. The esophagus was dissected, and the distal part was resected due to it being necrotic. The gastroesophageal junction was closed with silk sutures to prevent the passage of stomach contents into the

mediastinum. An approximately 1-cm incision was made at the fifth intercostal space at the right posterior chest wall to create a stoma, and the entire proximal end of the esophagus was drawn and sutured here. A 16 French chest tube was placed into the esophagus from the outside (Figure 2). Two chest tubes were placed into the thoracic cavity, and the thoracotomy was closed as usual. After the thoracic interventions above, gastrostomy was performed during the same session. During the postoperative period, daily intrapleural saline irrigations were done through the chest tubes, and enteral feeding was started from the gastrostomy tube. One week after surgery, the patient was intubated for 16 days due to pneumonia. The patient was treated with antibiotics following tracheal aspirate culture sensitivities. By the time the patient was extubated, their general condition and blood parameters had significantly improved, and the patient was discharged 35 days after the initial operation. Following discharge, the patient continued to be enterally fed via a gastrostomy tube. The patient also had regular clinical and radiological follow-ups. The patient was rehospitalized 113 days after discharge for a planned



**Figure 1.** (a) Esophageal enlargement (arrows) on a chest radiograph and (b) computed tomography section. (b-d) The computed tomography sections also demonstrate mediastinal emphysema, subcutaneous emphysema, pleural effusion, and (d) wall thickening in the distal esophagus due to fibrosis.



**Figure 2.** Intraoperative photographs showing (a) the distal esophagus and (b) the thoracic esophagostomy procedure.

esophagogastronomy. The general condition of the patient was good, and the patient had gained weight. The operation continued as planned. First, a laparotomy was performed. The stomach was skeletonized, and the gastrostomy site was closed. Second, a right thoracotomy was performed, and adhesions between the esophagus and the upper lobe were freed. A partial esophagectomy was performed again due to the long end of the free esophagus. The stomach was pulled to the thorax, and an esophagogastric anastomosis was performed manually (Figure 3). Gastric tubing was not done before the anastomosis. The patient was instructed to drink methylene blue on the sixth

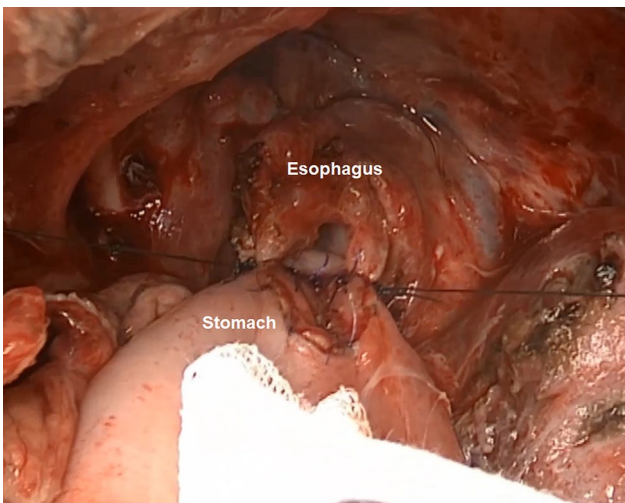
postoperative day, and no anastomotic leakage was observed. Consequently, oral feeding was initiated, and the chest tube was removed. The patient was discharged on the 10<sup>th</sup> postoperative day and is still under follow-up with no complications in four years.

## DISCUSSION

Although treatment options vary depending on the time interval after the foreign body ingestion, localization, and nature, the main treatment method in the management of EFBI is rigid or flexible esophagoscopy.<sup>[1]</sup> Nevertheless, there is no consensus on which of these methods is superior. Other therapeutic options include observation, pushing the foreign body into the stomach, removal with a McGill clamp or Fogarty catheter, intravenous glucagon implementation, and esophagostomy.<sup>[2]</sup>

The highest incidence rates of EFBI occur among children between six months and six years of age, and coins constitute the majority of ingested foreign bodies.<sup>[3]</sup> In cases where adults have ingested sharp and pointed objects, foreign body-related esophageal perforations usually occur while removing such sharp and pointed foreign objects. However, soft and smooth foreign bodies that are not removed during the acute period may also cause perforation. Ordinarily, hard and sharp-pointed foreign body ingestions are diagnosed early since they can produce severe symptoms after ingestion.

Occasionally, rigid esophagoscopy may be insufficient in the diagnosis of a perforation in the acute period, requiring flexible esophagoscopy. In the



**Figure 3.** Intraoperative photograph demonstrating the posterior wall of the intrathoracic esophagogastric anastomosis that was manually performed.

latter method, compressed air is delivered to the lumen of the esophagus, and the mucosa can be evaluated in more detail. In our case, the ingested foreign body was a piece of boneless meat, and it was removed uneventfully. We performed rigid esophagoscopy again after removing the foreign body; however, we could neither pass the scope nor a nasogastric catheter distally into the esophagus. Although the CT scan showed pleural effusion and subcutaneous emphysema, a definitive diagnosis of perforation was made through surgery.

Treatment options for esophageal perforation cases vary according to the size and localization of the foreign body, the time elapsed after perforation, and the general medical conditions of the cases.<sup>[4]</sup> Although primary repair is usually a good alternative in the acute period, surgeons may require more aggressive interventions in delayed cases, and the decision-making process may be troublesome. In infected and delayed cases, mediastinal or cervical drainage with drainage tubes, exclusion, diversion, T-tube placement, and esophagectomy may be preferred for mediastinal rehabilitation.<sup>[5]</sup> The length of the esophagus should be complete for these methods, except for esophagectomy. If a part of the esophagus is necrotic, esophagectomy must be performed. In the case of our patient, we preferred to perform distal esophagectomy and thoracic esophagostomy. Other techniques were not appropriate for this patient as the distal esophagus was necrotic, and there was a widespread infection in the mediastinum. Moores and Moores<sup>[6]</sup> reported their intraoperative technique with two cases performed via end thoracic esophagostomy, which is useful to preserve esophageal length for subsequent reconstruction without the need for a long-standing percutaneous tube, and it avoids ongoing mediastinal contamination.

We prefer to perform intrathoracic esophagogastric anastomosis where possible. In our opinion, esophagectomy and thoracic esophagostomy are both good options in such cases. This is because the esophageal length is partially preserved, and an esophagogastric anastomosis can be performed more easily in the thorax compared to the cervical region. In addition, this technique is more aesthetic and less dramatic. Indeed, clothes can easily cover the esophagostomy site, and daily care is more effortless. Additionally, cervical esophagogastric anastomosis has more complications than thoracic anastomosis. The incidences of laryngeal nerve paralysis, anastomotic leakage, and aspiration pneumonia are higher in cervical approaches than in thoracic approaches. Another problem is that pediatric patients may have

severe anastomotic tension in the stomach to pull them up to the cervical region since their stomachs are small. In such cases, a gastrostomy tube can be placed in the stomach, and the stomach can be expanded in a few months by parenteral feeding. The main disadvantage of this procedure is that the esophagostomy remains in an infective intrathoracic environment. However, if the thoracic esophagostomy is performed well and is accompanied by an aggressive approach against infections, there should not be any issues.<sup>[4,7,8]</sup> Therefore, thoracic anastomosis should be preferred in such patients. In our case, a thoracic anastomosis was done above the azygos vein. The gastric fundus was fixed on the mediastinum as an antireflux mechanism. Symptoms related to reflux did not occur during the postoperative period.

In conclusion, thoracic esophagostomy and subsequent esophagectomy are extremely rare operations in the management of benign esophageal perforations in children. Although this patient is a rare case, this technique should be performed in benign large esophageal perforations that cannot be treated by other methods. We believe this can be a safe and useful technique in carefully selected cases.

**Patient Consent for Publication:** A written informed consent was obtained from each patient.

**Data Sharing Statement:** The data that support the findings of this study are available from the corresponding author upon reasonable request.

**Author Contributions:** Concept - A.E.; Design - Y.A., A.B.U.; Supervision - A.E.; Resources - Y.A., A.B.U., A.E.; Materials - Y.A., A.B.U., A.E.; Data Collection and/or Processing - Y.A., A.B.U.; Analysis and/or Interpretation - Y.A., A.B.U., A.E.; Literature Search - Y.A., A.B.U.; Writing Manuscript - Y.A., A.B.U., A.E.; Critical Review - Y.A., A.E.

**Conflict of Interest:** The authors declared no conflicts of interest with respect to the authorship and/or publication of this article.

**Funding:** The authors received no financial support for the research and/or authorship of this article.

## REFERENCES

1. Eroglu A, Can Kürkçüoğlu I, Karaoganoğlu N, Tekinbaş C, Yılmaz O, Başoğlu M. Esophageal perforation: The importance of early diagnosis and primary repair. *Dis Esophagus* 2004;17:91-4.
2. Eroglu A, Turkyılmaz A, Aydın Y, Yekeler E, Karaoglanoglu N. Current management of esophageal perforation: 20 years experience. *Dis Esophagus* 2009;22:374-80.
3. Turkyılmaz A, Aydın Y, Yılmaz O, Aslan S, Eroğlu A, Karaoğlanoğlu N. Ozofagus yabancı cisimleri: 188 olgunun analizi. *Ulus Travma Acil Cerrahi Derg* 2009;15:222-7.

4. Eroglu A, Aydin Y, Yilmaz O. Thoracic perforations-surgical techniques. *Ann Transl Med* 2018;6:40.
5. Bufkin BL, Miller JI Jr, Mansour KA. Esophageal perforation: Emphasis on management. *Ann Thorac Surg* 1996;61:1447-51.
6. Moores CR, Moores D. Thoracic esophagostomy: A novel surgical approach for preservation of esophageal length for use in subsequent reconstruction. *J Thorac Cardiovasc Surg* 2009;138:1439-41.
7. Sancheti MS, Fernandez FG. Surgical management of esophageal perforation. *Operative Techniques in Thoracic and Cardiovascular Surgery* 2016;20:234-50.
8. Jones WG 2nd, Ginsberg RJ. Esophageal perforation: A continuing challenge. *Ann Thorac Surg* 1992;53:534-43.